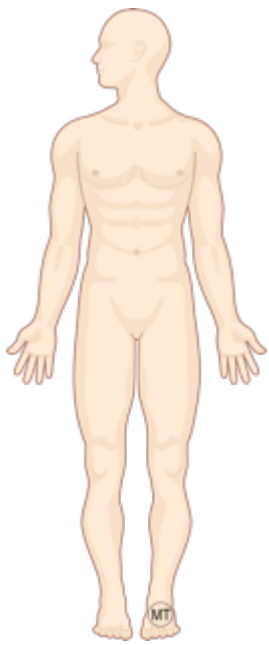
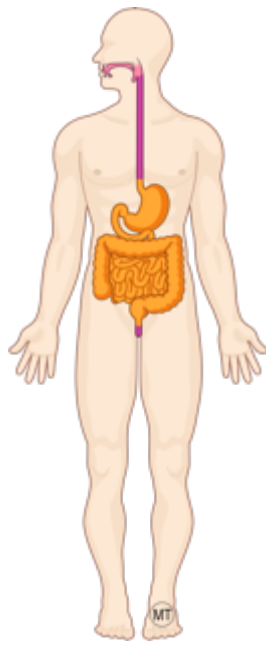


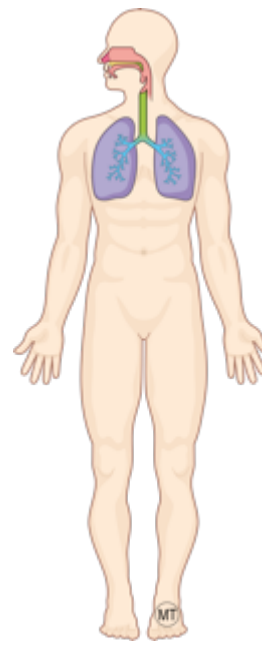
Schémas Epithéliums



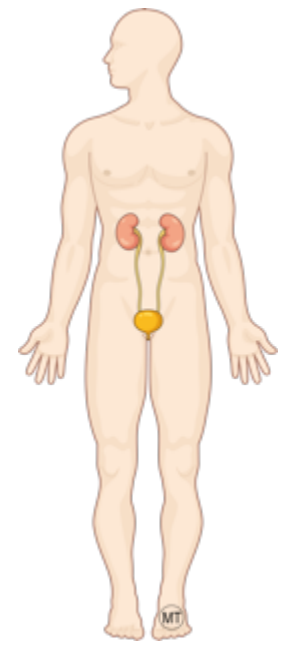
La surface du corps



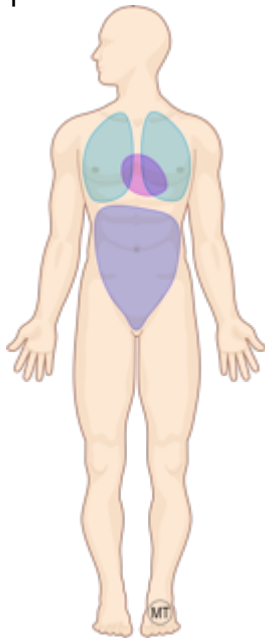
Le tube digestif



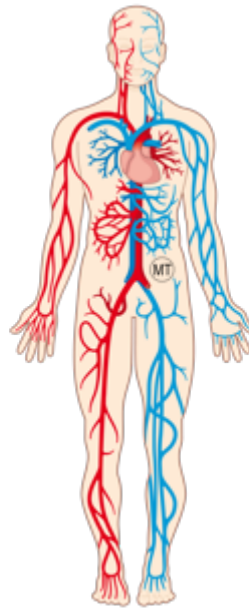
Les voies respiratoires



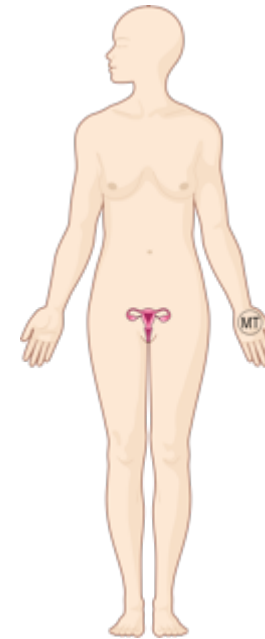
Les voies urinaires



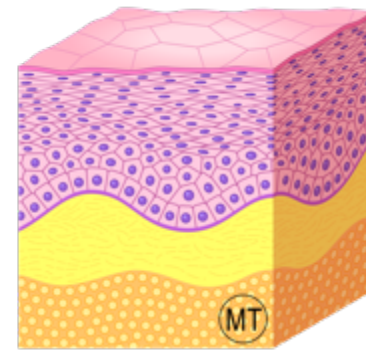
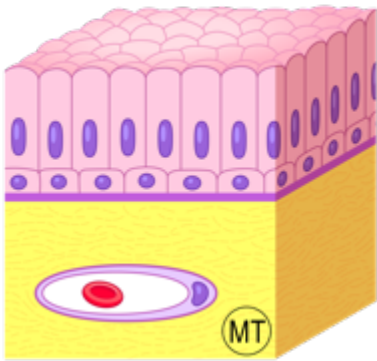
Les cavités fermées



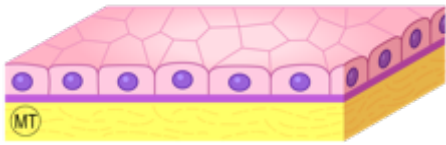
Les cavités cardio-vasculaires




Les voies génitales



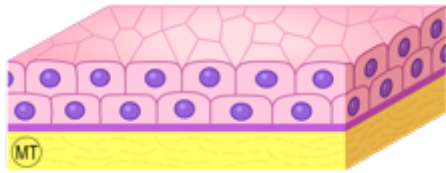
La peau



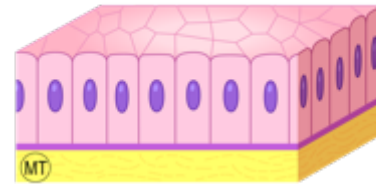
Epithélium simple



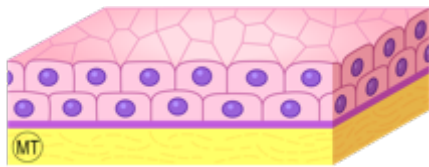
Epithélium pavimenteux



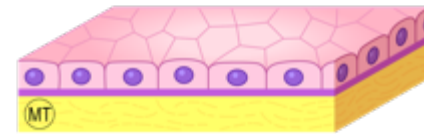
Epithélium stratifié



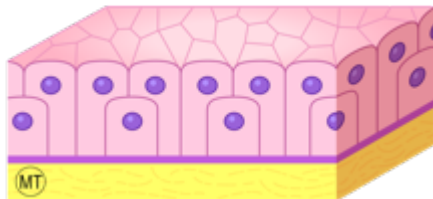
Epithélium cylindrique



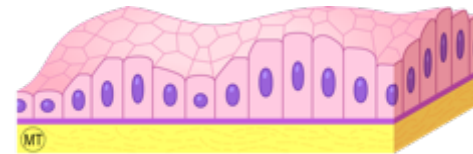
Epithélium stratifié



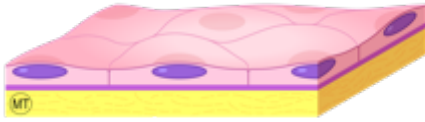Epithélium cubique



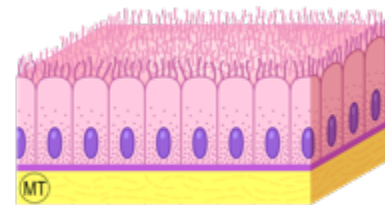
Epithélium pseudo-stratifié



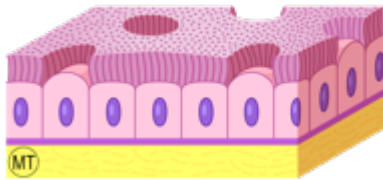
Epithélium polymorphe



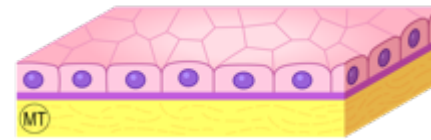
Epithélium pavimenteux simple



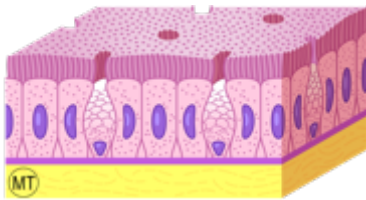
Epithélium cylindrique simple à stéréocils



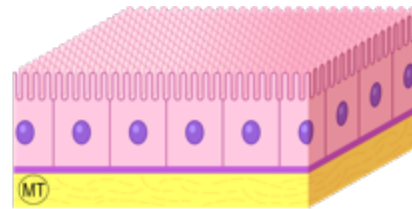
Epithélium cylindrique simple cilié



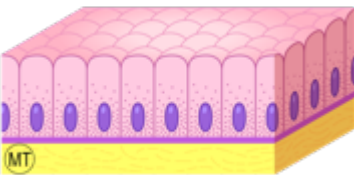
Epithélium cubique simple



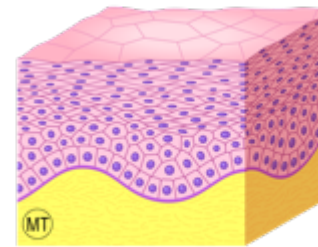
Epithélium cylindrique simple à plateau strié et à cellules caliciformes



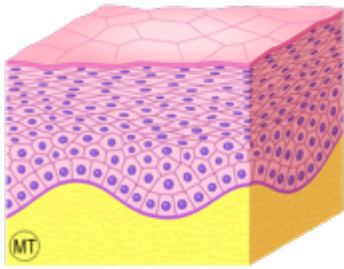
Epithélium cubique simple à bordure en brosse



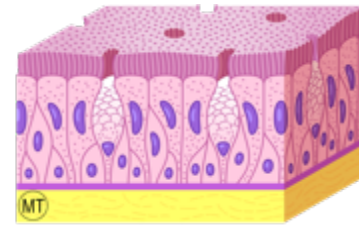
Epithélium cylindrique simple à cellules muqueuses fermées



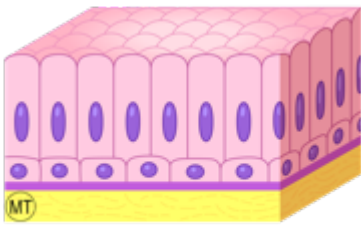
Epithélium pavimenteux stratifié non kératinisé



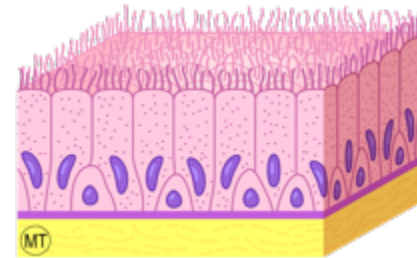
Epithélium pavimenteux stratifié kératinisé



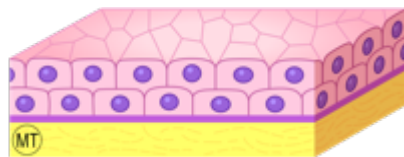
Epithélium cylindrique pseudo-stratifié cilié



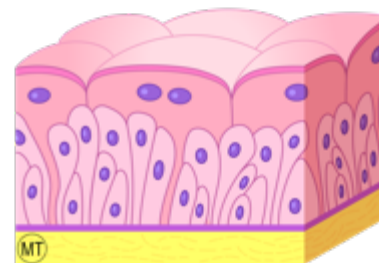
Epithélium cylindrique bistratifié



Epithélium cylindrique pseudo-stratifié à stéréocils

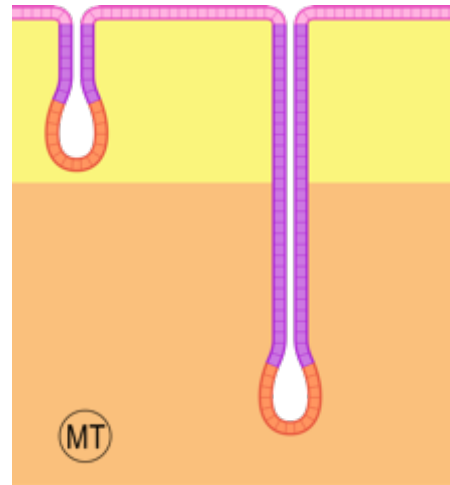
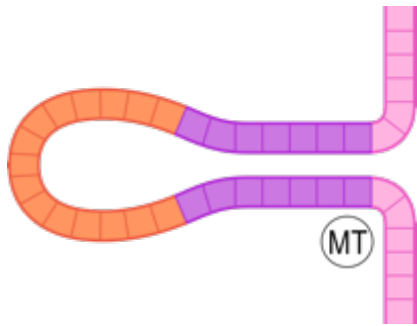


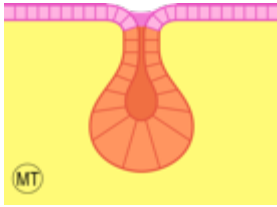
Epithélium cubique bistratifié



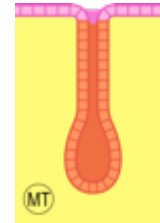
Epithélium polymorphe pseudo-stratifié



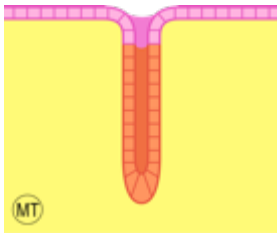




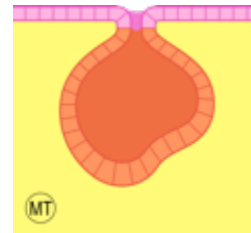
Glande acineuse




Glande tubulo-acineuse



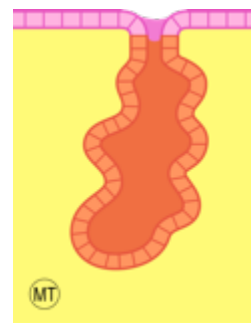
Glande tubuleuse droite



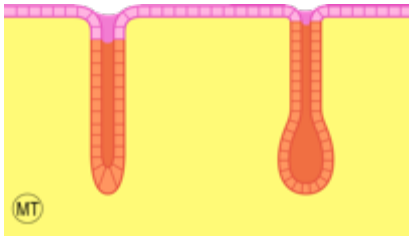
Glande alvéolaire



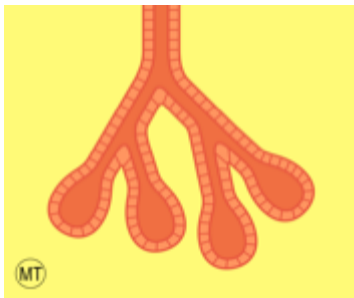
Glande tubuleuse contournée



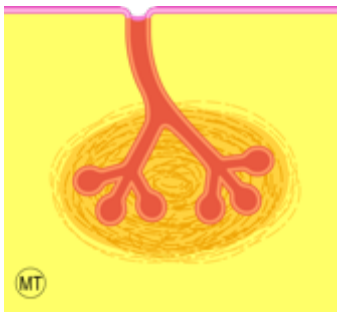
Glande tubulo-alvéolaire



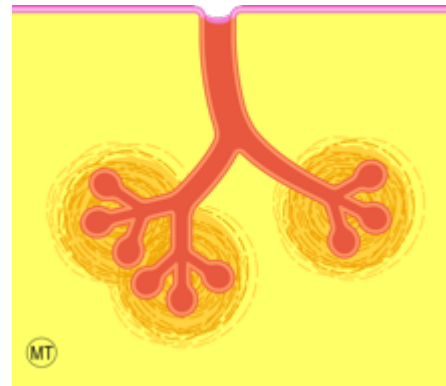
Glandes simples



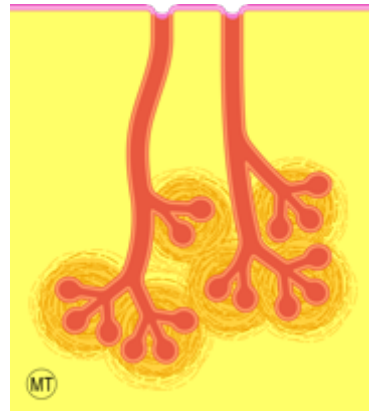Glandes composées



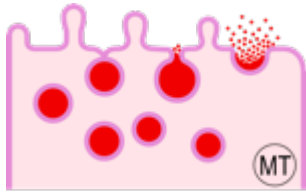
Glandes unilobulées



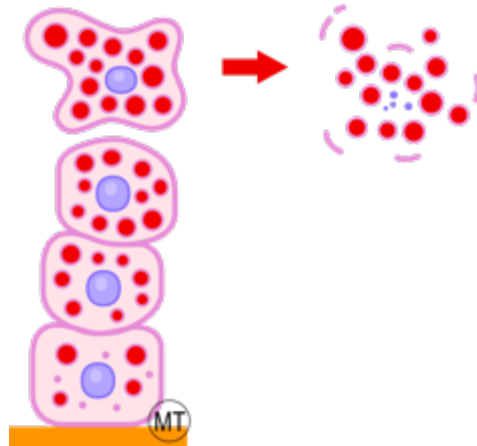
Glandes multilobulées, conglomerées



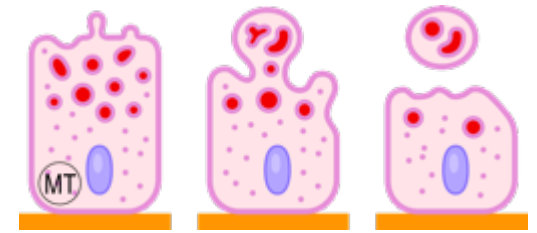
Glandes multilobulées, agminées



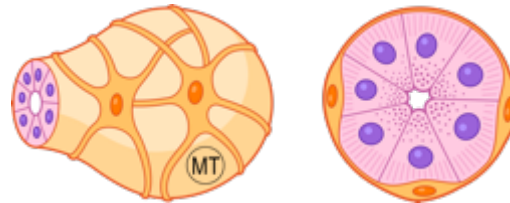
Excrétion mérocrine



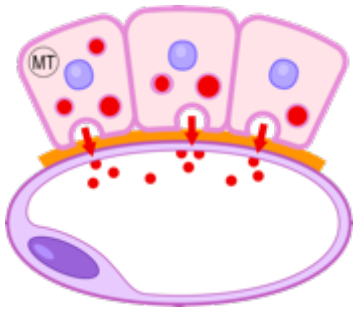
Excrétion holocrine



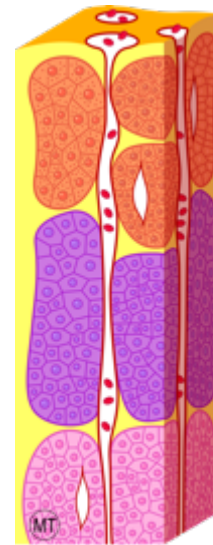
Excrétion apocrine



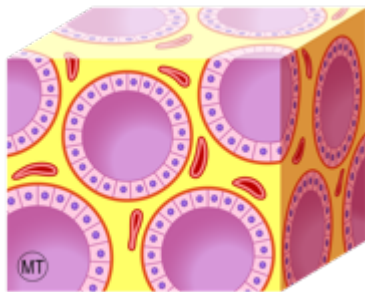
Cellules myoépithéliales



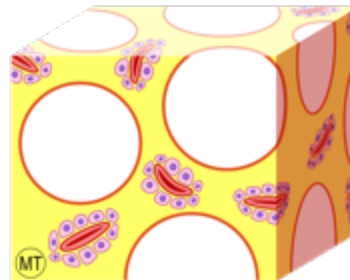
Glande endocrine
(entité histologique)



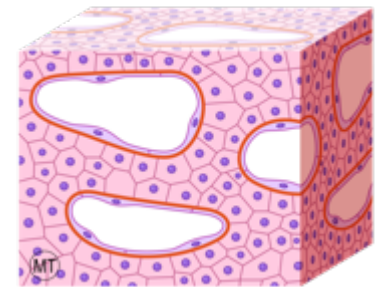
Glande trabéculaire orientée



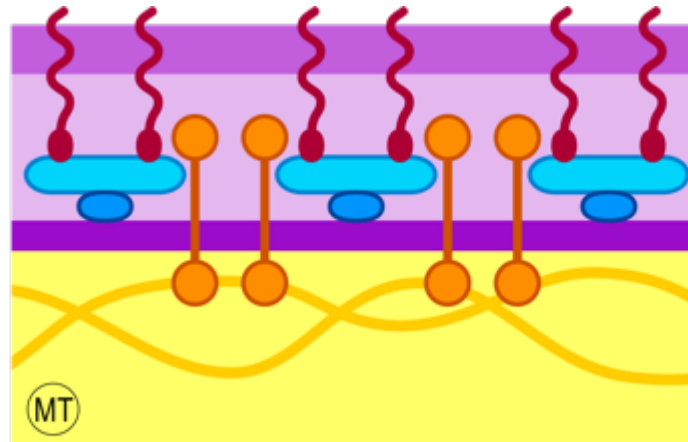
Glande vésiculaire



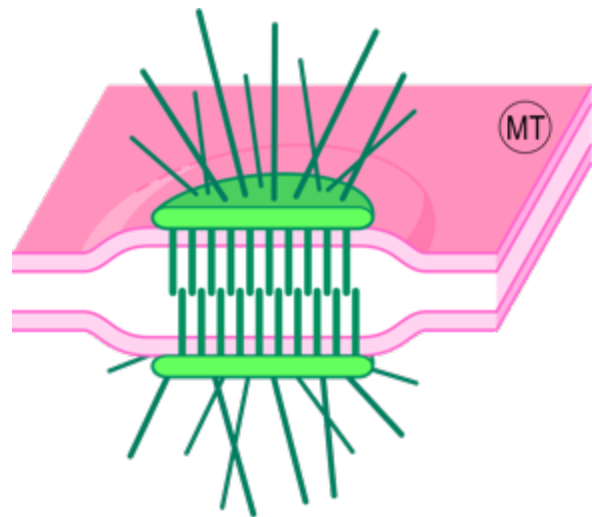
Glande interstitielle



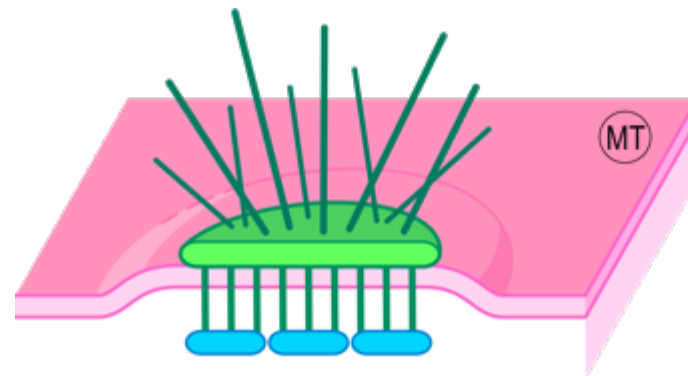
Glande trabéculaire non orientée



Membrane basale



Desmosome



Hémidésososome