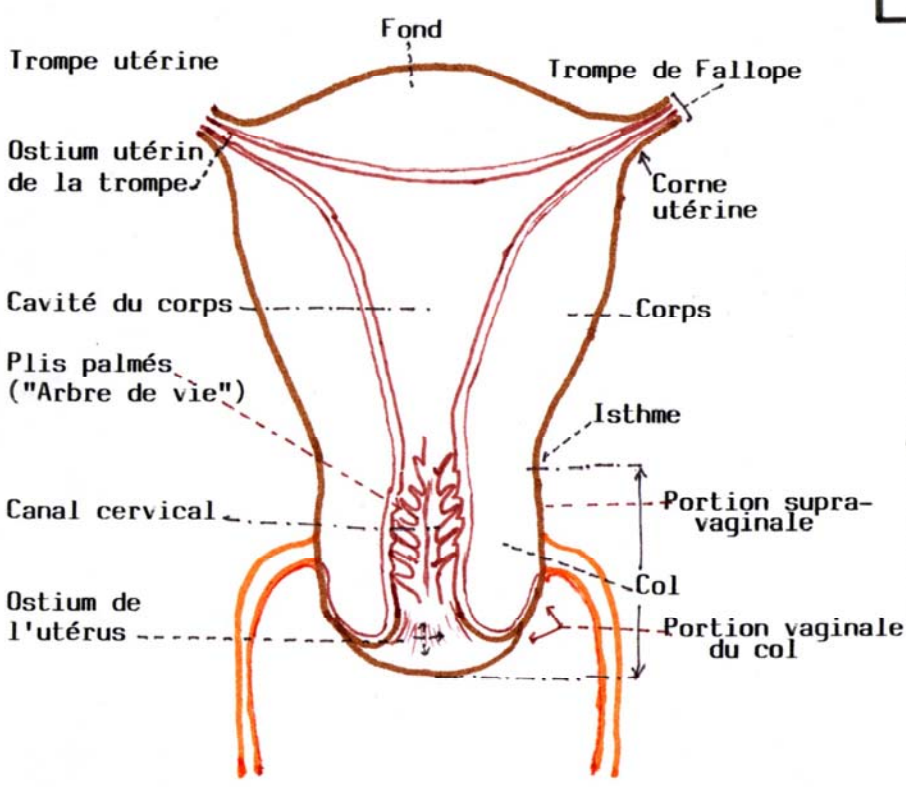
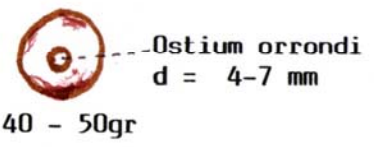
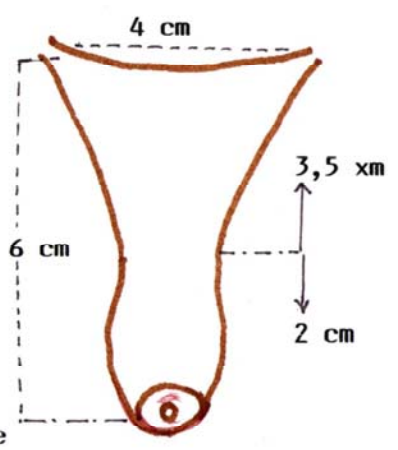


UTERUS : COUPE FRONTALE SCHEMATIQUE

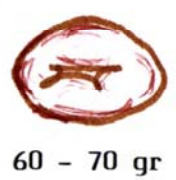
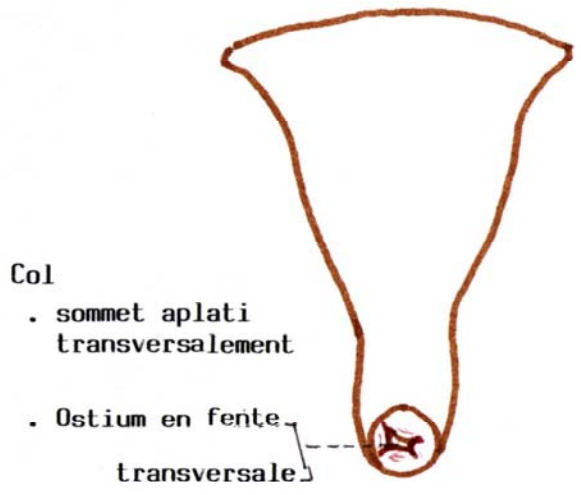


VARIATIONS MORPHOLOGIQUES AVEC LA PARITE A B C

A. NULLIPARE



B. PRIMIPARE



C. GRANDE MULTIPARE AGEE

