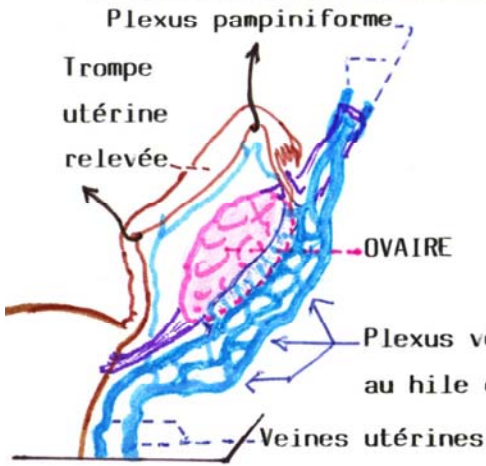
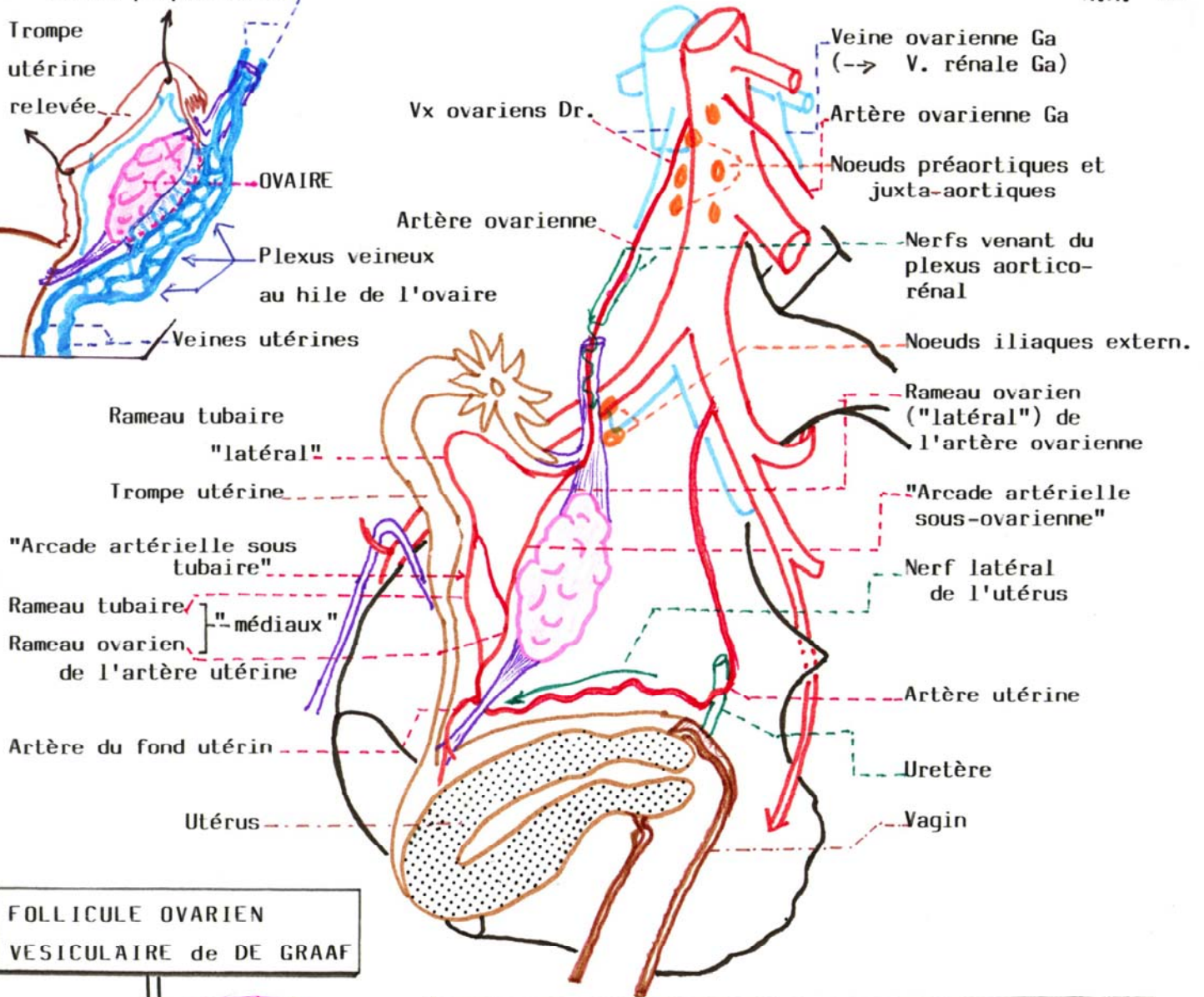


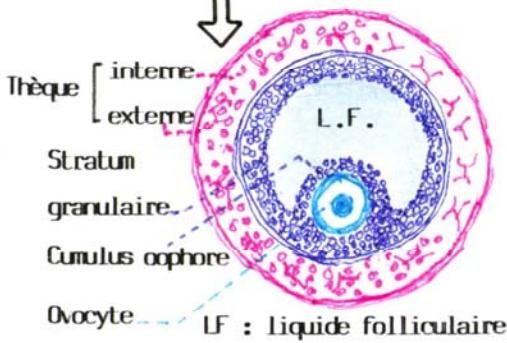
PLEXUS VEINEUX OVARIEN



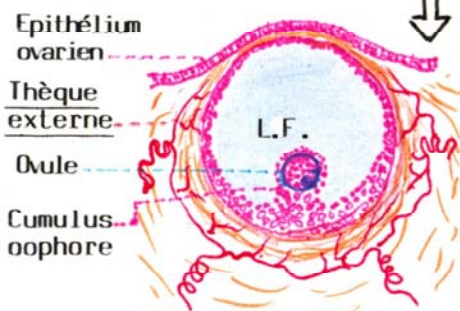
ARTERES DE L'OVAIRE et de la TROMPE UTERINE



FOLLICULE OVARIEN VESICULAIRE de DE GRAAF




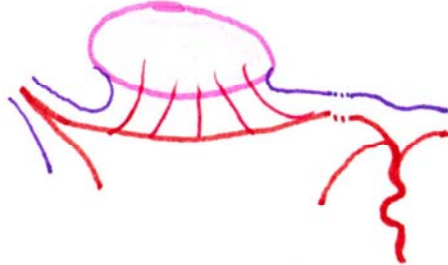
FOLLICULE PRES DE SA RUPTURE



4 TYPES DE VASCULARISATION ARTERIELLE de l'OVAIRE

1. Arcade anastomotique

2. 2 bouquets avec fine anastomose



3. Prédominance utérine (U)

4. Prédominance ovarienne (O)

