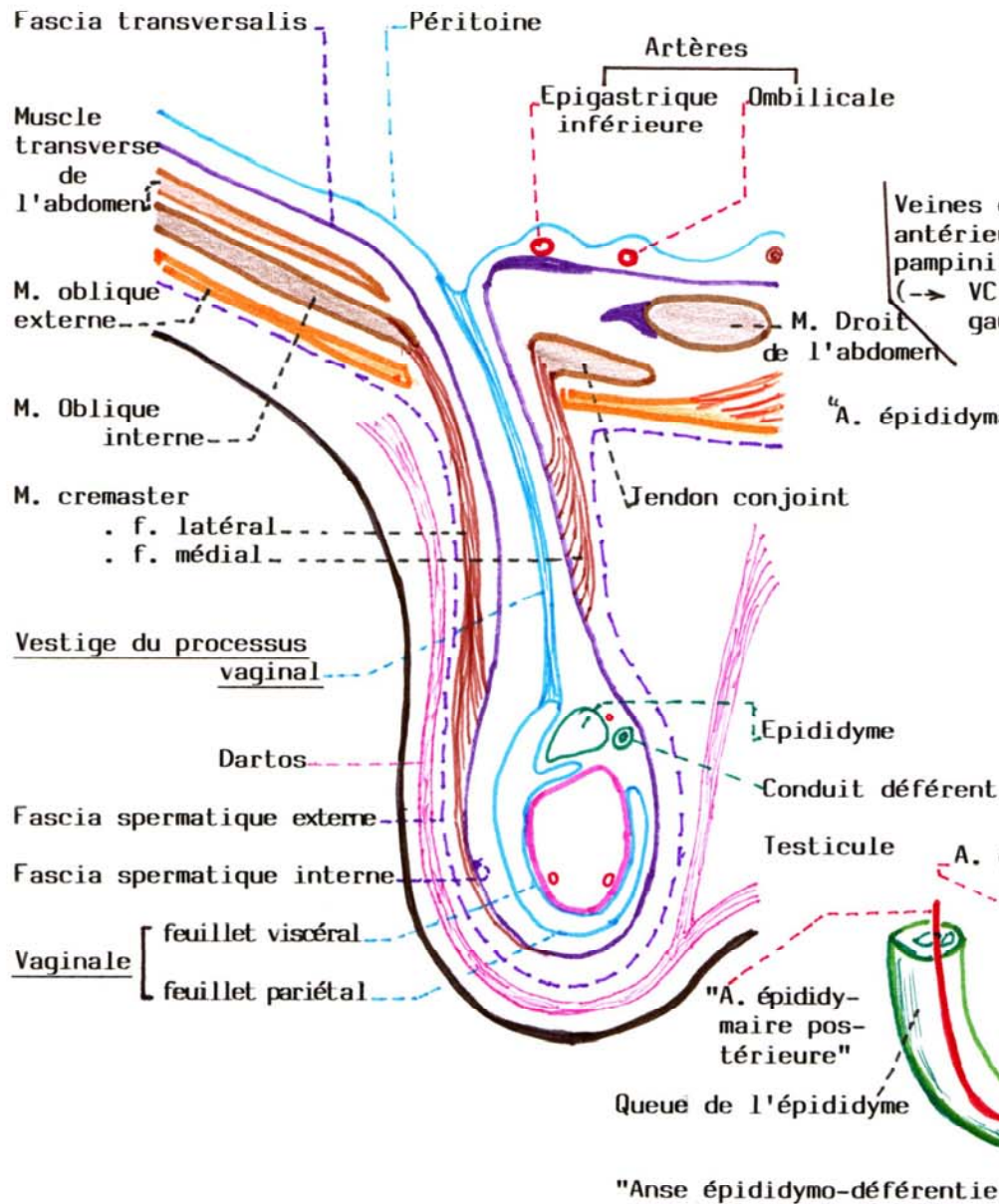
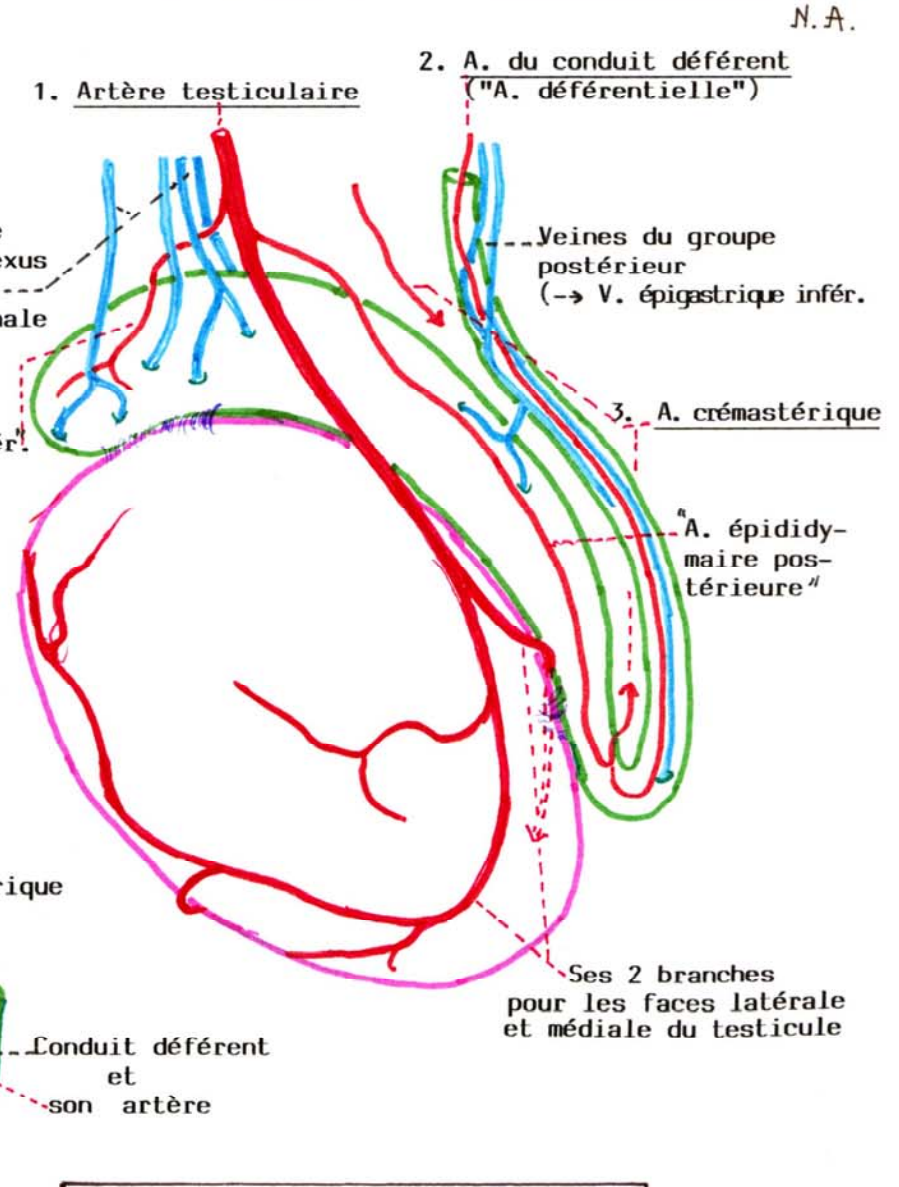


**COUPE FRONTALE PAR LE VESTIGE DU PROCESSUS VAGINAL : SCHEMATIQUE**



**VASCULARISATION DU COMPLEXE EPIDIDYMO-TESTICULAIRE VUE MEDIALE**



**ANASTOMOSE ARTERIELLE A L'ANSE EPIDIDYMO-DEFERENTIELLE**

N.A.