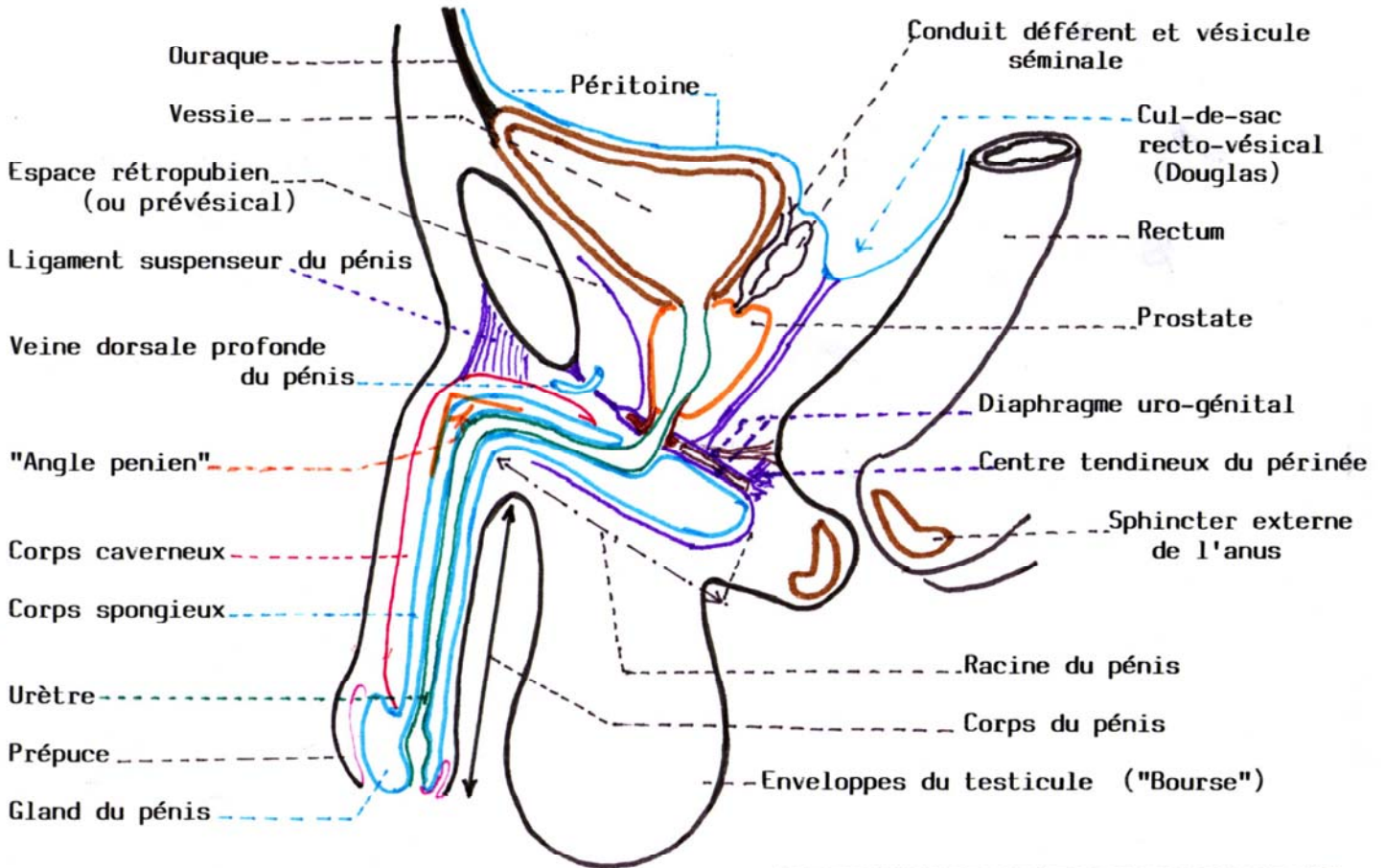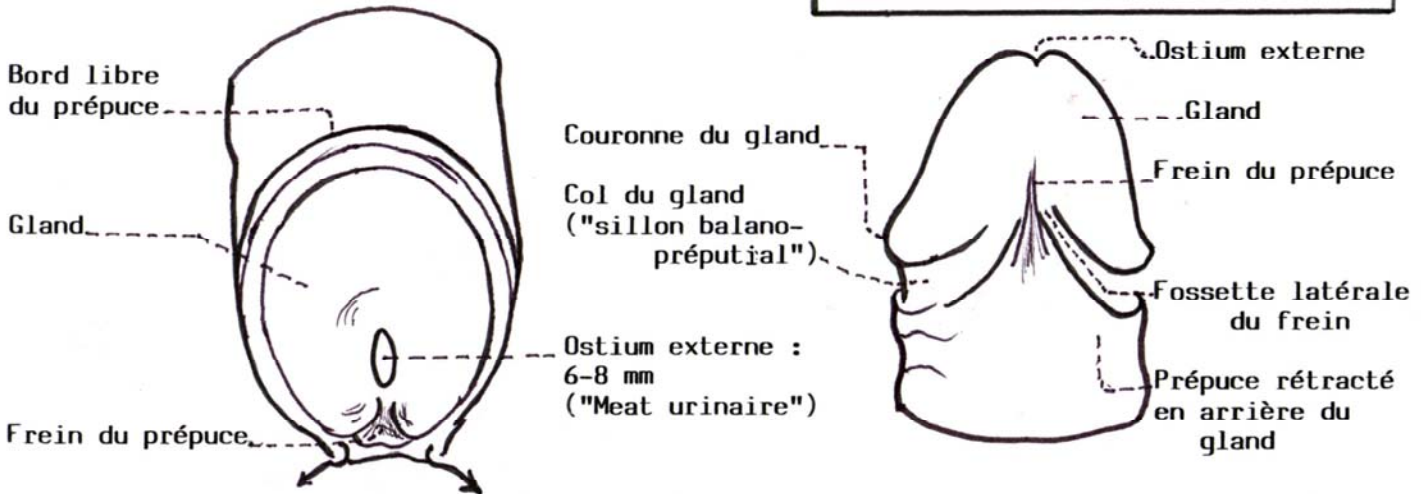


EXTREMITE ANTERIEURE DU PELVIS



2 COUPES SAGITTALES

