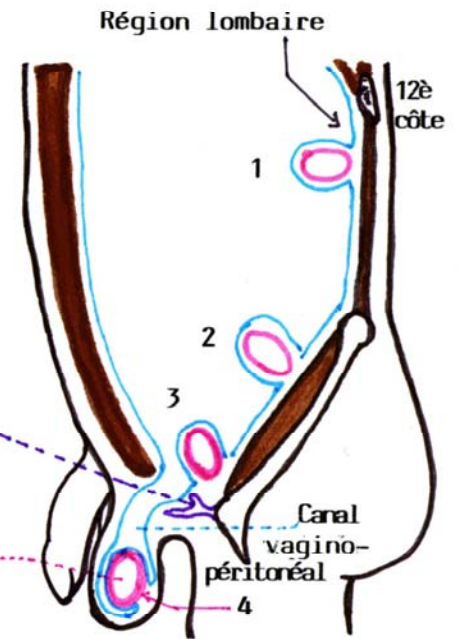
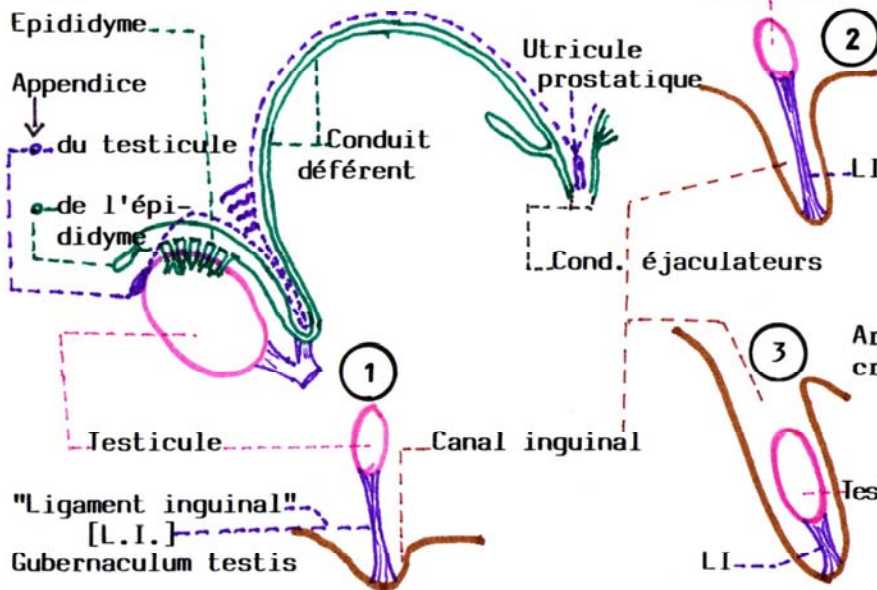


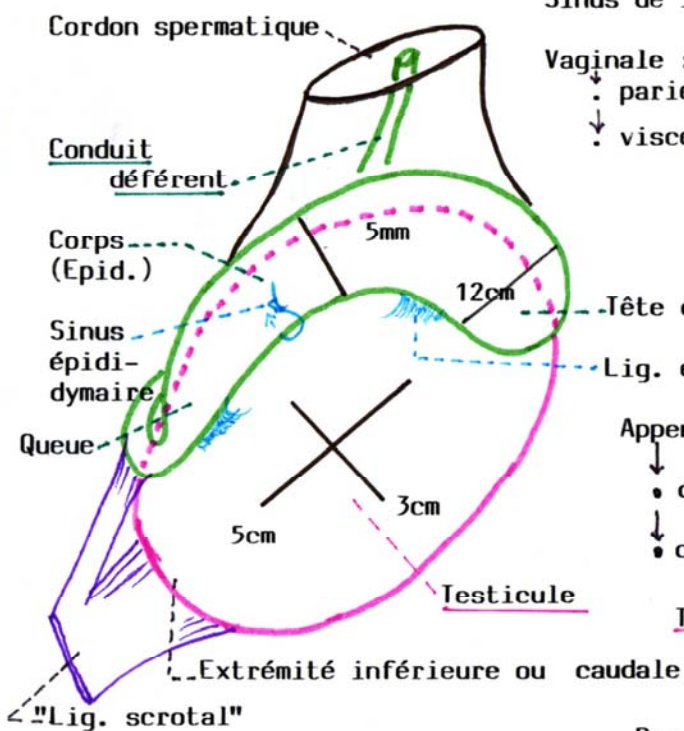
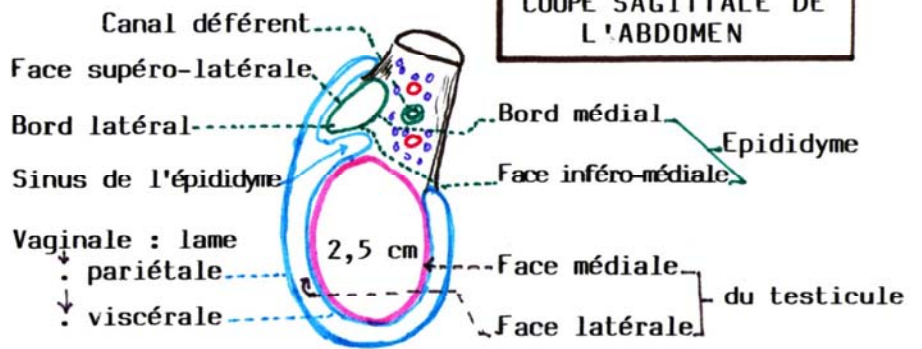
**"DESCENTE" du COMPLEXE EPIDIDYMO-TESTICULAIRE**  
 (Région lombaire -> canal inguinal -> scrotum ("bourse"))

④ Paradidyme (Org. de Giraldes)

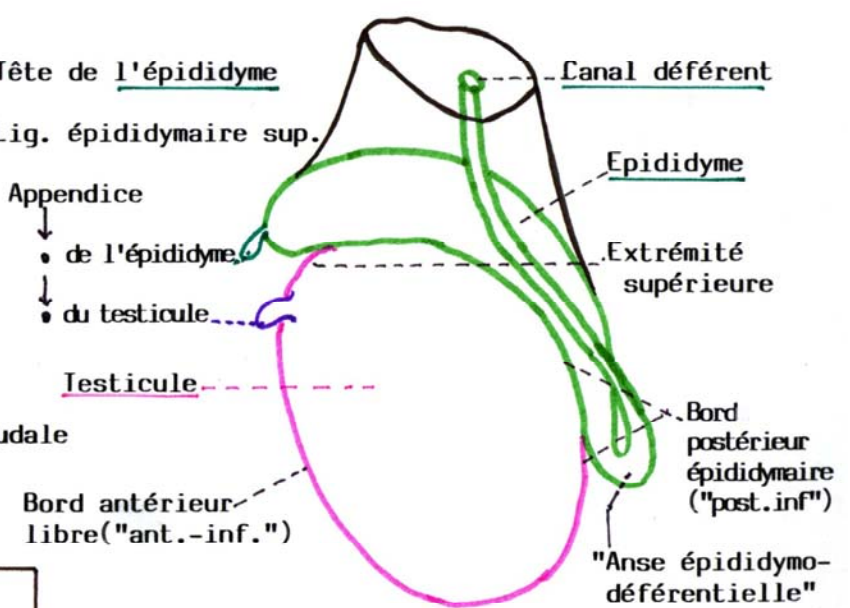


COUPE SAGITTALE DE L'ABDOMEN

COUPE AXIALE



FACE LATÉRALE du TESTICULE et de l'EPIDIDYME



FACE MÉDIALE