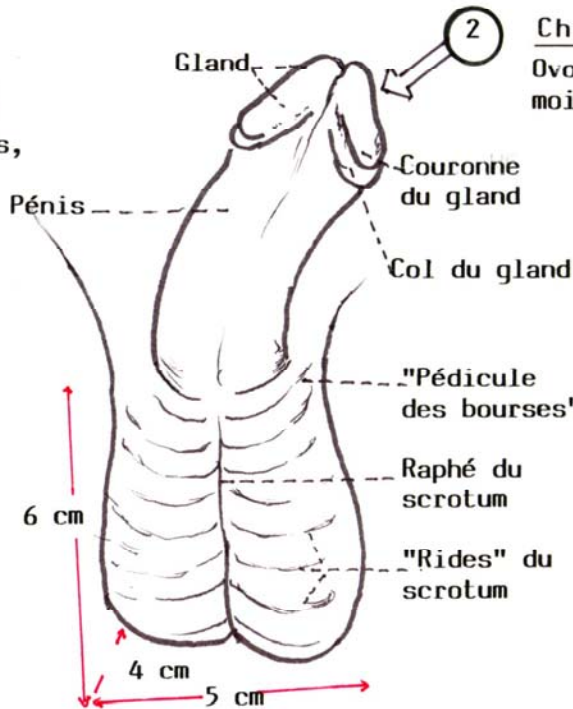
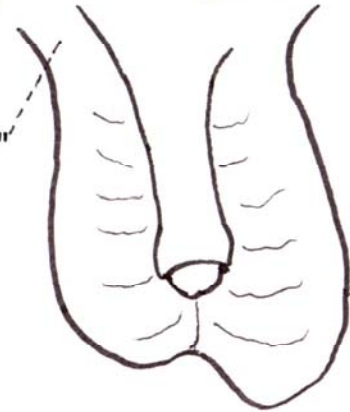


1 Chez l'enfant  
petites, globuleuses,  
fermes



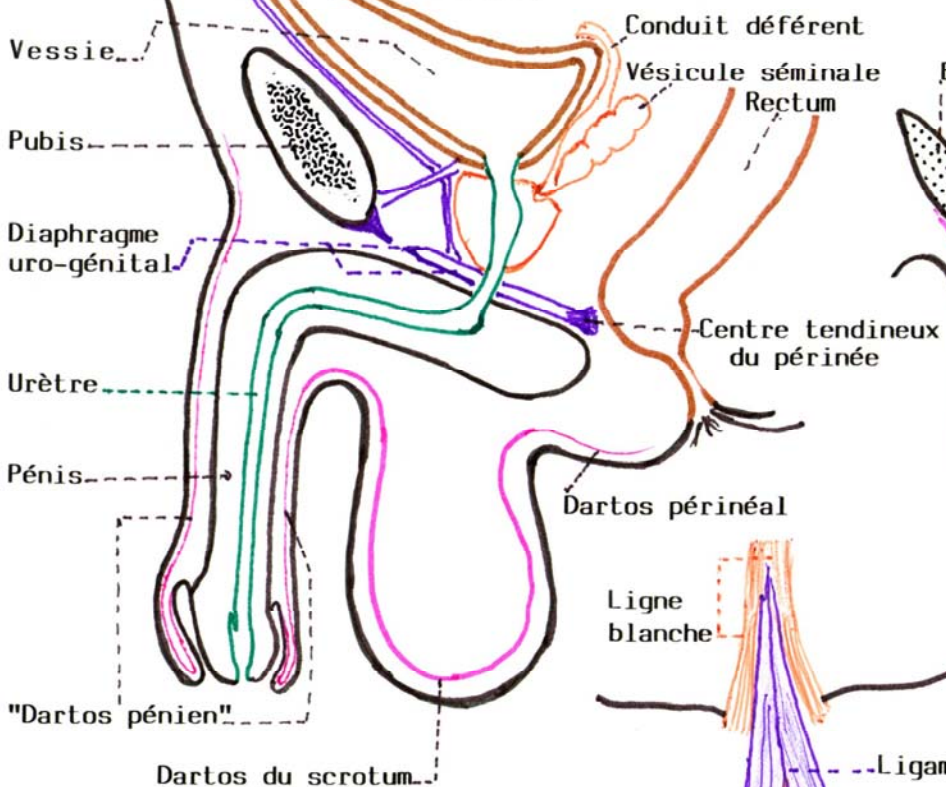
2 Chez l'adulte  
Ovoïdes, plus renflées en bas,  
moitié Ga plus basse que moitié Dr

3 Chez le Vieillard  
flasques, pendantes  
piriformes

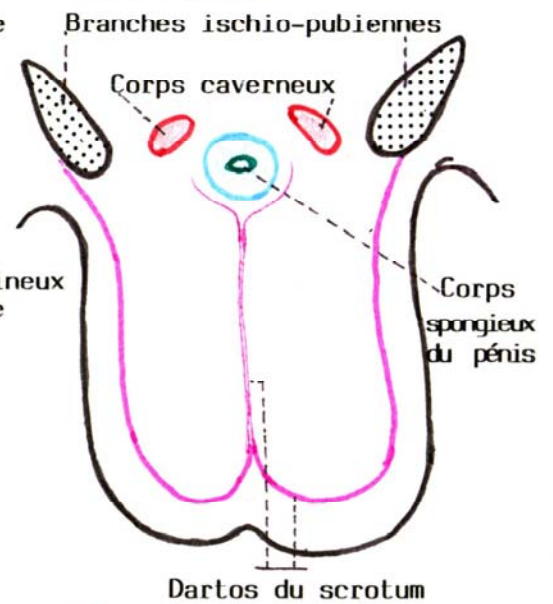


SAGITTALE

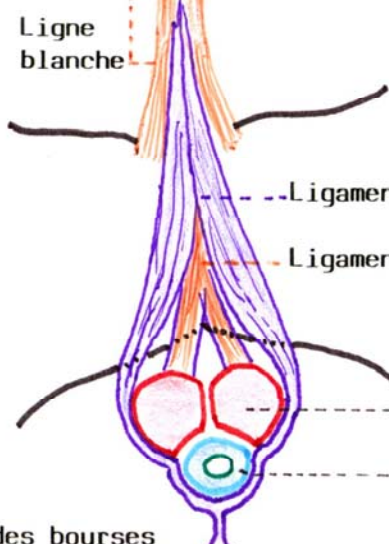
LE DARTUS SUR 2 COUPES



FRONTALE



LE LIGAMENT SUSPENSEUR DU PENIS



Septum ("cloison") des bourses