N.A.

ARTERES DE LA MOELLE EPINIERE

VUE ANTERO-LATERALE DR

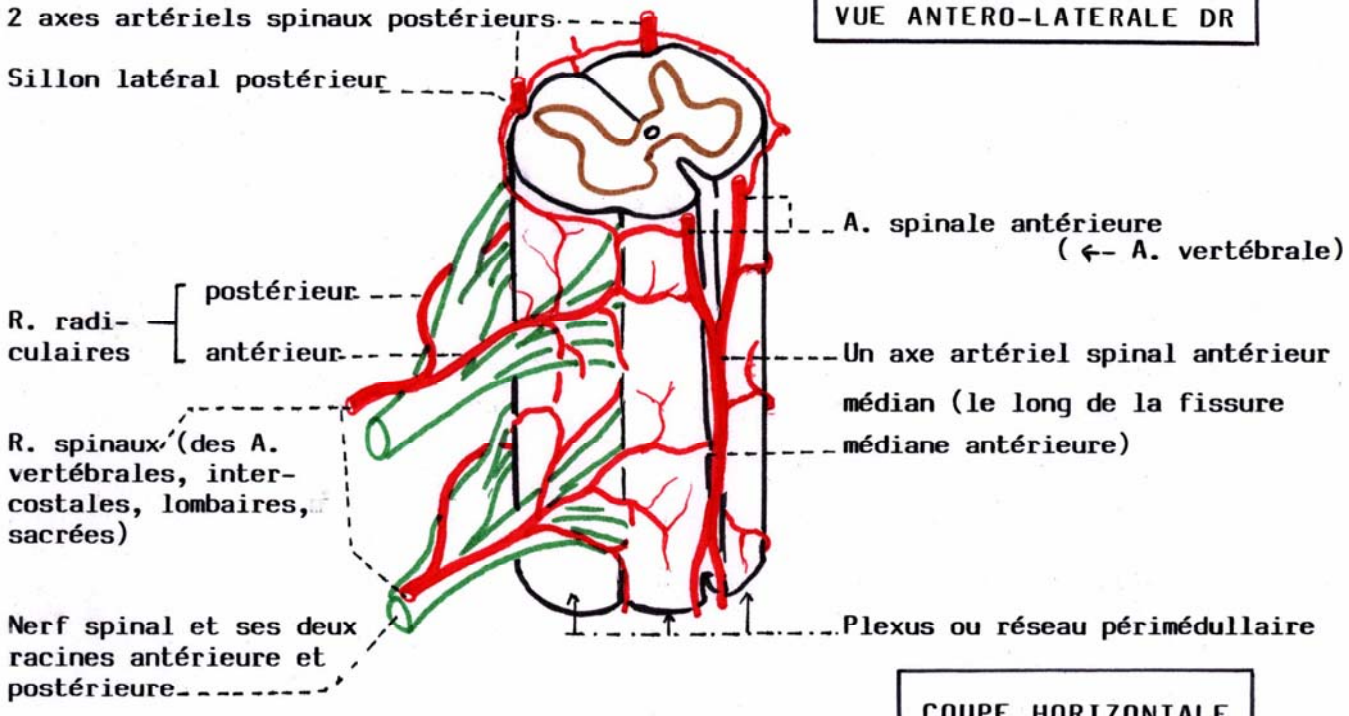

COUPE HORIZONTALE

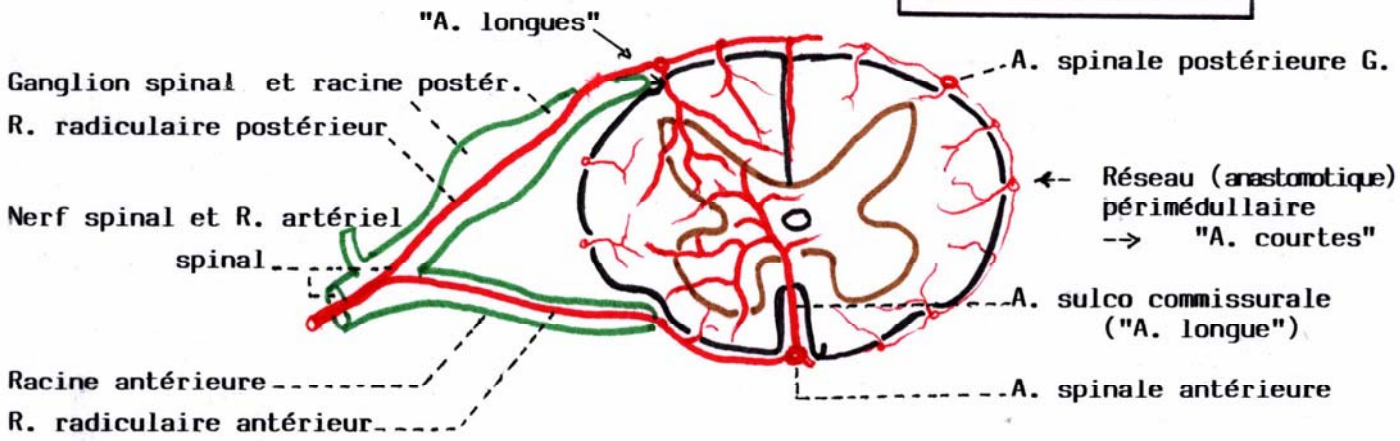

TERRITOIRES ARTERIELS

(Selon Gillilan, 1972)

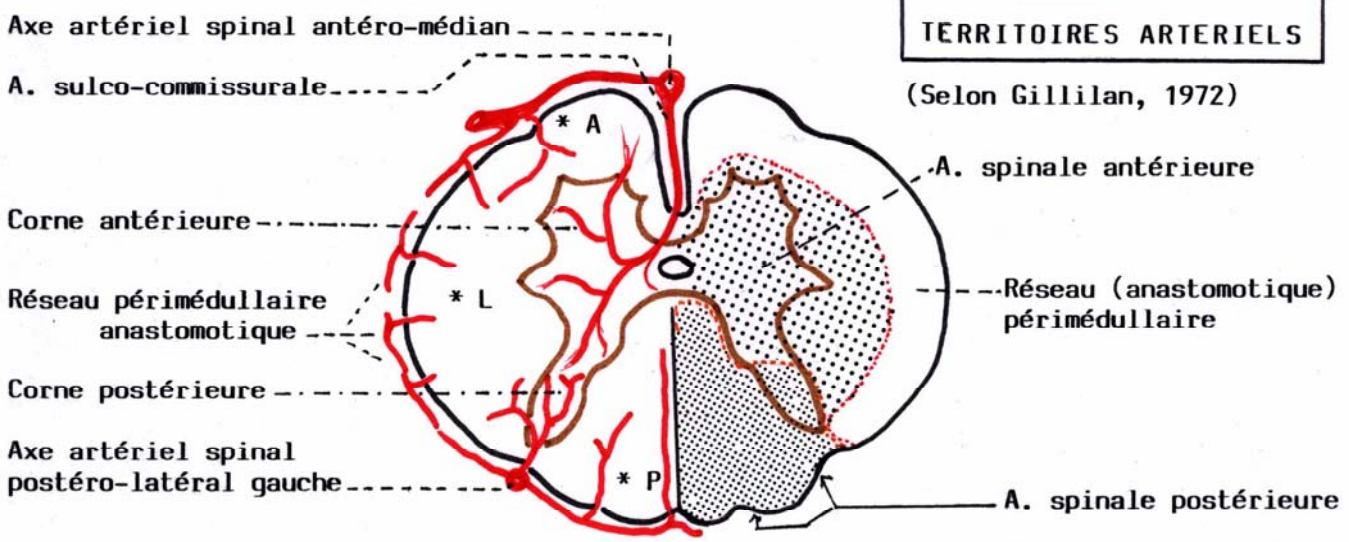

* A, * L, * P : les 3 cordons antérieur, latéral et postérieur