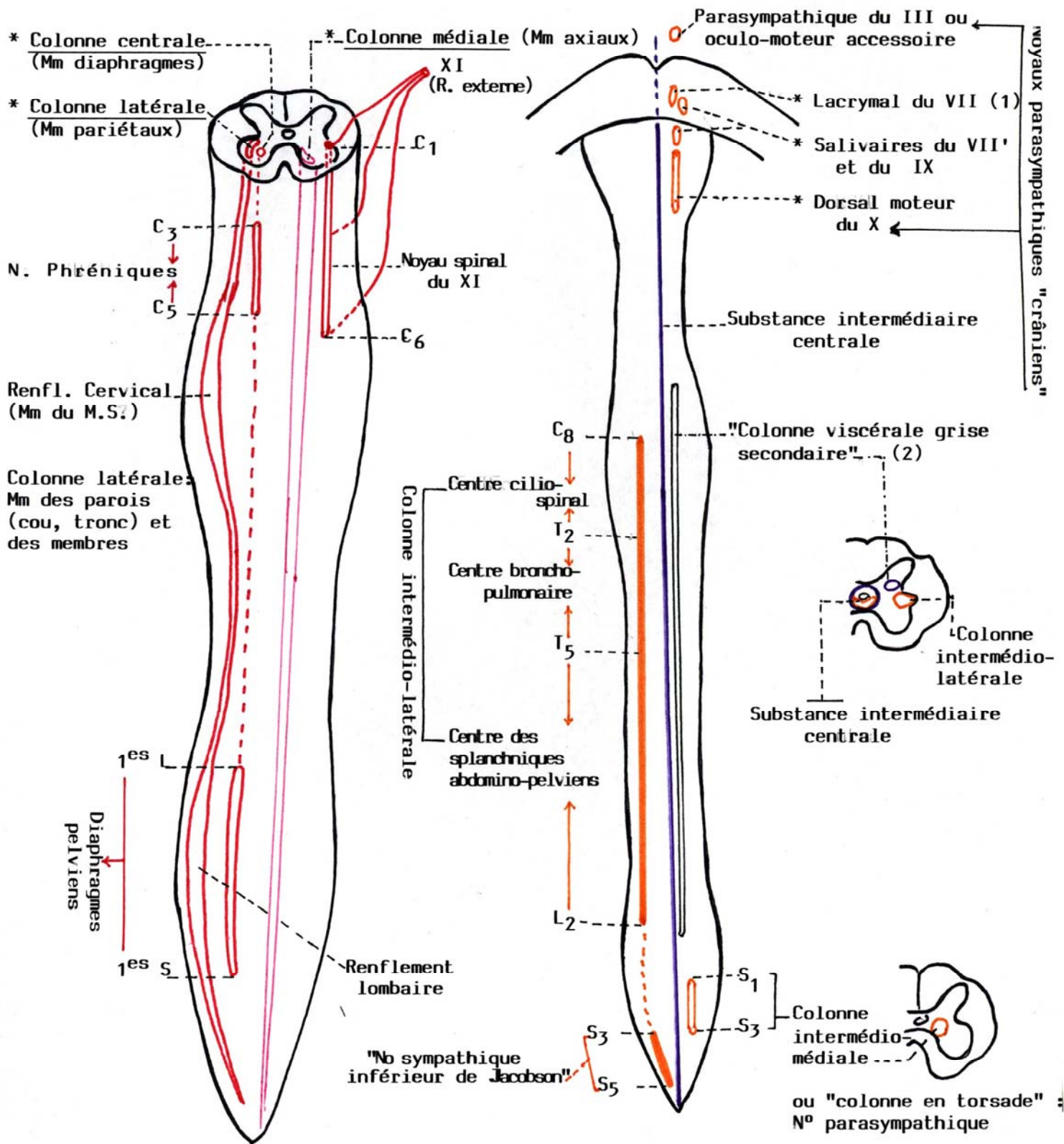


MOELLE EPINIÈRE . COLONNES GRISES

MOTRICITE SOMATIQUE

MOTRICITE ET SENSIBIL. VISCERALES



(1) ou "Noyau lacrymo-muco-nasal"

(2) Secondary visceral gray (dans Crosby)