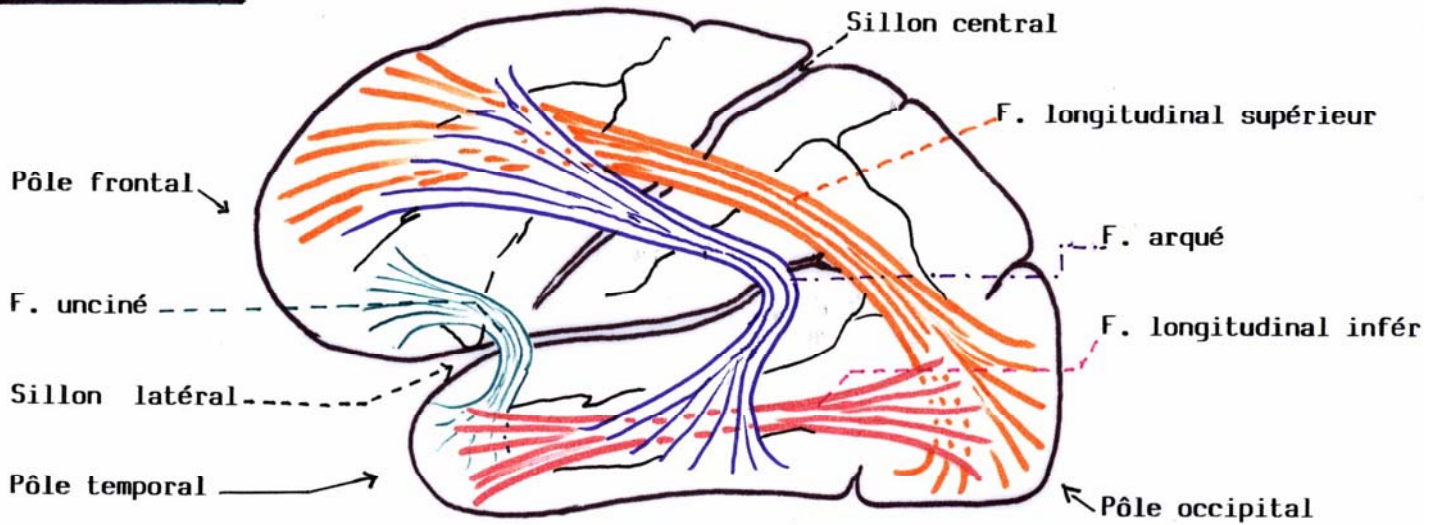
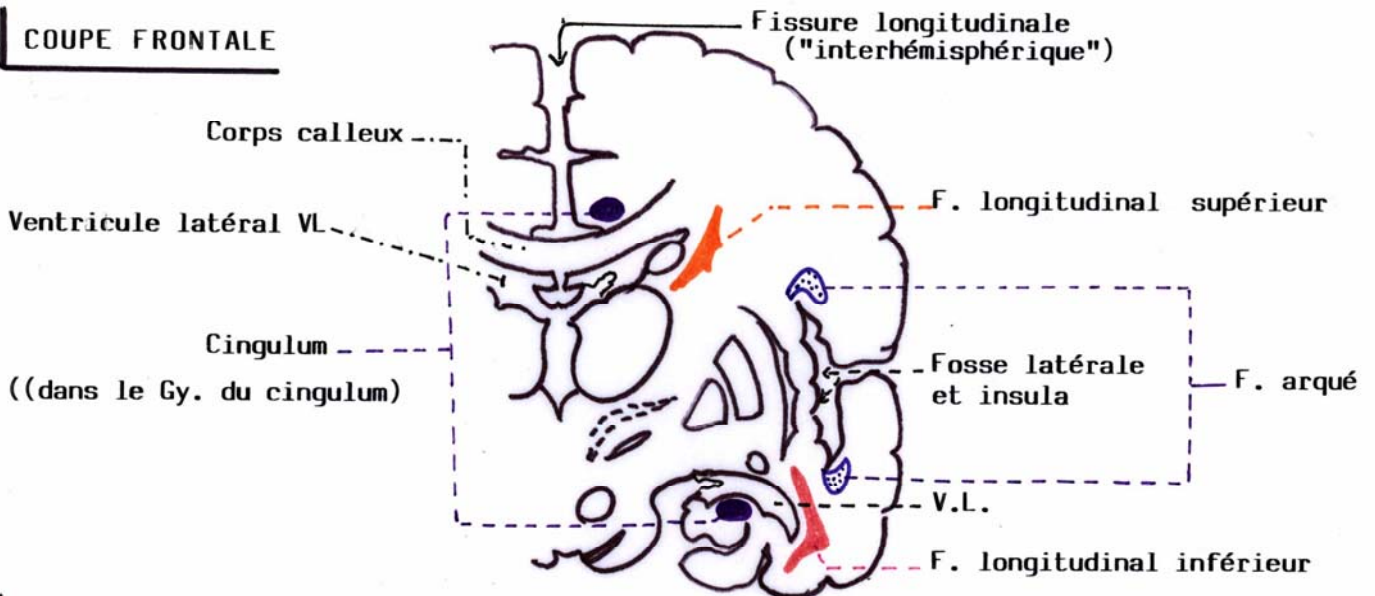


FAISCEAUX (de neurofibres) d'ASSOCIATION INTRA-HEMISPHERIQUES

VUE LATÉRALE



COUPE FRONTALE



VUE MÉDIALE : COUPE SAGITTALE

