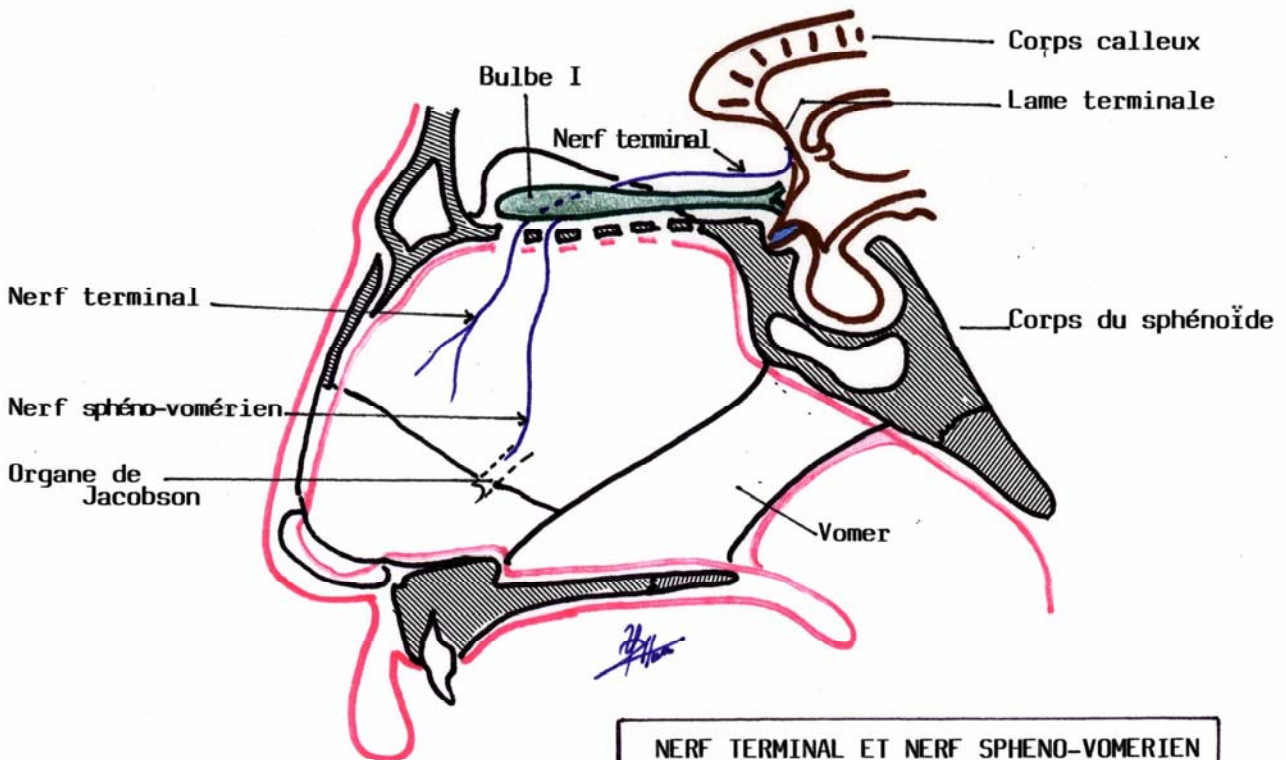
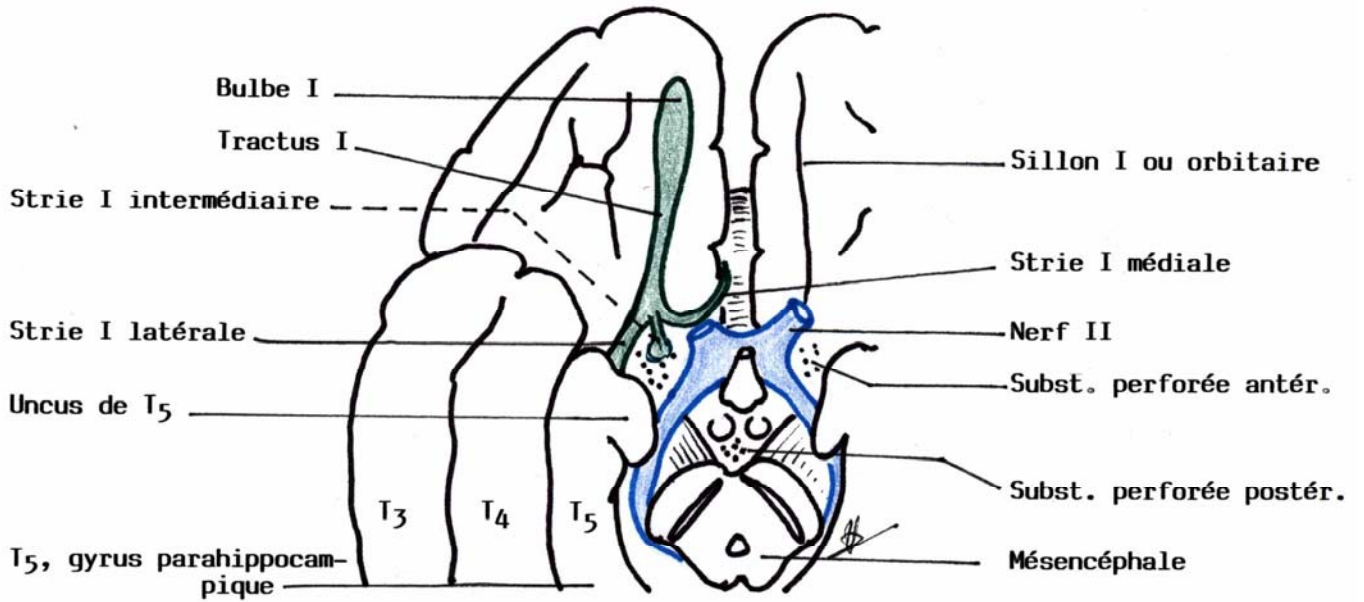


VUE INFÉRIEURE DU CERVEAU HÉMISPHERIQUE

BULBE, TRACTUS et STRIES I



NERF TERMINAL ET NERF SPHENO-VOMÉRIEN