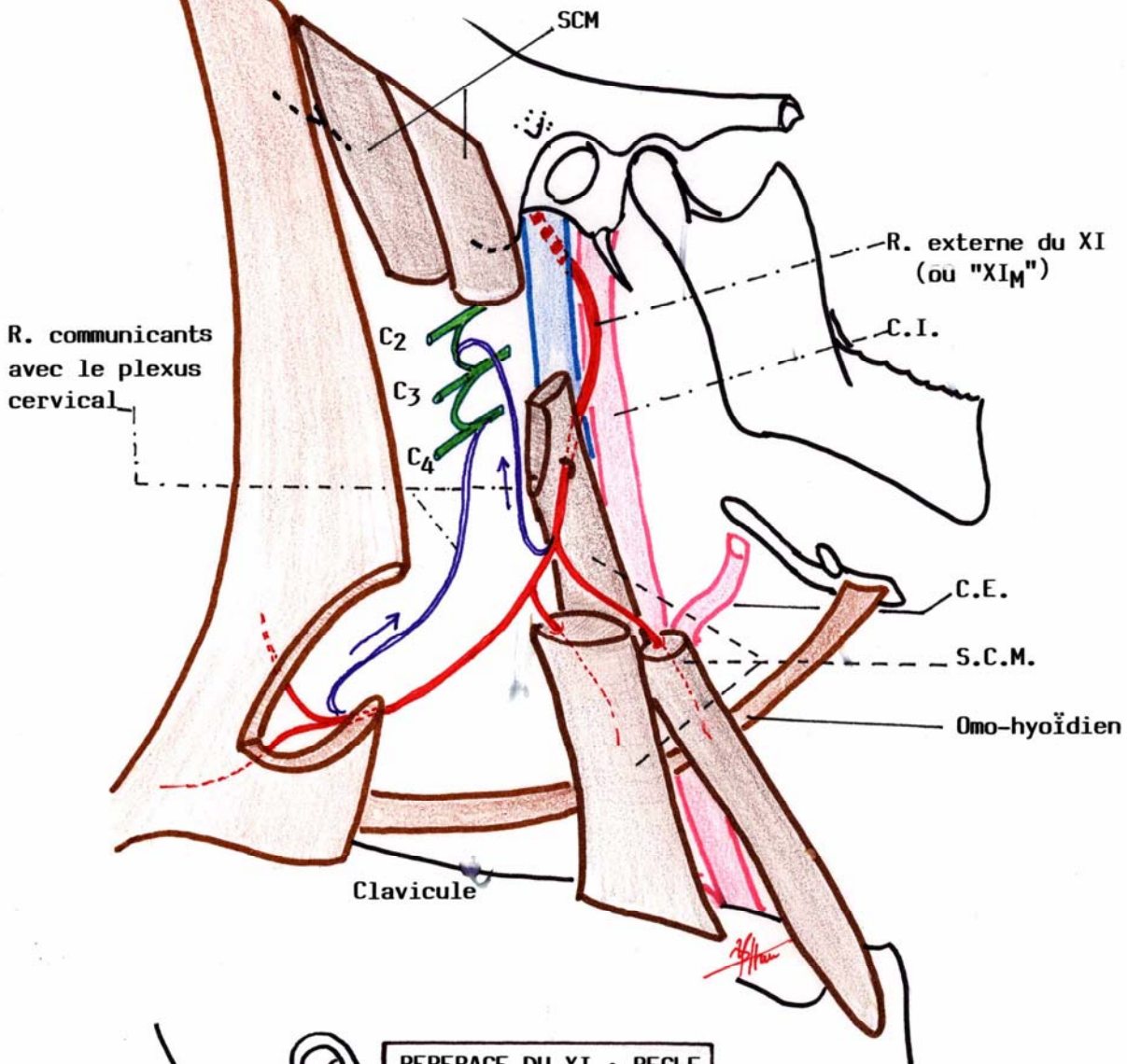
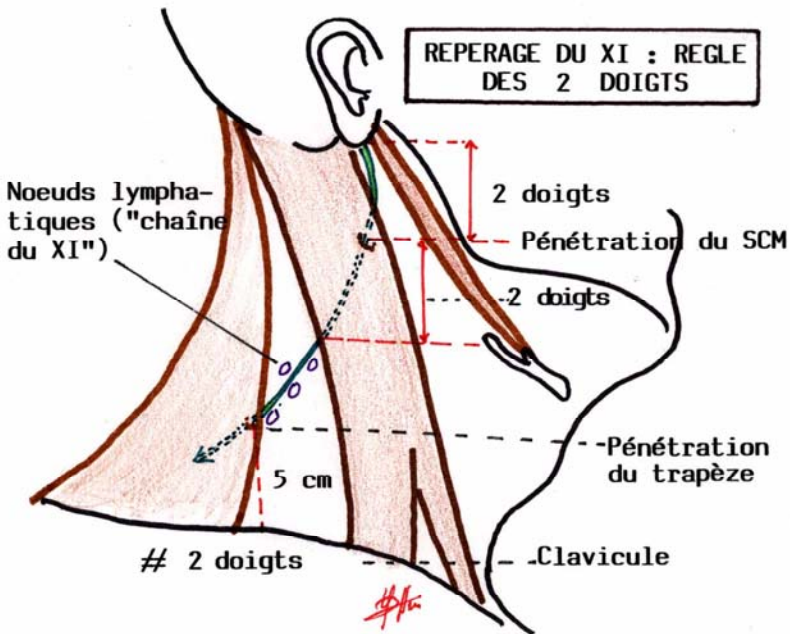


LE NERF CEPHALOXYRE : RAMEAU EXTERNE DU XI ou "XI_M"
("XI MEDULLAIRE")



REPERAGE DU XI : REGLE
DES 2 DOIGTS



XI ET PLEXUS CERVICAL

