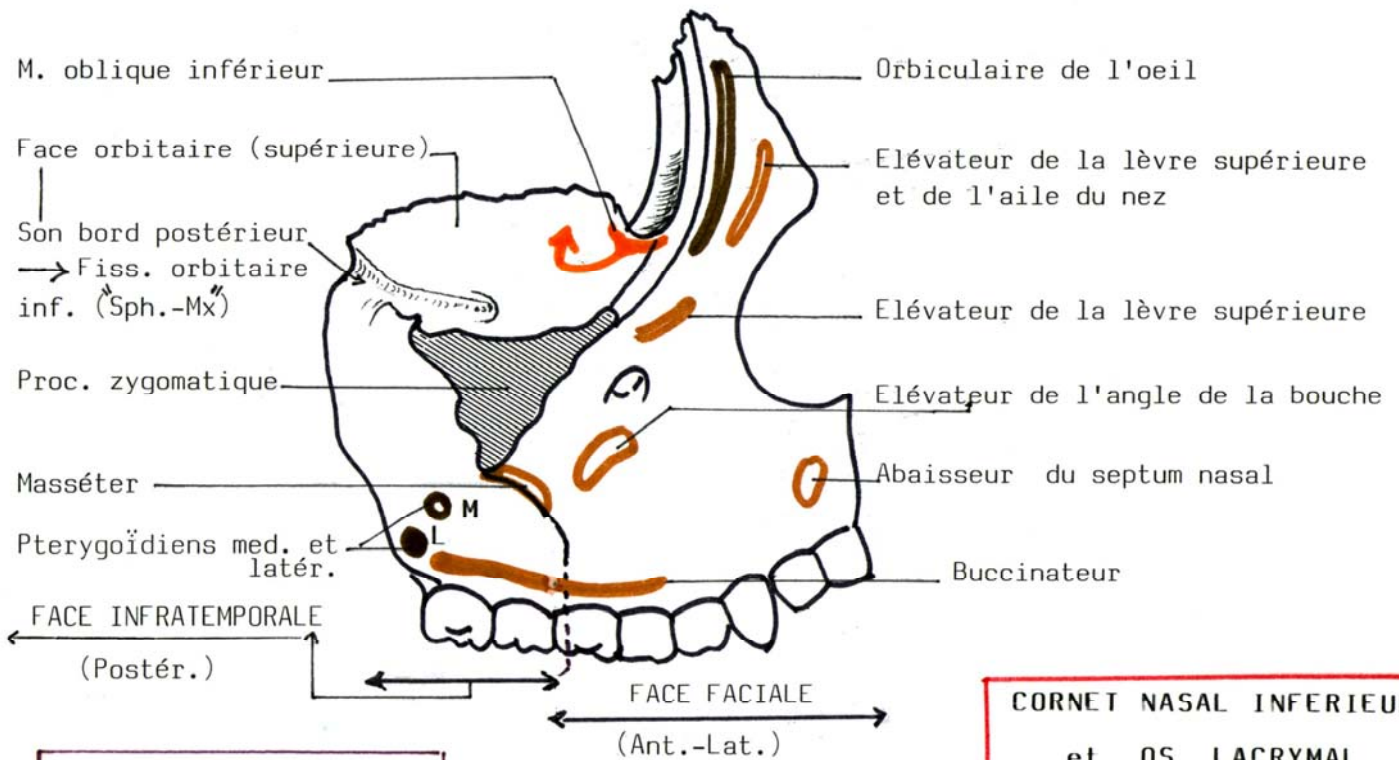
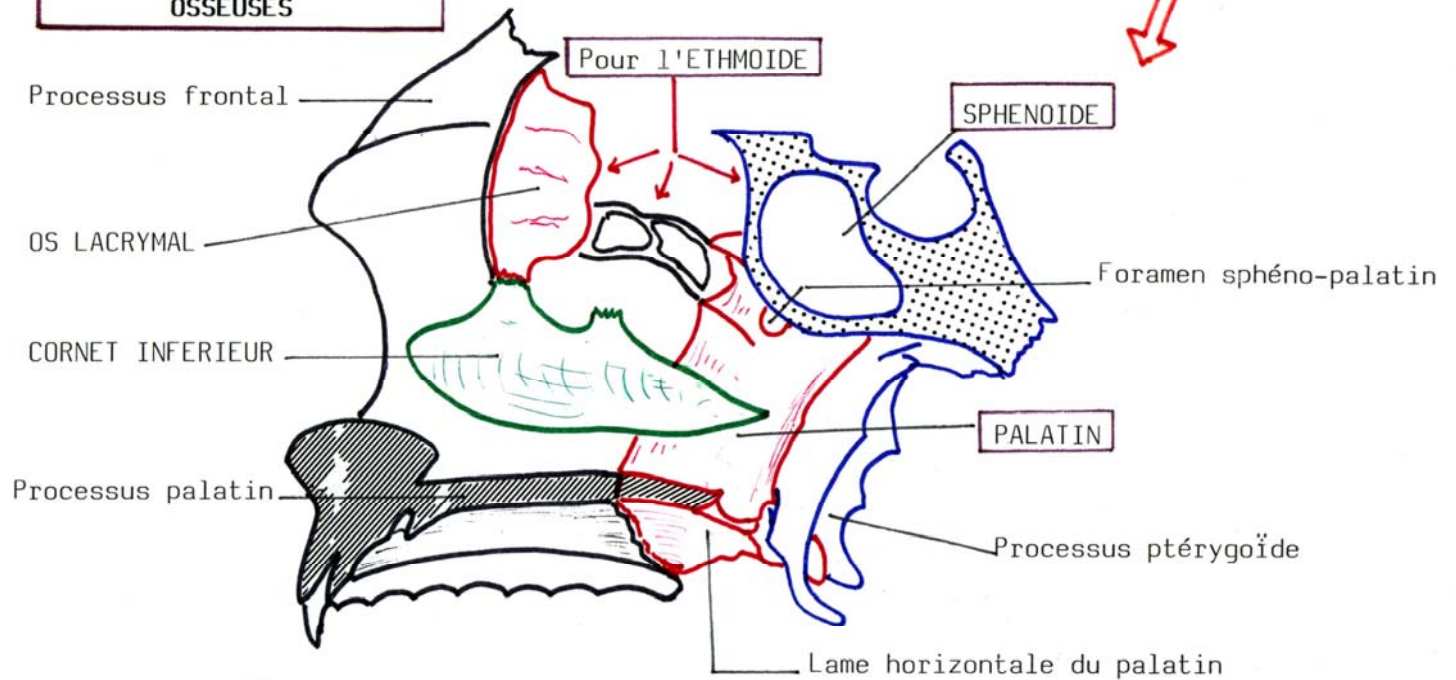


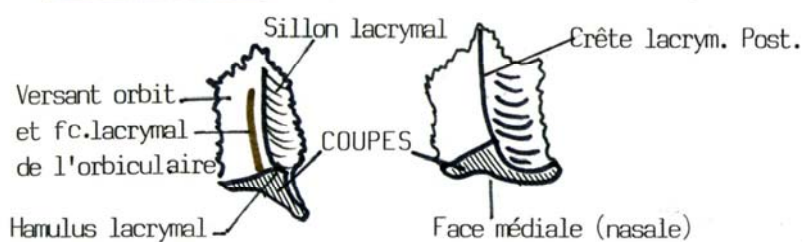
**MAXILLAIRE : VUE LATÉRALE
INSERTIONS MUSCULAIRES**



VUE MÉDIALE : CONNEXIONS OSSEUSES



OS LACRYMAL



CORNET NASAL INFÉRIEUR

