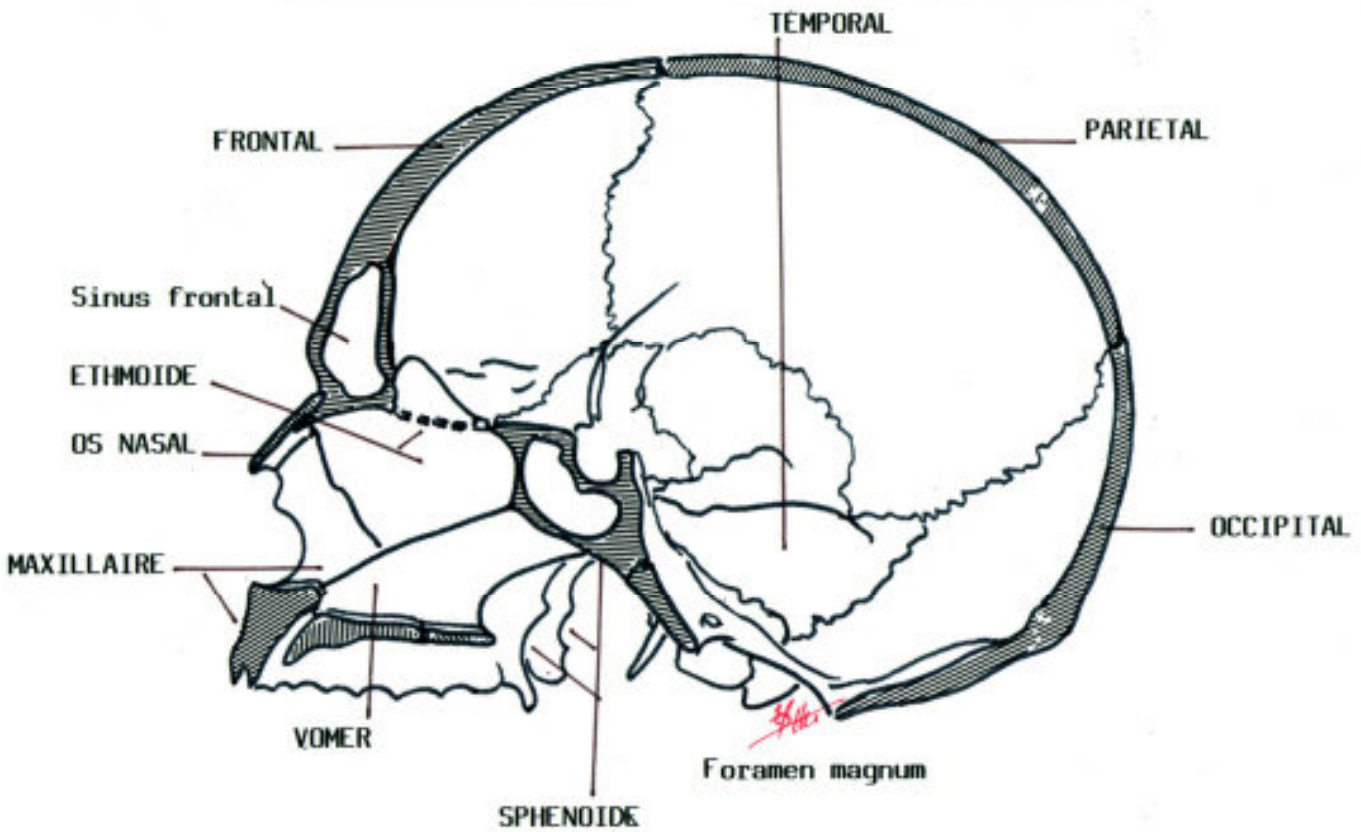


MASSIF CRANIO-FACIAL : COUPE SAGITTALE montrant le septum nasal



MASSIF FACIAL : COUPE SAGITTALE PARAMÉDIANE

