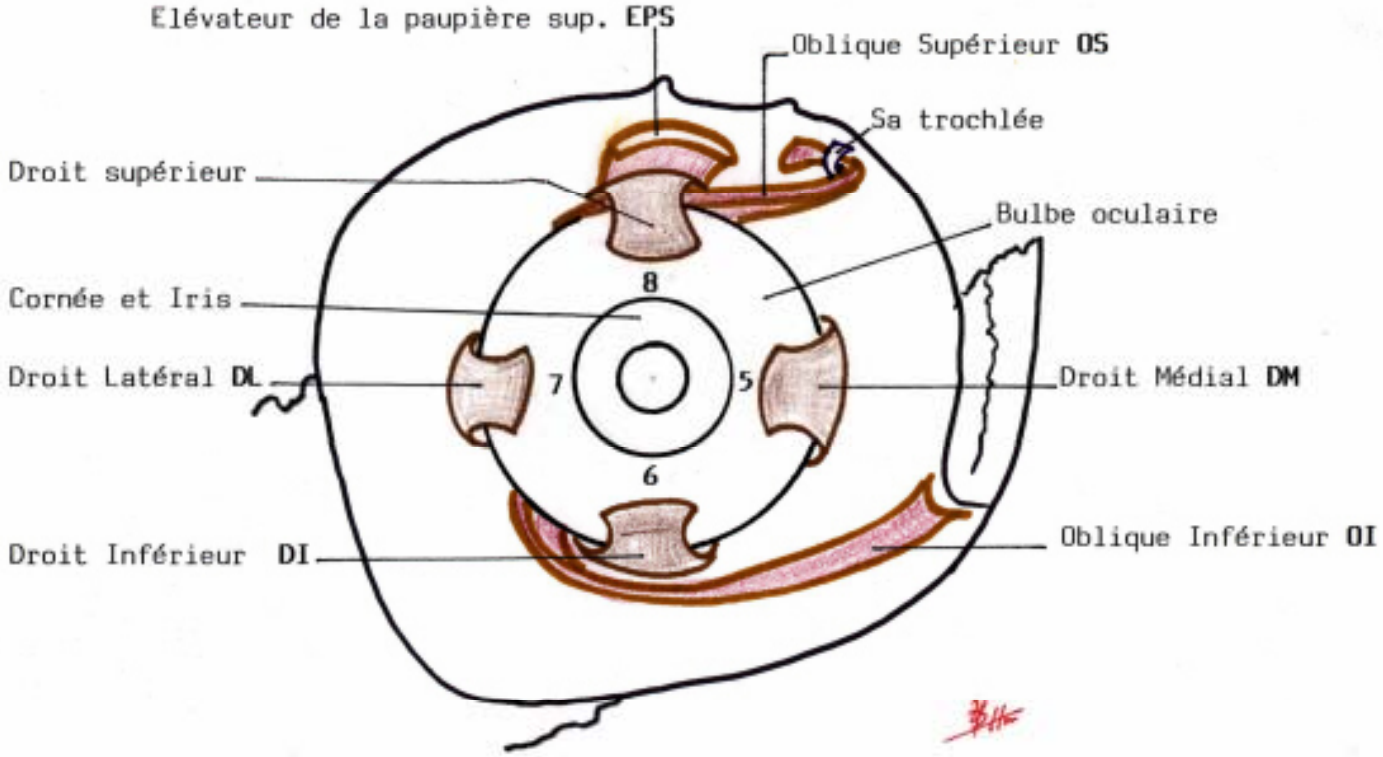
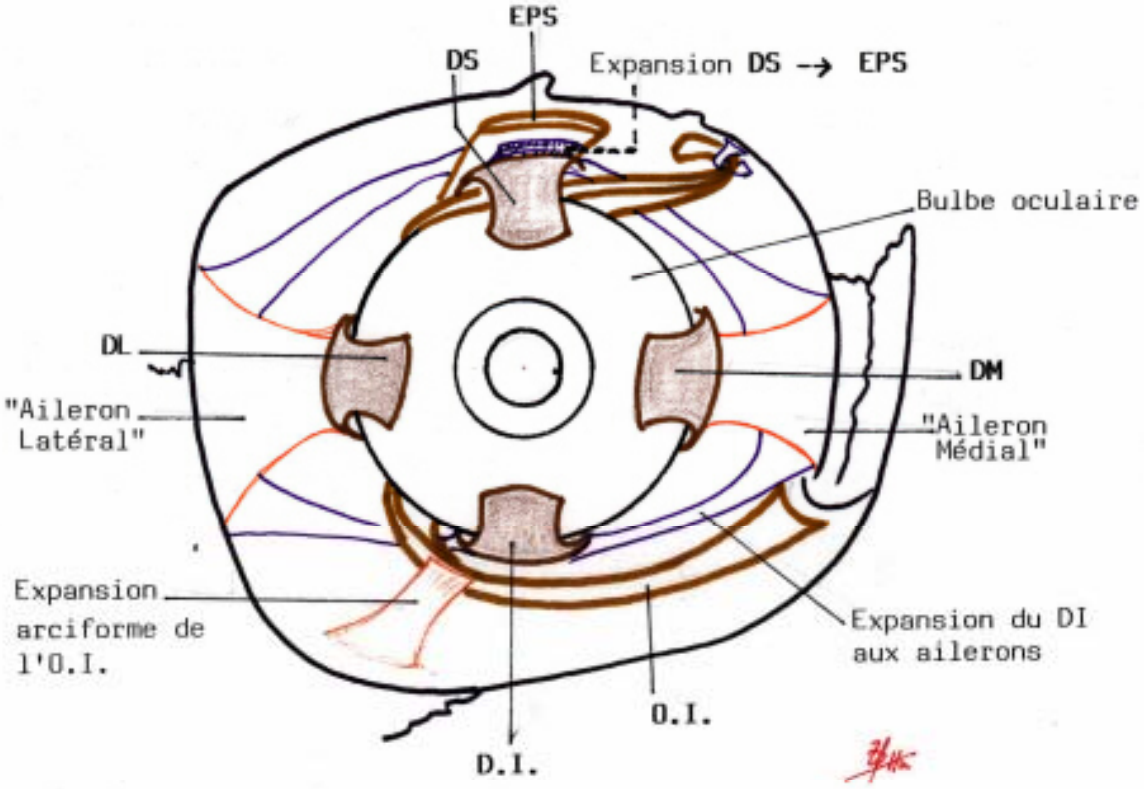
MUSCLES DU BULBE OCULAIRE ET FASCIAS