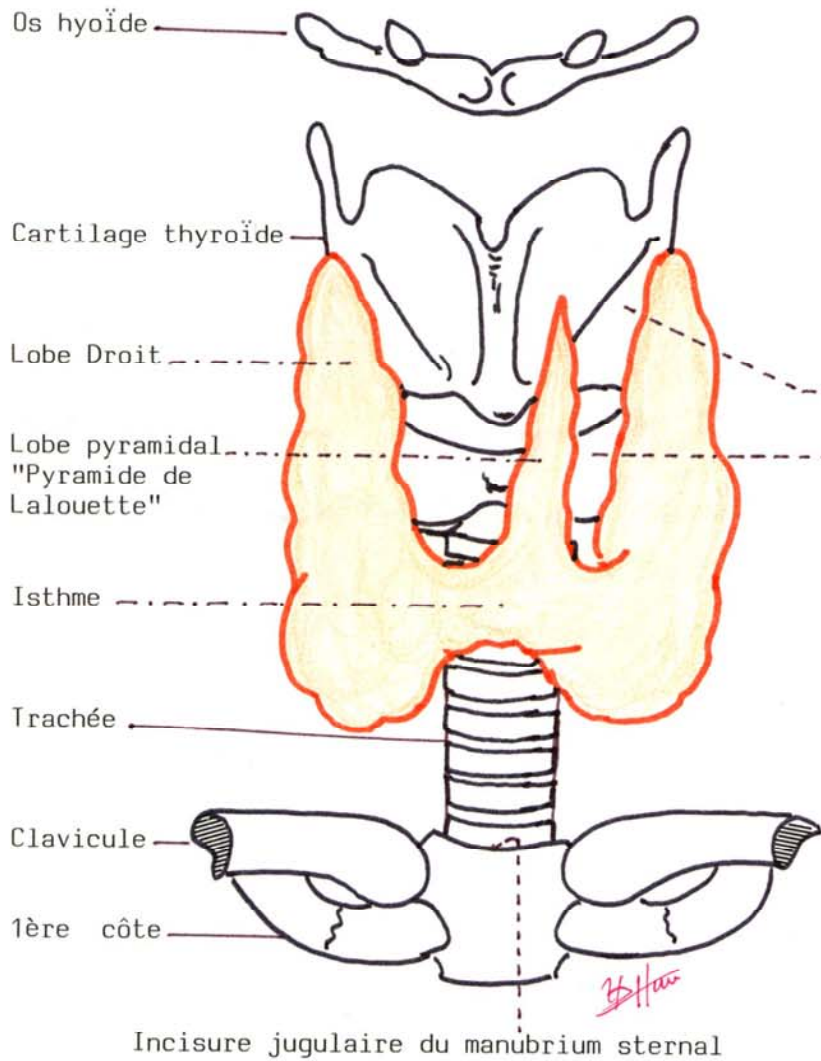


GLANDE THYROÏDE . VUE ANTERIEURE



COUPE SAGITTALE PARAMEDIANE

