

PAROI ANTERIEURE DU PHARYNX

(après ouverture de sa paroi postérieure)

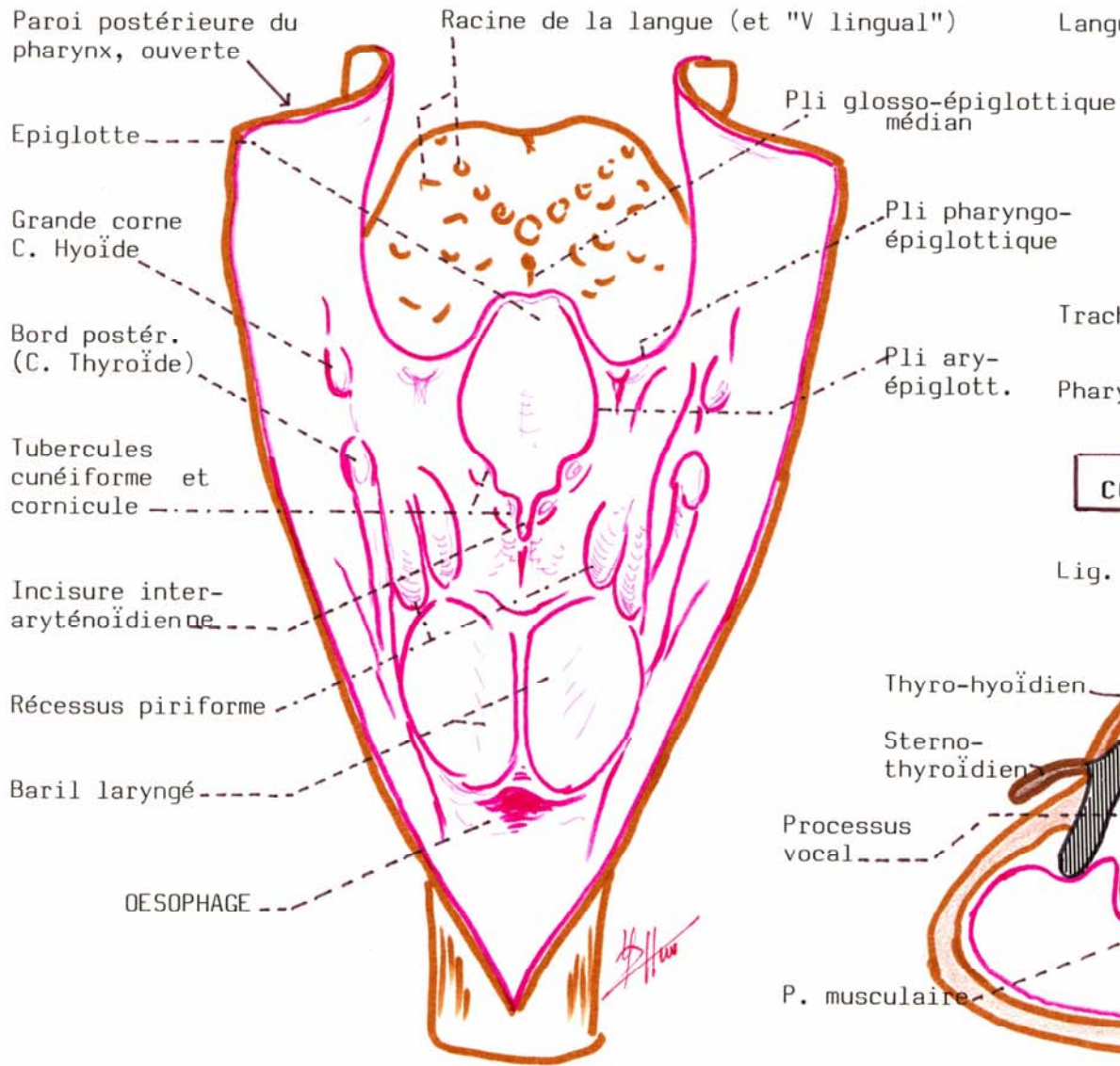
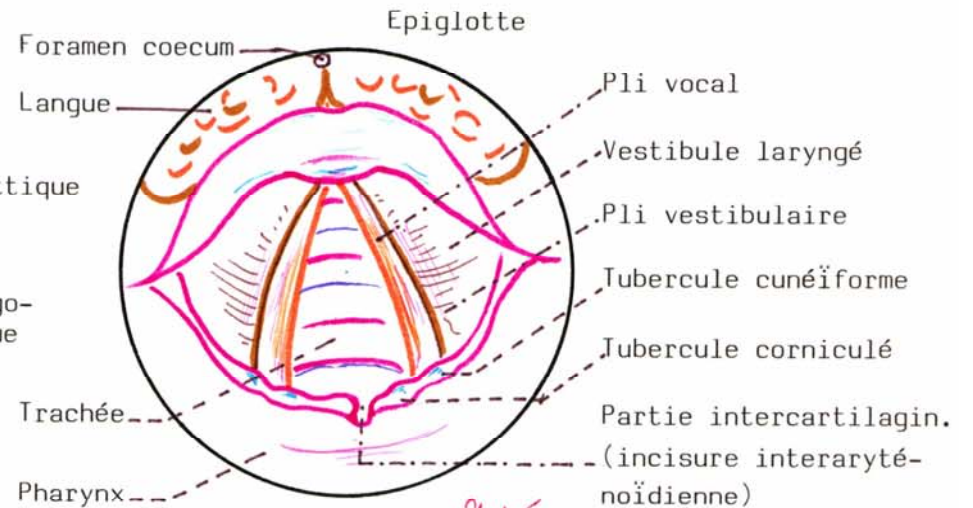
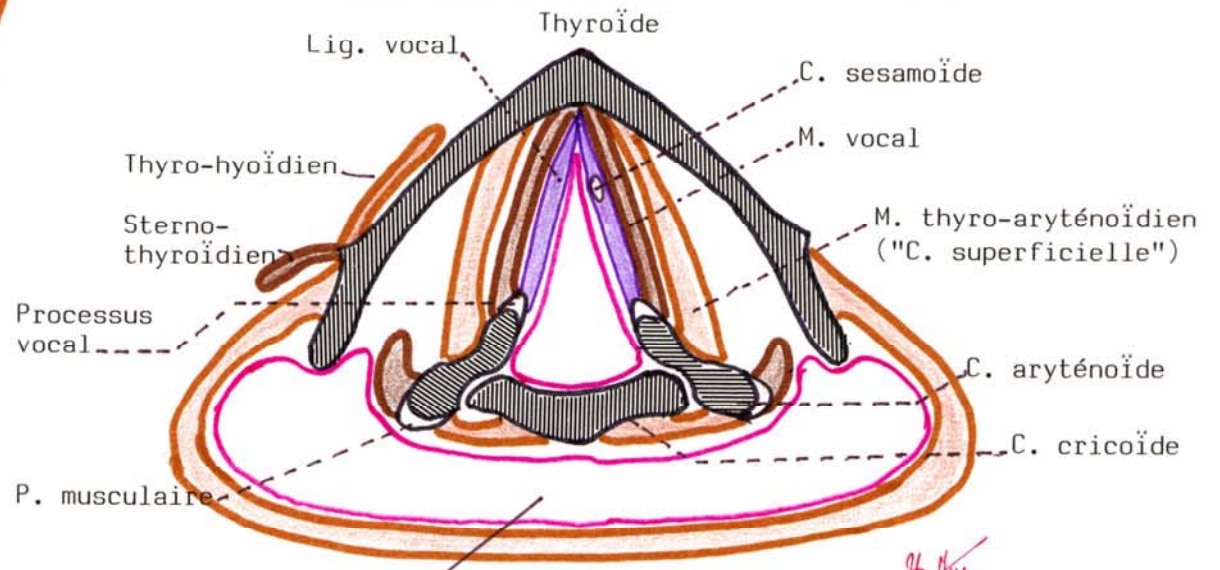


IMAGE LARYNGOSCOPIQUE



COUPE HORIZONTALE SCHEMATIQUE



"LARYNGO-PHARYNX" (Partie laryngée du Pharynx)