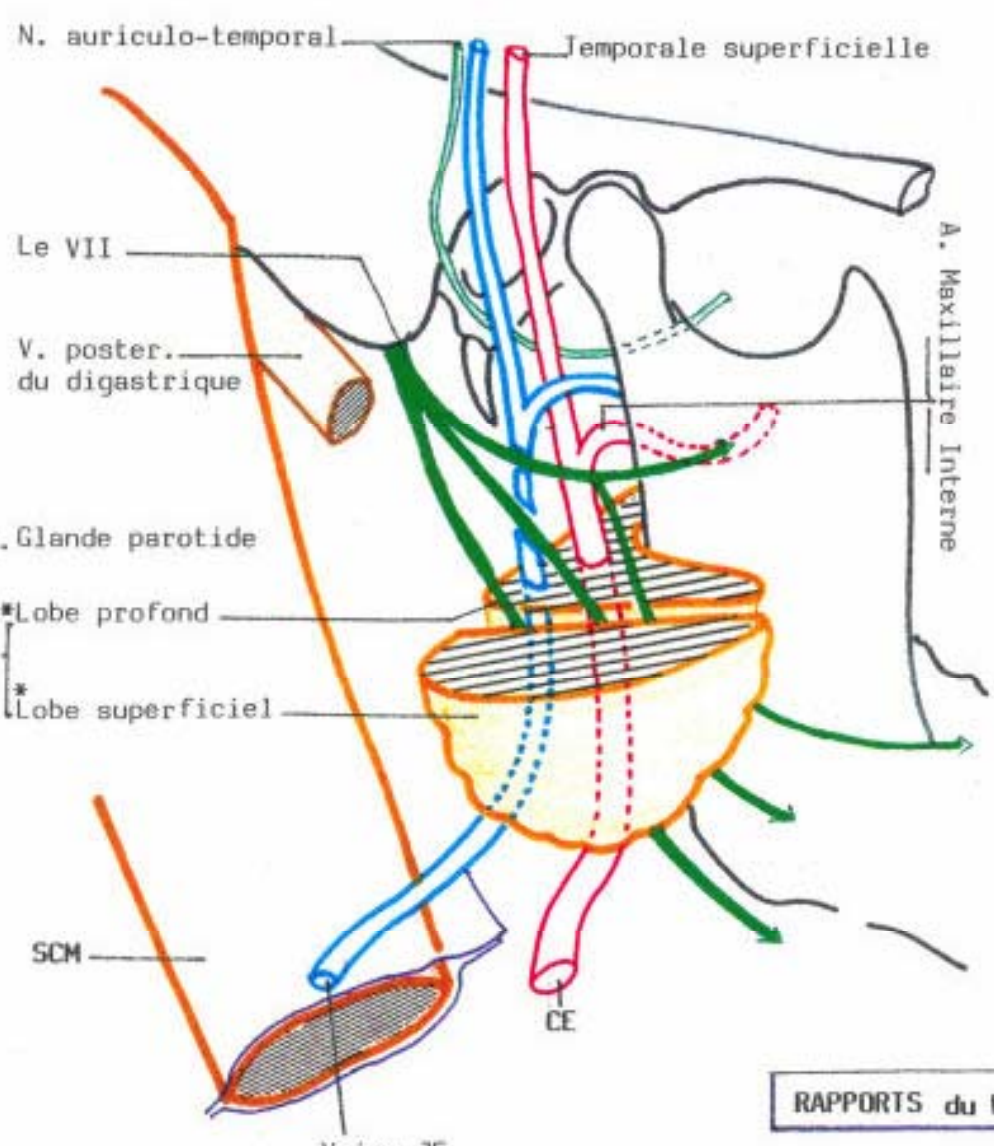
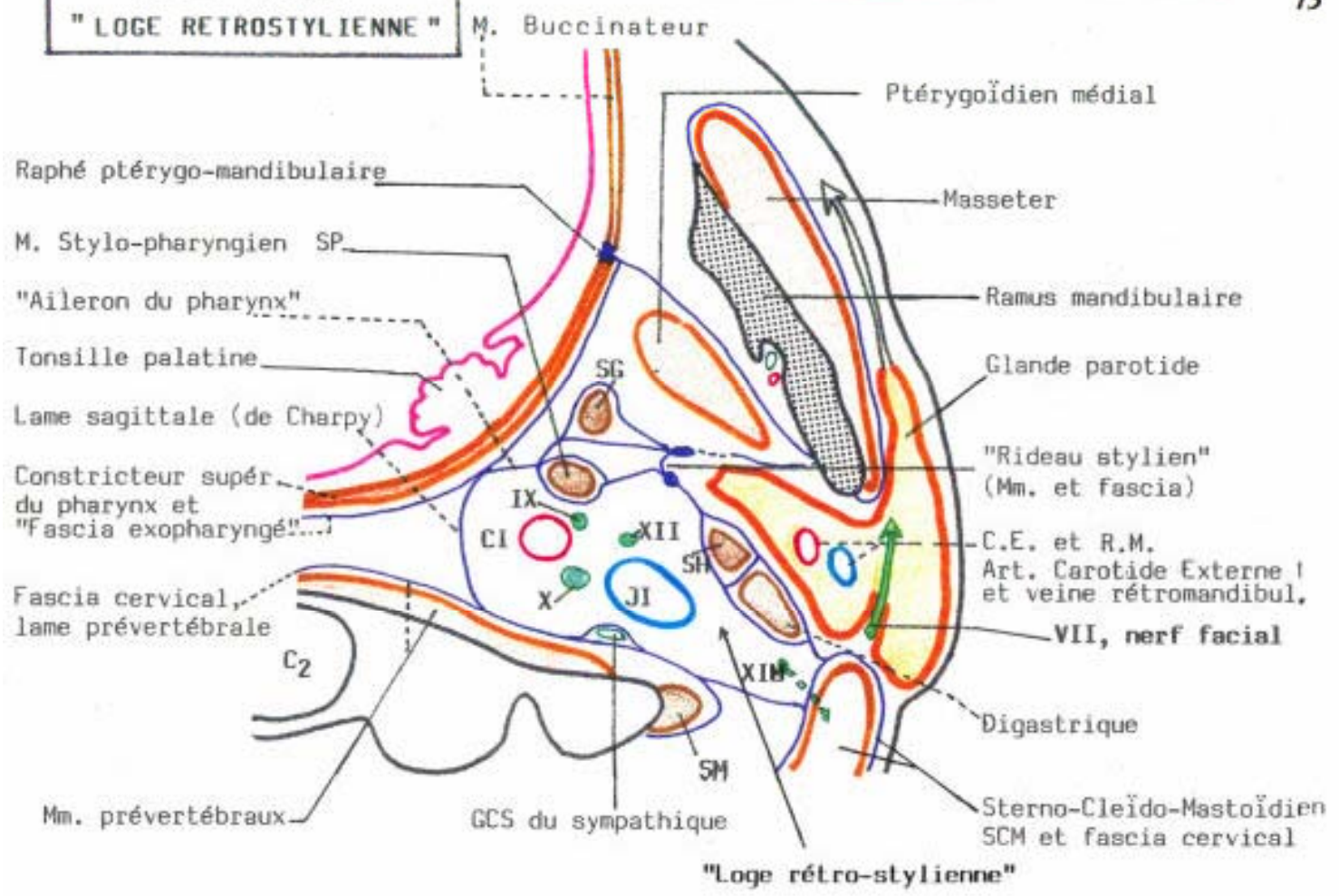


RAPPORTS DE LA GLANDE PAROTIDE

**COUPE AXIALE
" LOGE RETROSTYLIENNE "**



RAPPORTS du FACIAL : GLANDE PAROTIDE