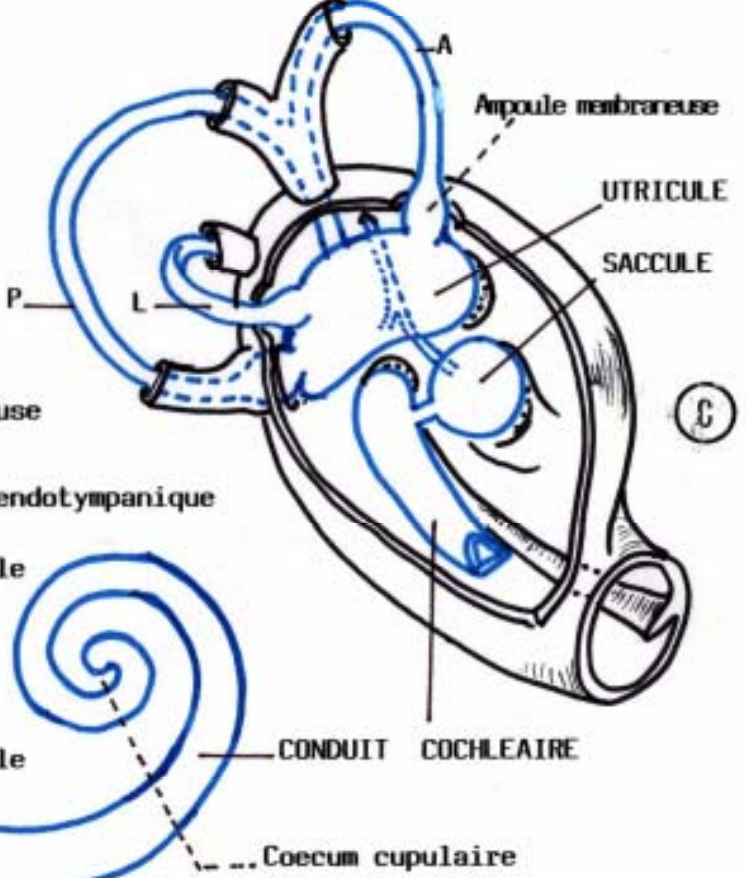
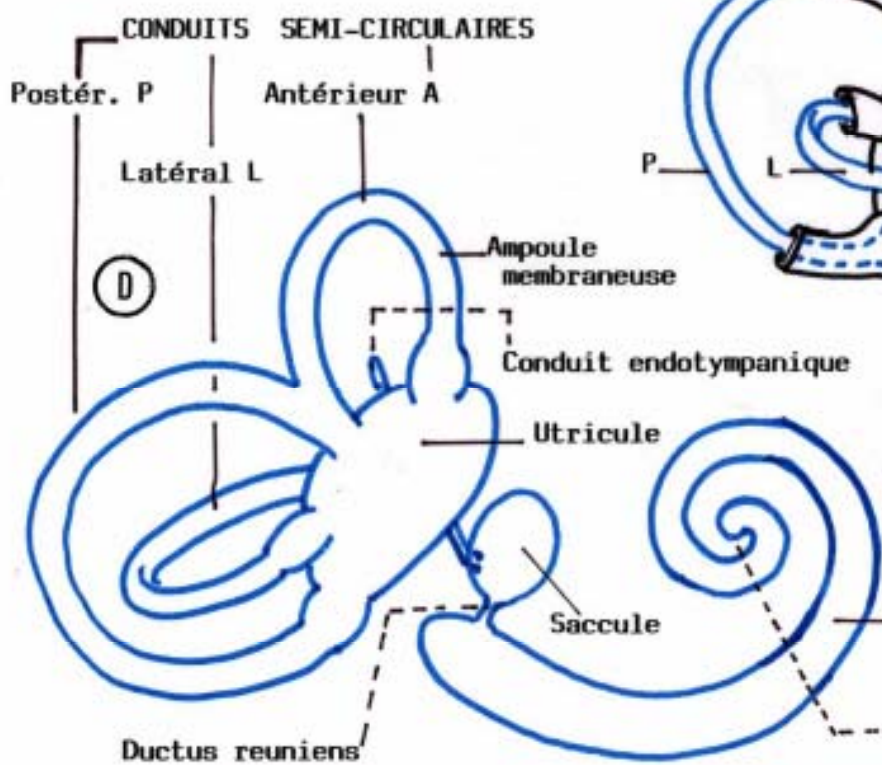
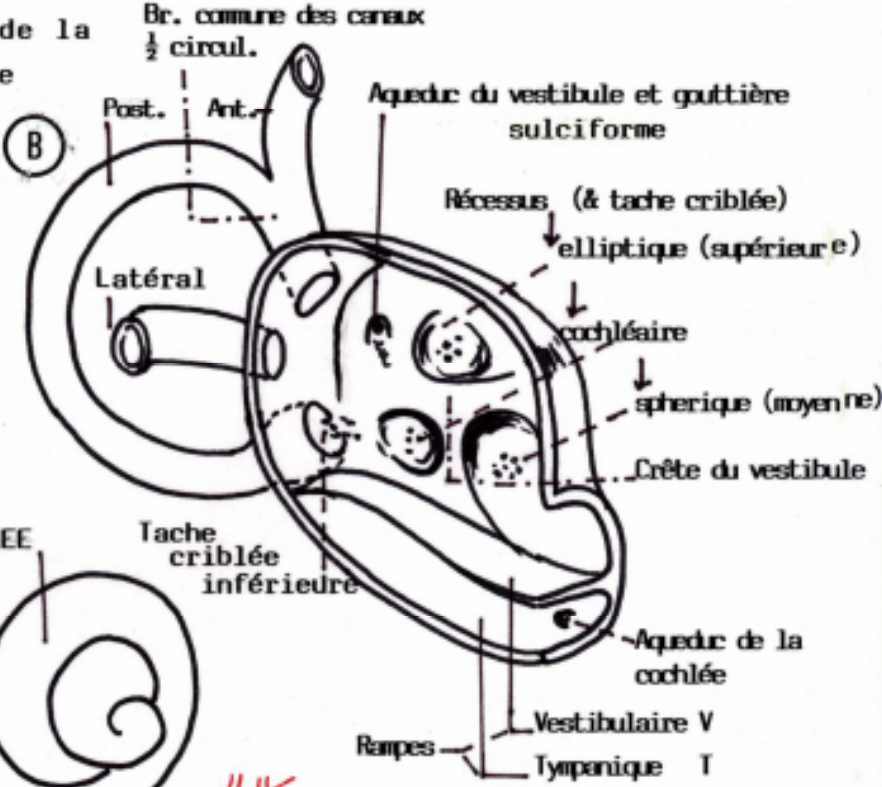
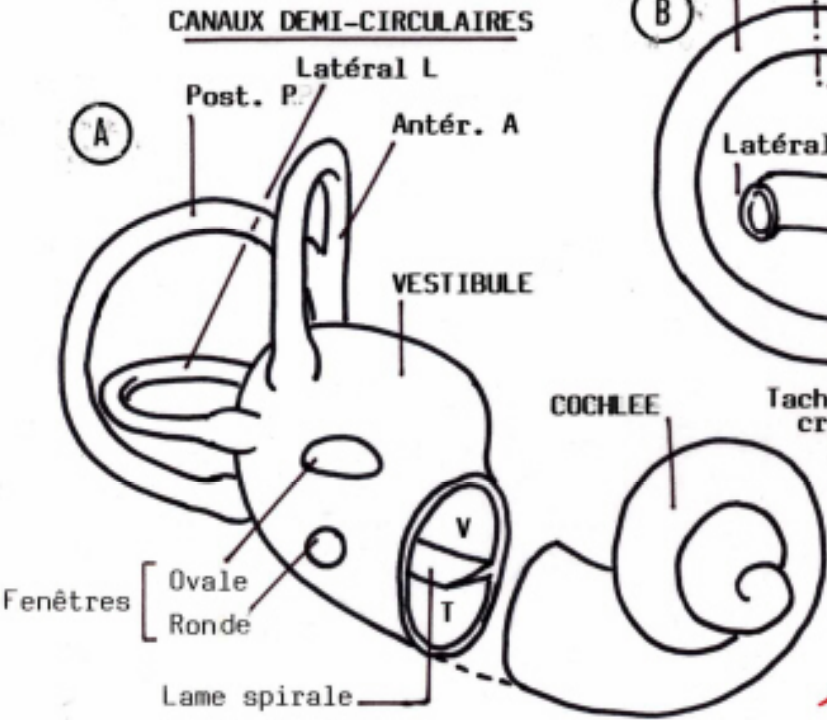


LABYRINTHE OSSEUX - VUE LATÉRALE

(B) ET (C) Après ablation de la paroi latérale du vestibule



(D) LE LABYRINTHE MEMBRANEUX VUE LATÉRALE