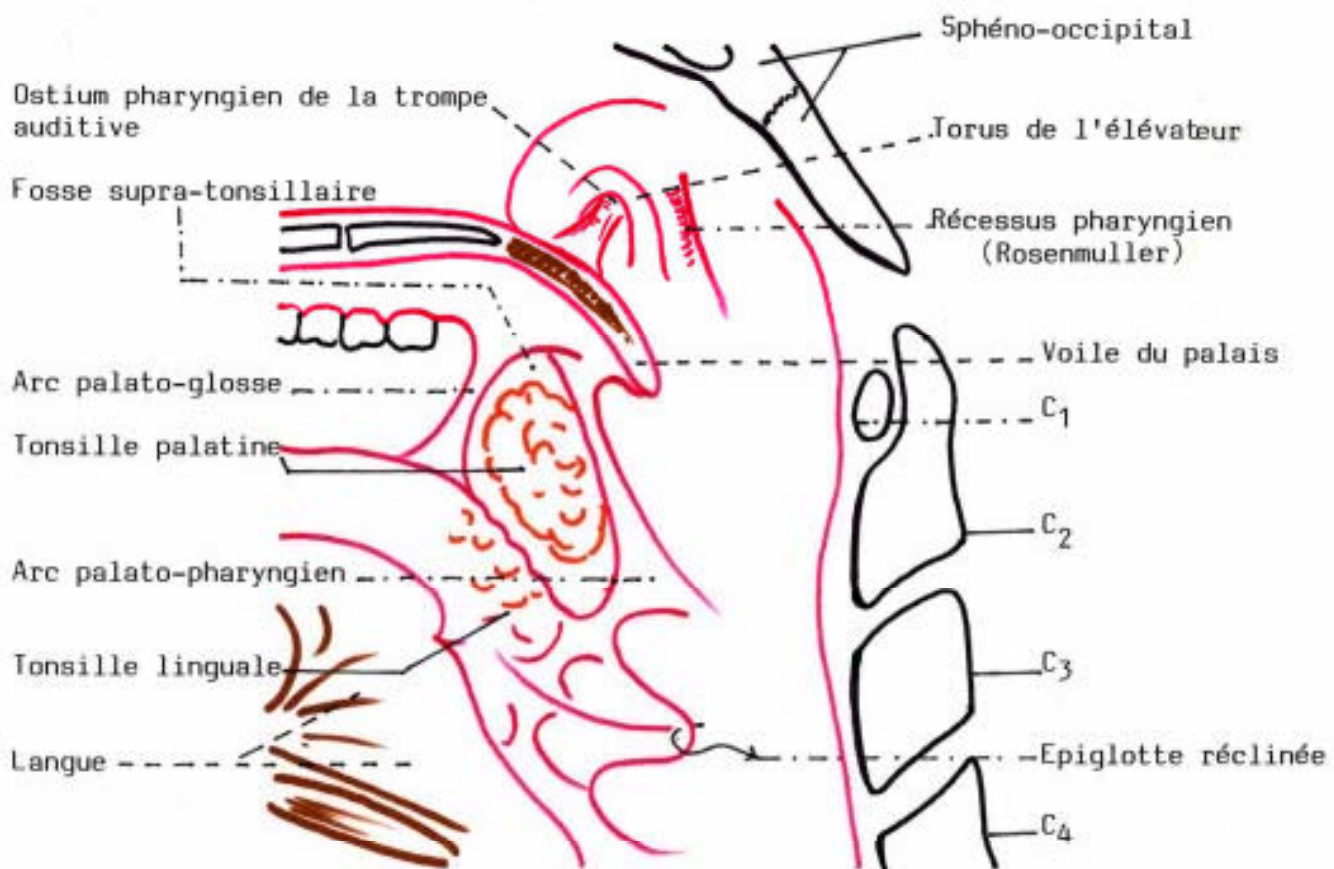
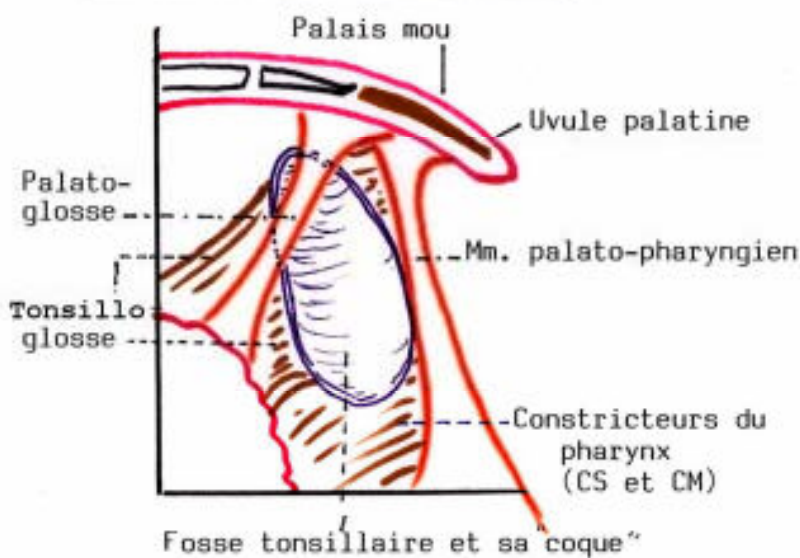


TONSILLE PALATINE et PALAIS MOU



LOGE, après ablation de la muqueuse et de la tonsille



VUE MEDIALE

LOGE TONSILLAIRE : COUPE HORIZONTALE

