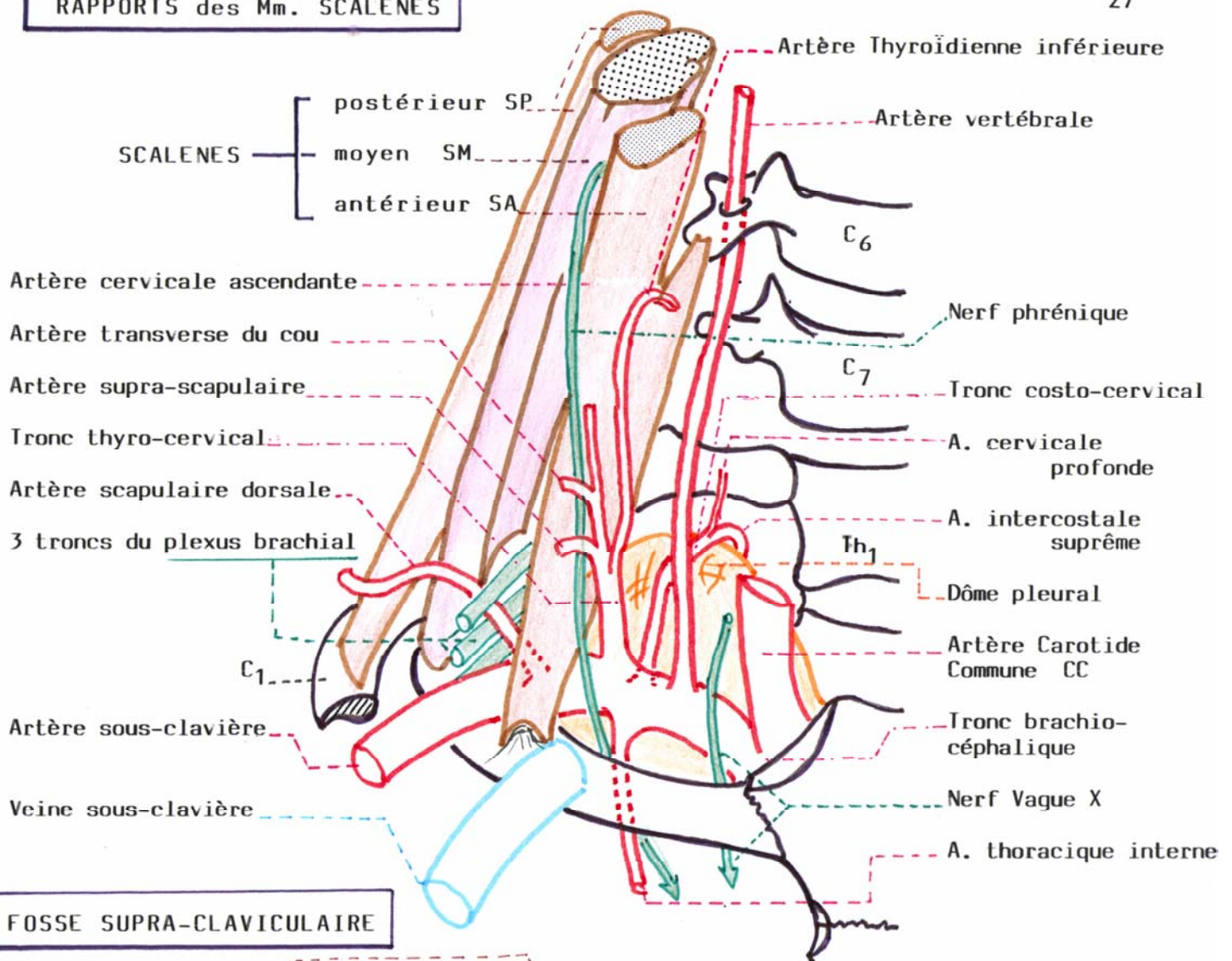


RAPPORTS des Mm. SCALENES



FOSSE SUPRA-CLAVICULAIRE

