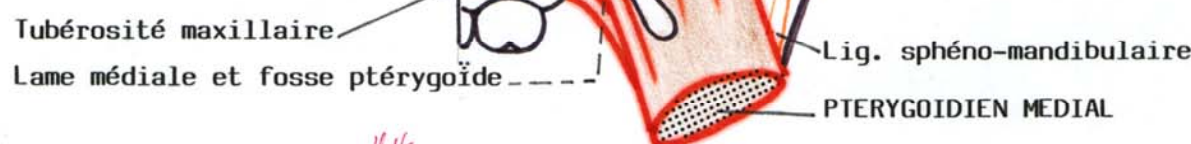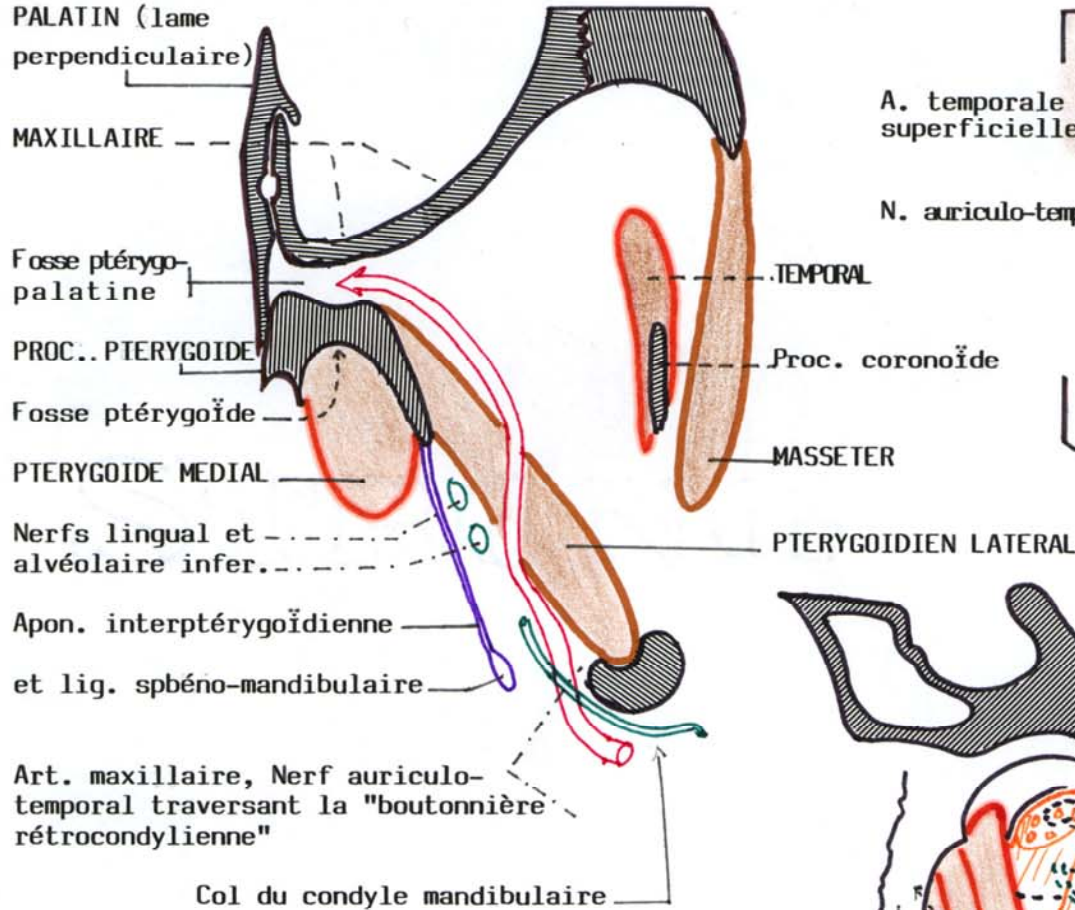
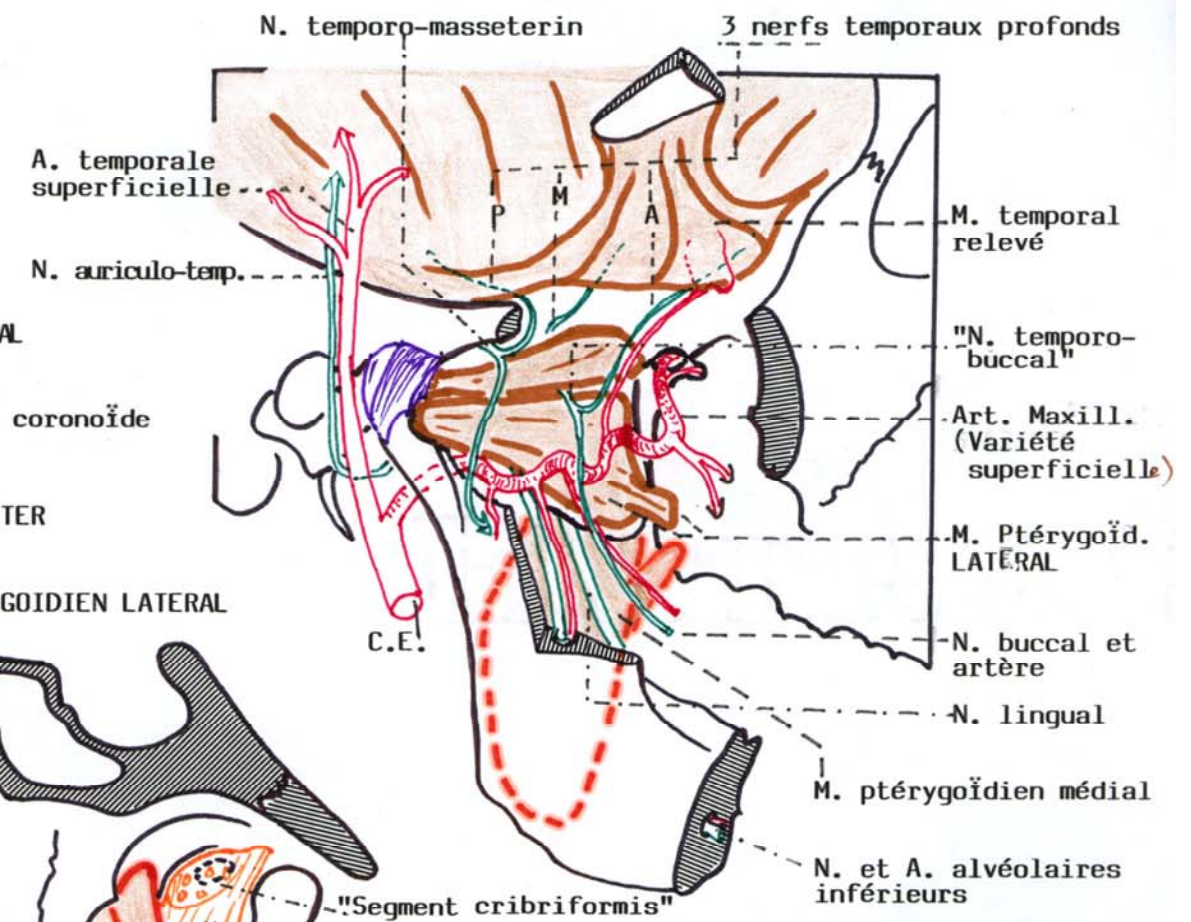


COUPE HORIZONTALE . FOSSE INFRATEMPORALE



RAPPORTS DES MUSCLES PTÉRYGOÏDIENS

N.A.



APONEVROSE INTERPTÉRYGOÏDIENNE (VUE MÉDIALE)

*4/11*