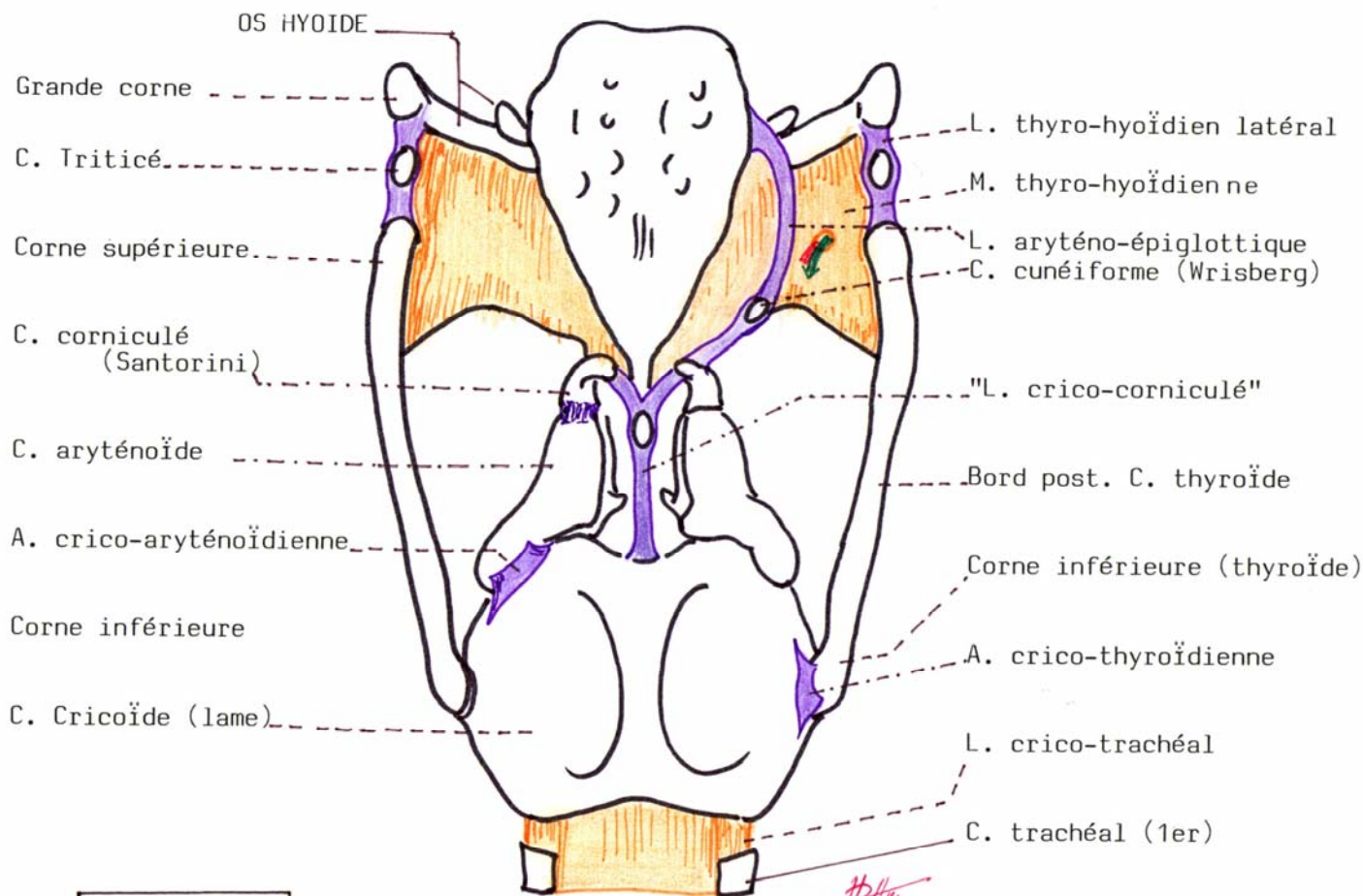


**CARTILAGES du LARYNX : VUE POSTERIEURE**

N.A.

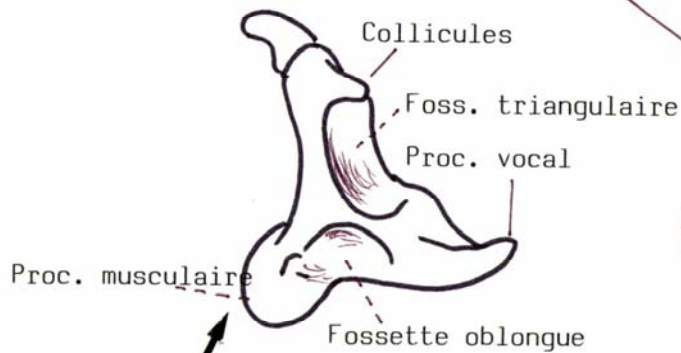
A : Articulation ; L : Ligament ; M : Membrane.

75

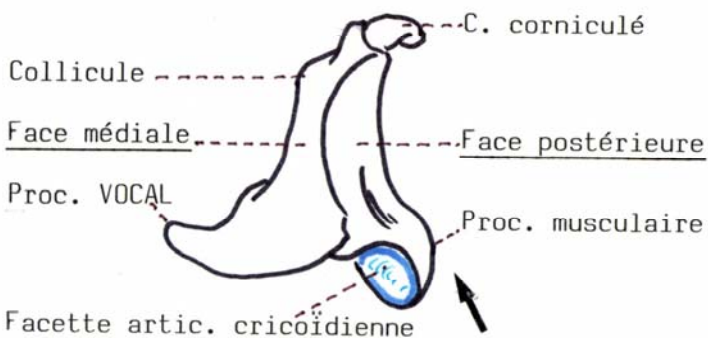


**ARYTENOÏDE**

CART. CORNICULE

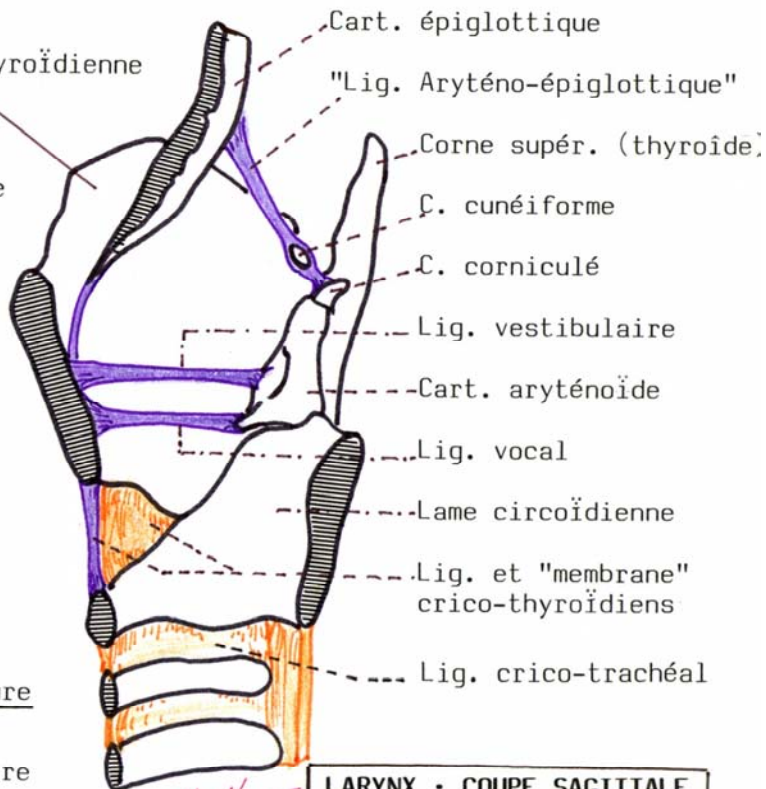


FACE ANTERO-LATERALE



VUE POST-MEDIALE

Lame thyroïdienne



**LARYNX : COUPE SAGITTALE**