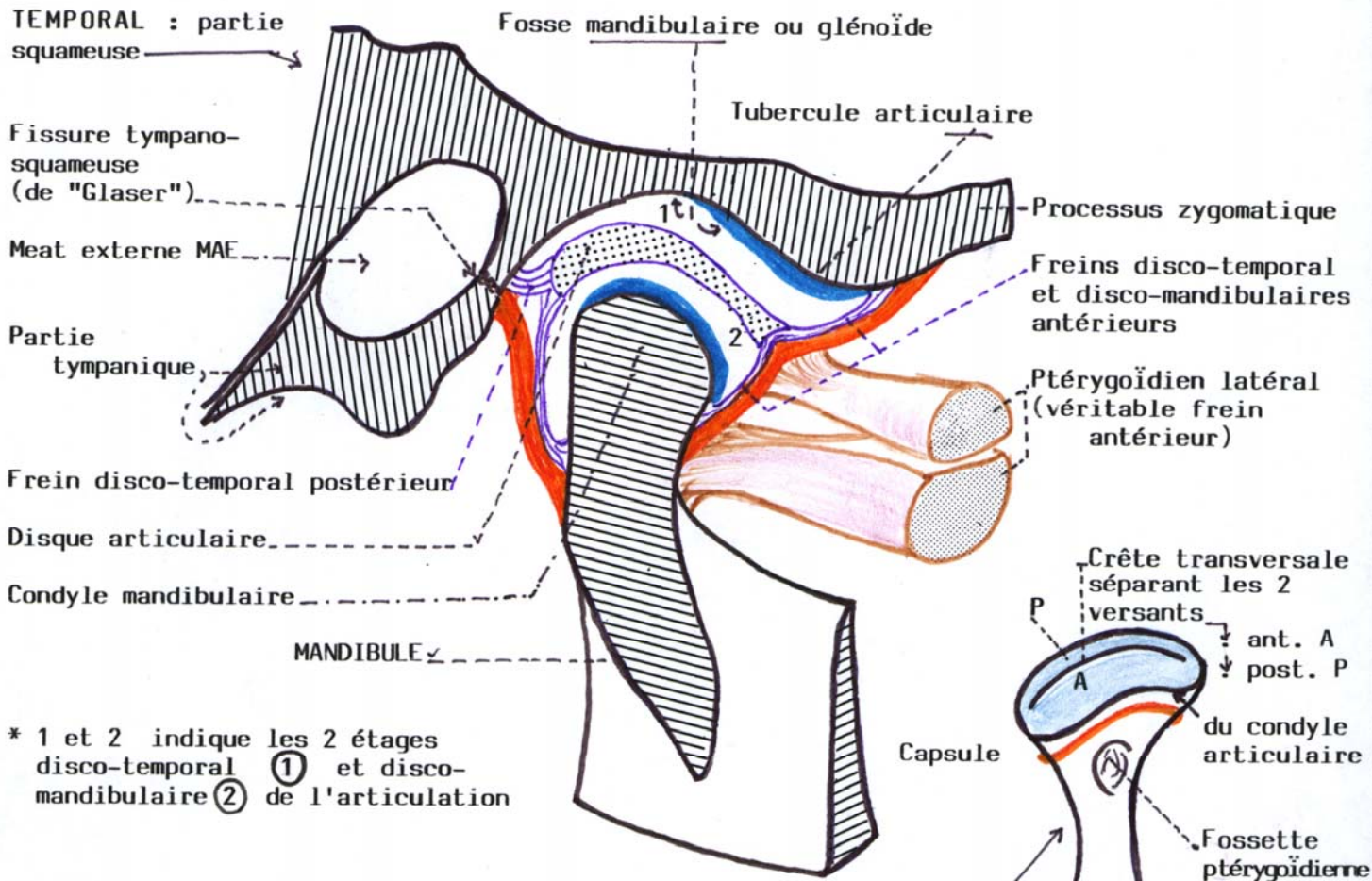
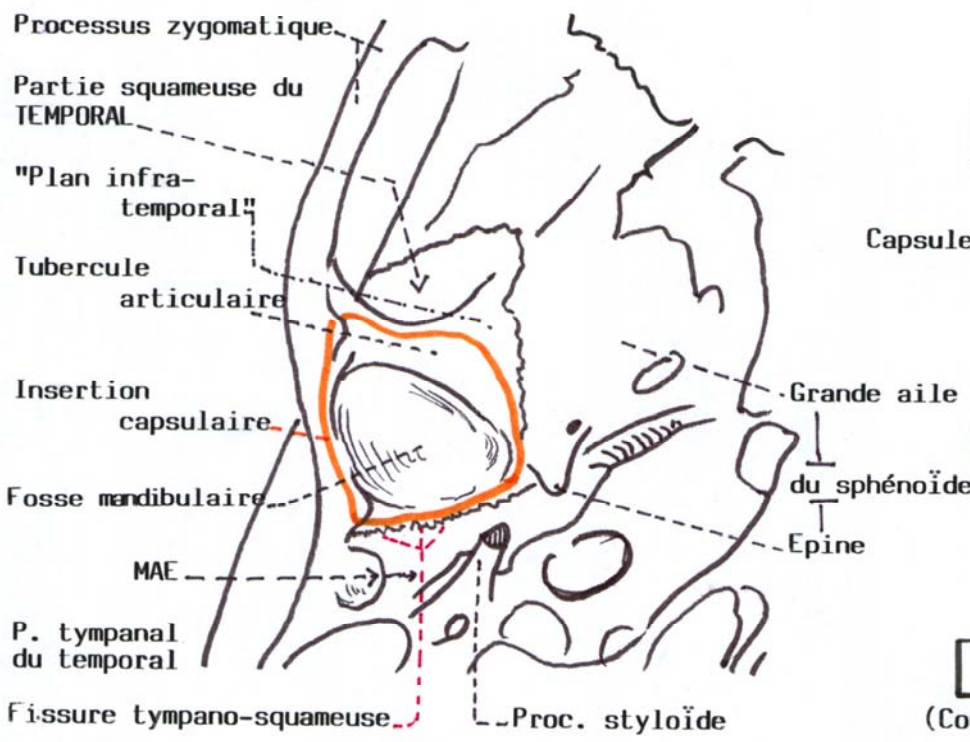


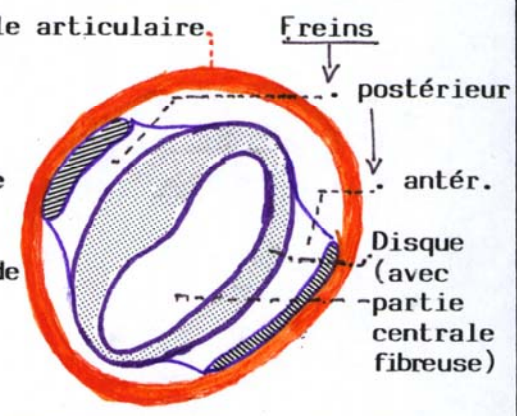
ARTICULATION TEMPORO-MANDIBULAIRE : COUPE SAGITTALE



INSERTION CAPSULAIRE : VUE INF. du TEMPORAL



PROCESSUS CONDYLAIRE



DISQUE ARTICULAIRE

(Coupe horizontale de l'articulation)