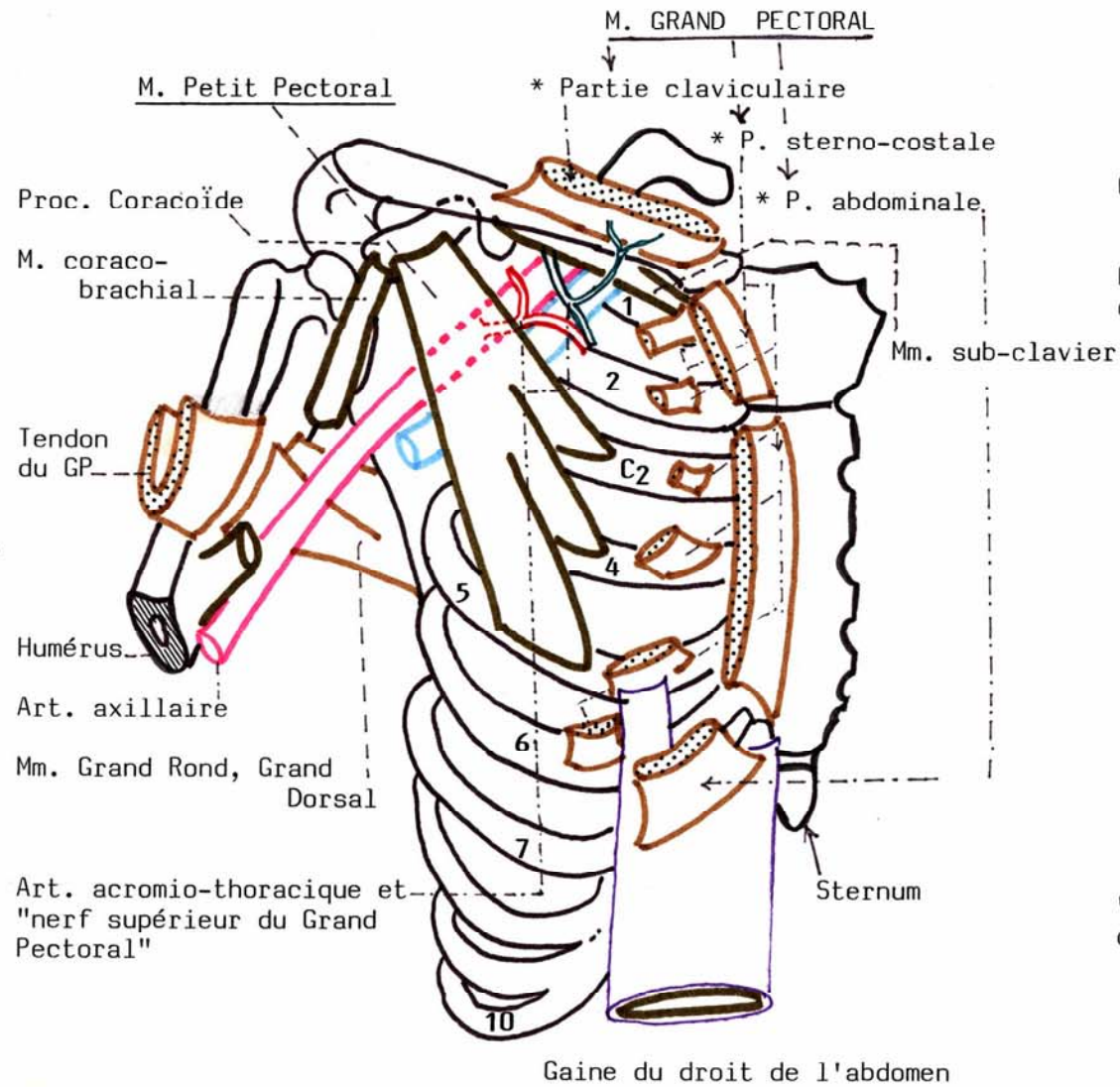


LE PETIT PECTORAL et le FASCIA CLAVI-PECTORAL

VUE ANTERIEURE



*** Mm. Petit Pectoral et sa "gaine"**

