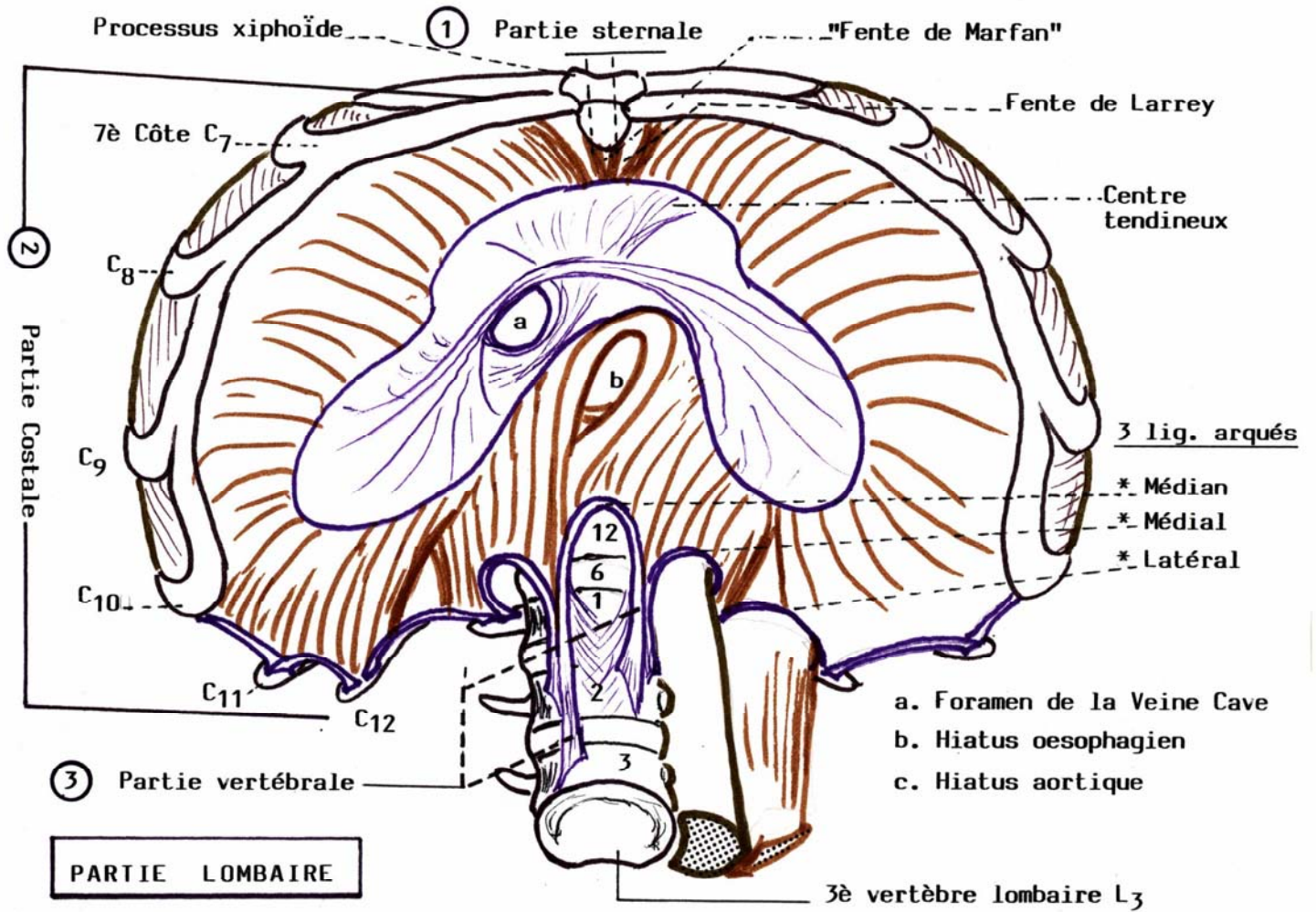
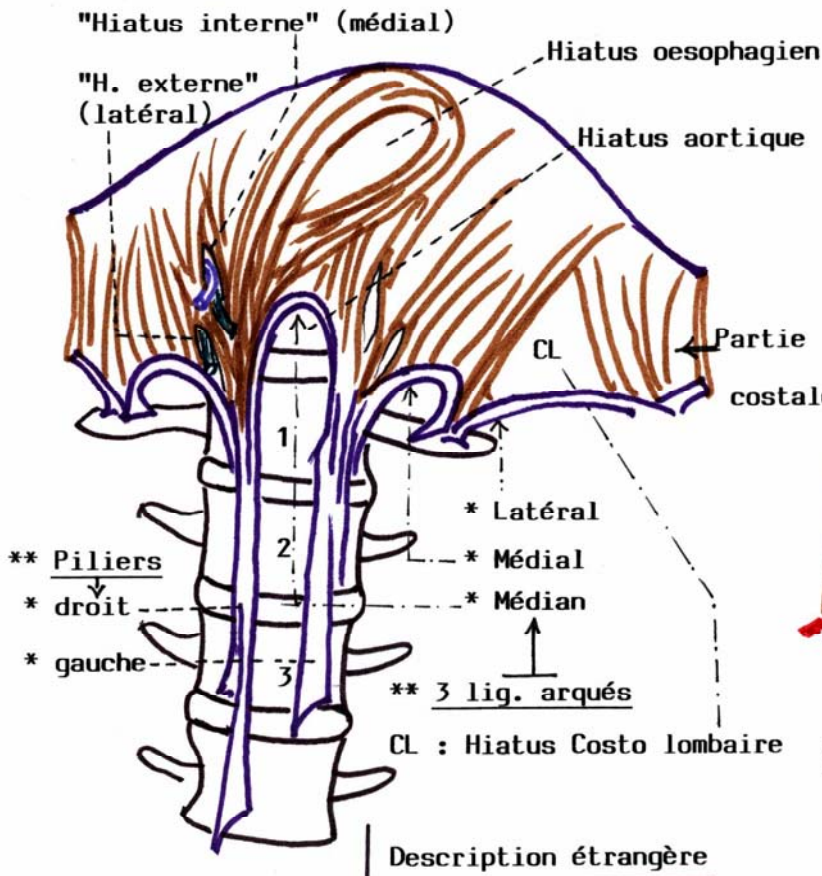


DIAPHRAGME VU D'EN BAS

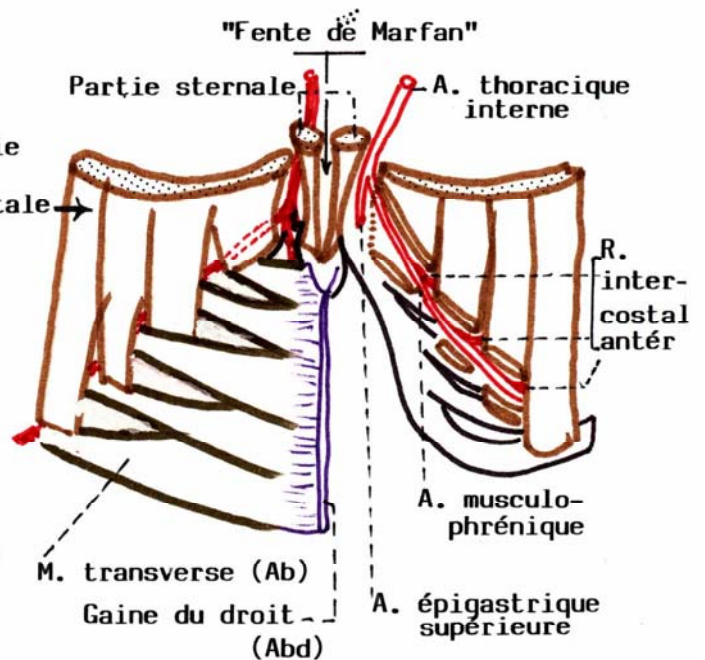
N.A.



PARTIE LOMBAIRE



INSERTIONS XIPHO-COSTALES



VUE POSTERIEURE