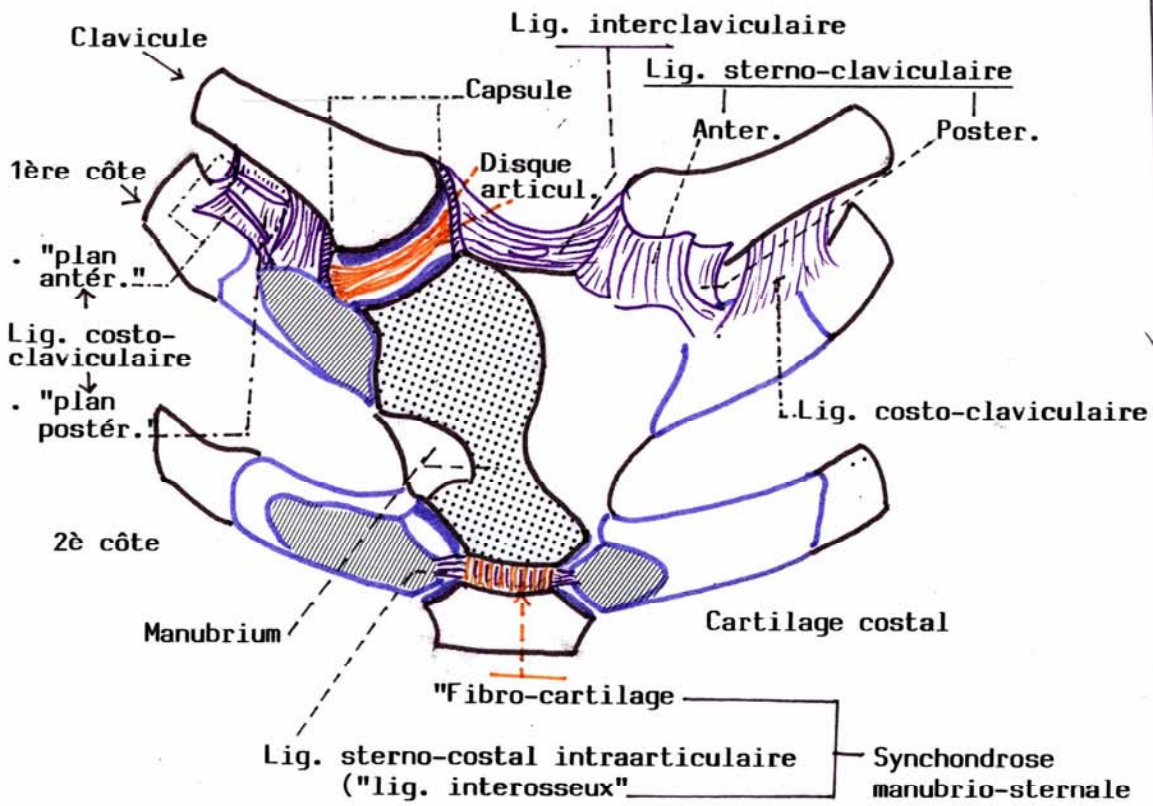


ARTICULATION STERNO-CLAVICULAIRE
A droite : coupe frontale



ARTICULATION STERNO-COSTALE

