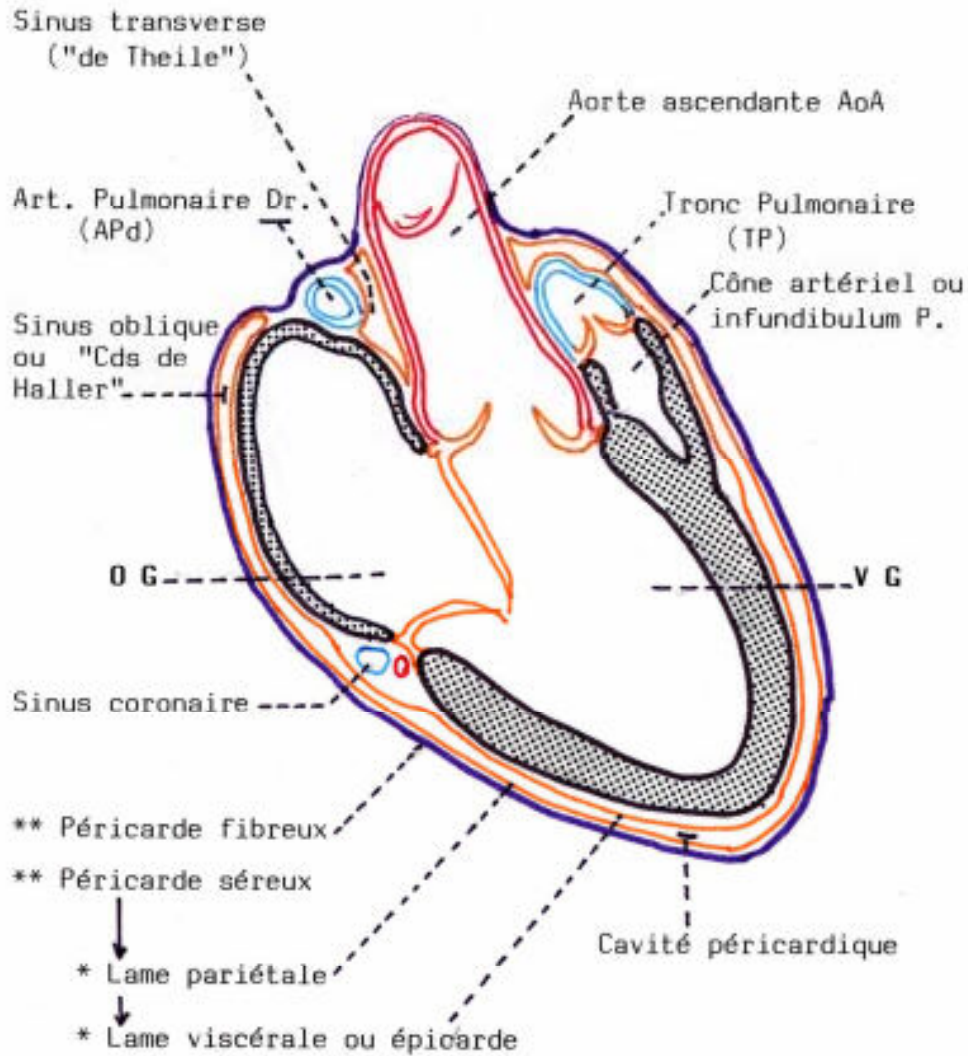


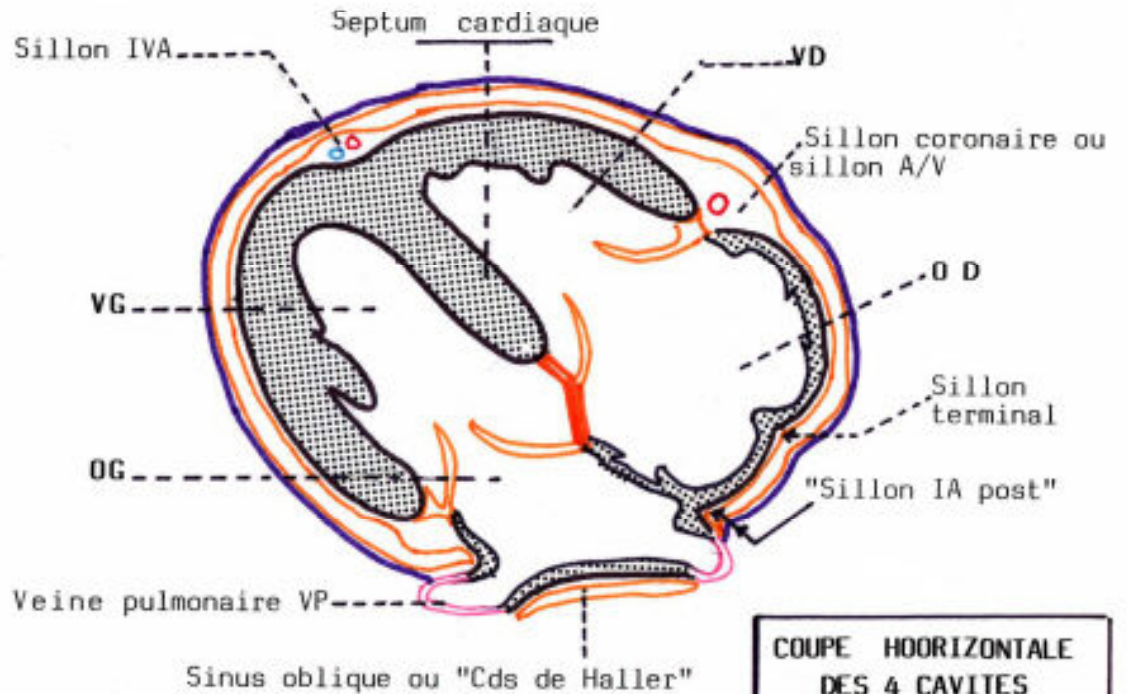
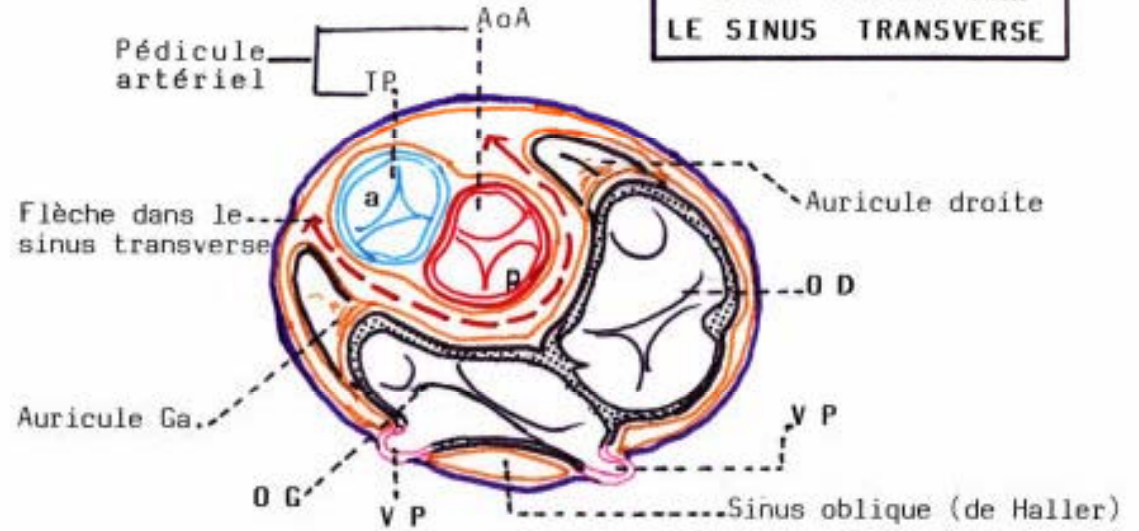
LE PERICARDE



COUPE SAGITTALE

N.A.

COUPE AXIALE PAR LE SINUS TRANSVERSE



COUPE HORIZONTALE DES 4 CAVITES