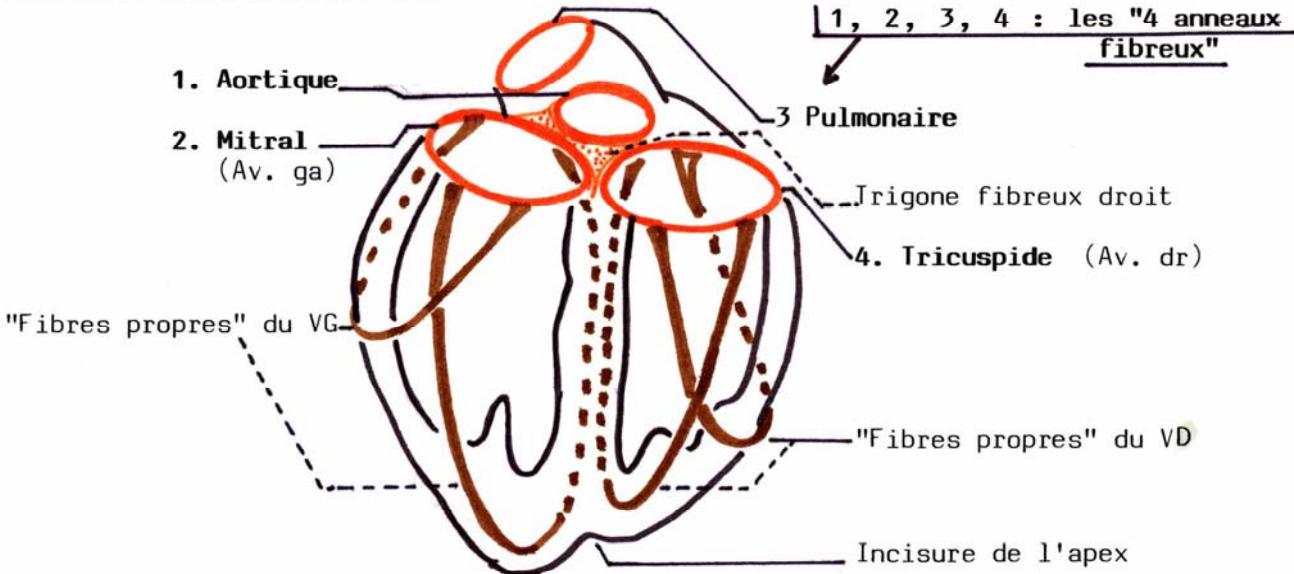
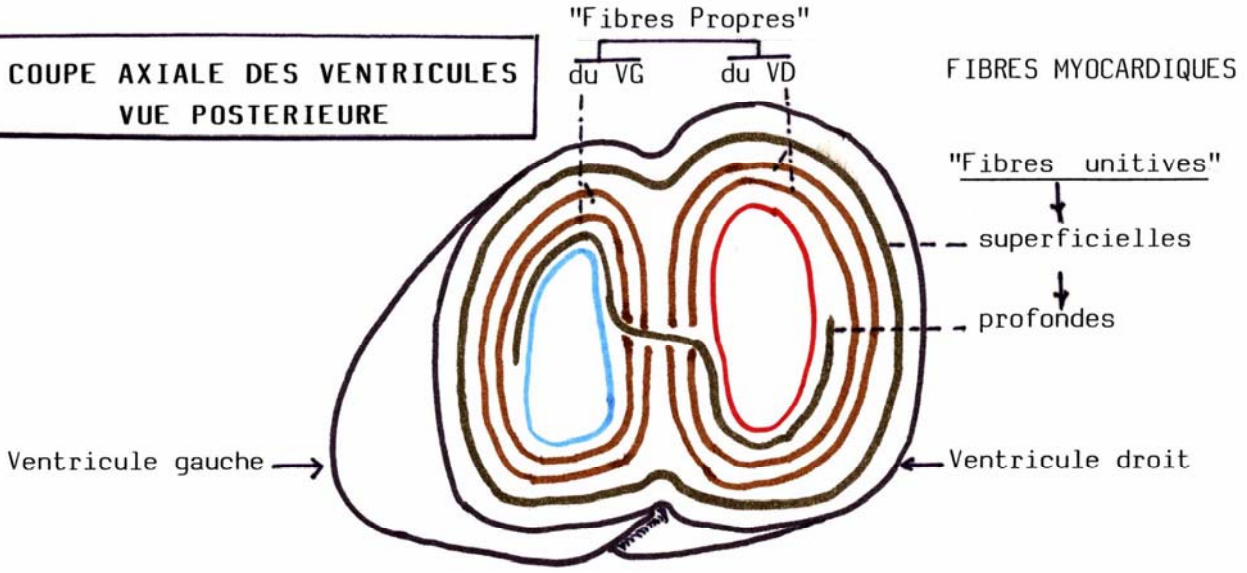


MYOCARDE VENTRICULAIRE

N.A.



COUPE AXIALE DES VENTRICULES VUE POSTERIEURE



VORTEX du COEUR : VUE ANTERIEURE

