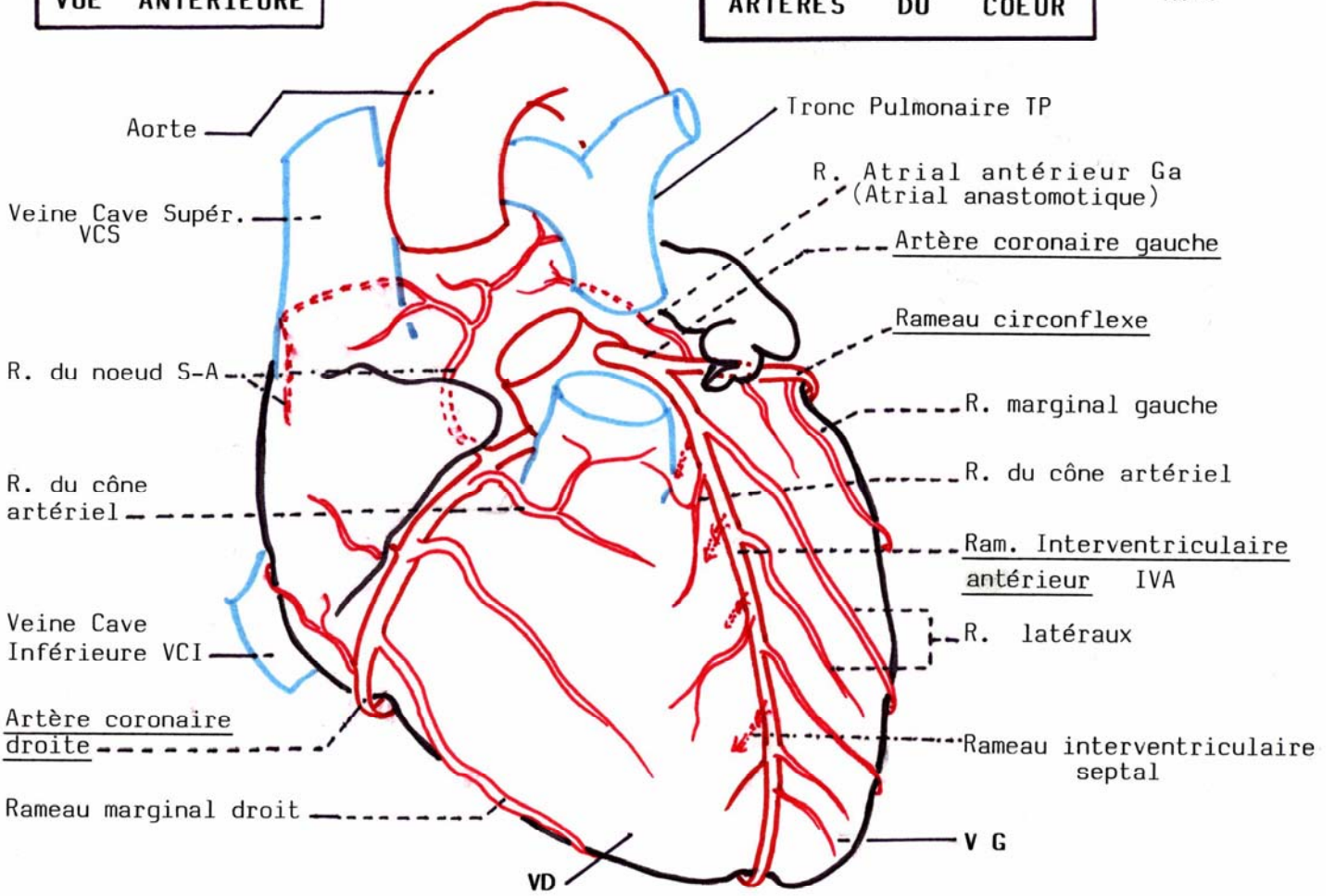


VUE ANTERIEURE

ARTERES DU COEUR



VUE POST-INF-GA

