ARTERE RENALE

L'artère rénale droite, normalement rétrocave

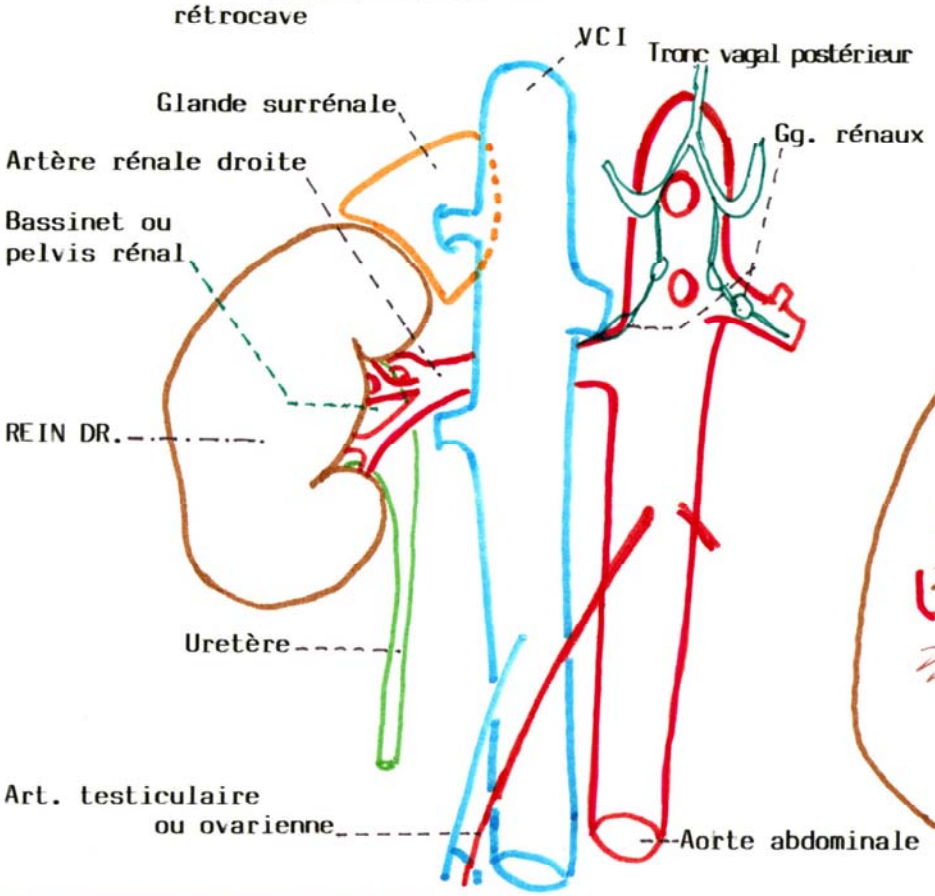

COUPE AXIALE DU HILE

Bifurcation fréquente en :

- 1 rameau antérieur prépyélique
- et 1 rameau postérieur, rétropyélique

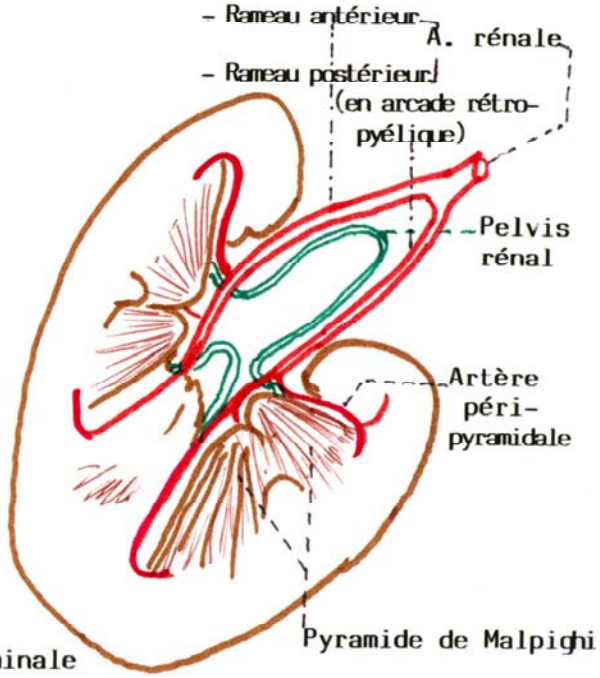

"L'ARC EXORENAL" DANS LA CAPSULE ADIPEUSE

(anastomoses avec les territoires voisins)

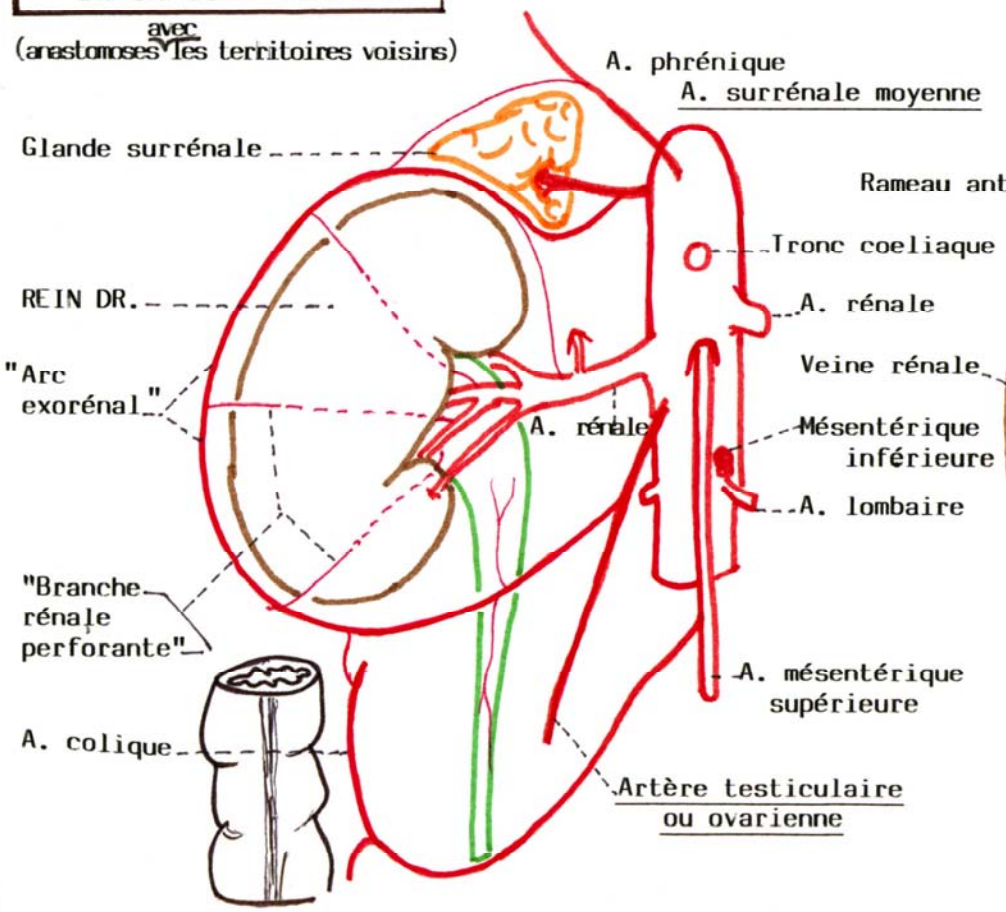
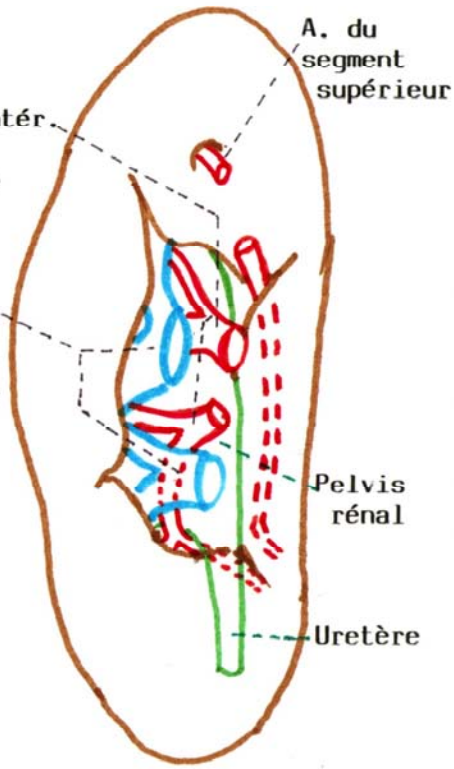
LE HILE RENAL