LE PERITOINE DU HILE DU FOIE et LE LIGAMENT VEINEUX

(vue postero-inférieure)

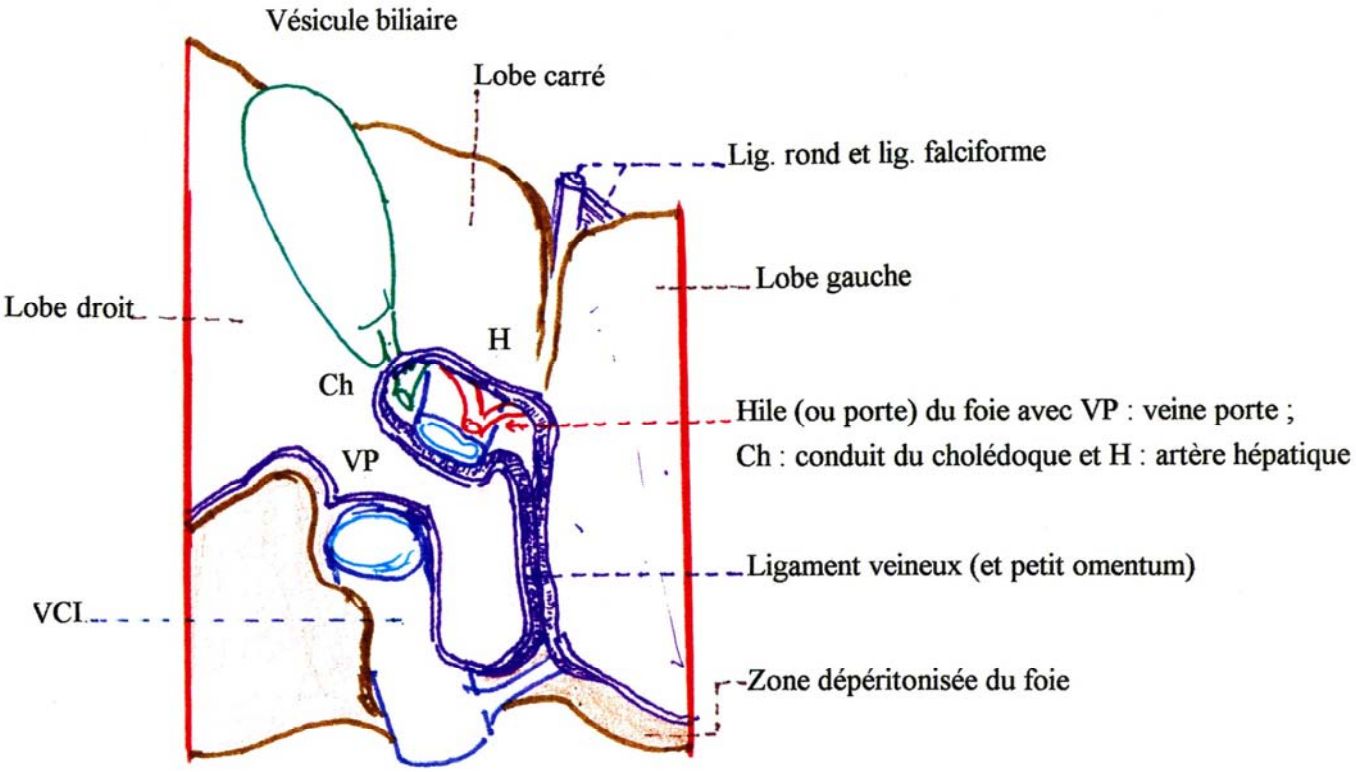
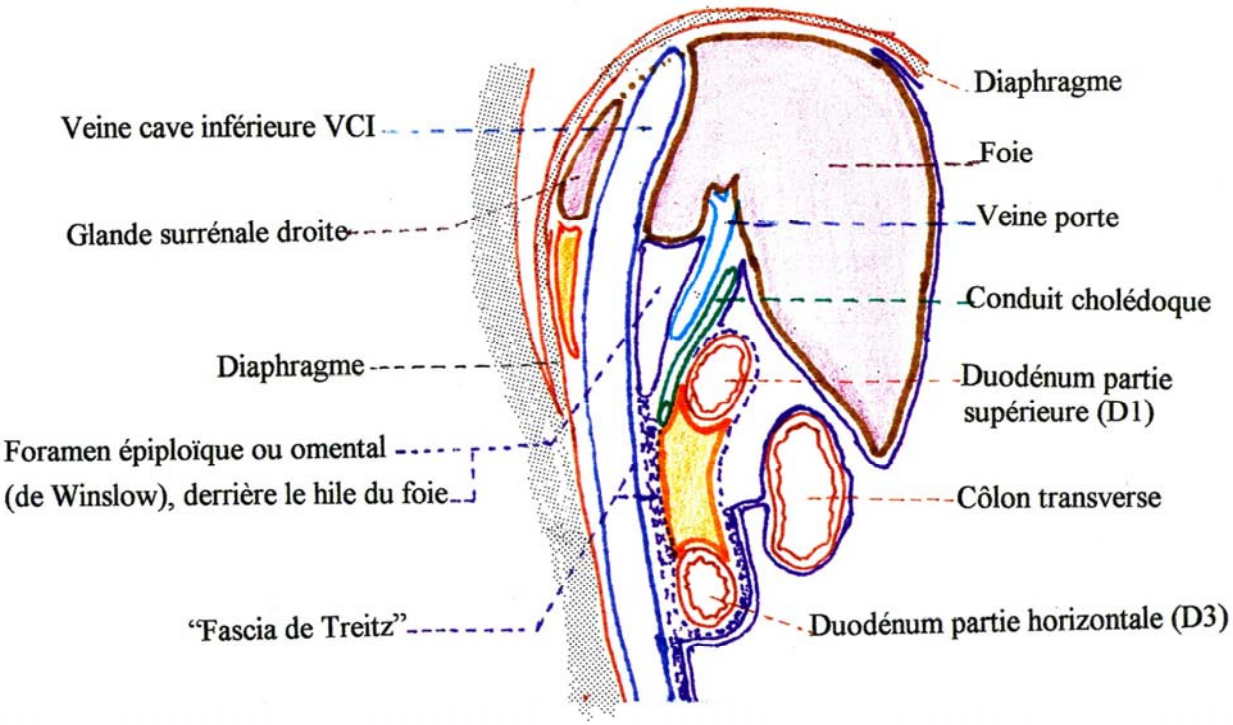
COUPE SAGGITALE DU FOIE : LE FORAMEN OMENTAL