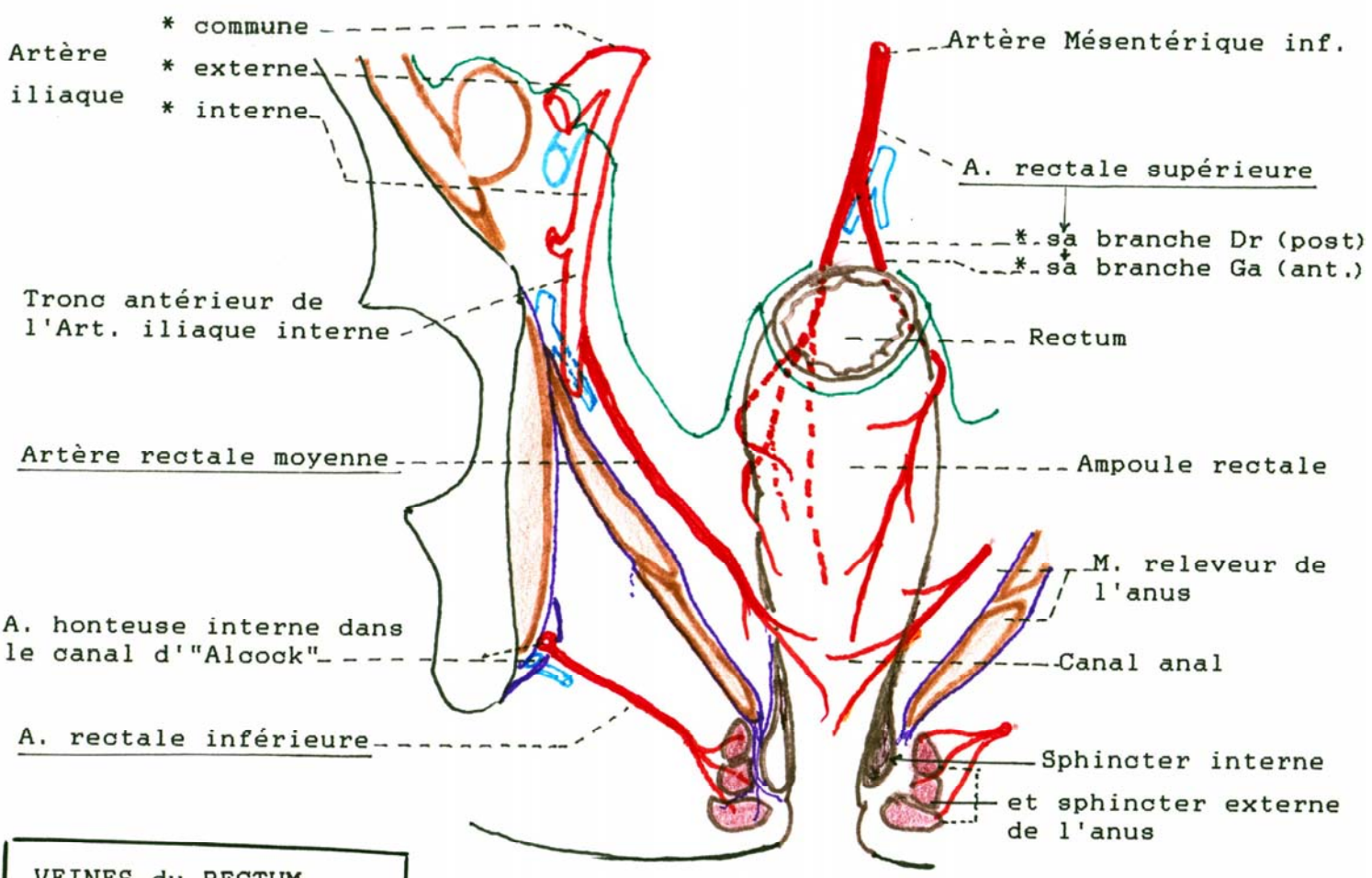
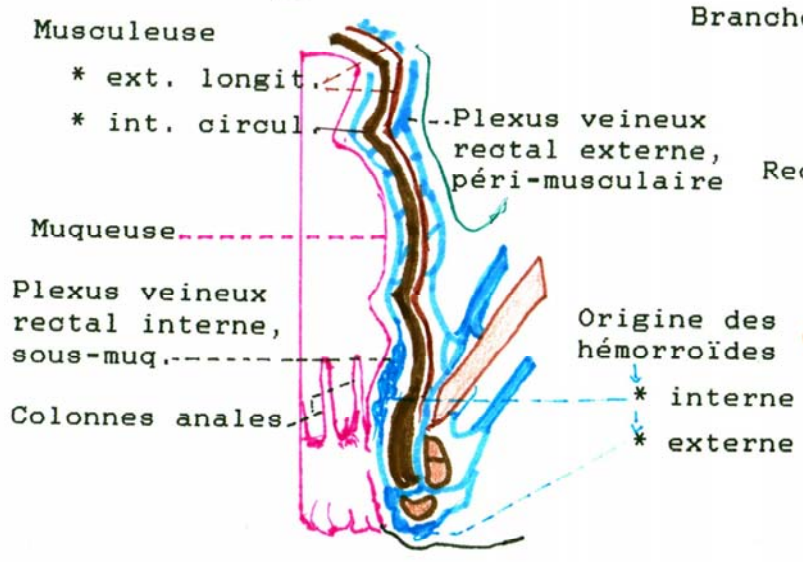


VASCULARISATION DU RECTUM

ARTERES :
VUE ANTERIEURE



VEINES du RECTUM
COUPE FRONTALE



Anus
VUE POSTERIEURE

