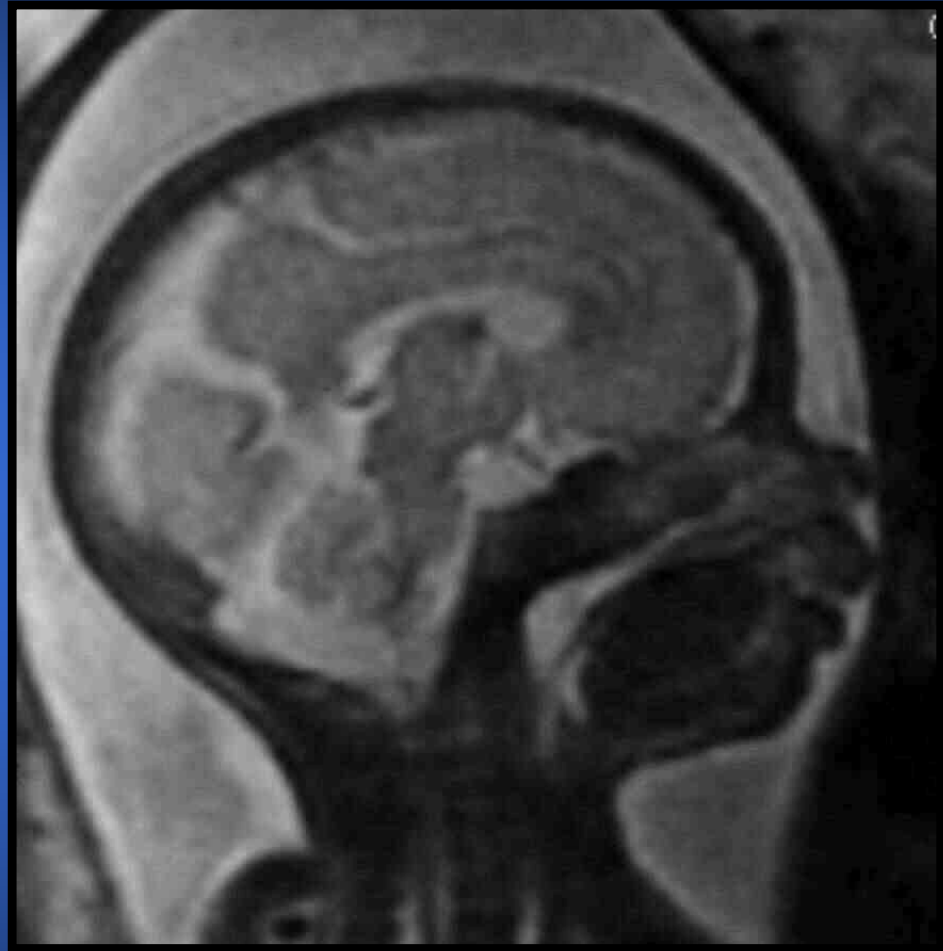
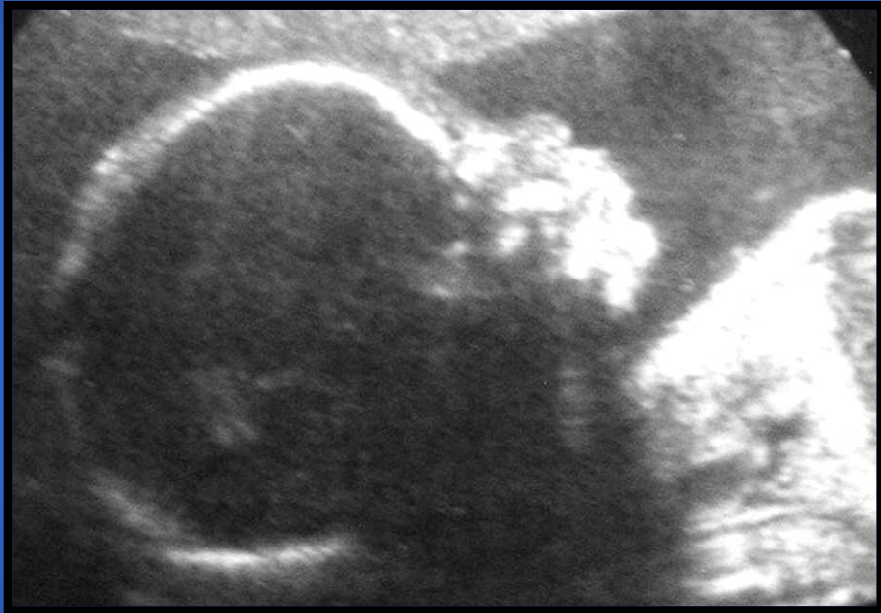

IRM foetale



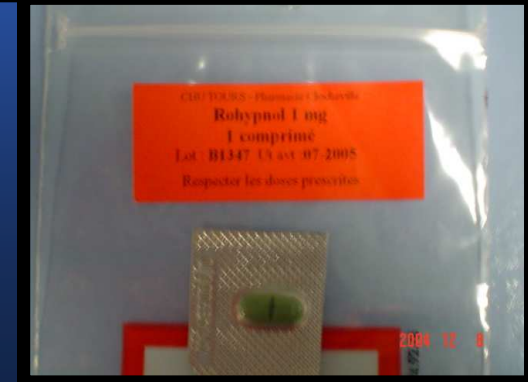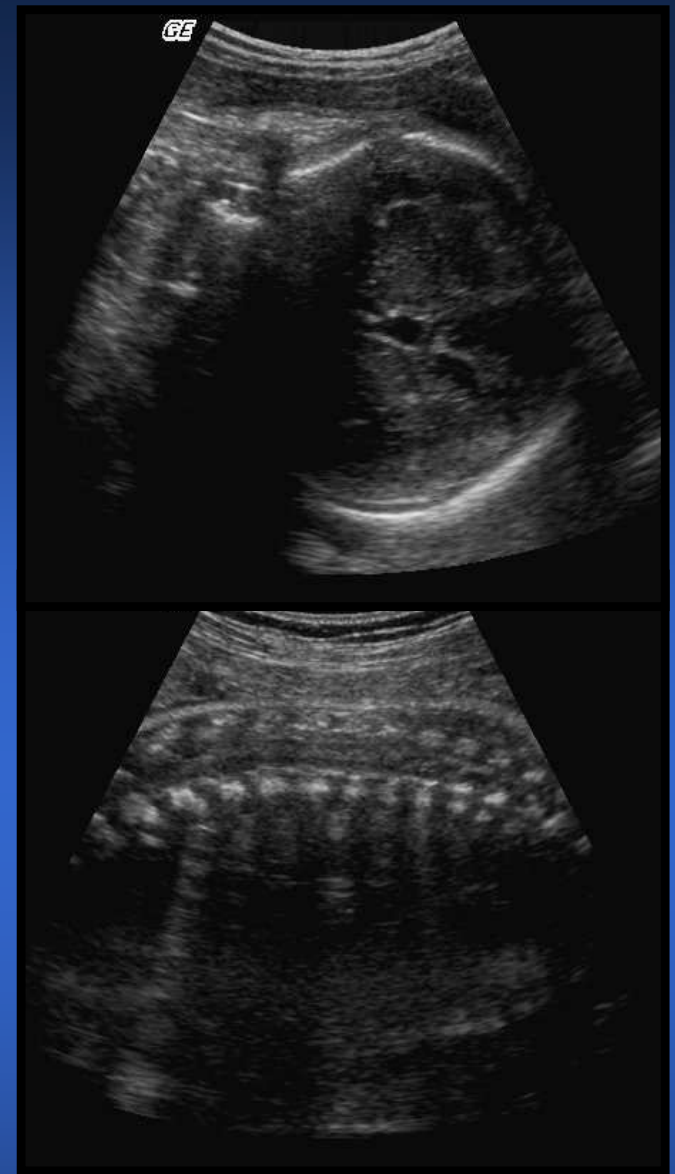
Dr C Sembely-Taveau CHU Tours

EXAMEN DE DEUXIEME INTENTION

- **STAFF PLURIDISCIPLINAIRE**
- **APPORT DIAGNOSTIC ET
PRONOSTIC POUR L'ENFANT A
NAITRE**
- **CERVEAU FCETALE**
- **AUTRES ORGANES : THORAX
ABDOMEN, MOELLE AUTRES**

PREPARATION

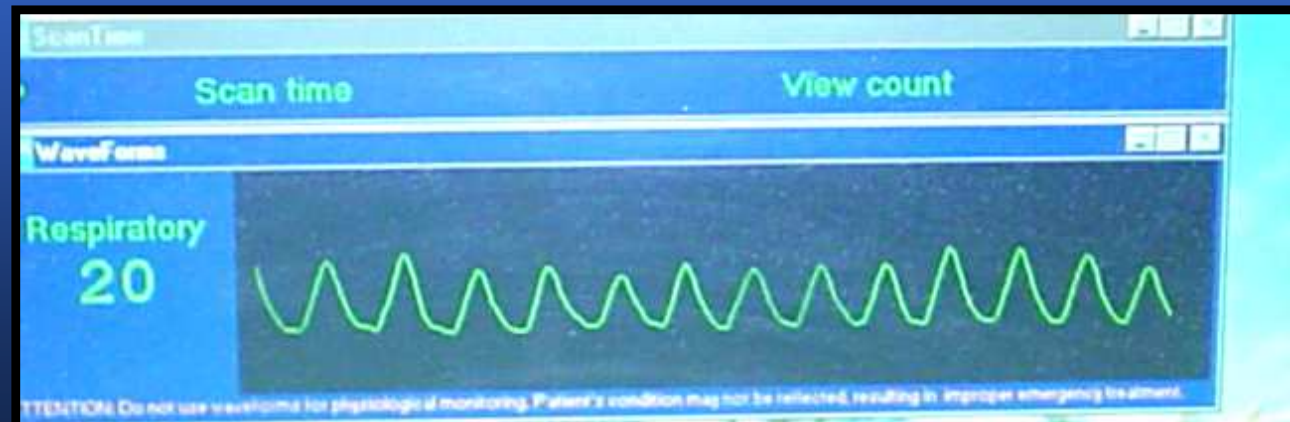
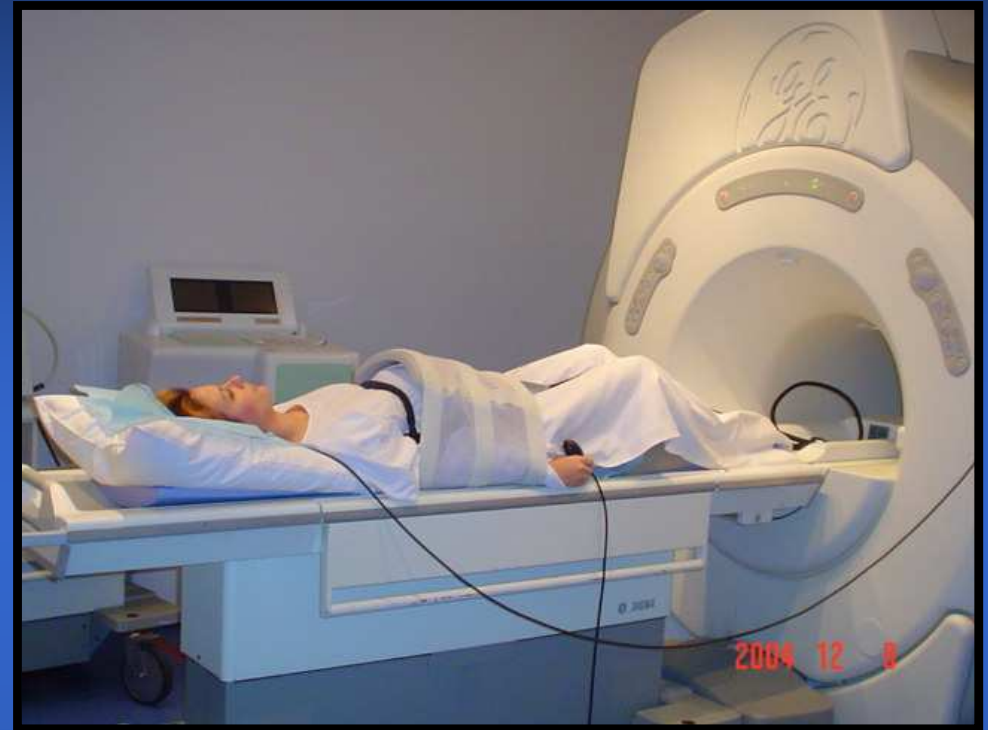- **ACCUEIL ET EXPLICATIONS :**
- **stress**
- **+/- Repérage échographique**
 - **présentation fœtale**
 - **pathologie**
- **Immobilité fœtale**
 - **Hyperpnée 20'**
 - **+/- Prémédication Rohypnol 1mg**
1/2h à 1h avant le début de
l'examen
 - **Musique ...**
- **Vessie vide**



PREPARATION



- **Décubitus dorsal**
- **Antenne centrée sur l'organe à explorer**
- **Gating respiratoire**

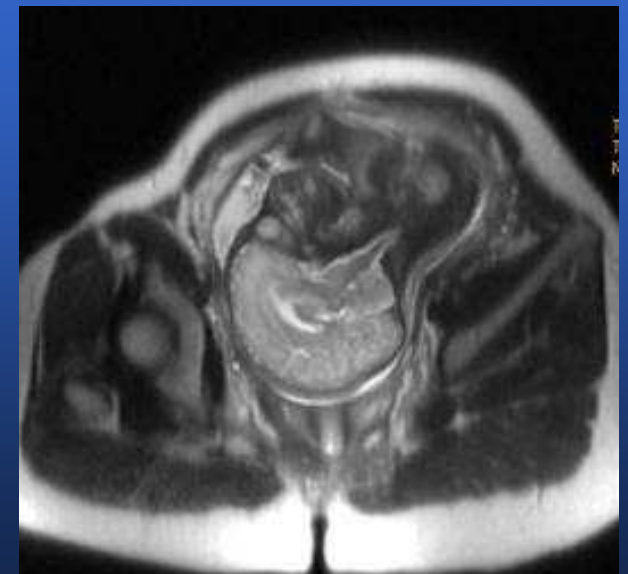
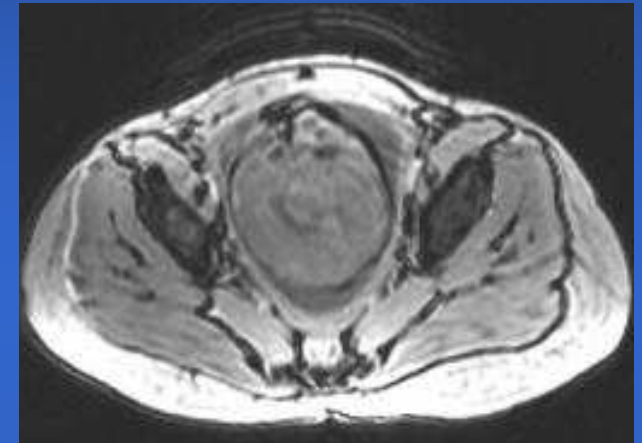
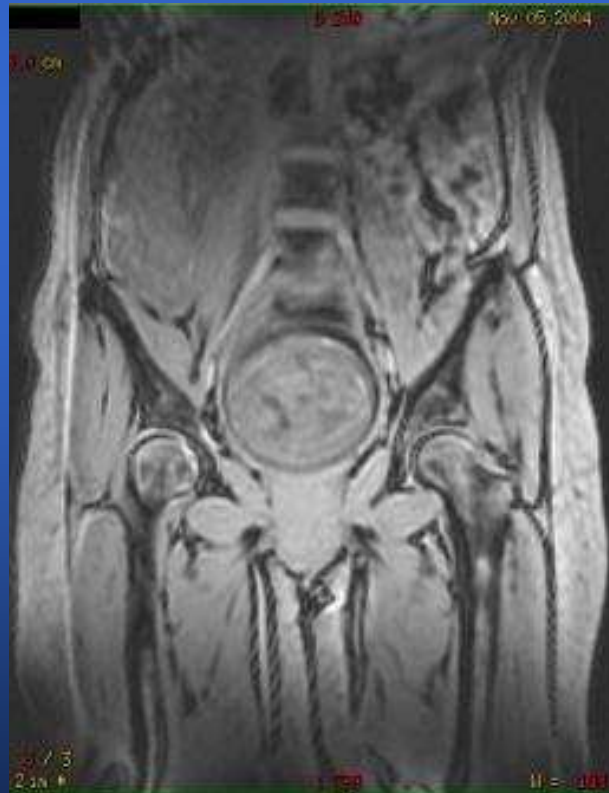
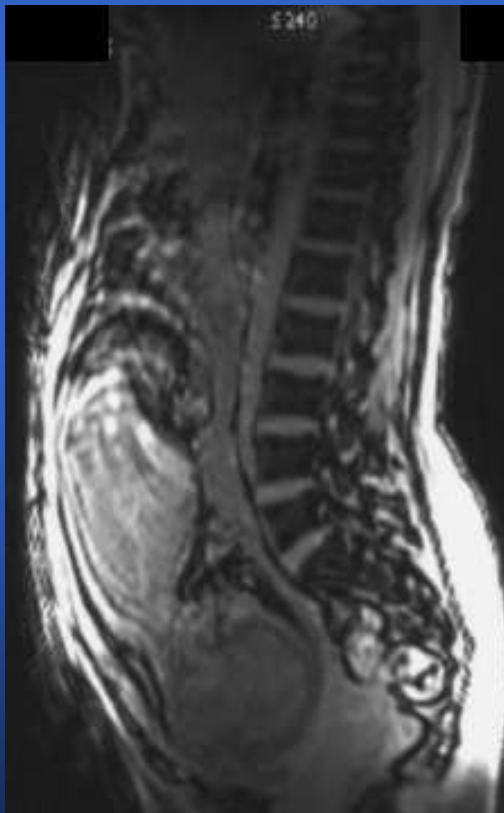


Réalisation : IRM cérébrale foetale

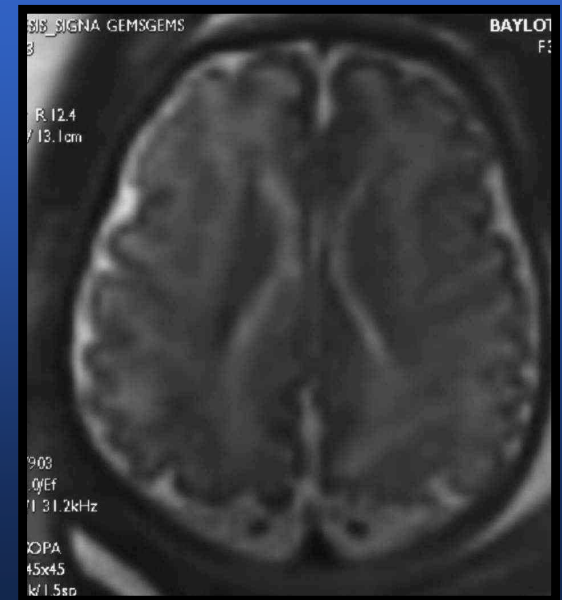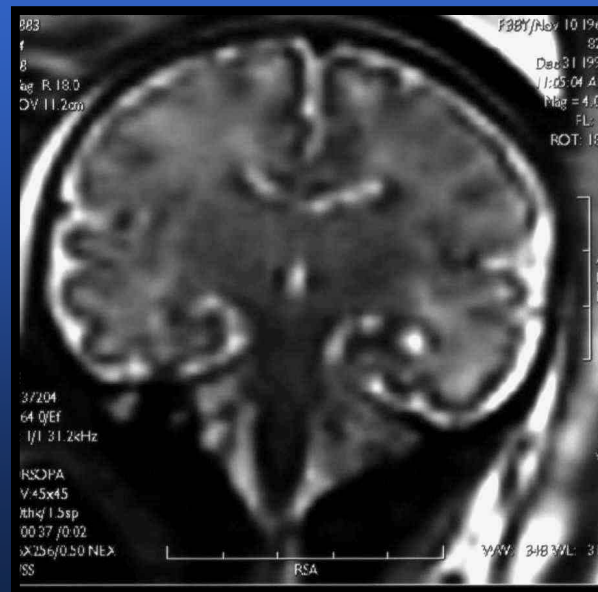
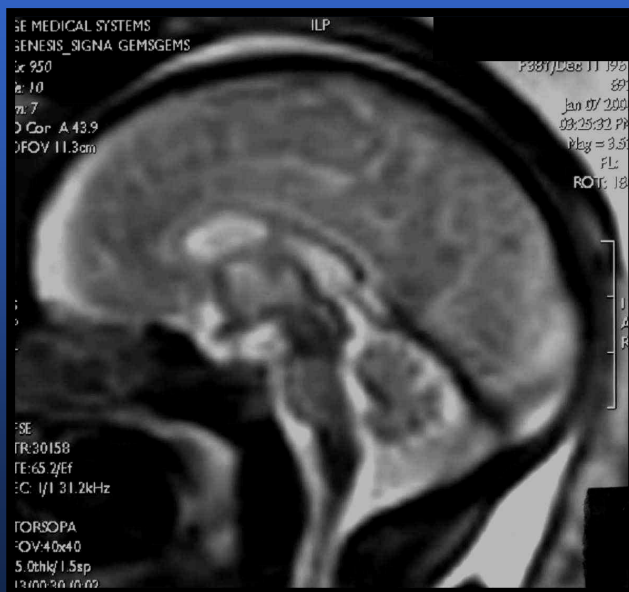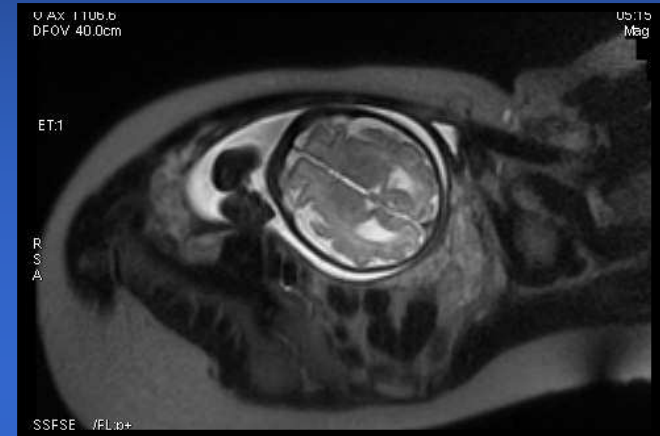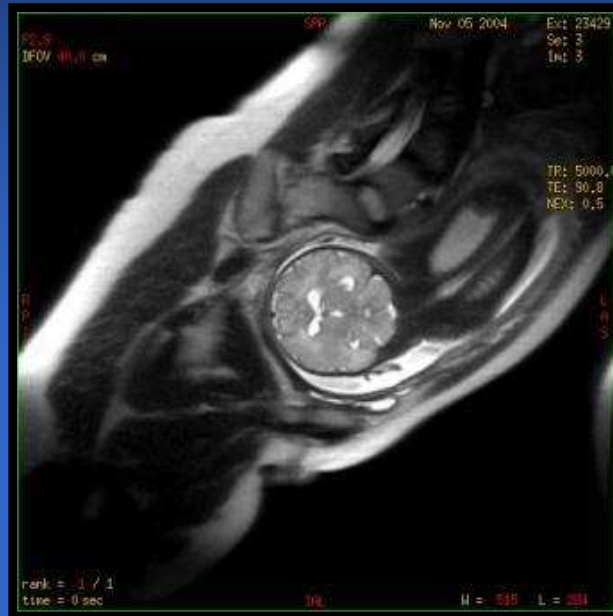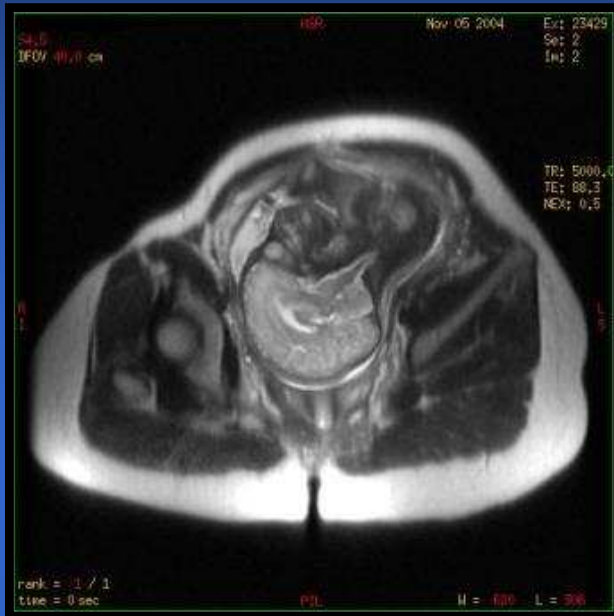- **Repérage /calibrations**
- **Séquences rapides de repérage jusqu'à obtention d'un plan anatomique :**
 - EG ultra rapide T2*/T1 : FIESTA 2D (balanced FFE, true fisp)
- **Séquences T2 SSFSE dans les trois plans anatomiques, coupes 1 seconde**
- **Séquence EG T1 axiale apnée 15 secondes**
 - +/- coronale et sagittale
- **Séquences T1 IR coupes 1 seconde**
- **Diffusion**
- **Séquences EG T2 2 minutes**

Réalisation : IRM cérébrale foetale

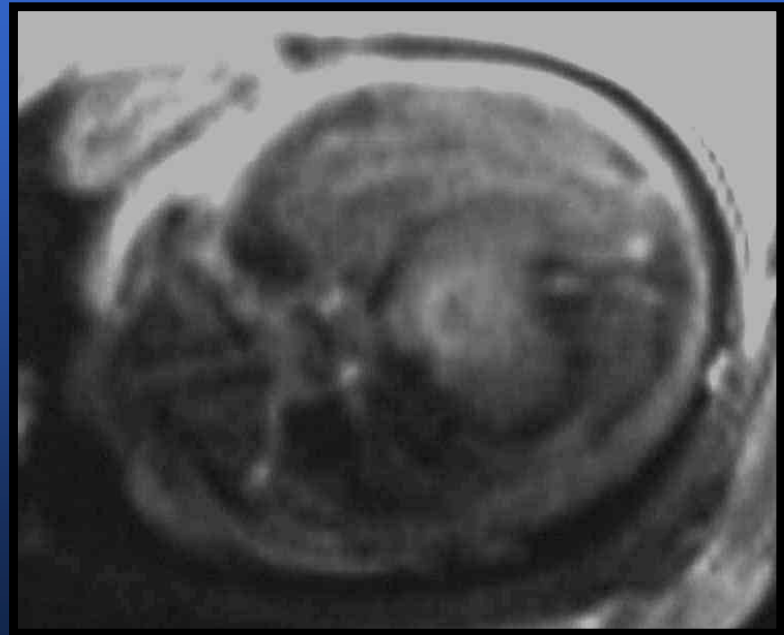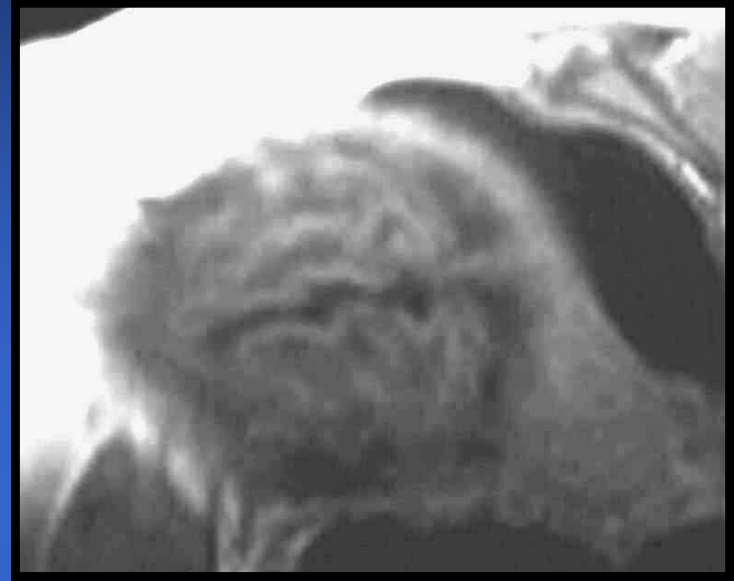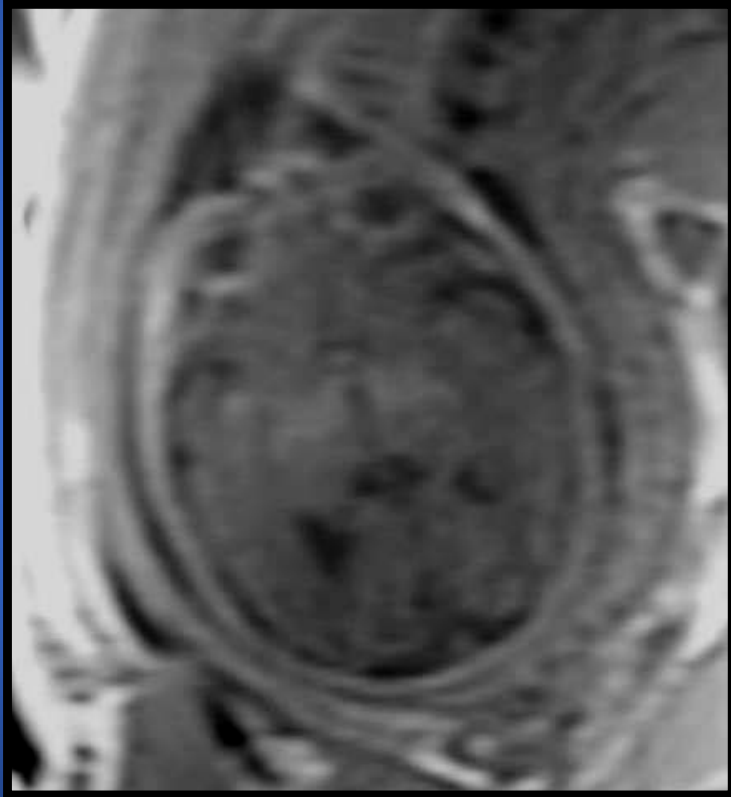
- Repérage
- Coupes fiesta : obtention d'un plan anatomique



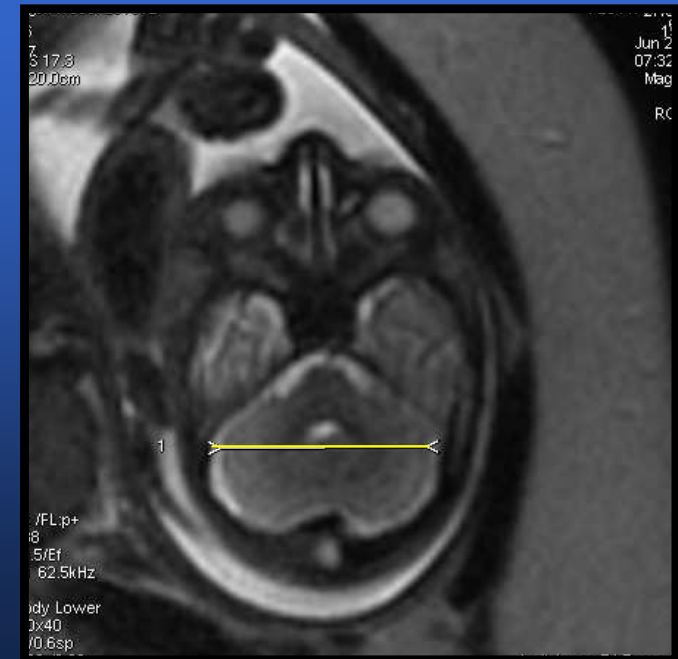
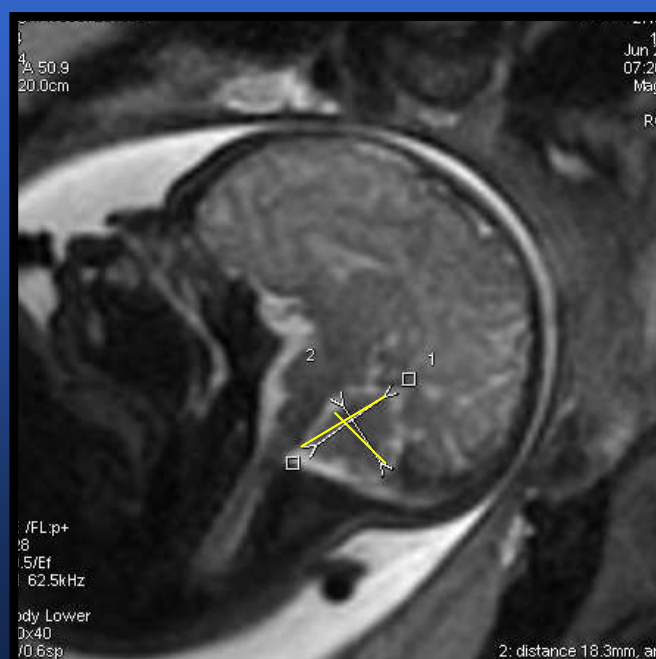
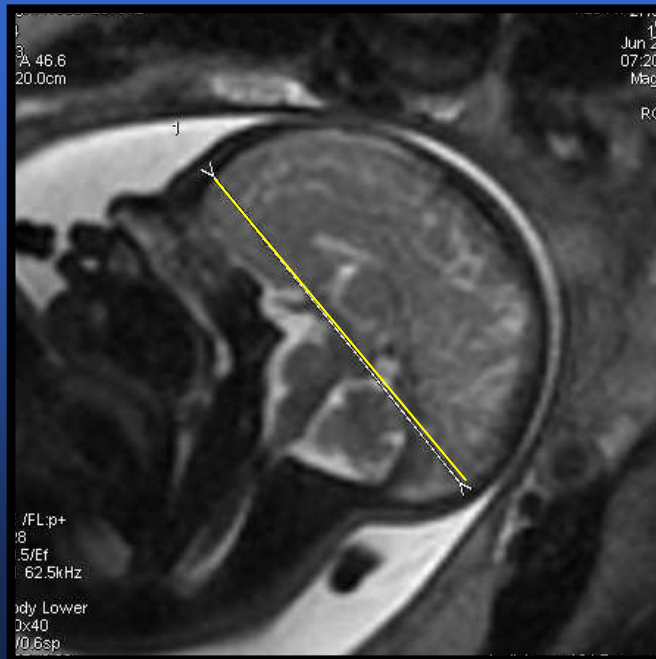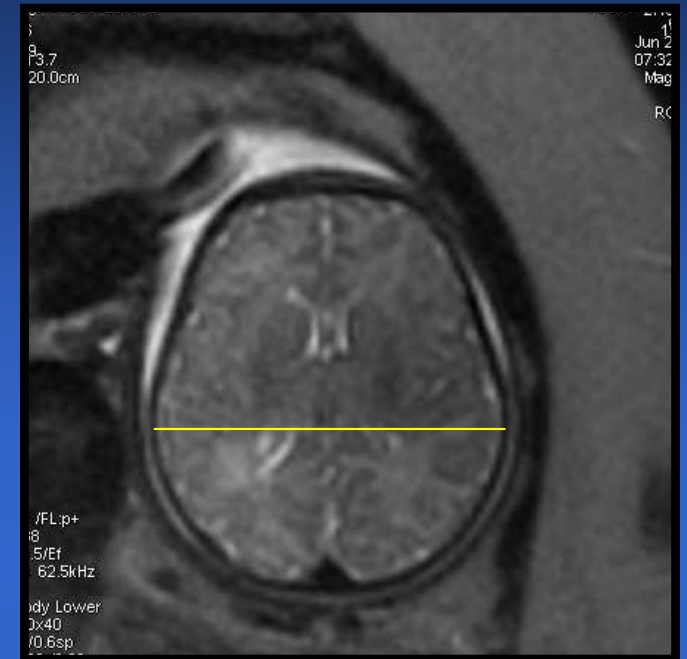
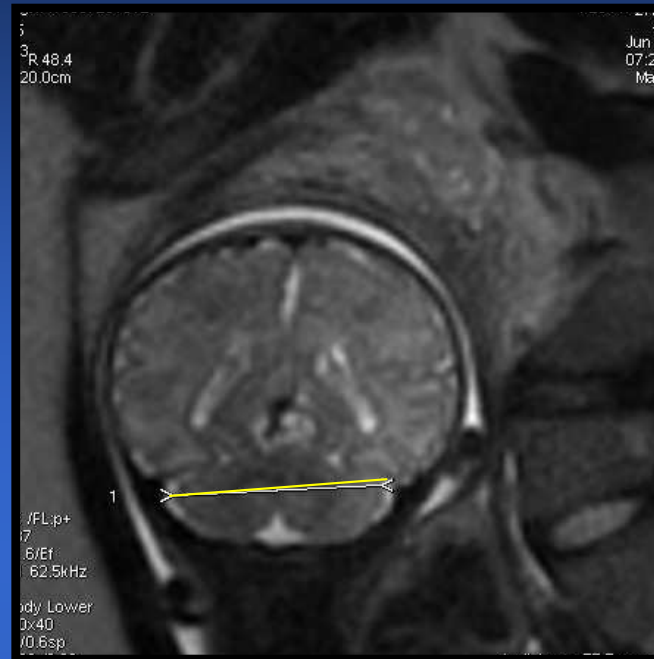
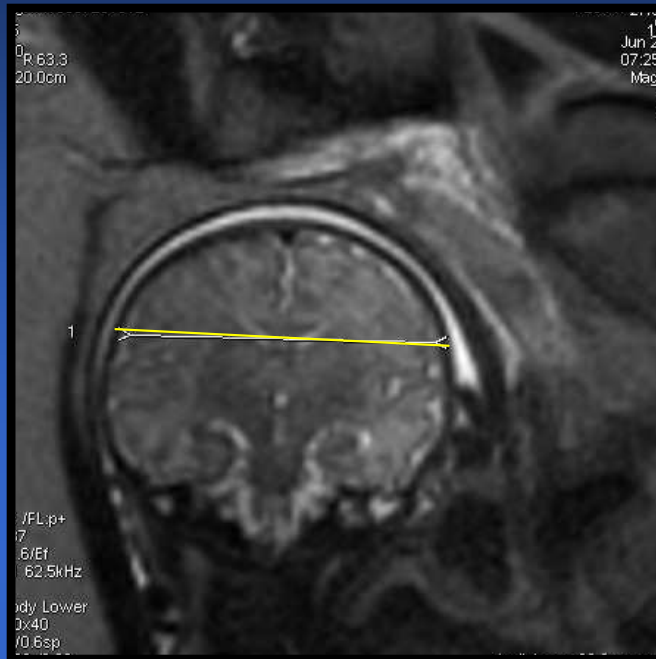
Séquences T2 SSFSE dans les trois plans anatomiques



Séquence EG T1 axiale (apnée 14 sec)

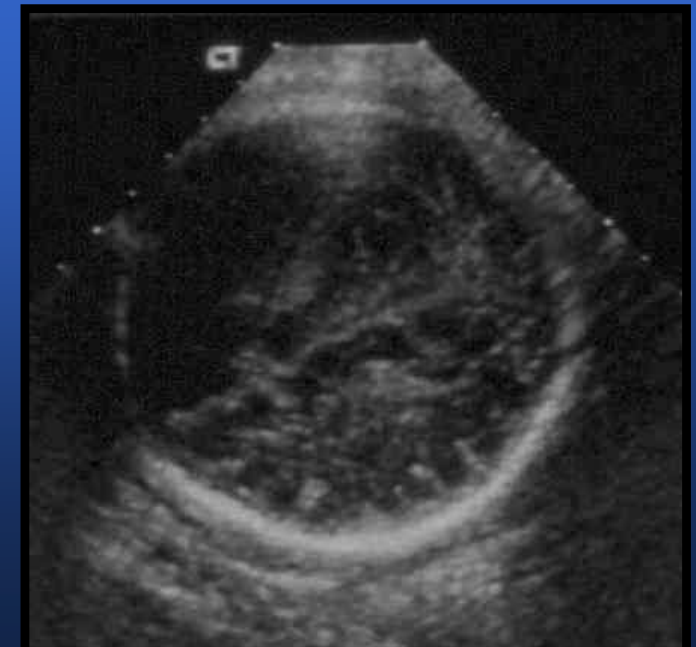
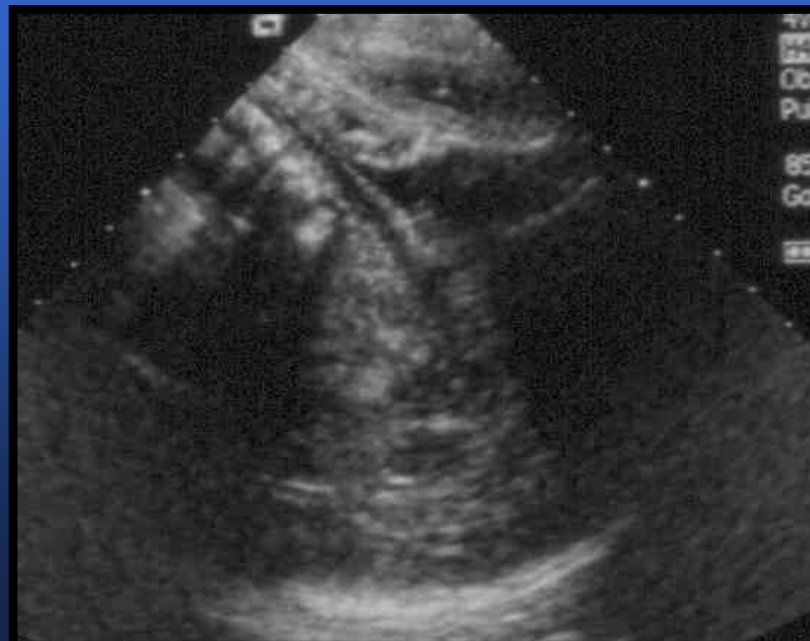
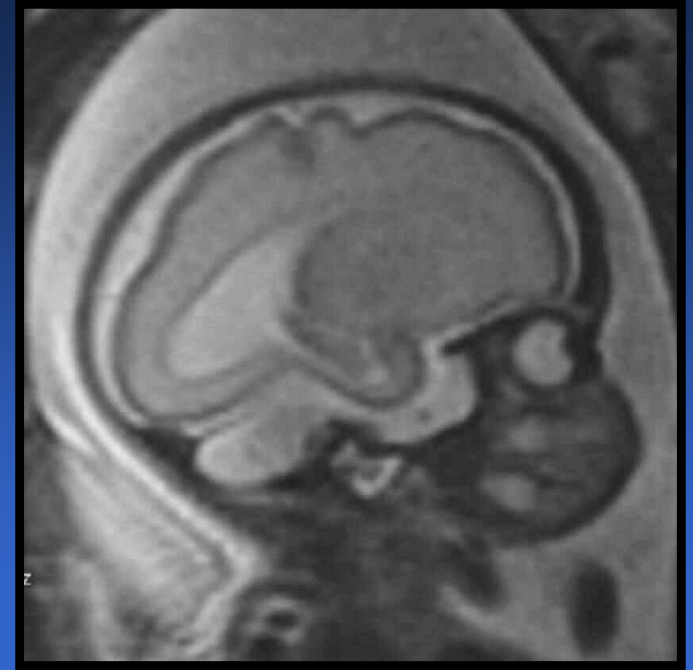
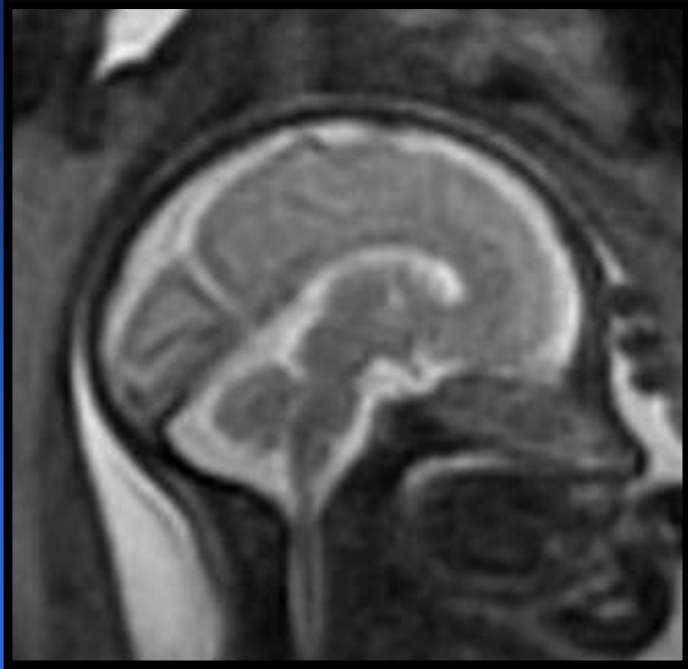
Analyse biométrique



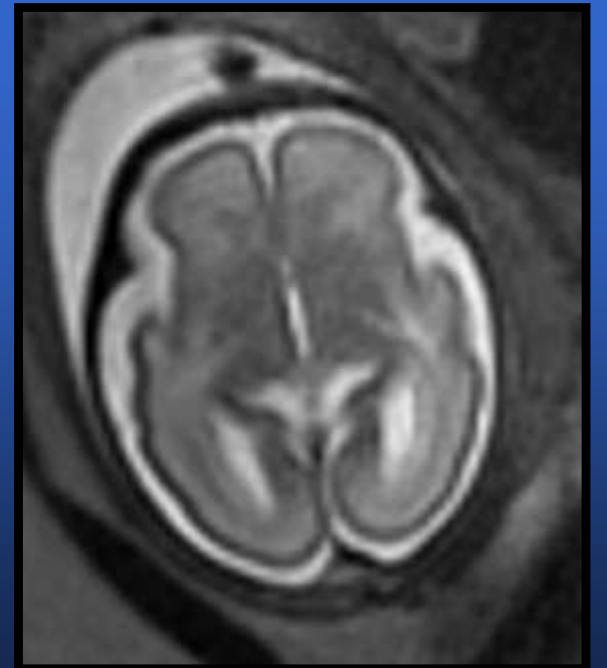
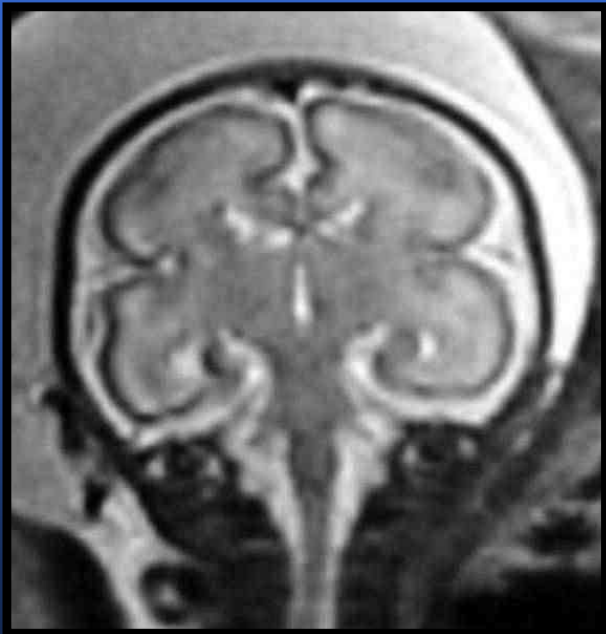ANALYSE MORPHOLOGIQUE : GYRATION CEREBRALE

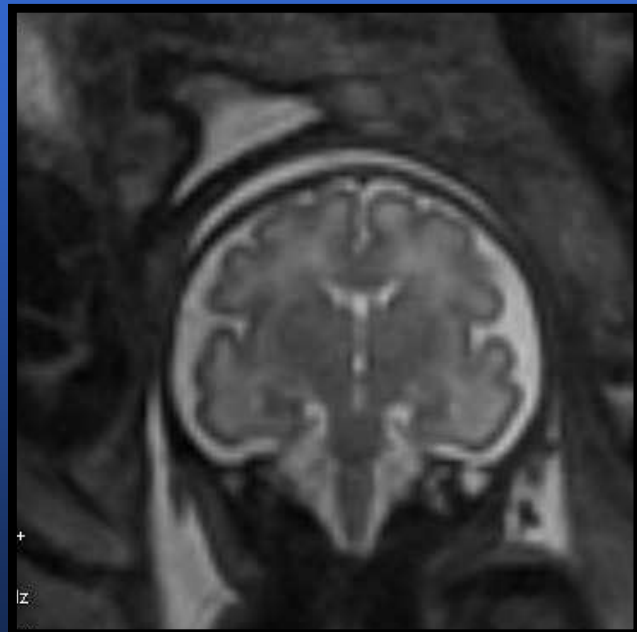
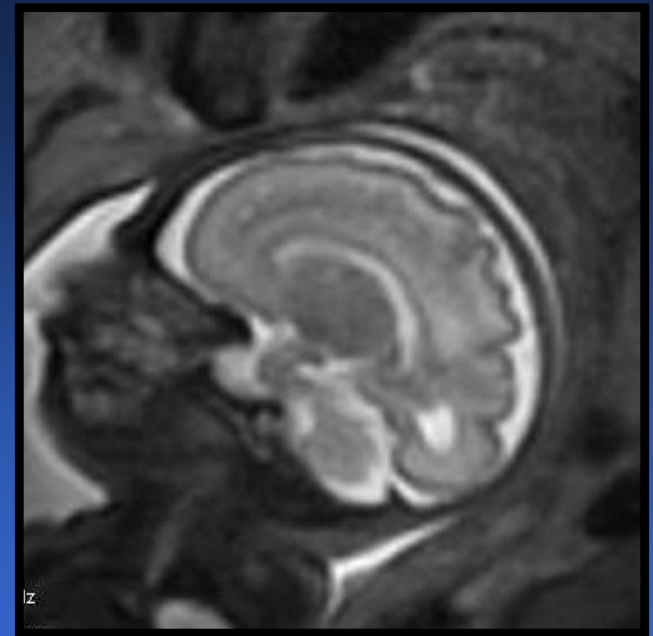
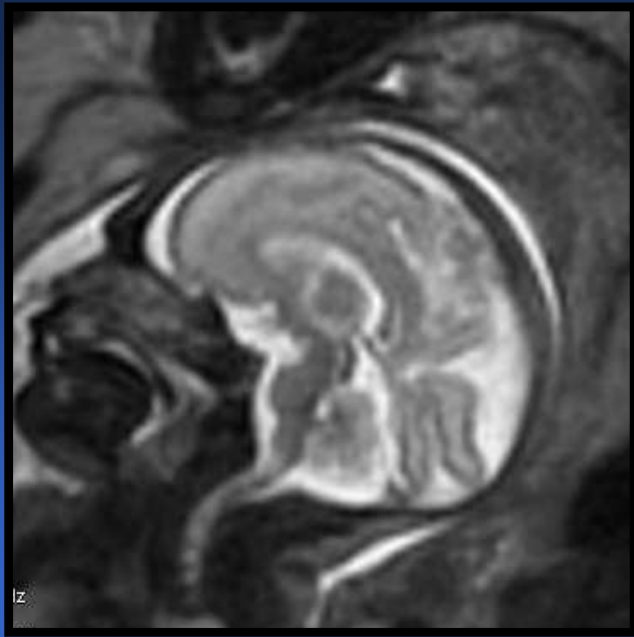
- **28 SA – 36SA**
- **Non parfaitement étudiée en échographie**
- **Date d'apparition de chaque sillon cortical connue : abaques et atlas de référence pour l'analyse en fonction de l'âge gestationnel**



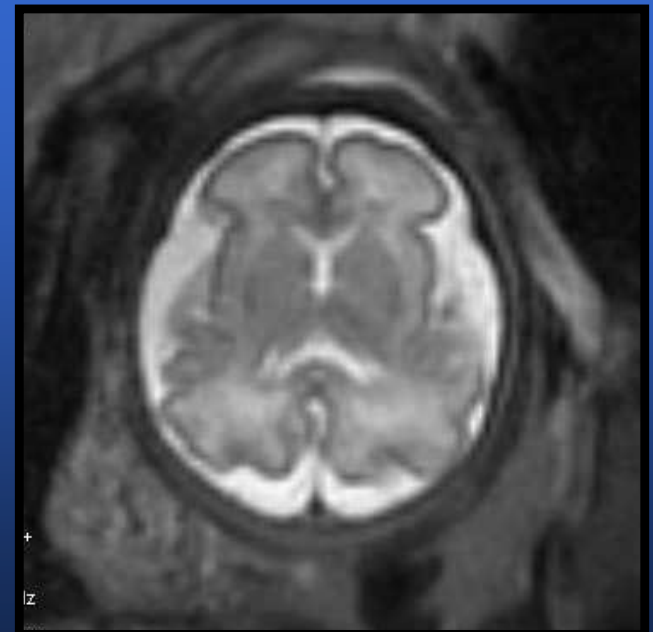


29 SA

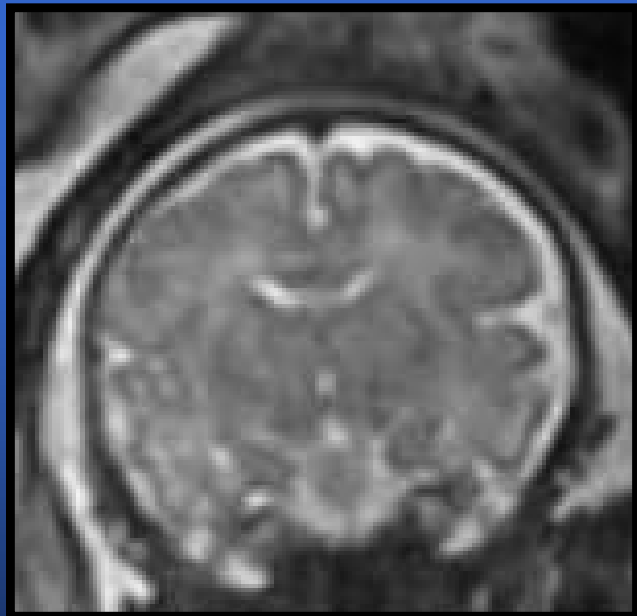
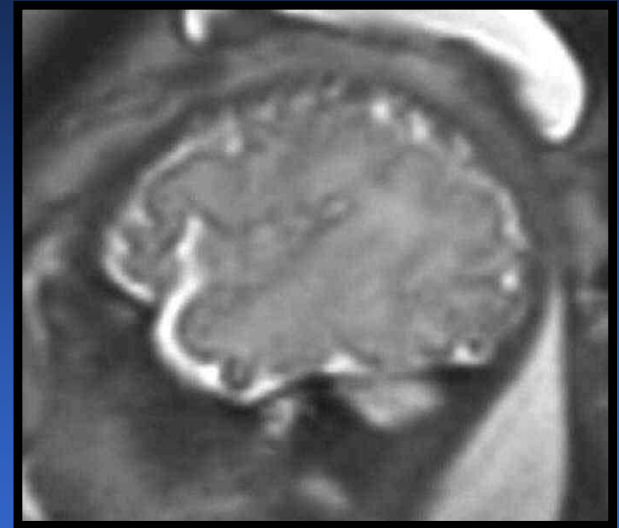
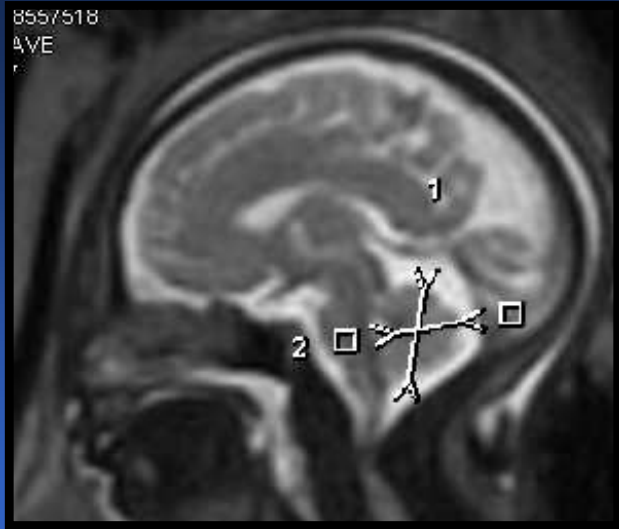




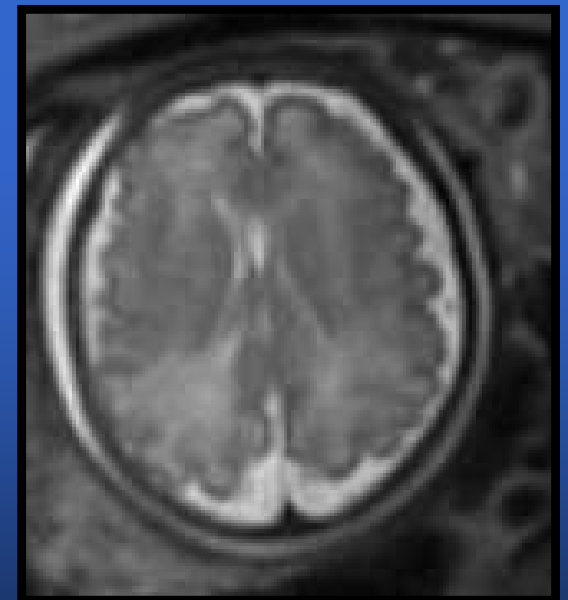
32 SA



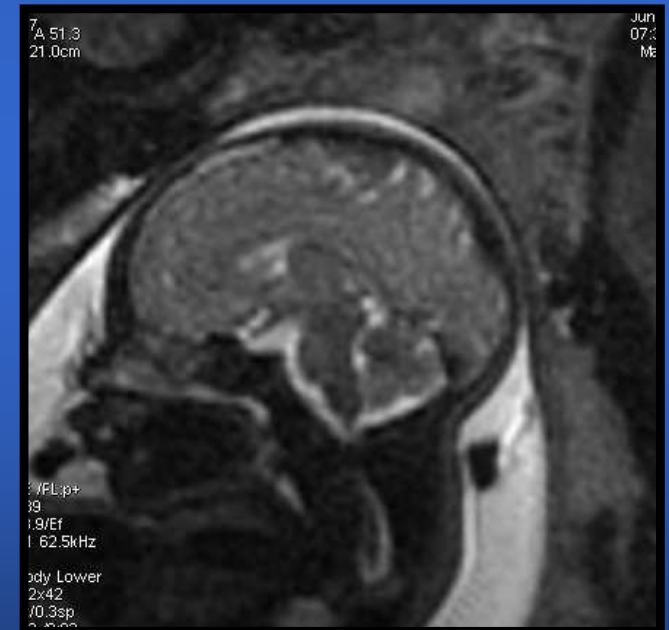
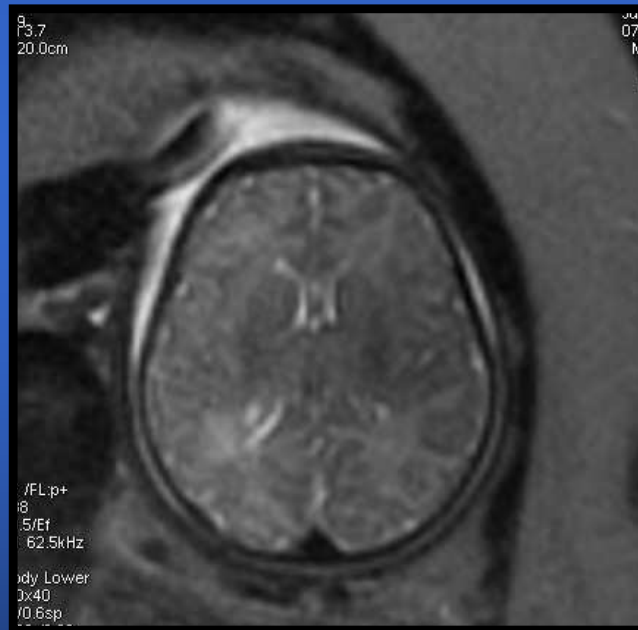
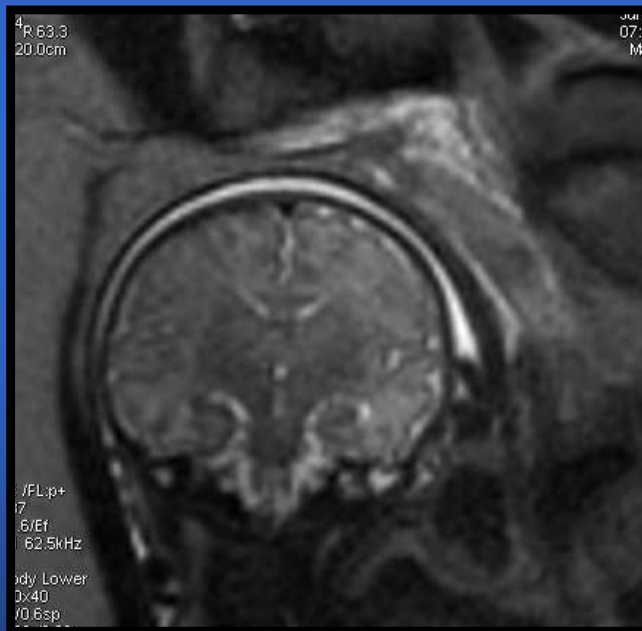
8557518
AVE
r



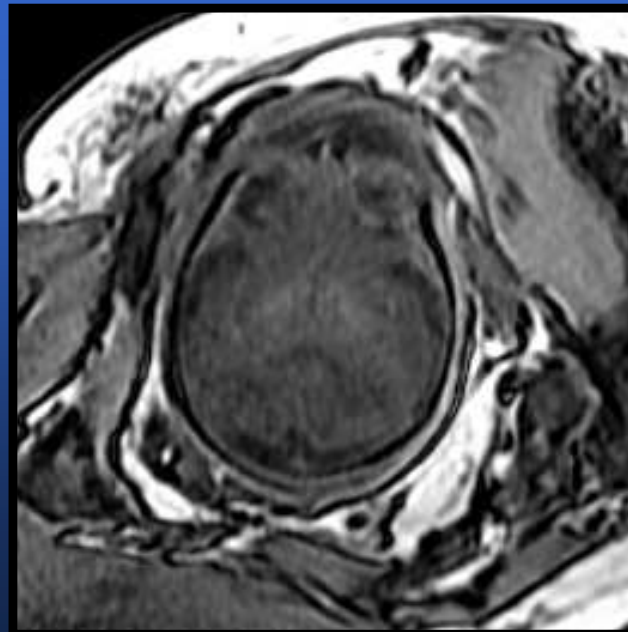
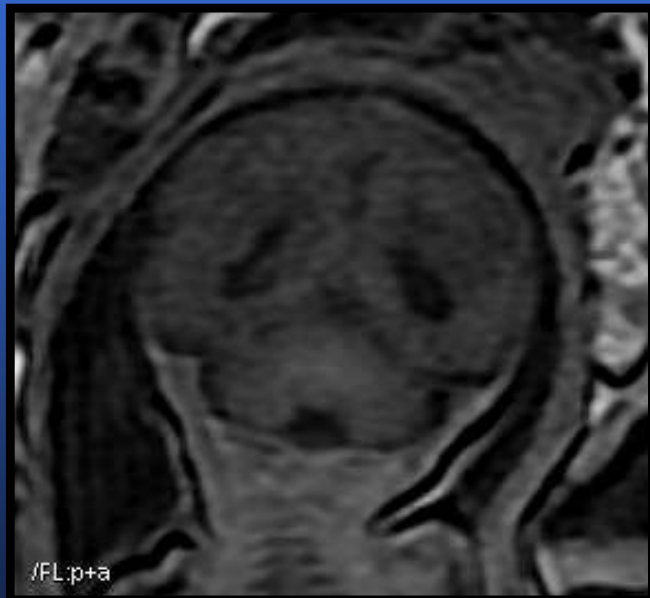
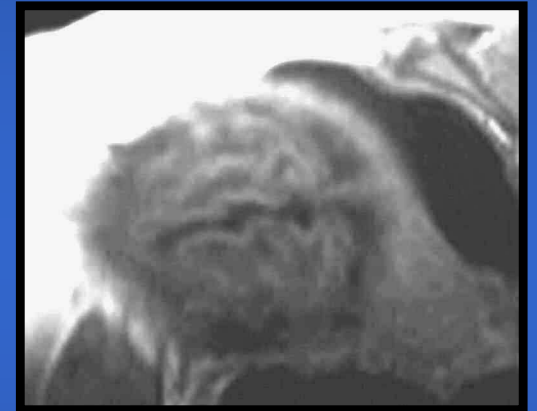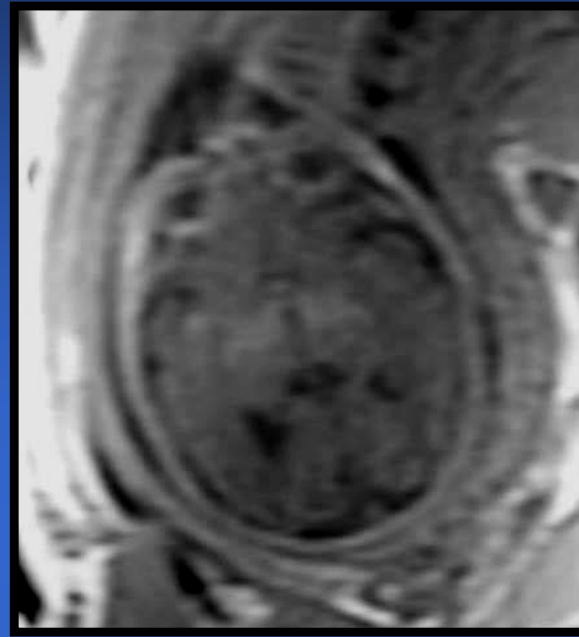
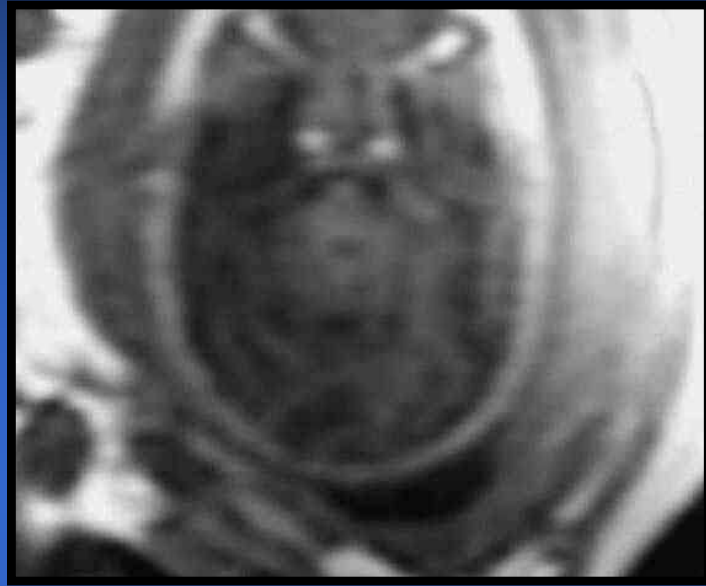34 SA



37 SA



Myélinisation



INDICATIONS : IRM CEREBRALE

Anomalies vues à l'échographie :

Malformations cérébrales

**Anomalies de l'écho-structure cérébrale :
(tumeurs, hémorragies ...)**

Dilatation ventriculaire

Autres ...

Préciser le diagnostic

**Chercher des anomalies associées non
dépistées en écho (gyration, hétérotopie)**

INDICATIONS : IRM CEREBRALE

Visualiser des anomalies non étudiables à l'échographie :

Soit sur signe d'appel échographique

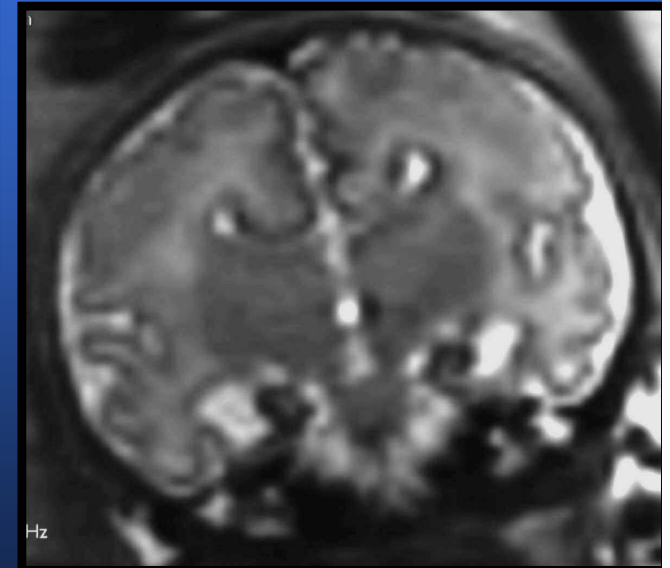
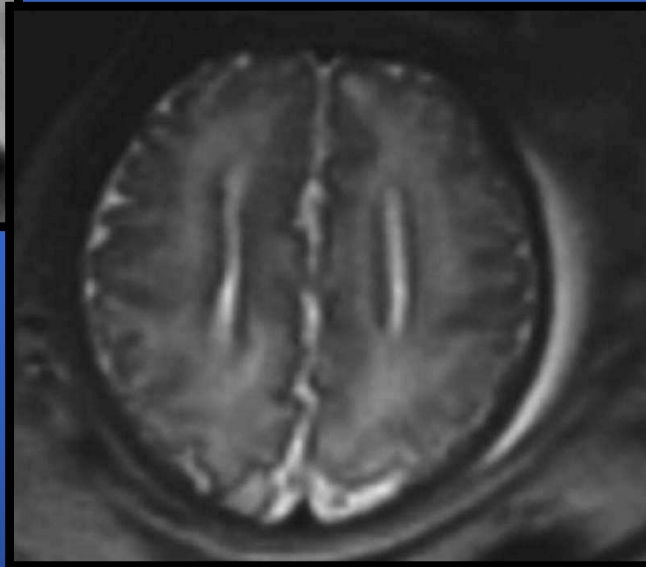
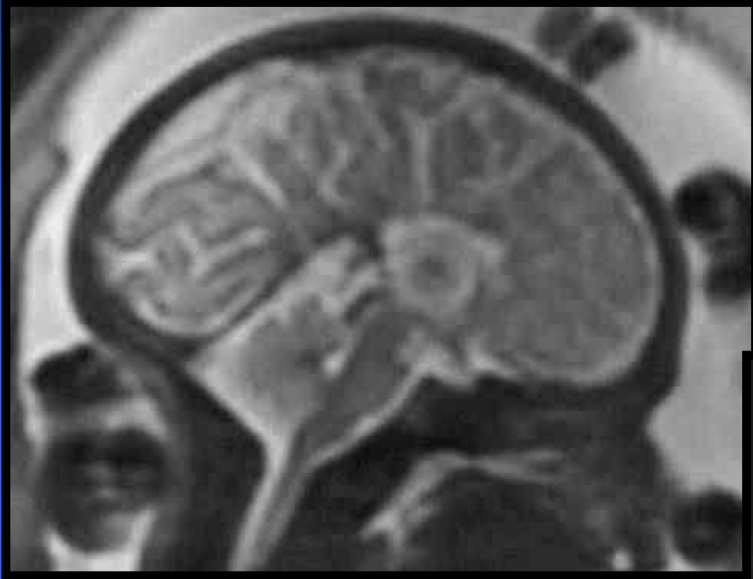microcéphalie

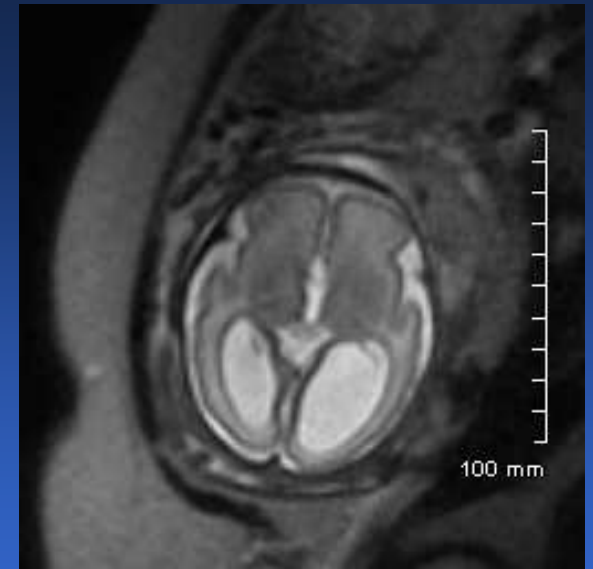
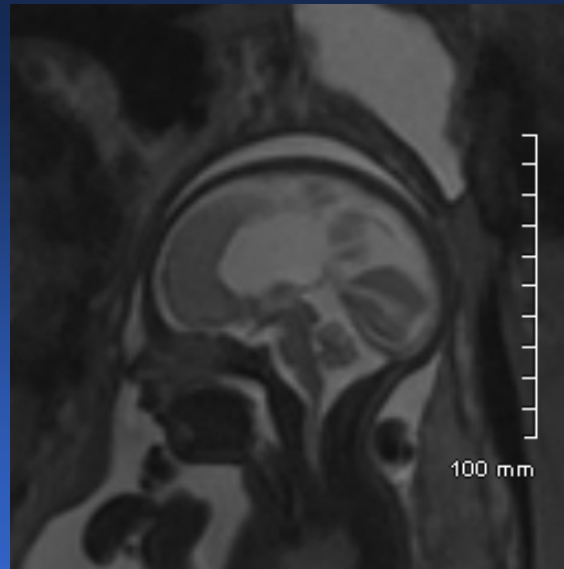
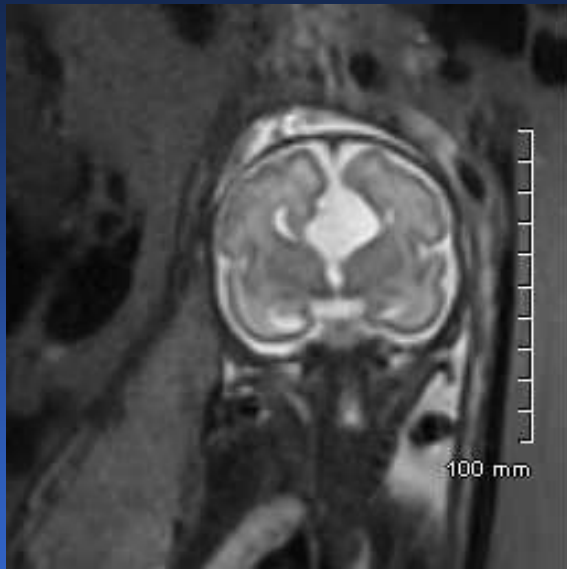
ventriculomégalie

Soit sur des antécédents particuliers

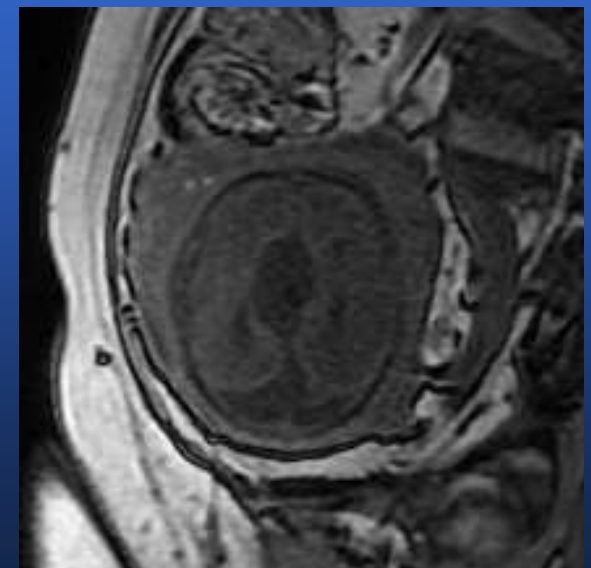
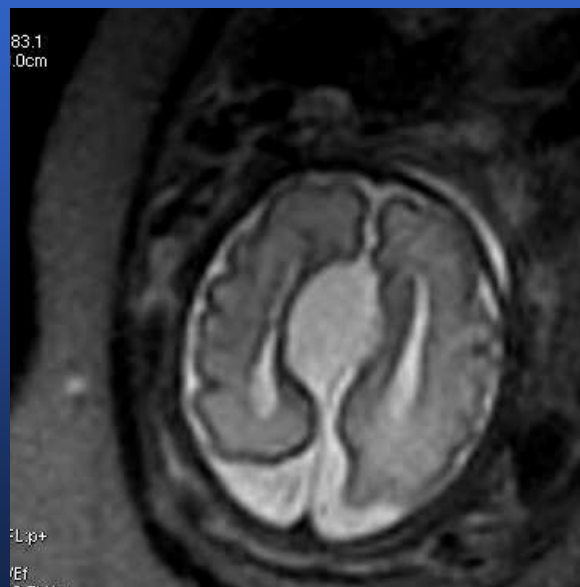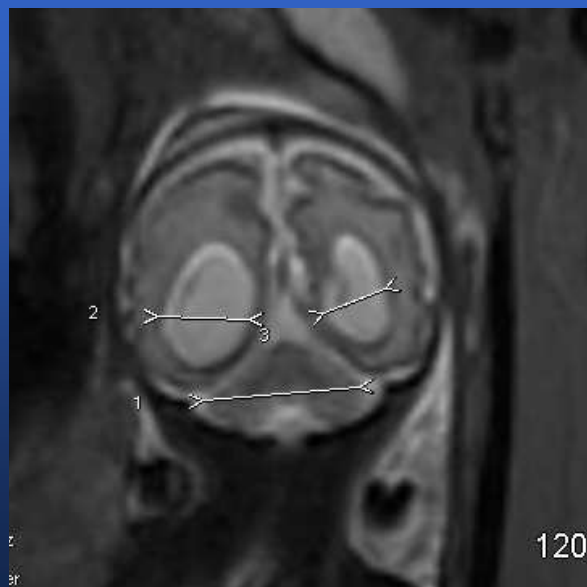
maladie génétique (STB ...), autre

MALFORMATIONS

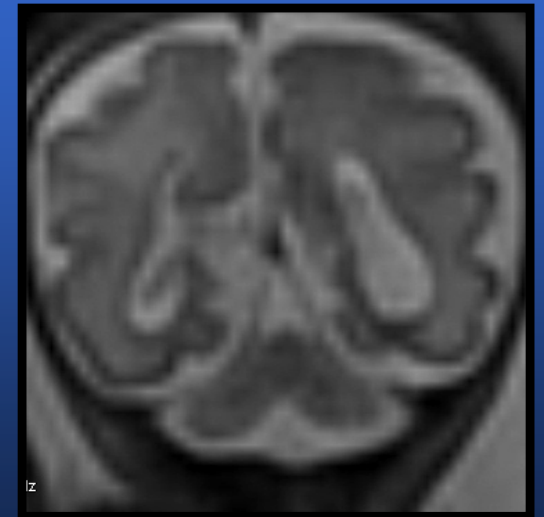
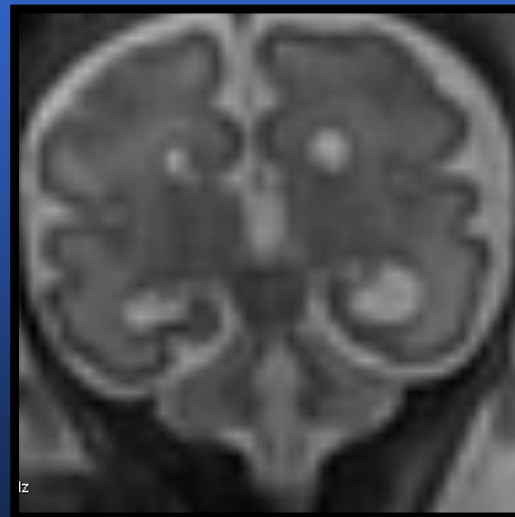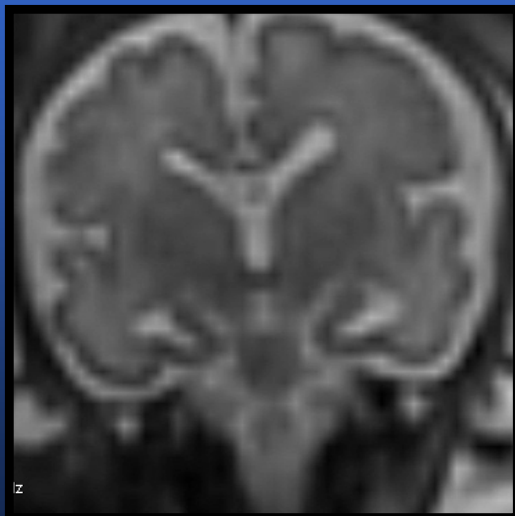
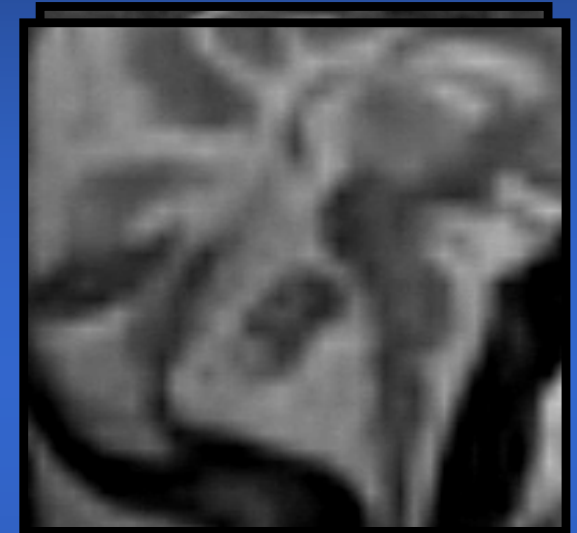
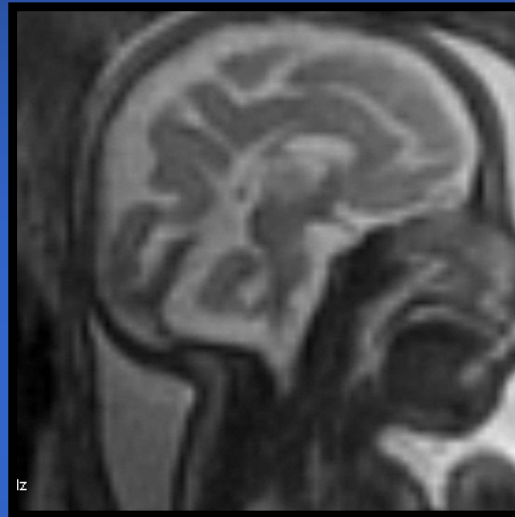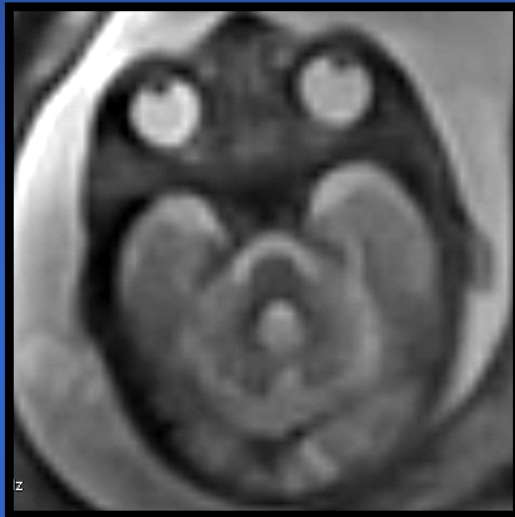




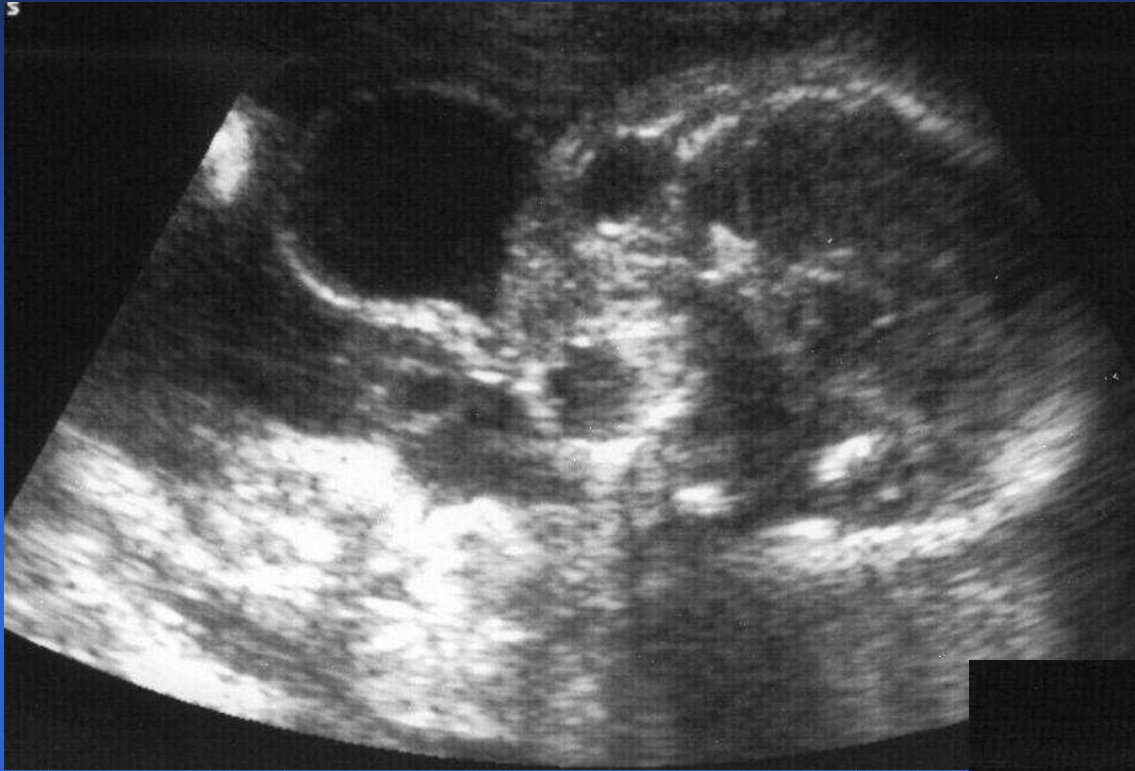
Agénésie du corps calleux avec kyste interhémisphérique



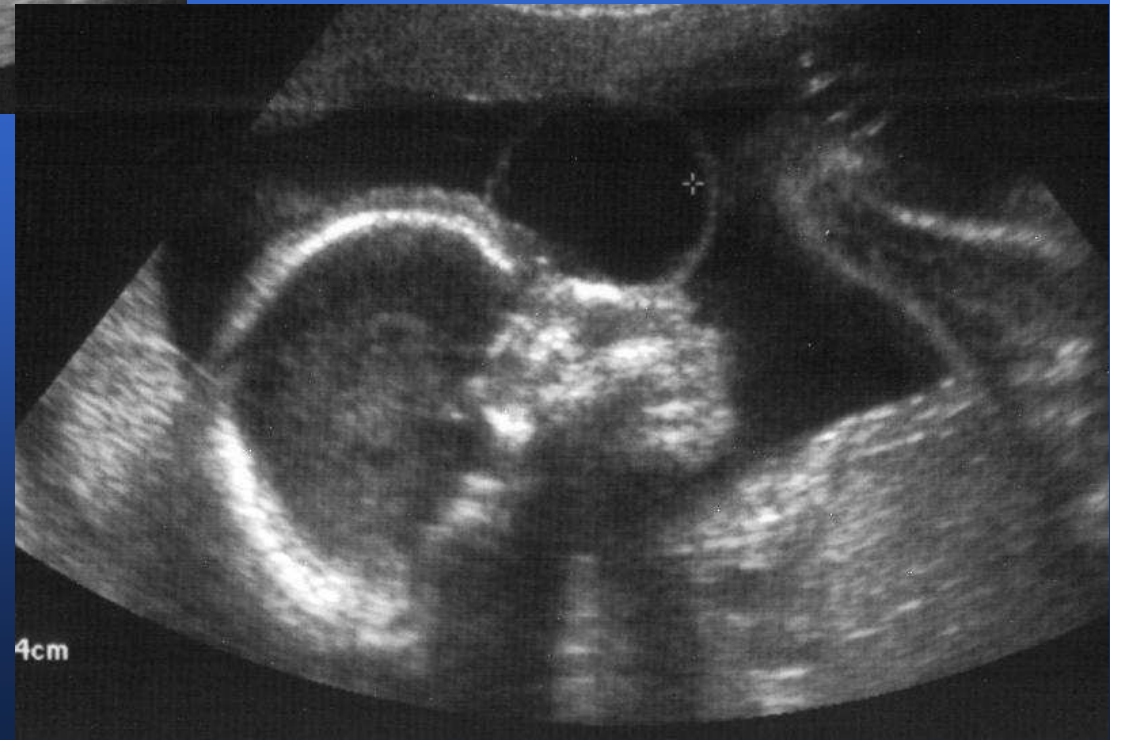Nuque épaisse CIV, ventriculomégalie

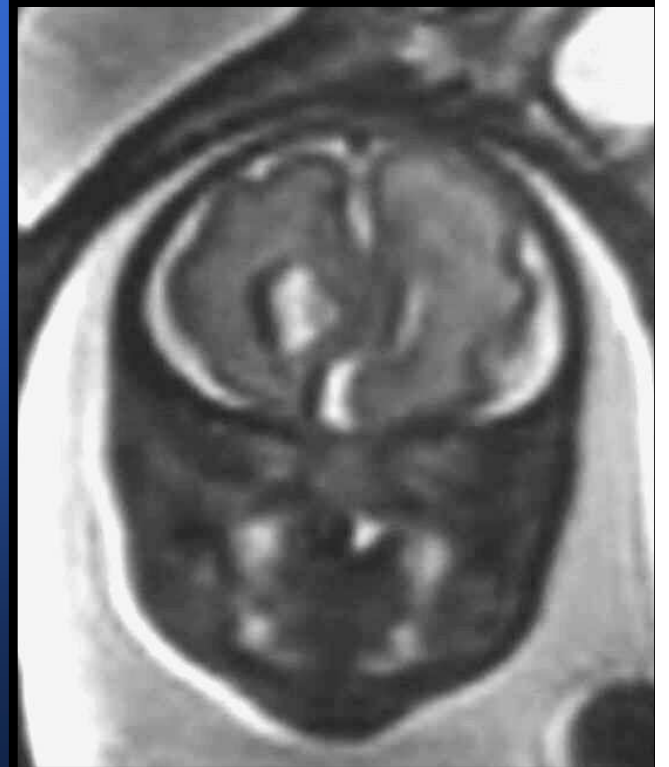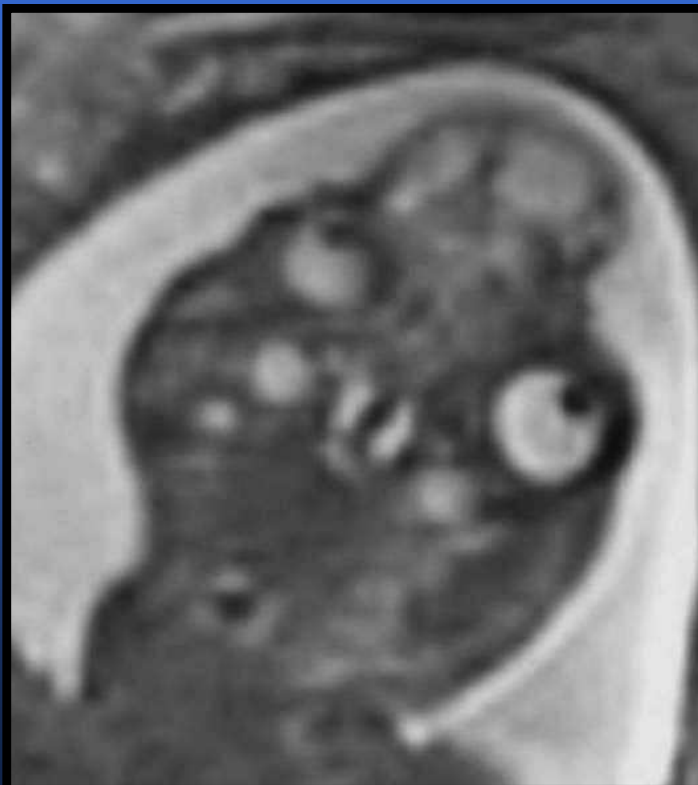
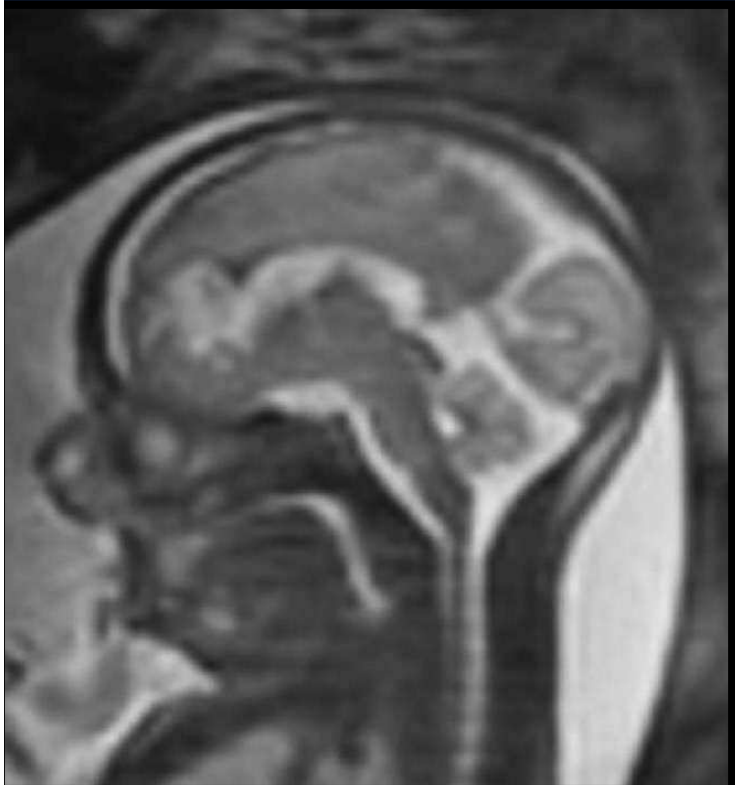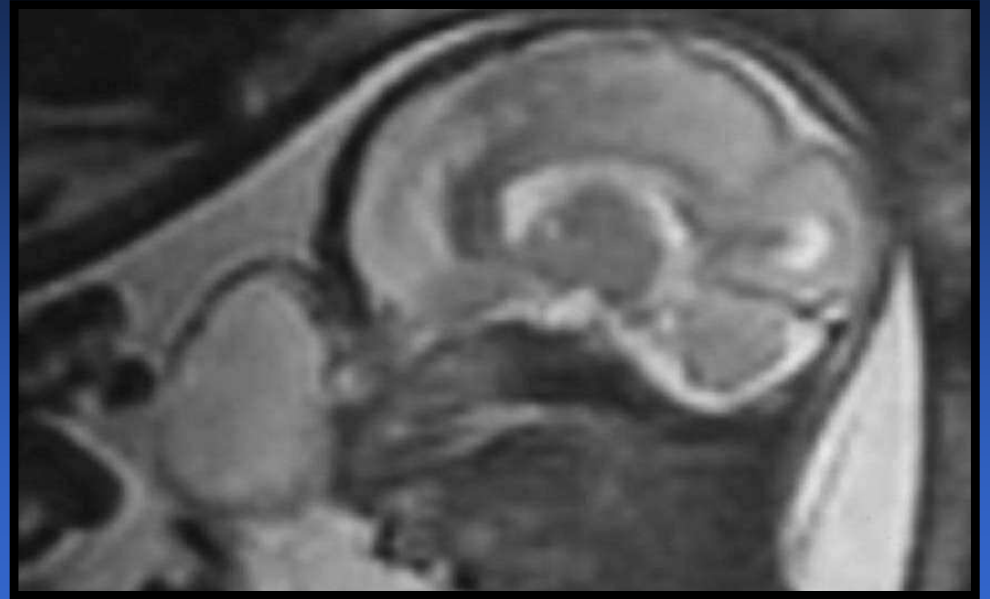
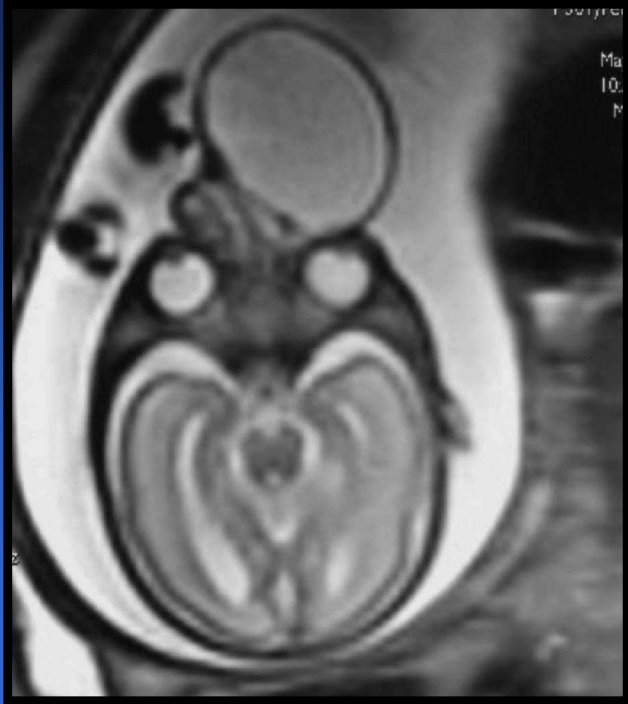


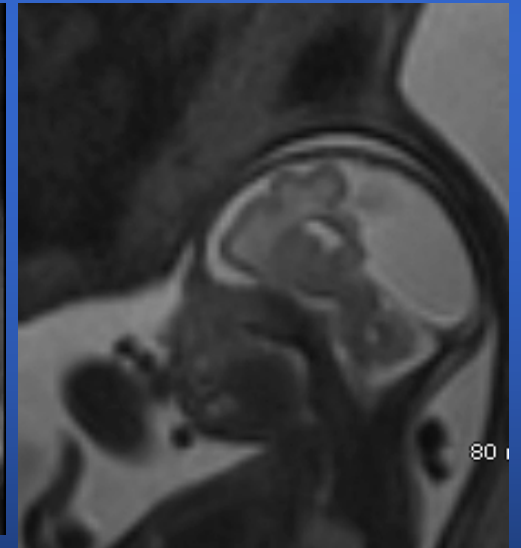
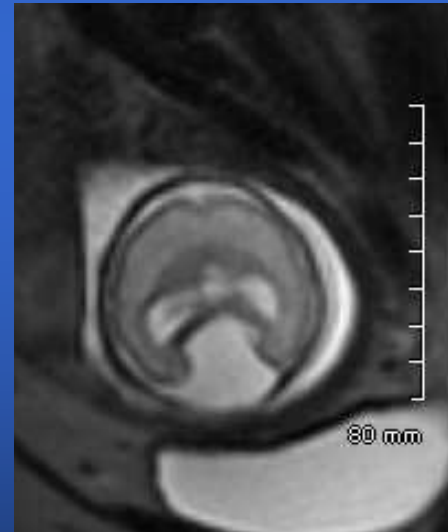
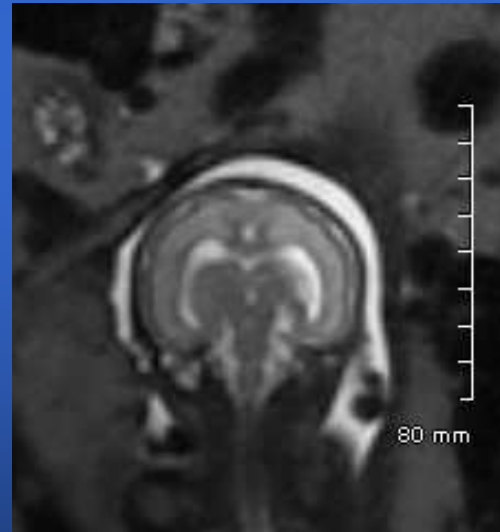
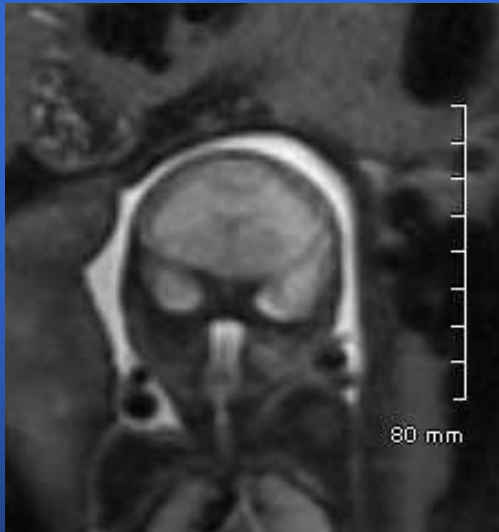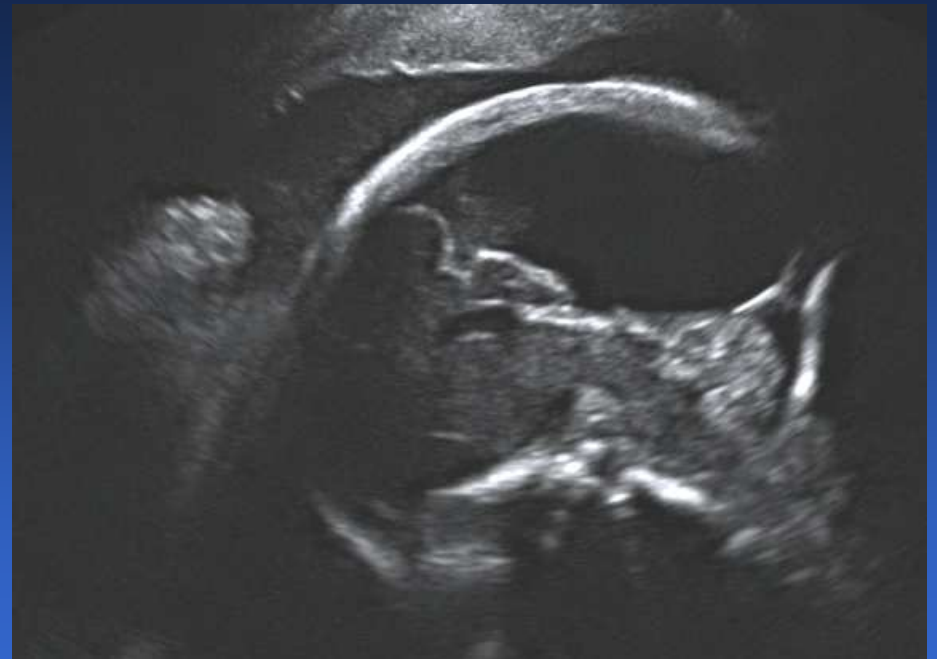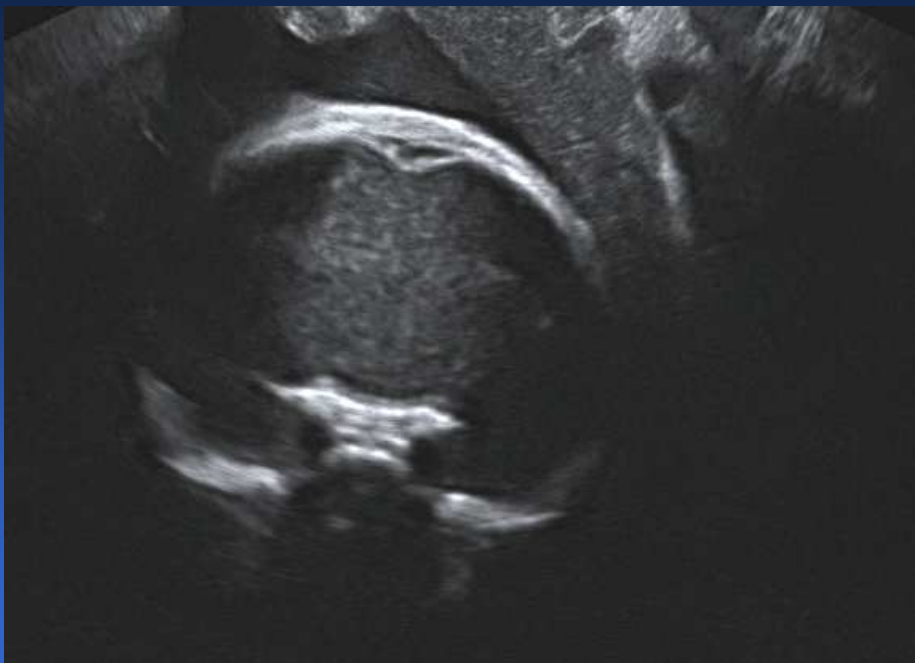MALFORMATIONS



Méningocèle/encéphalocèle ?

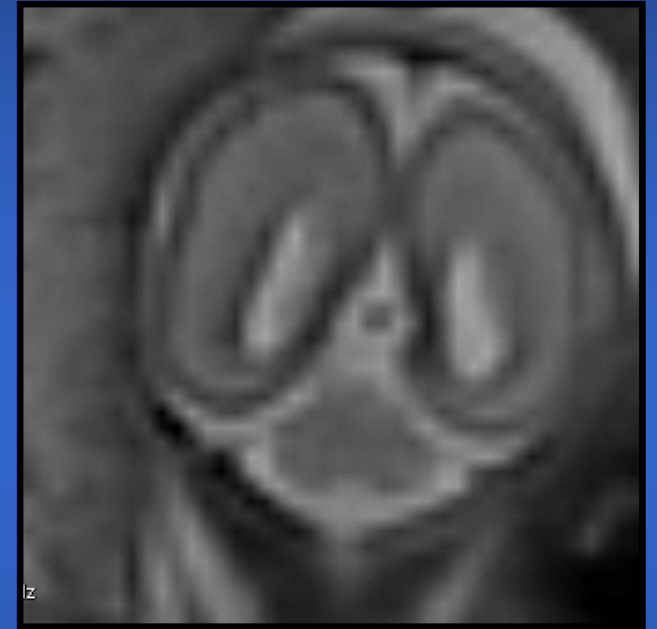
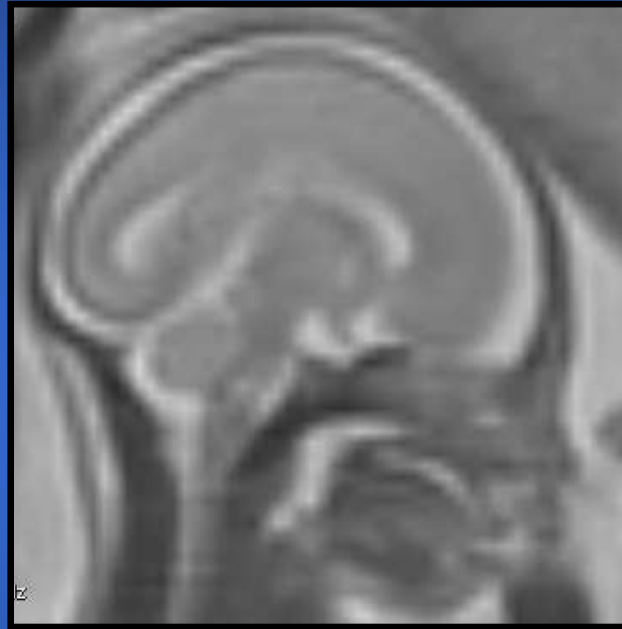
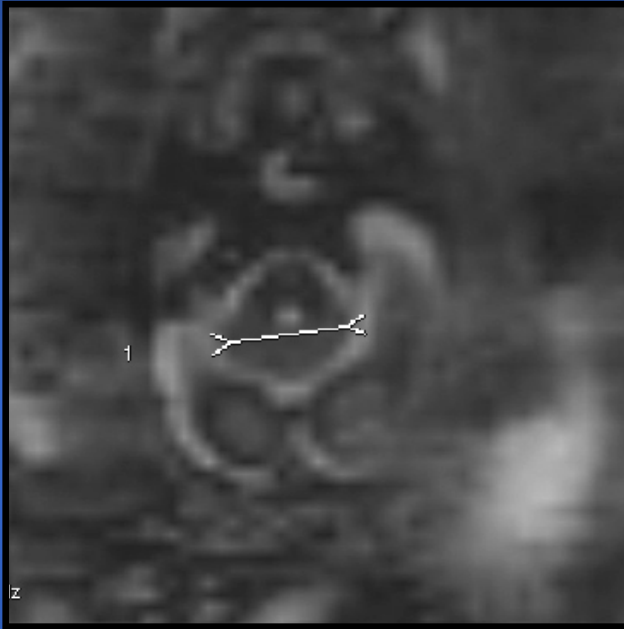



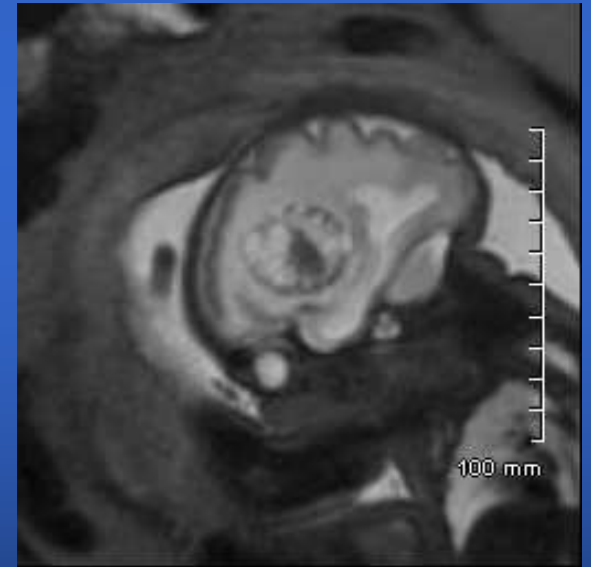
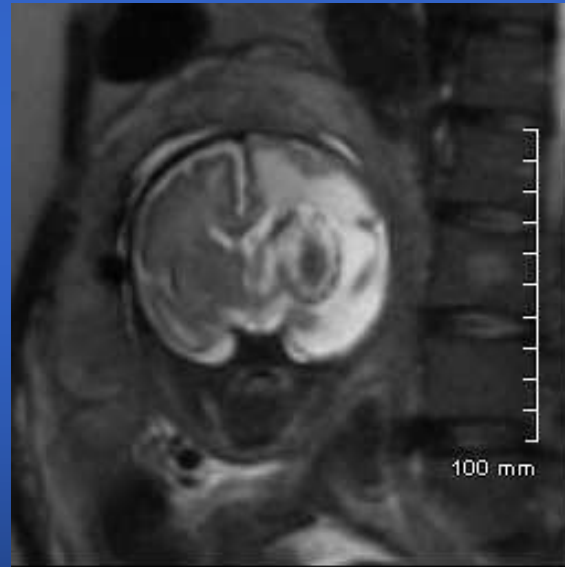
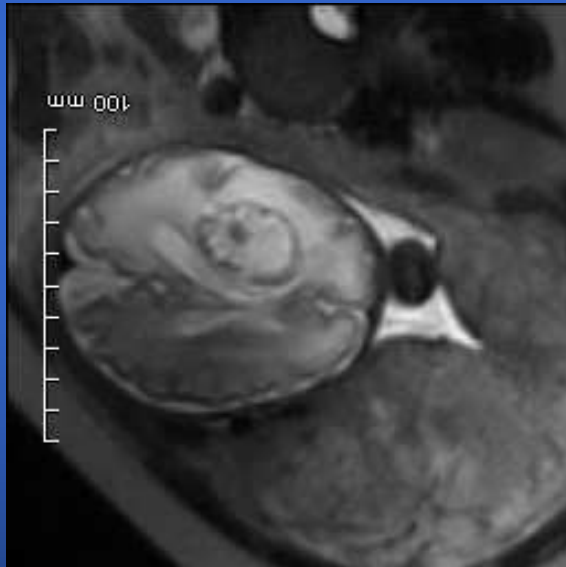
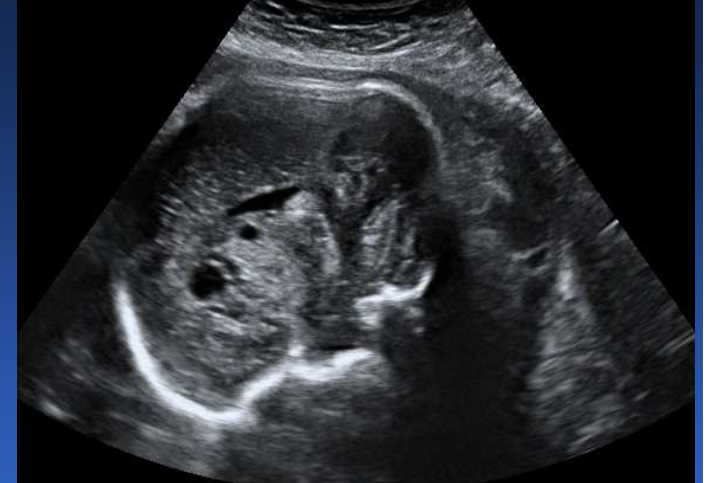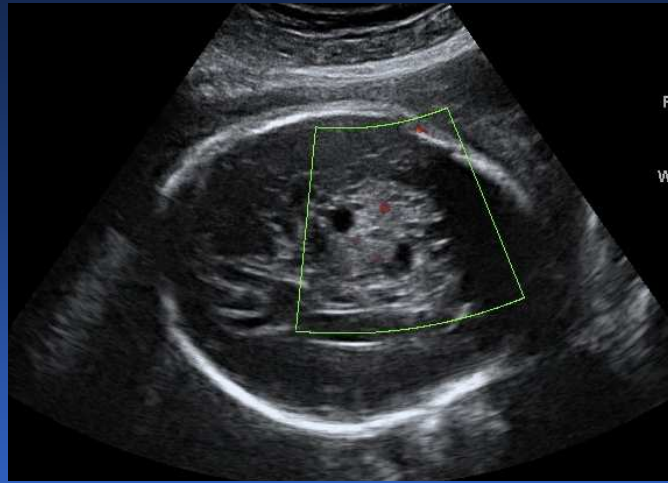


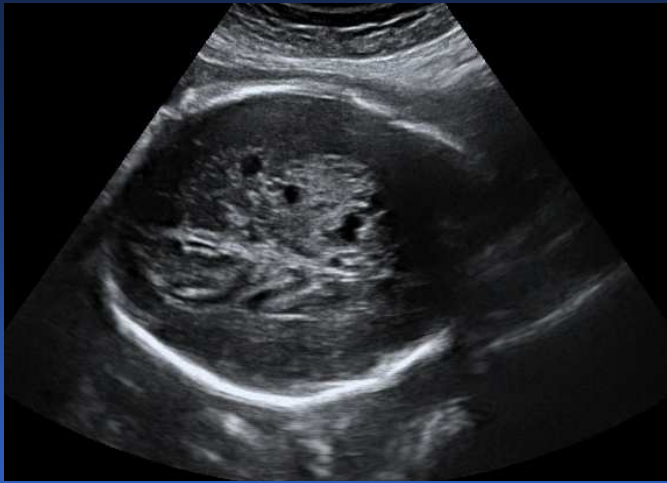holoprosencéphalie

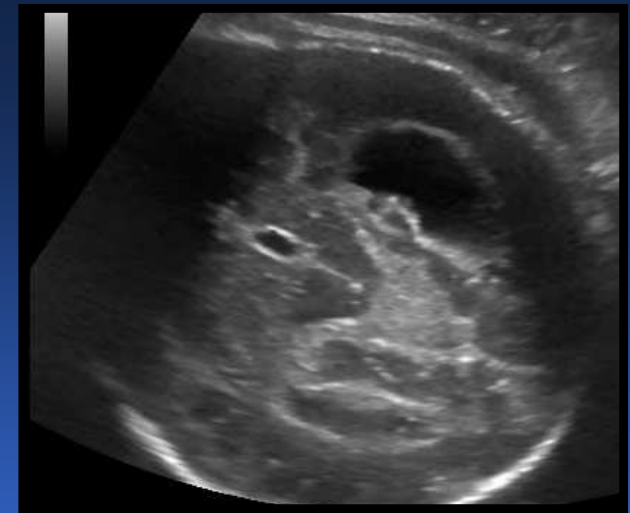
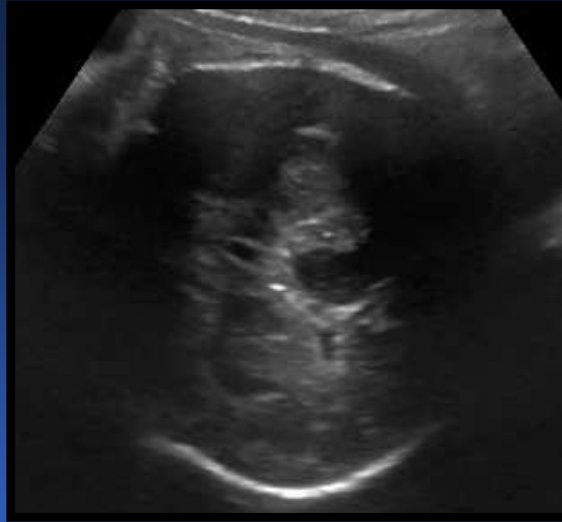
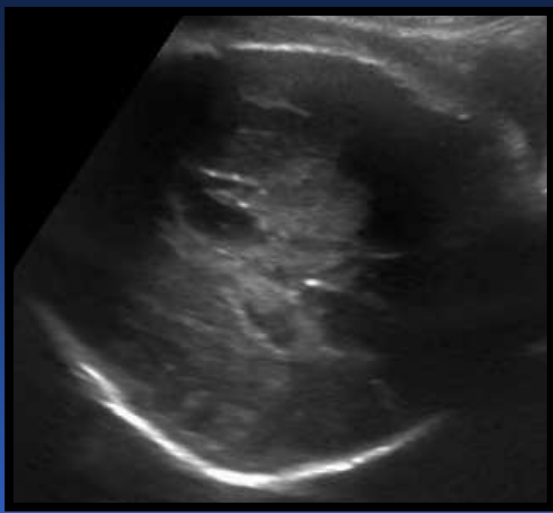
Signes d'appel échographiques



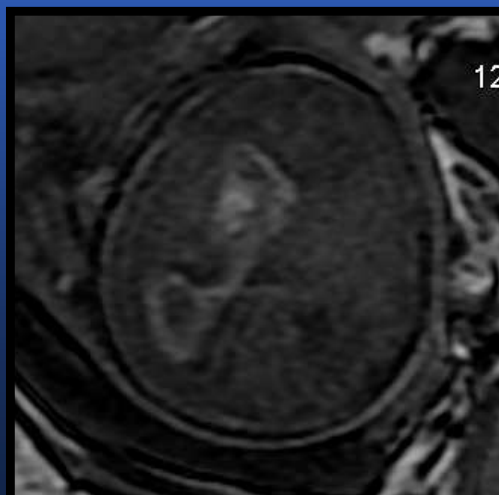
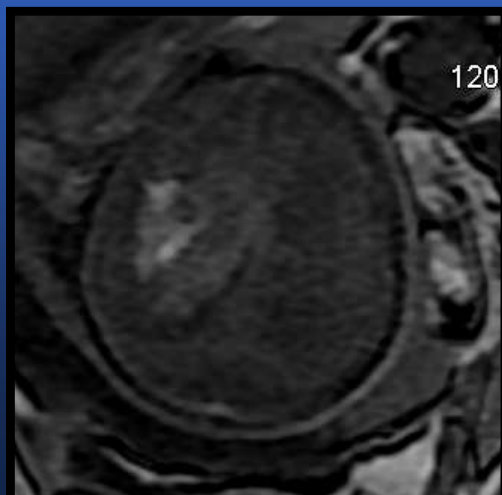
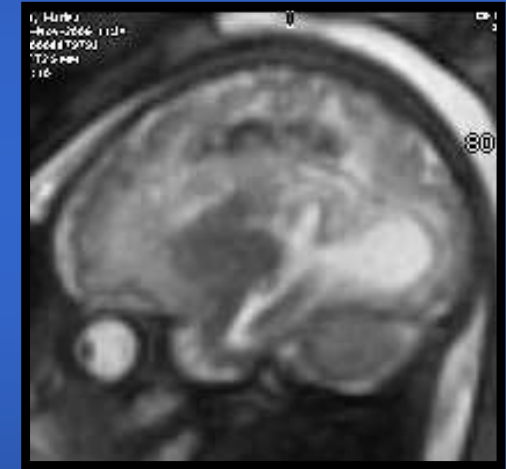
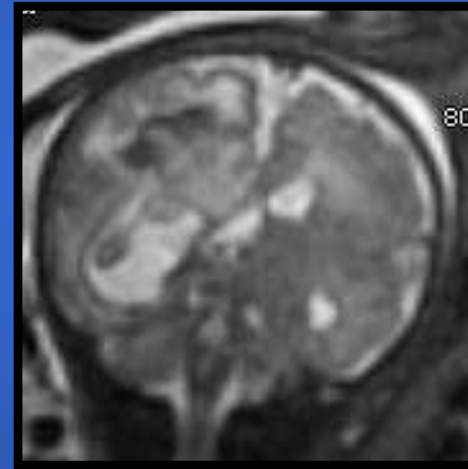
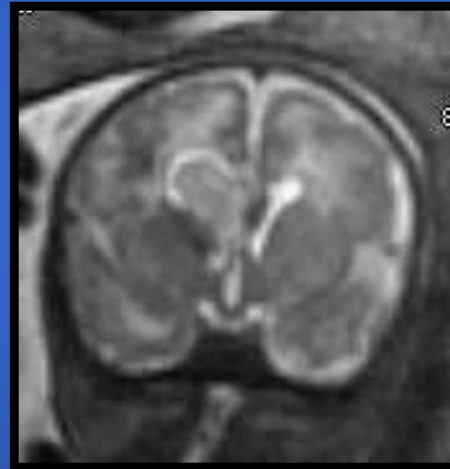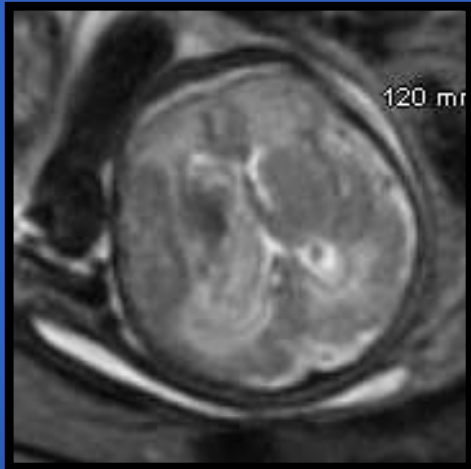
rhombencéphalosynapsis



Tumeur cérébrale

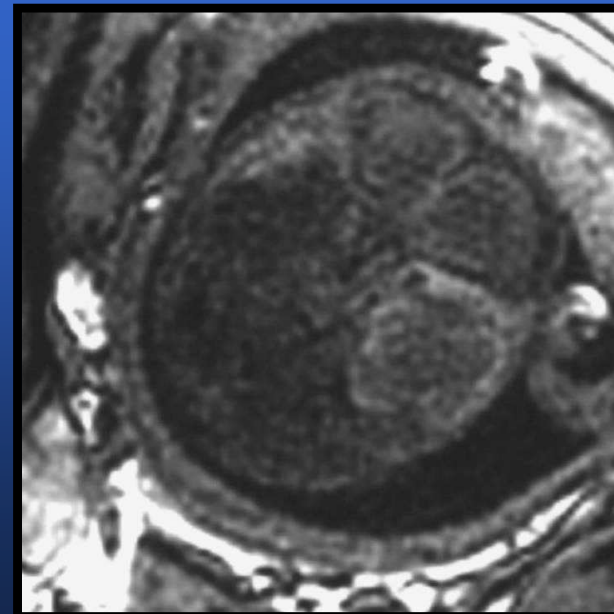
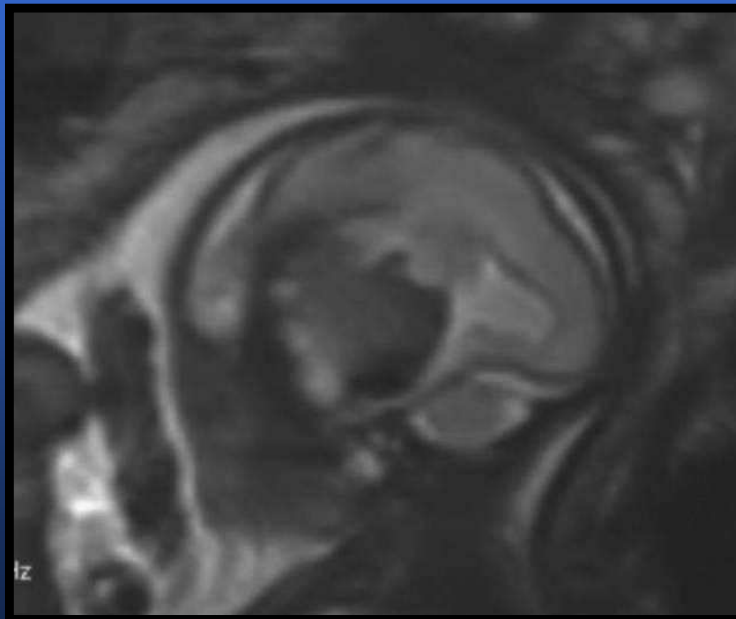
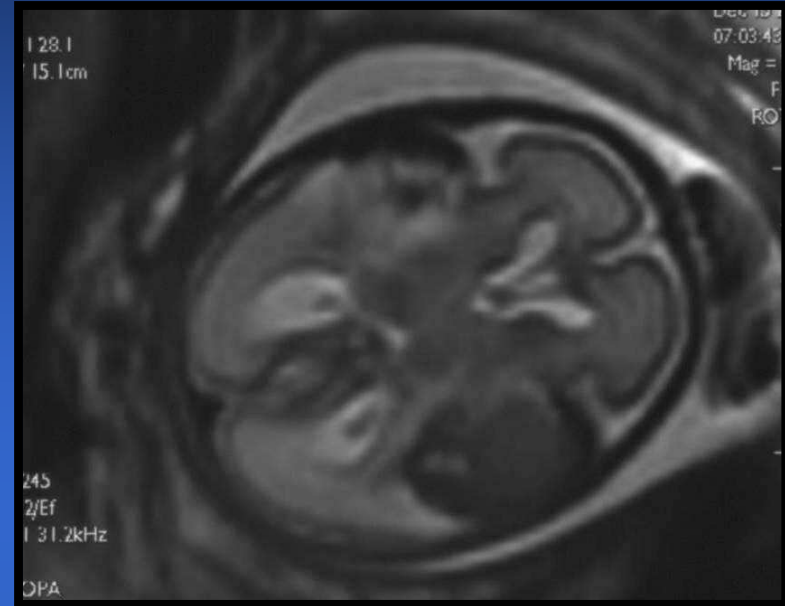
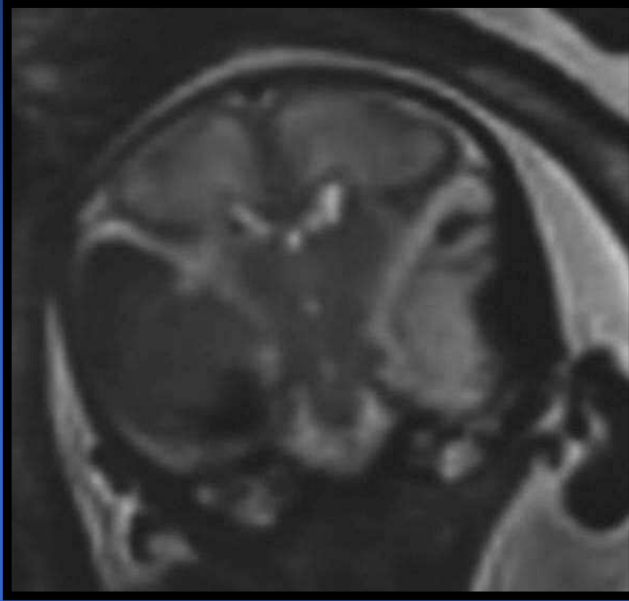


Tumeur ?

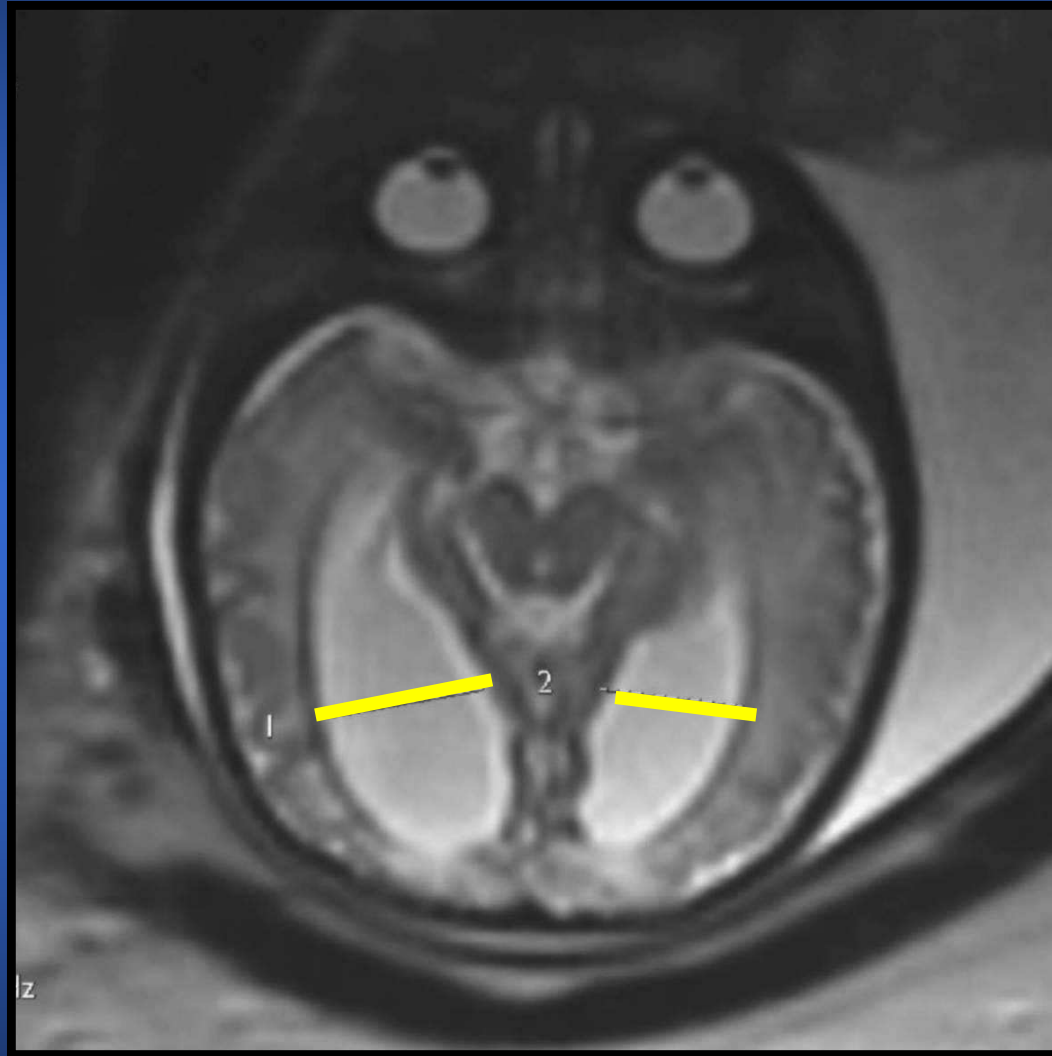


Hémorragie

Anomalies de l'échostructure

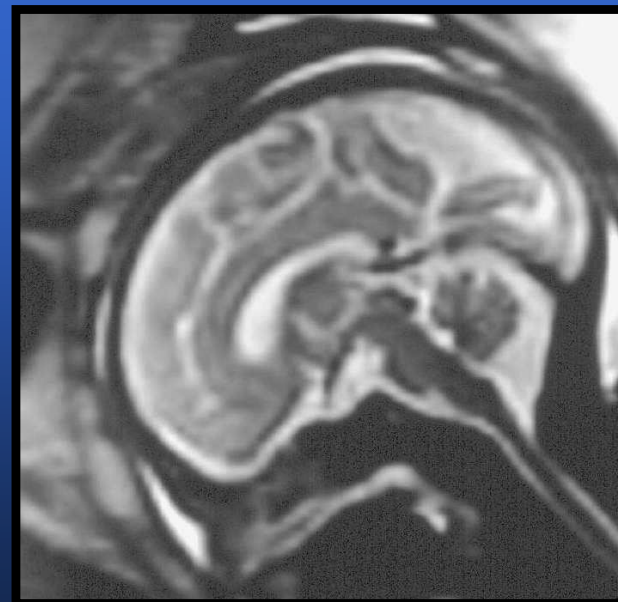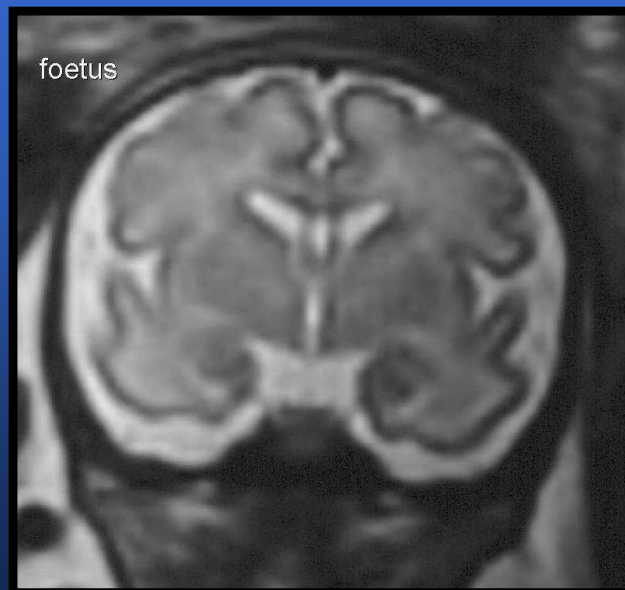
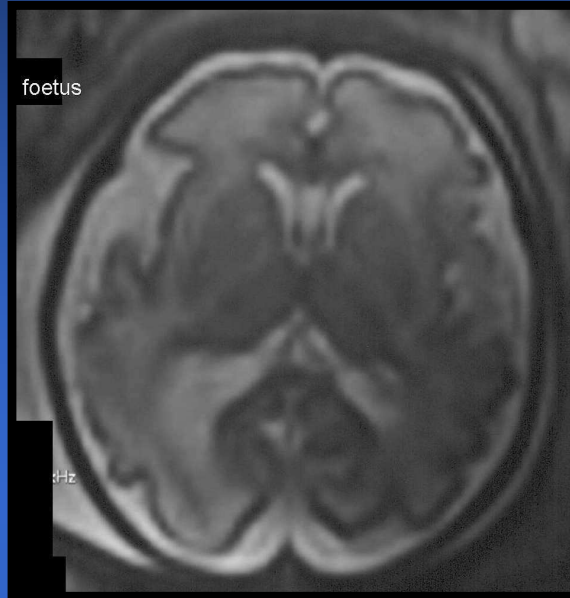


DILATATION VENTRICULAIRE

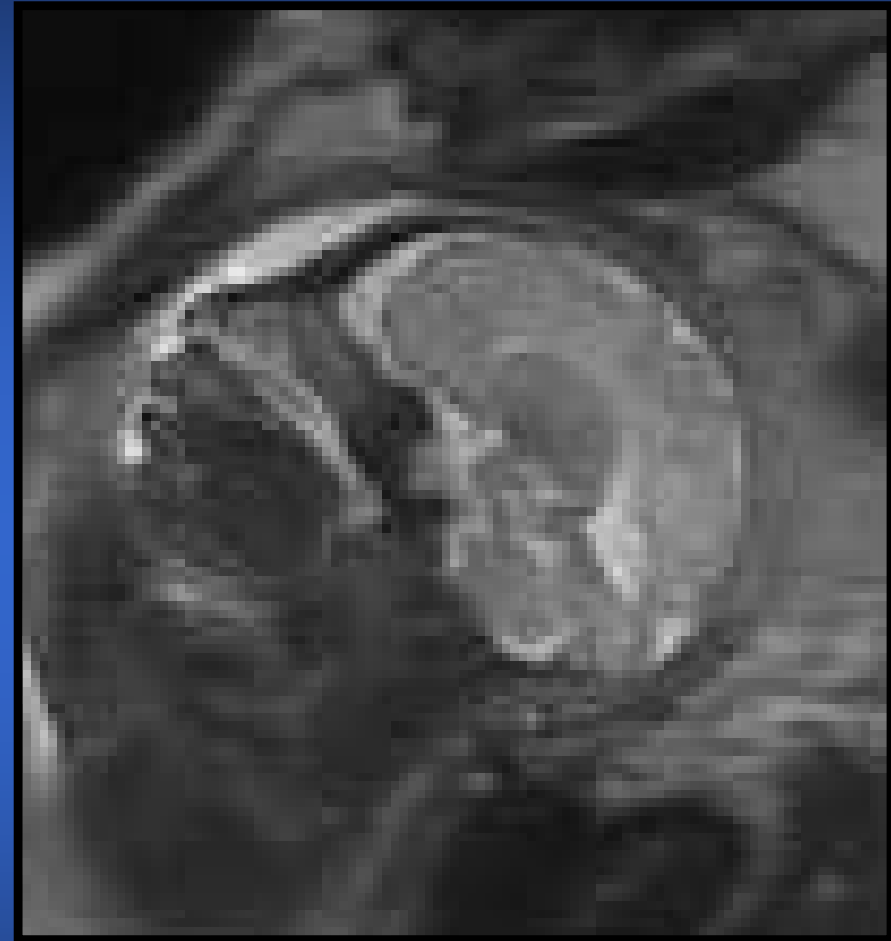
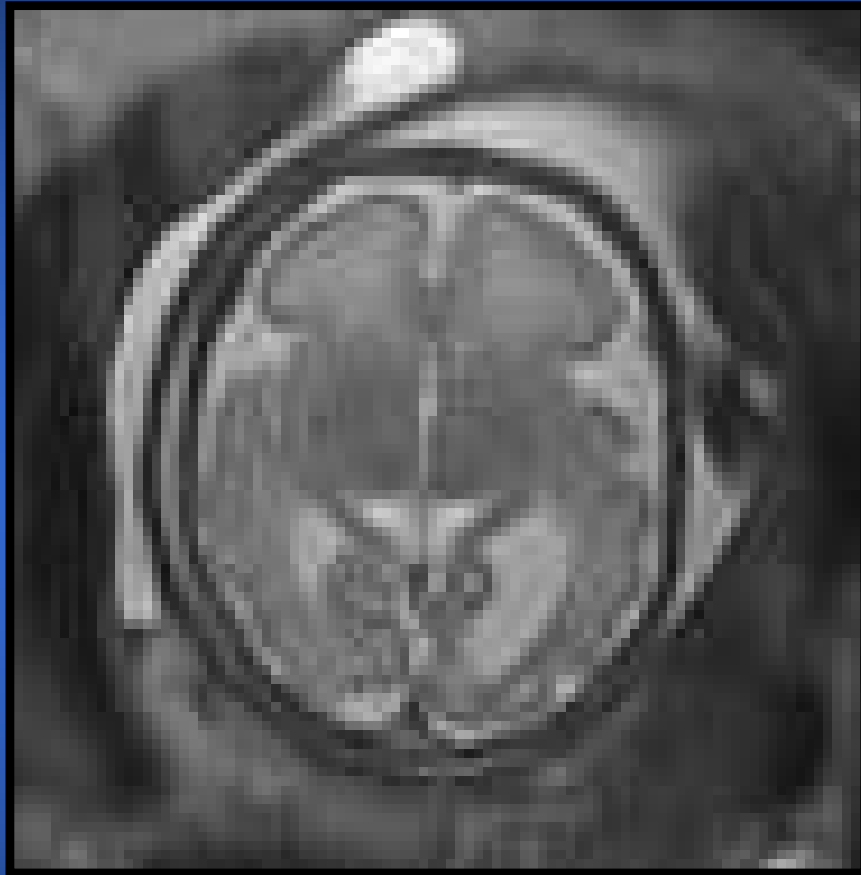


Mesure des carrefours ventriculaires

DILATATION VENTRICULAIRE

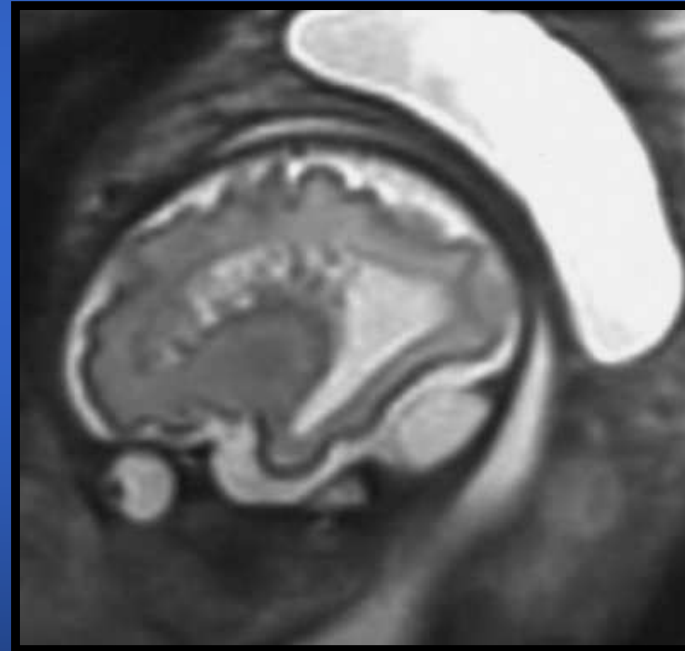
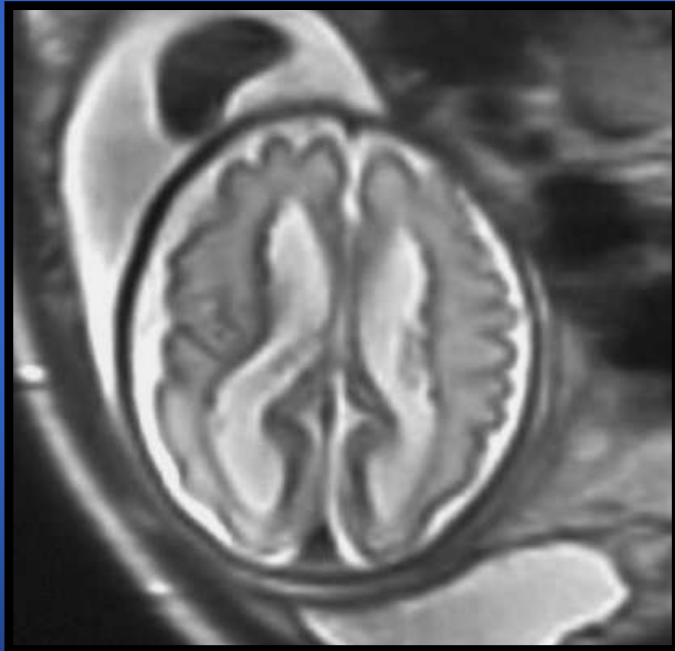


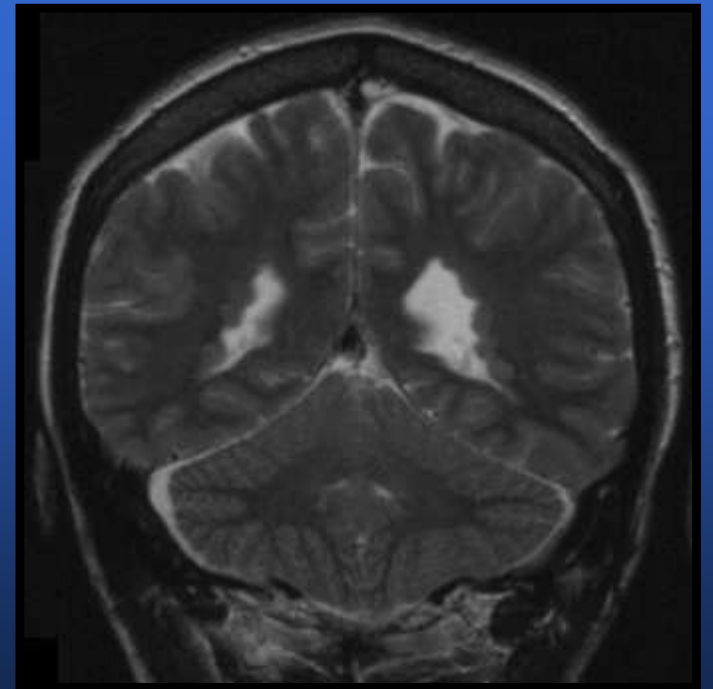
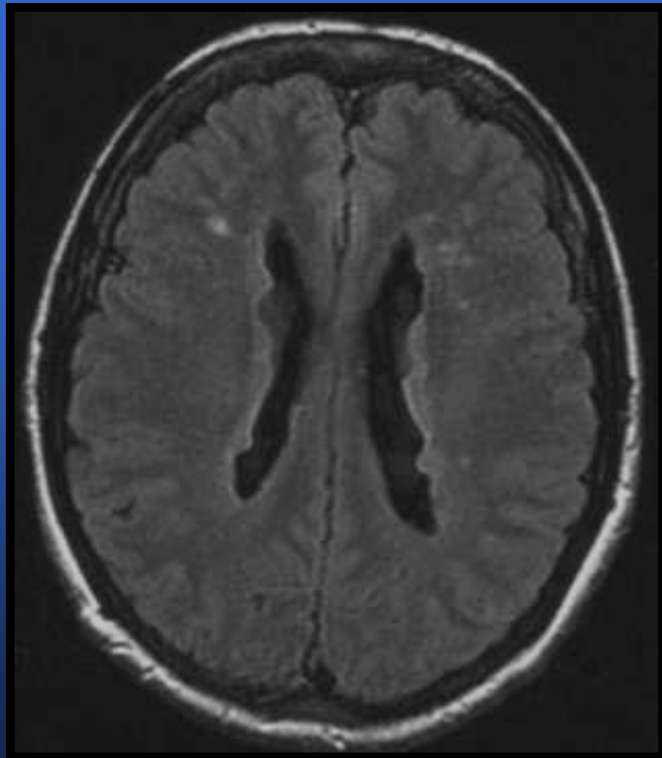
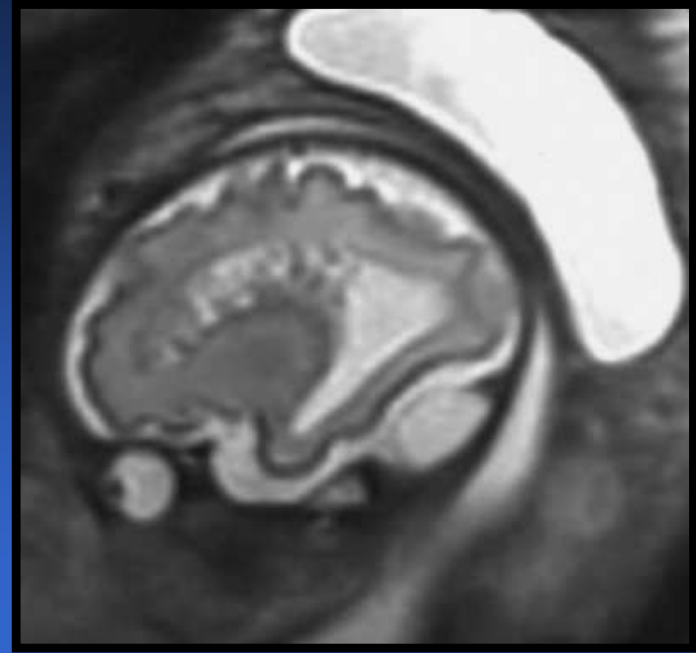
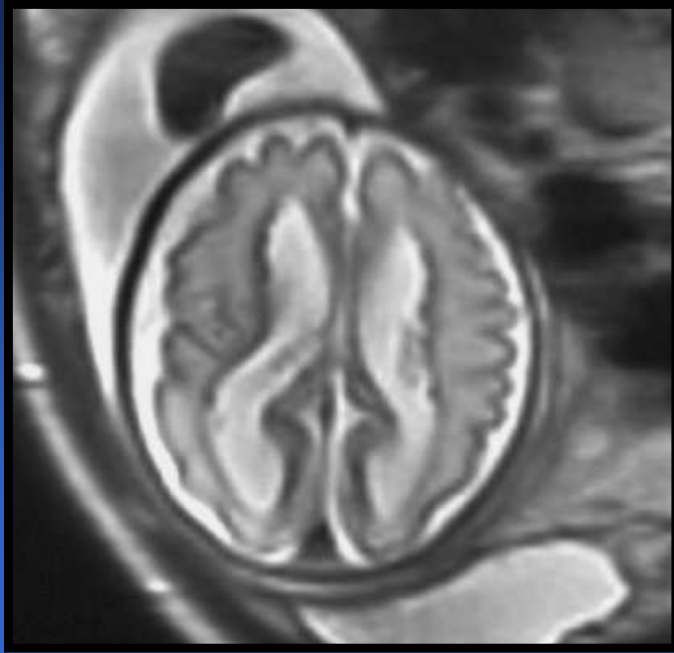
DILATATION VENTRICULAIRE



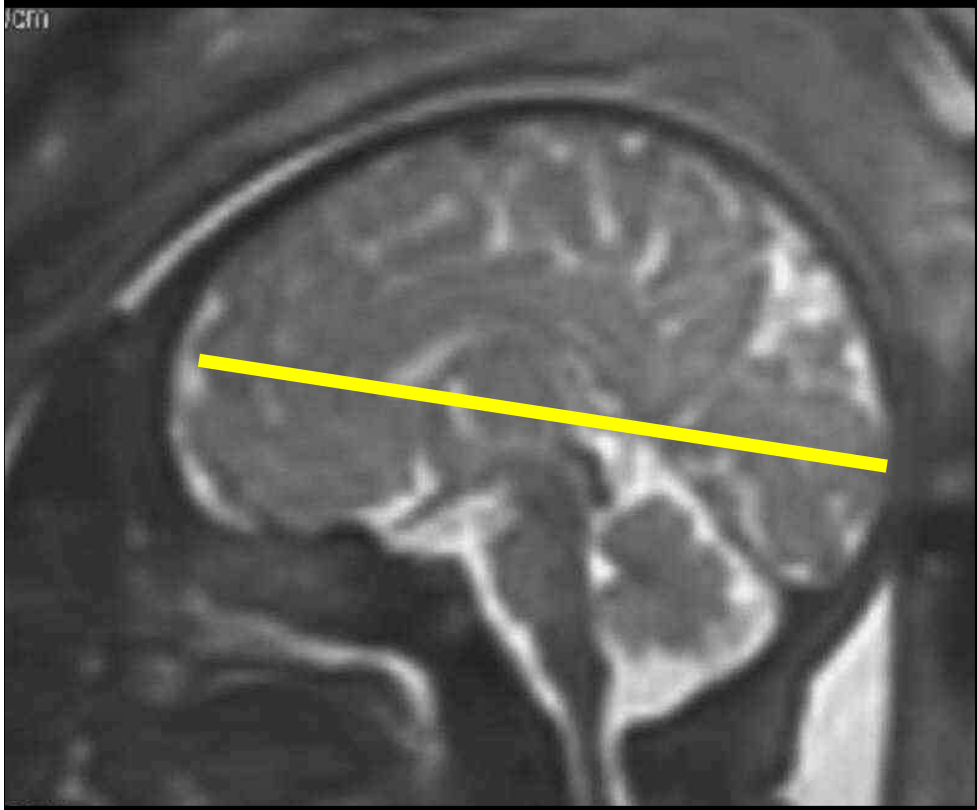
- 35 SA : PACHYGYRIE

DILATATION VENTRICULAIRE

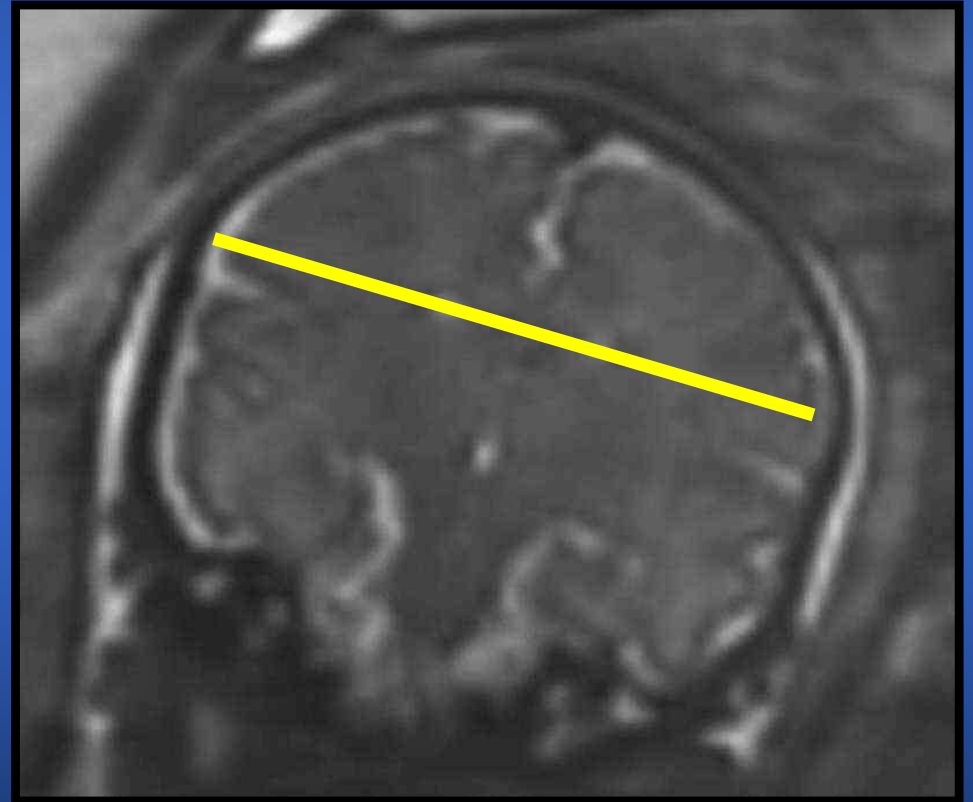




MICROCEPHALIE

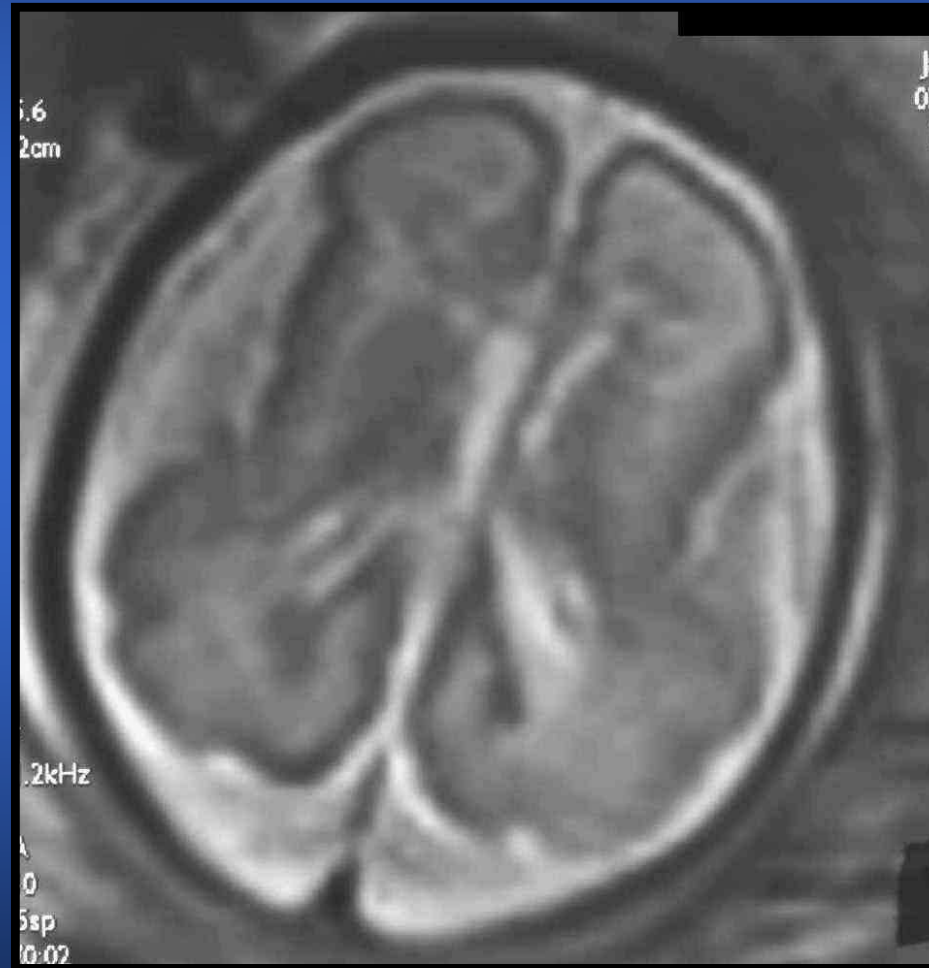


Diamètre antéro-postérieur



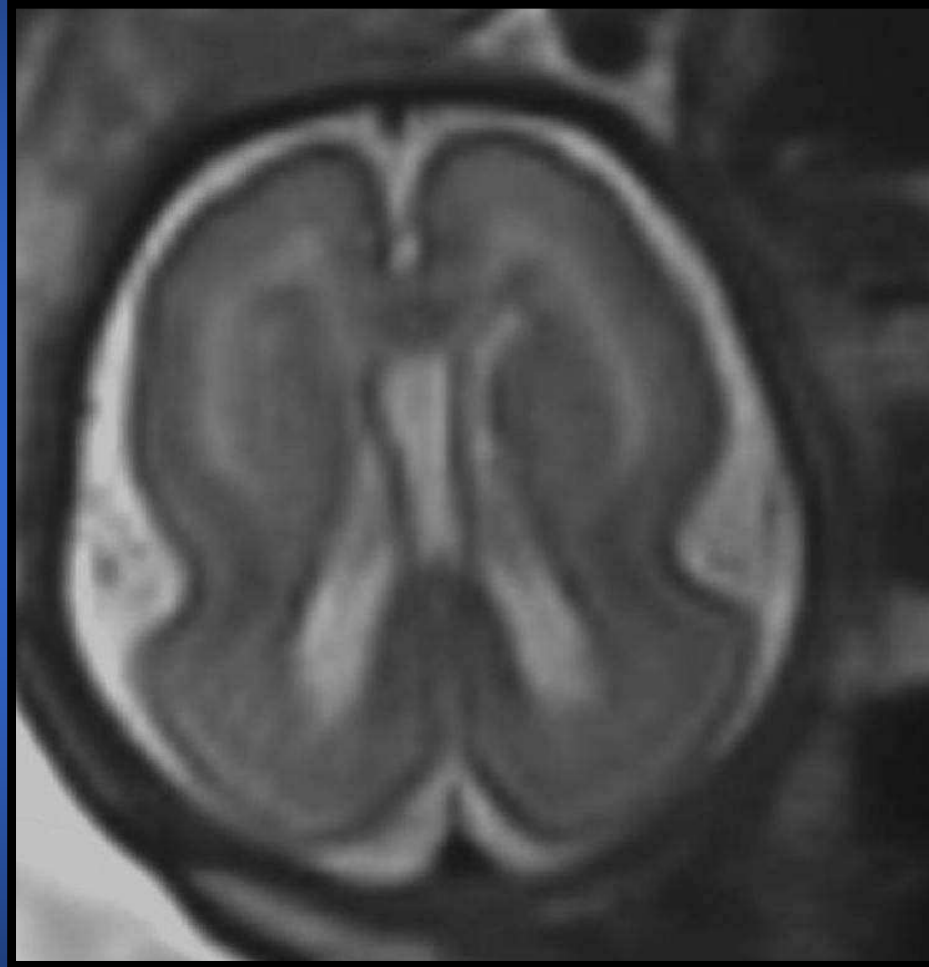
Diamètre bipariétal cérébral

MICROCEPHALIE

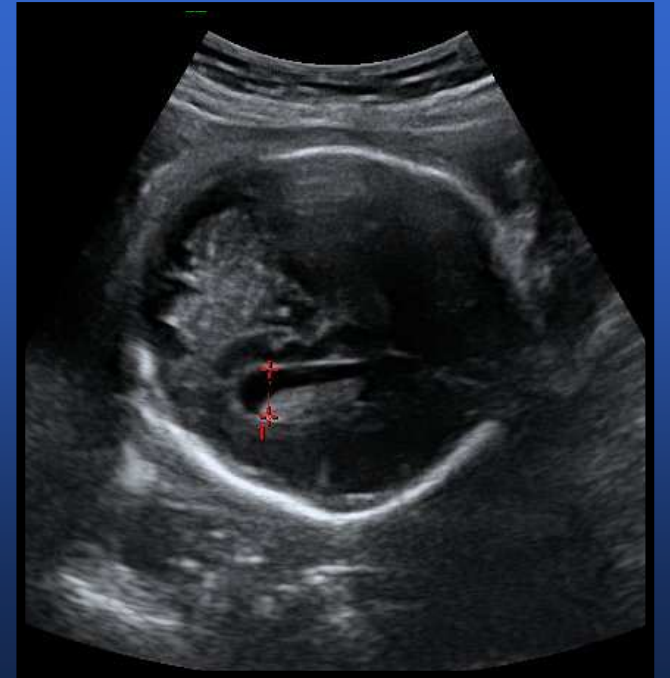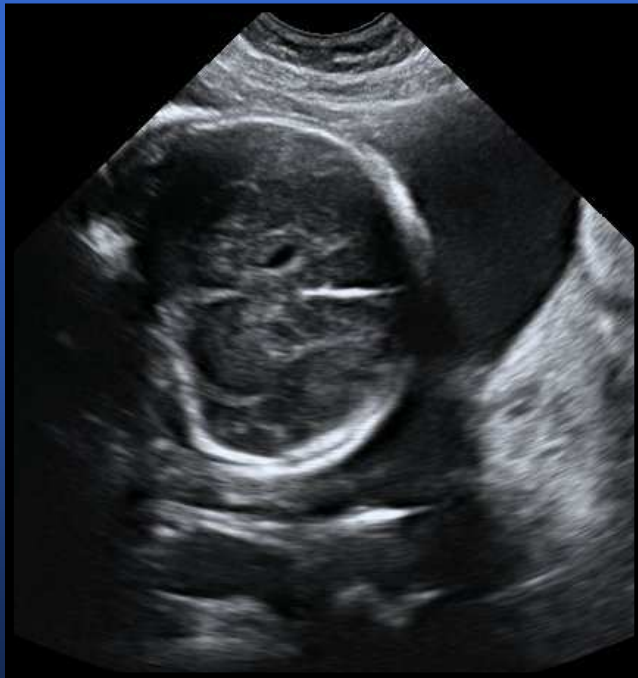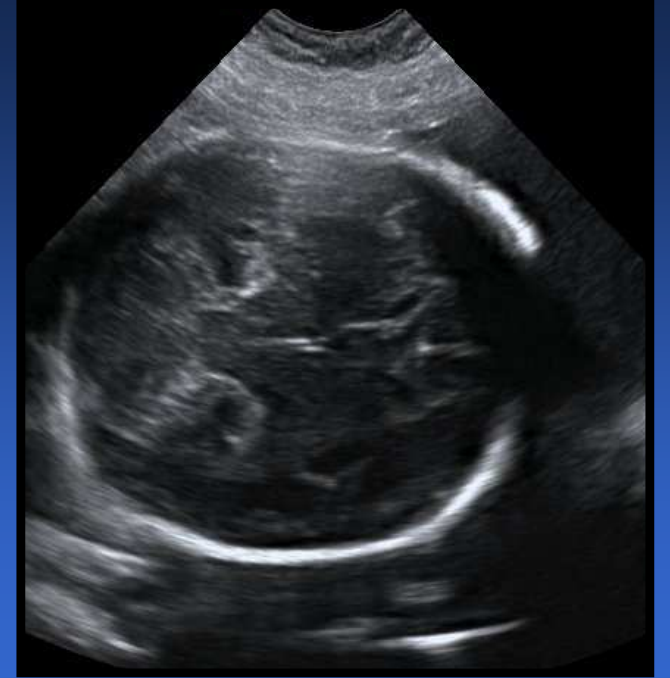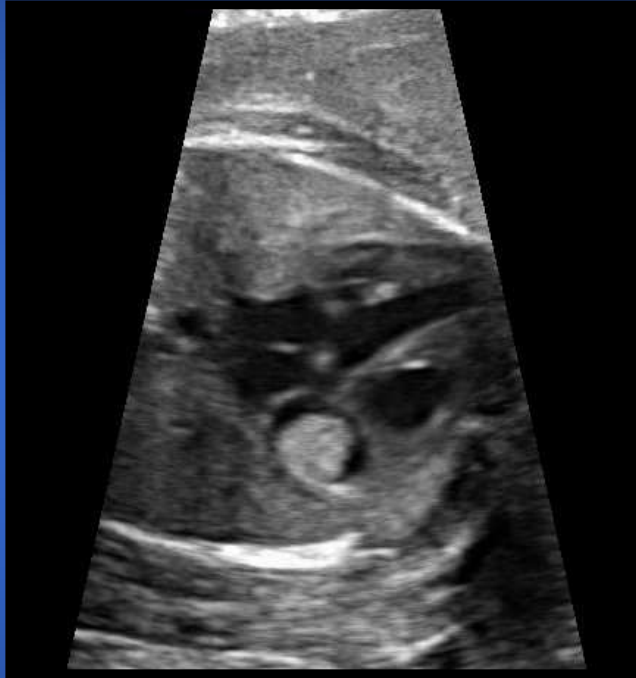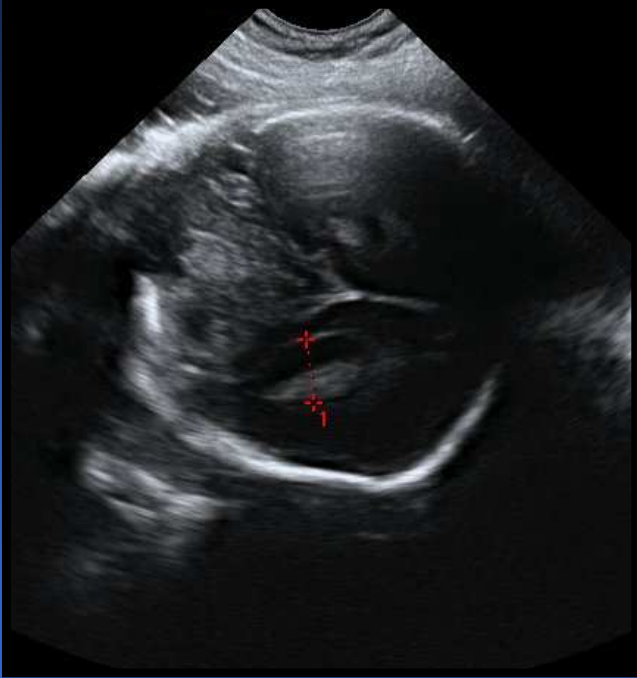


Pachygyrie 35 sa

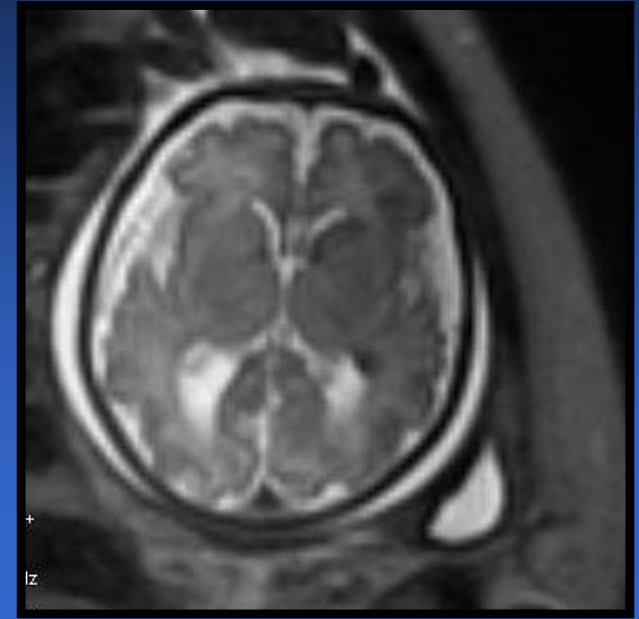
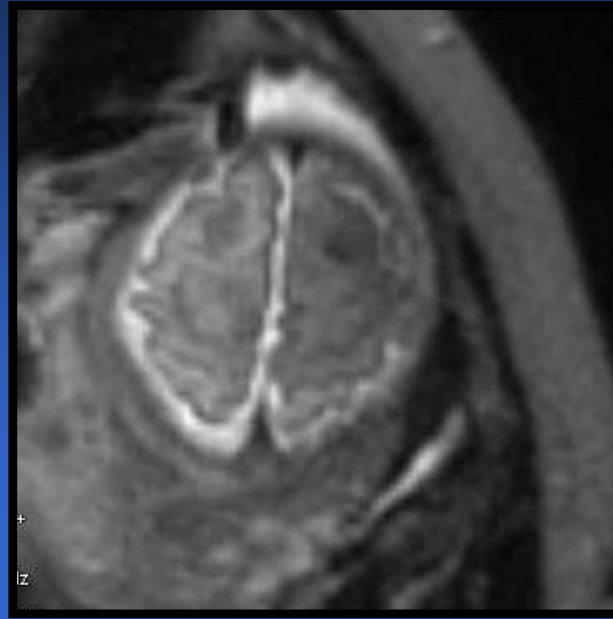
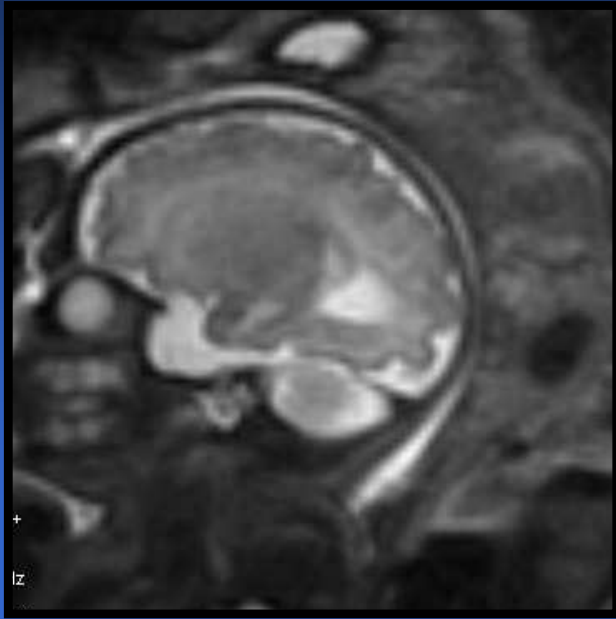
MICROCEPHALIE



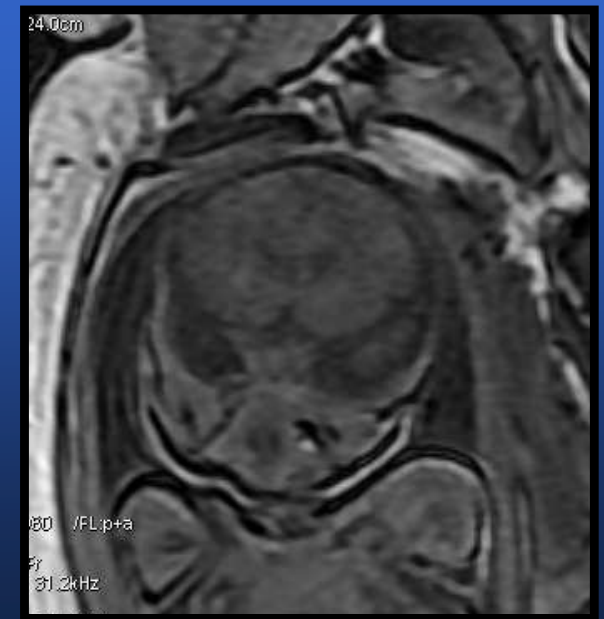
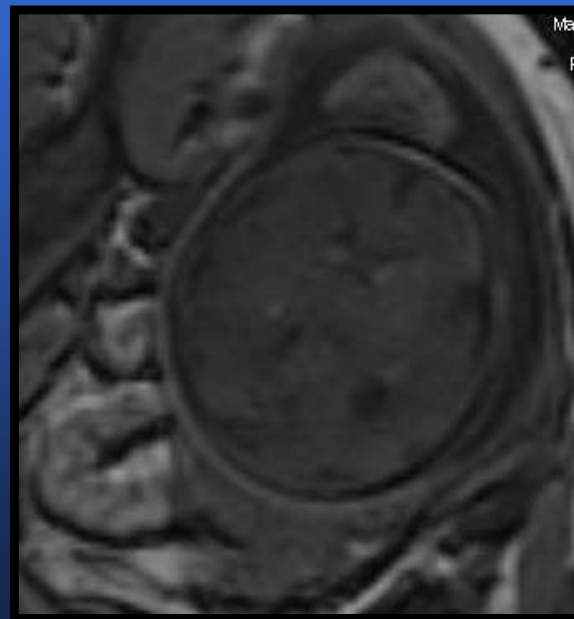
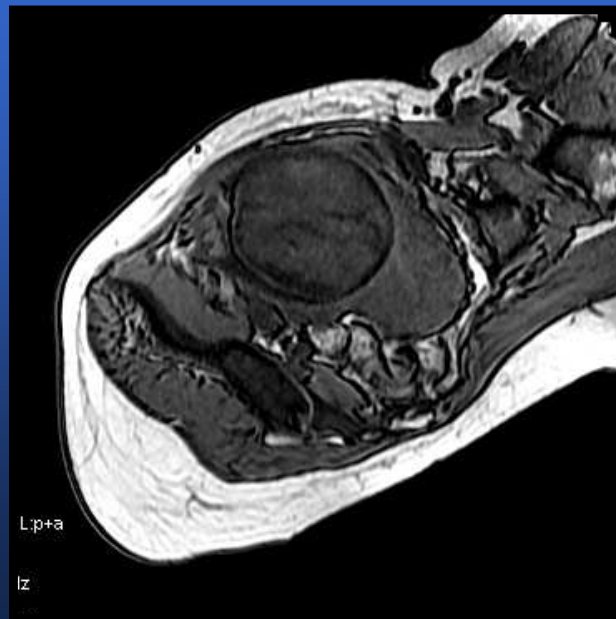lissencéphalie



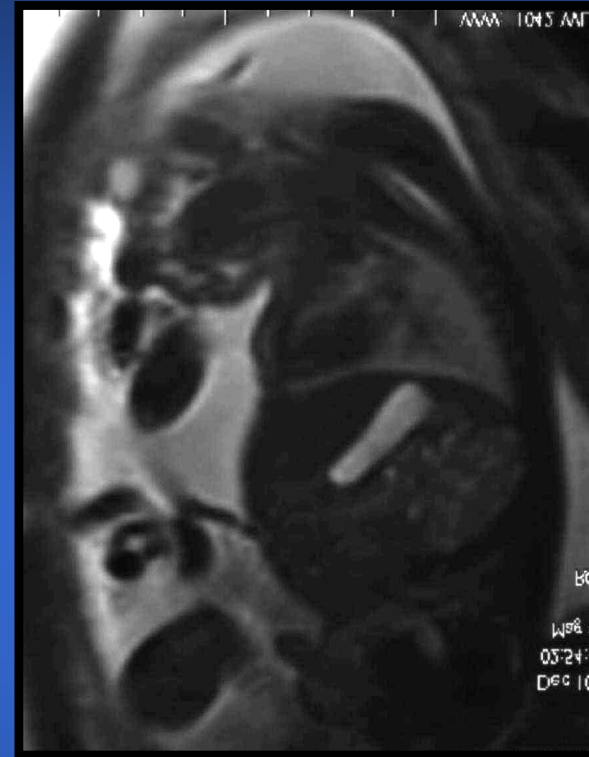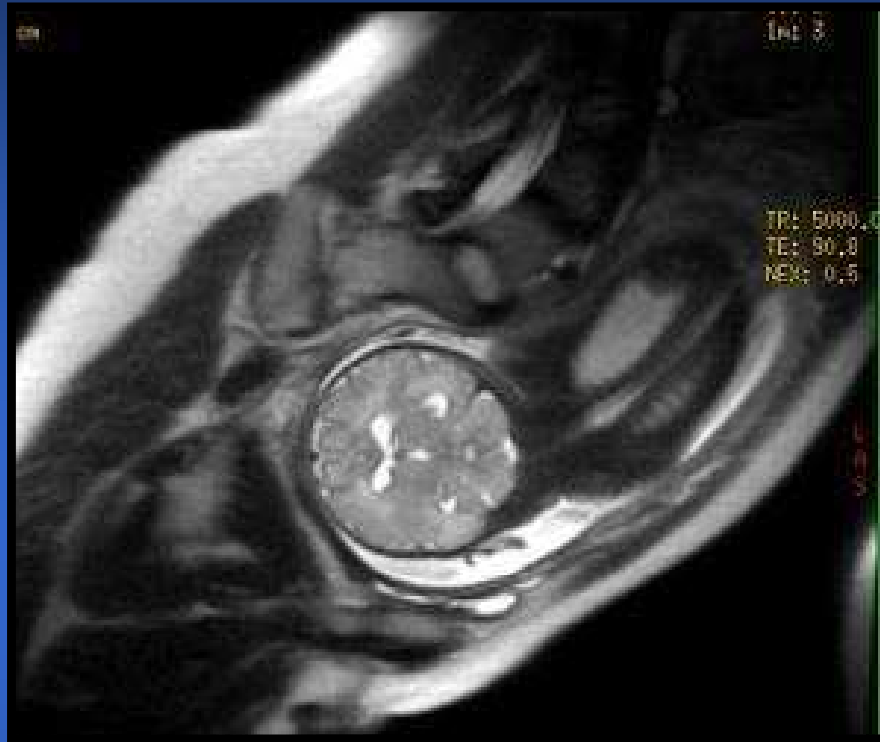Anomalie non visible à l'échographie



Sclérose Tubéreuse de Bourneville

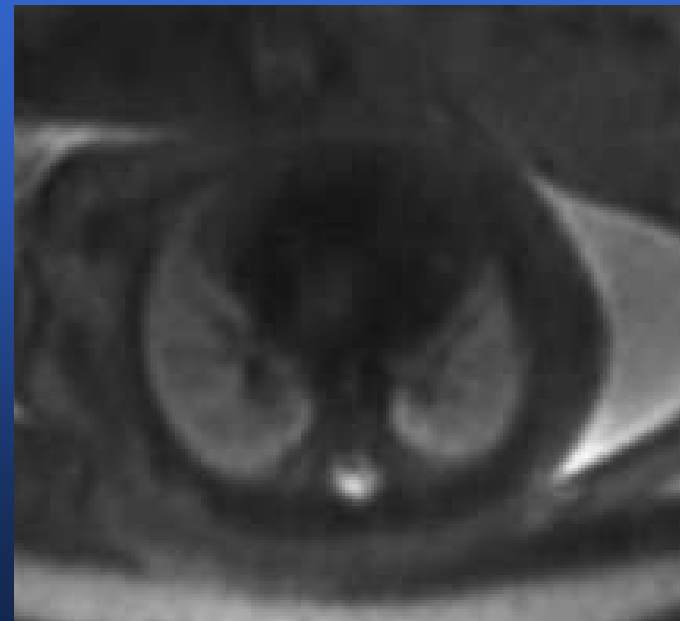
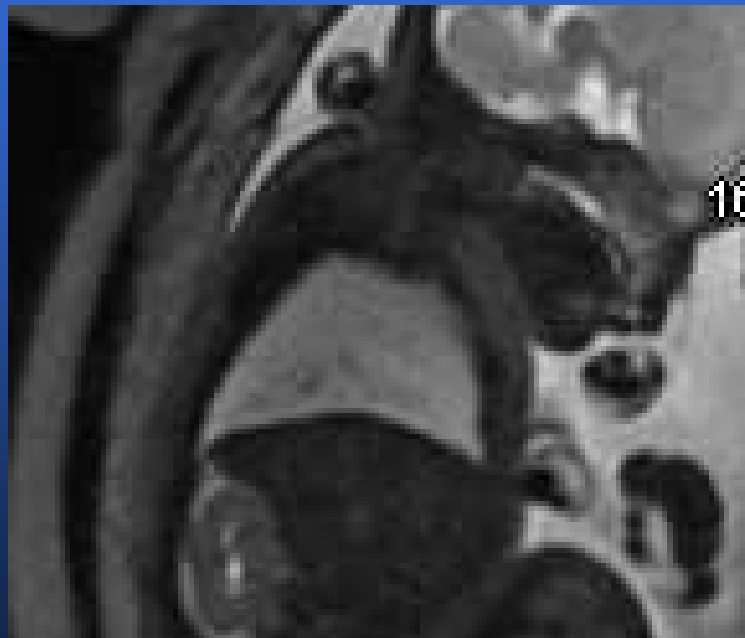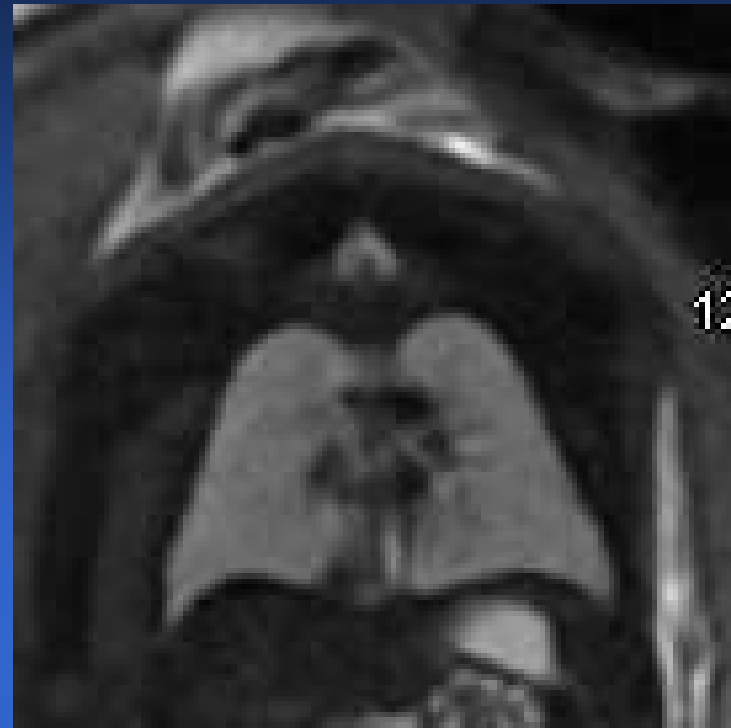

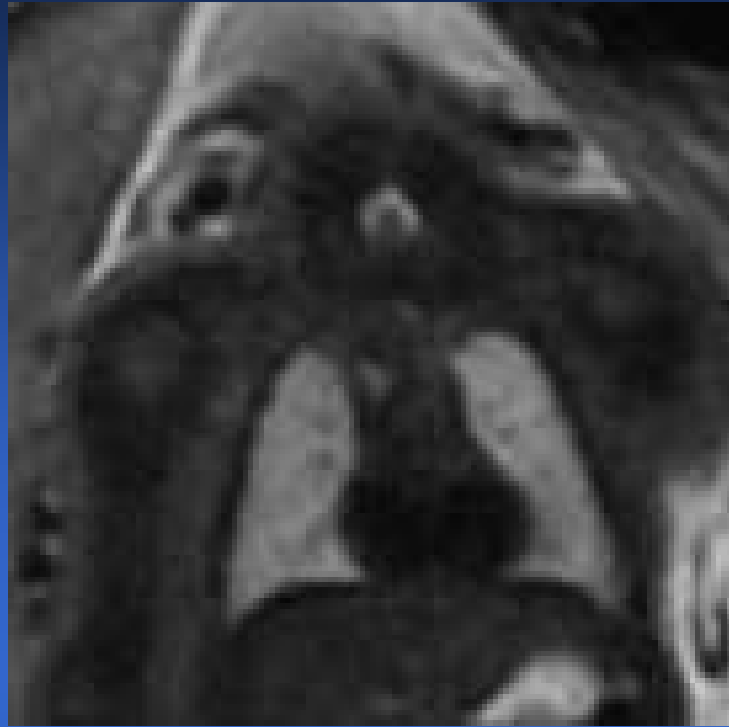
IRM fœtale : autre organe

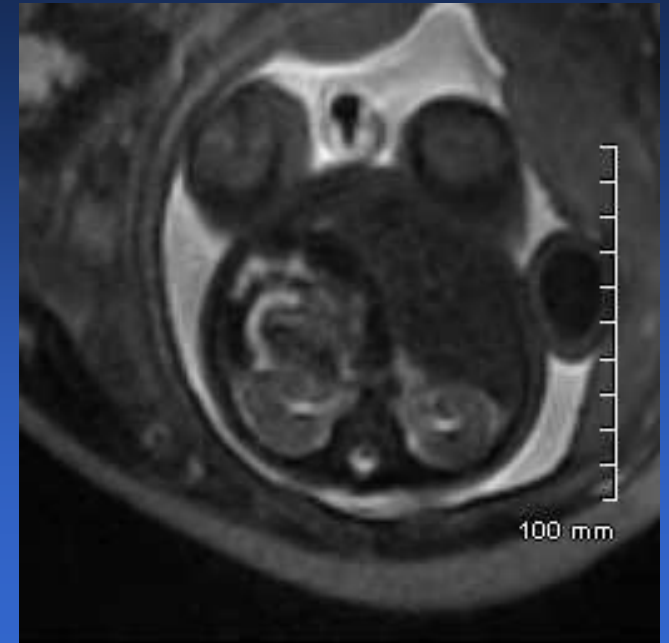
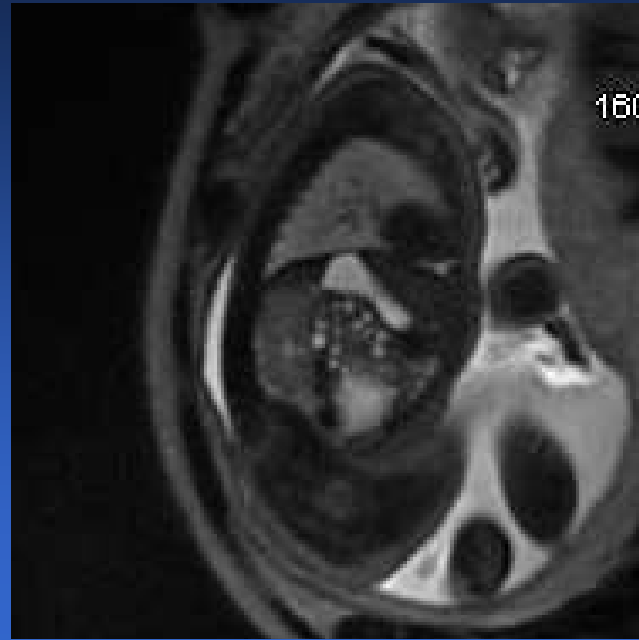
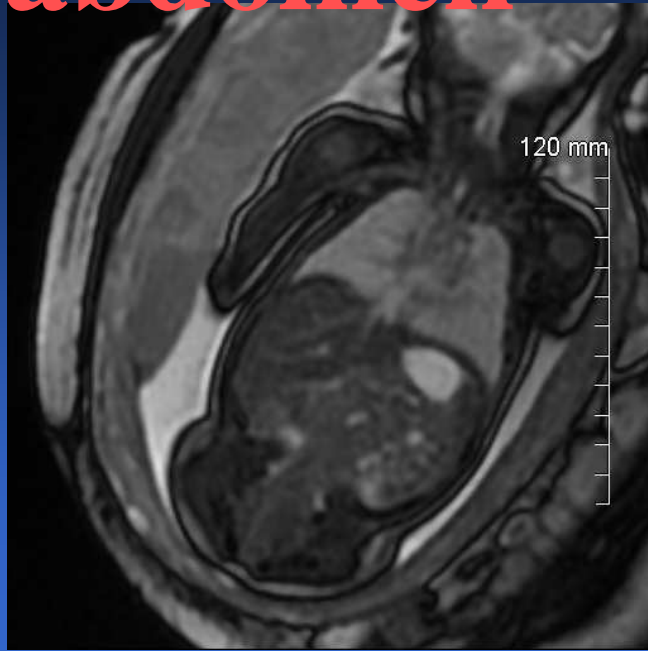


- Repérage ,
- T2 SSFSE pour obtention d'un plan anatomique
- Séquence T2 SSFSE 3 plans
- Séquence EG T1 apnée 3 plans: ABDOMEN

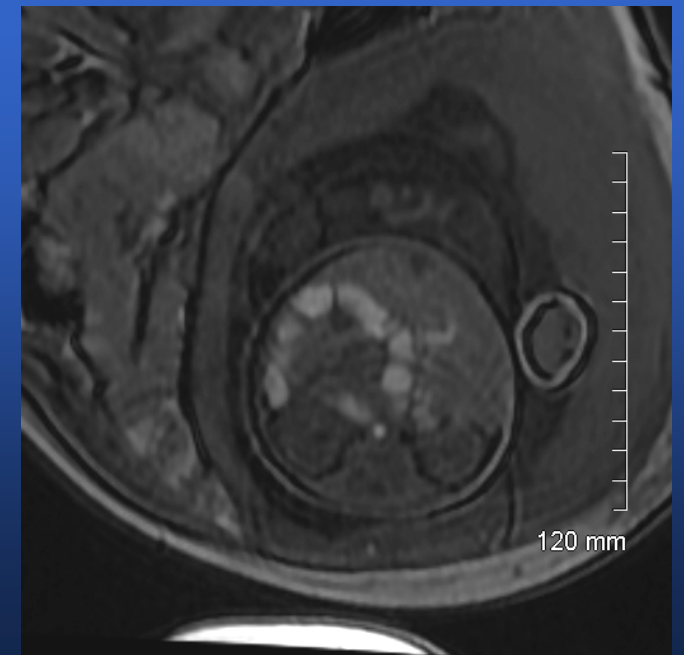
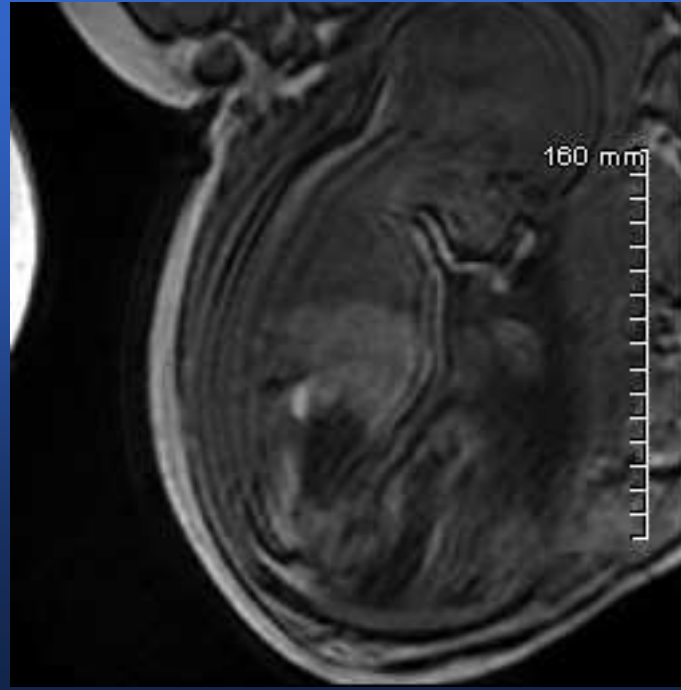
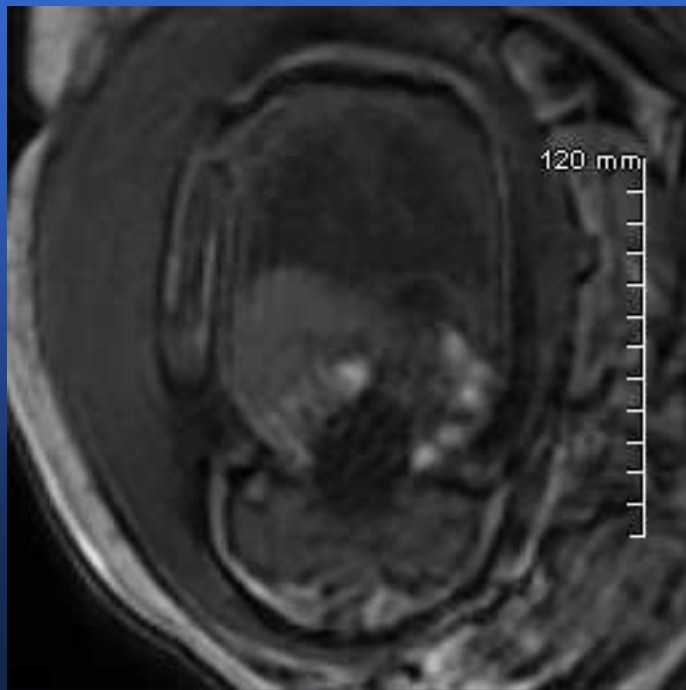
thorax



abdomen

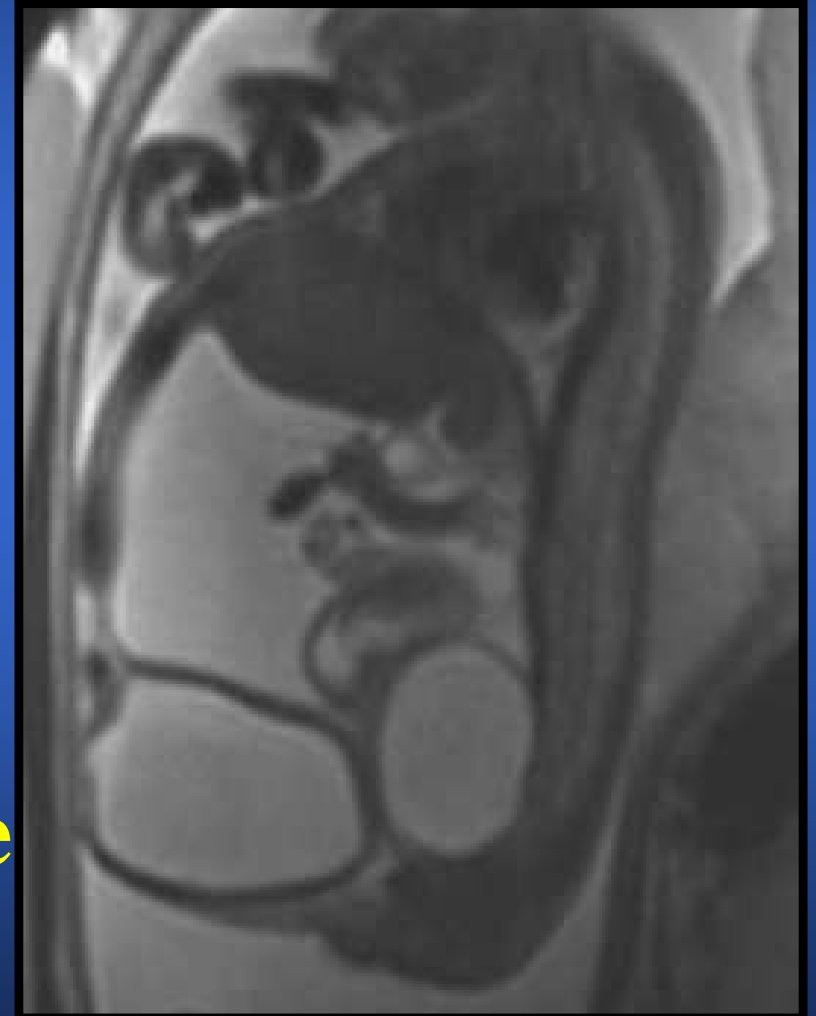

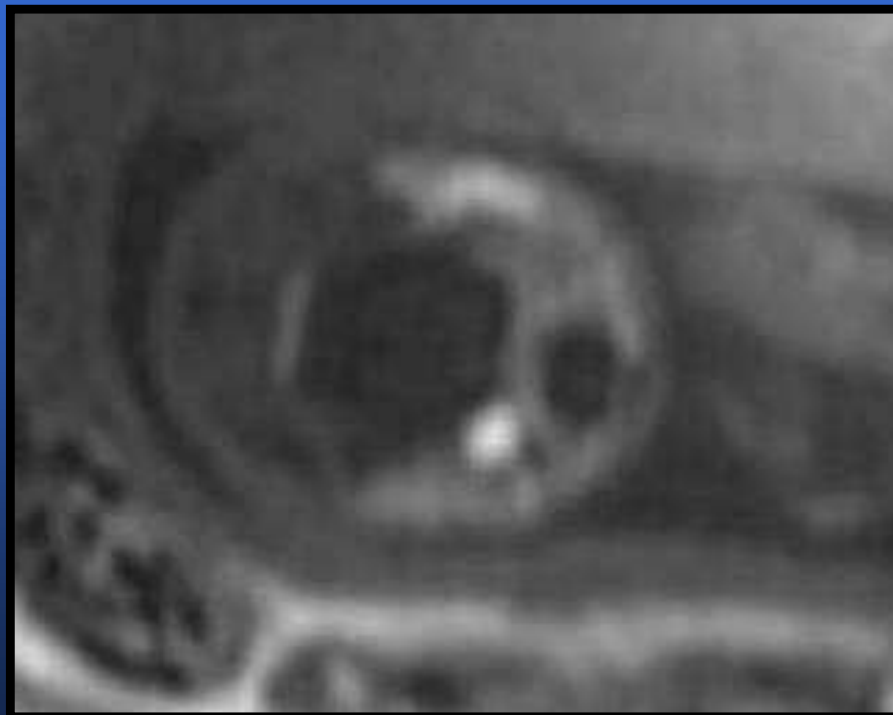
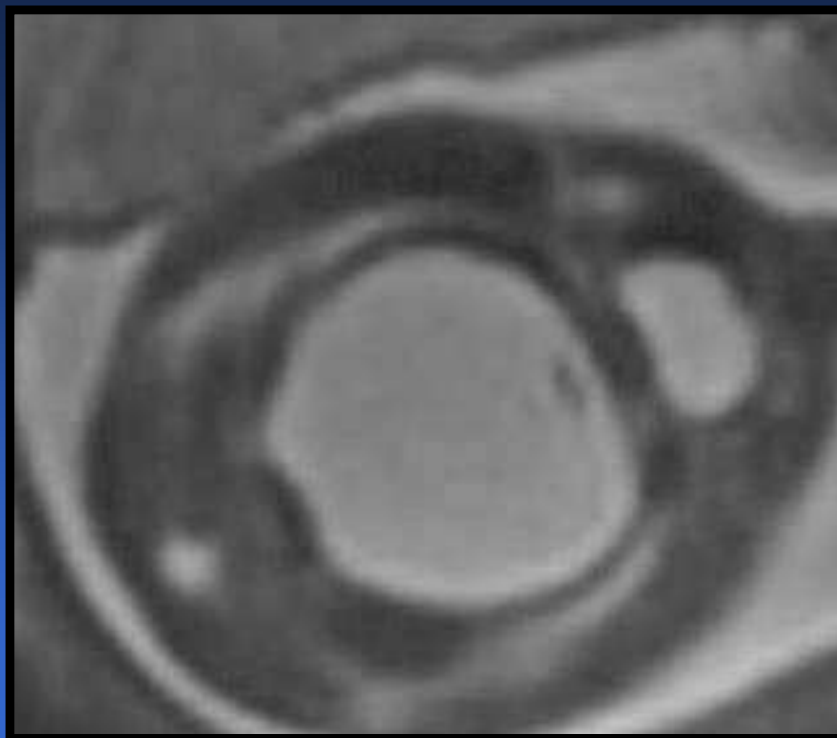
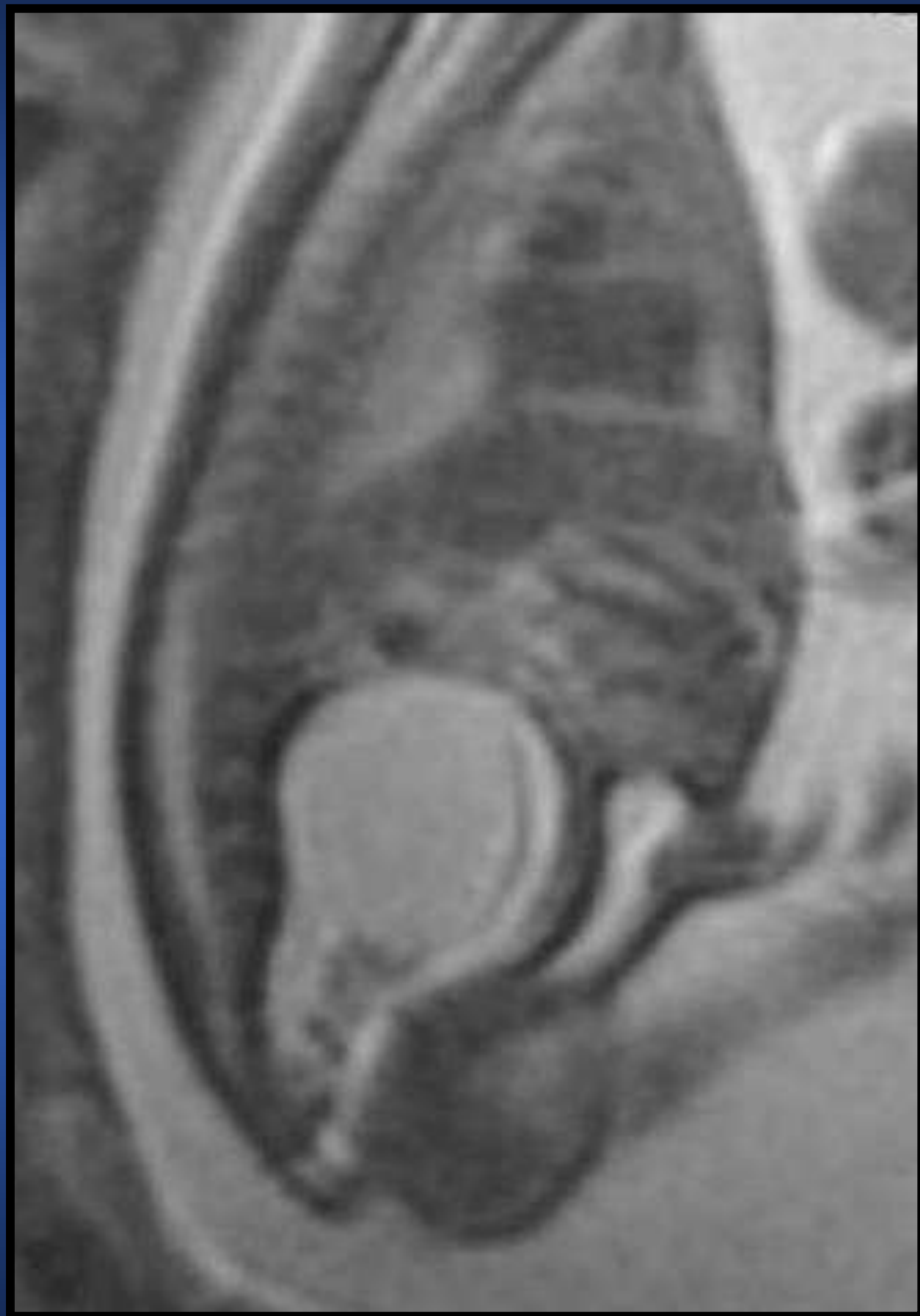3 plans T2 liquide Hyper S, 3 plans T1 Colon Hyper S

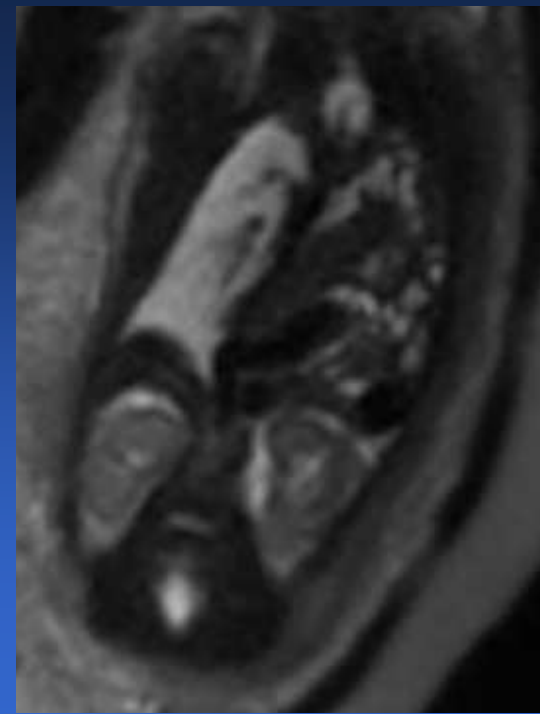
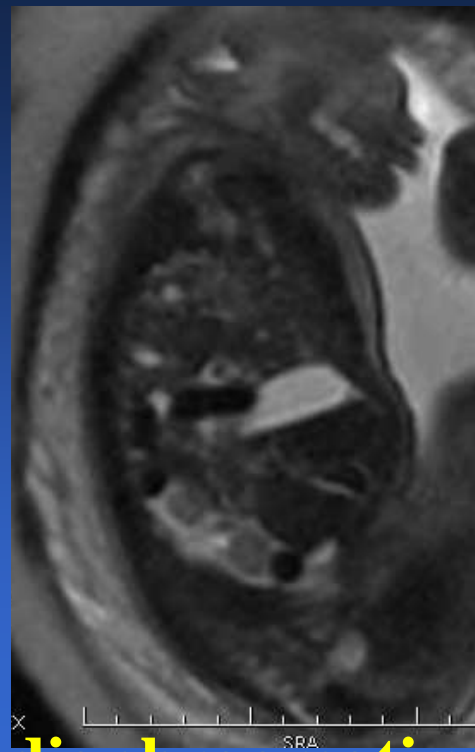
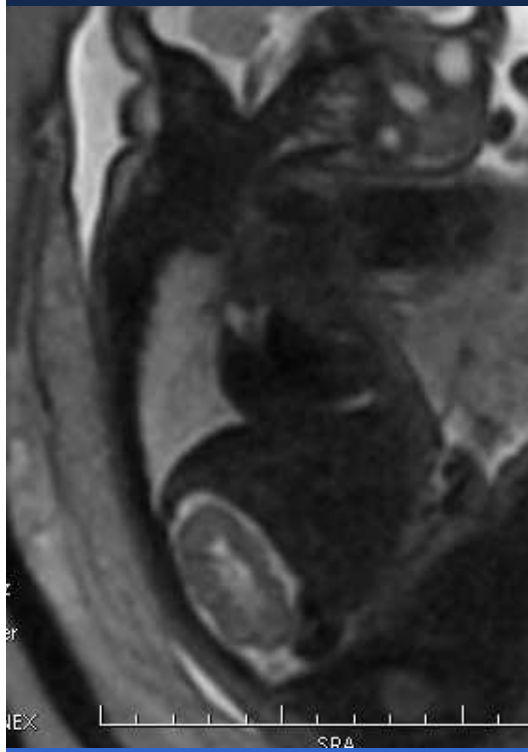


INDICATIONS EXTRACEREBRALES

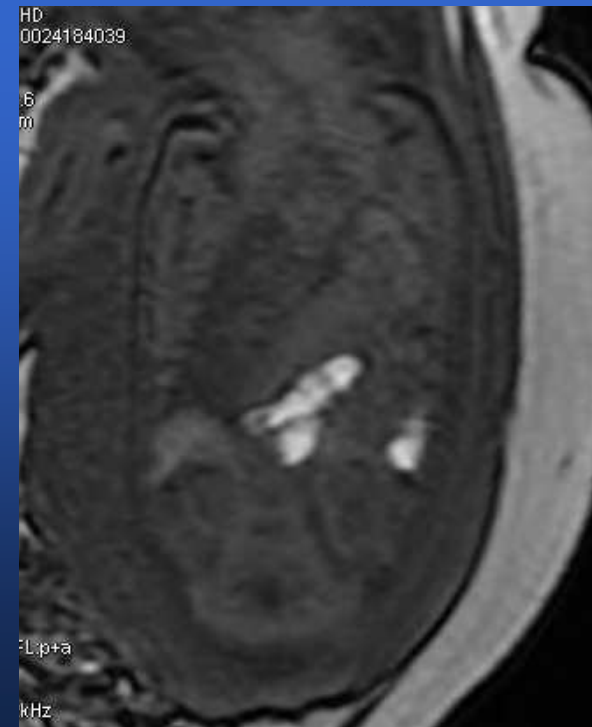
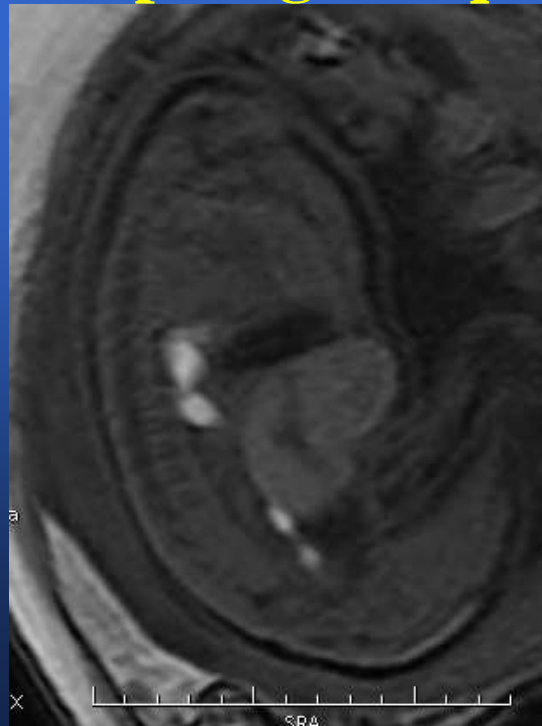
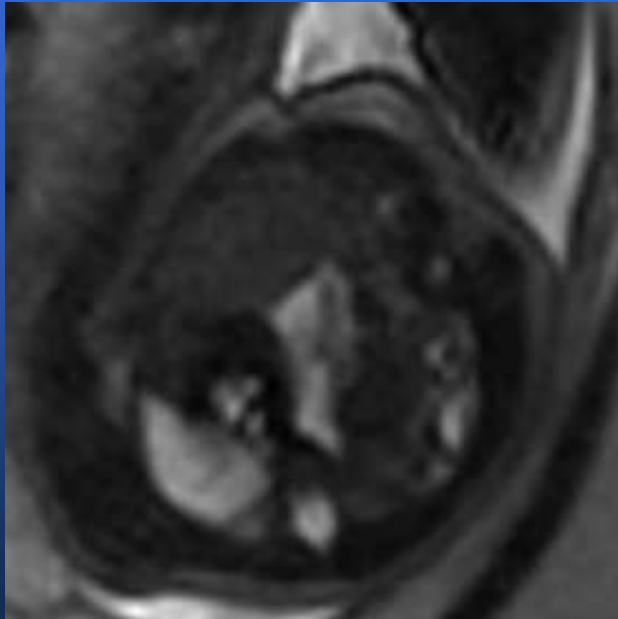
- Bilan de masses ou tumeurs
- Bilan de malformations
 - digestives (colon)
 - et/ou pulmonaires (volume pulmonaire)
 - Rachidiennes
- Anomalies de l'échostructure digestive

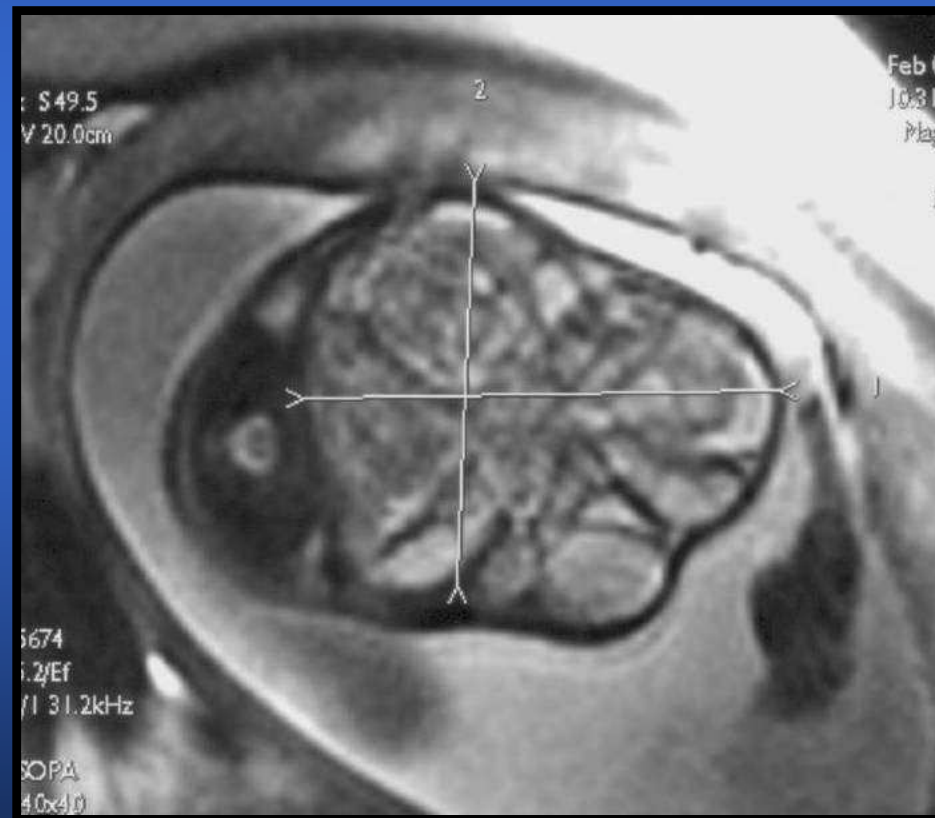
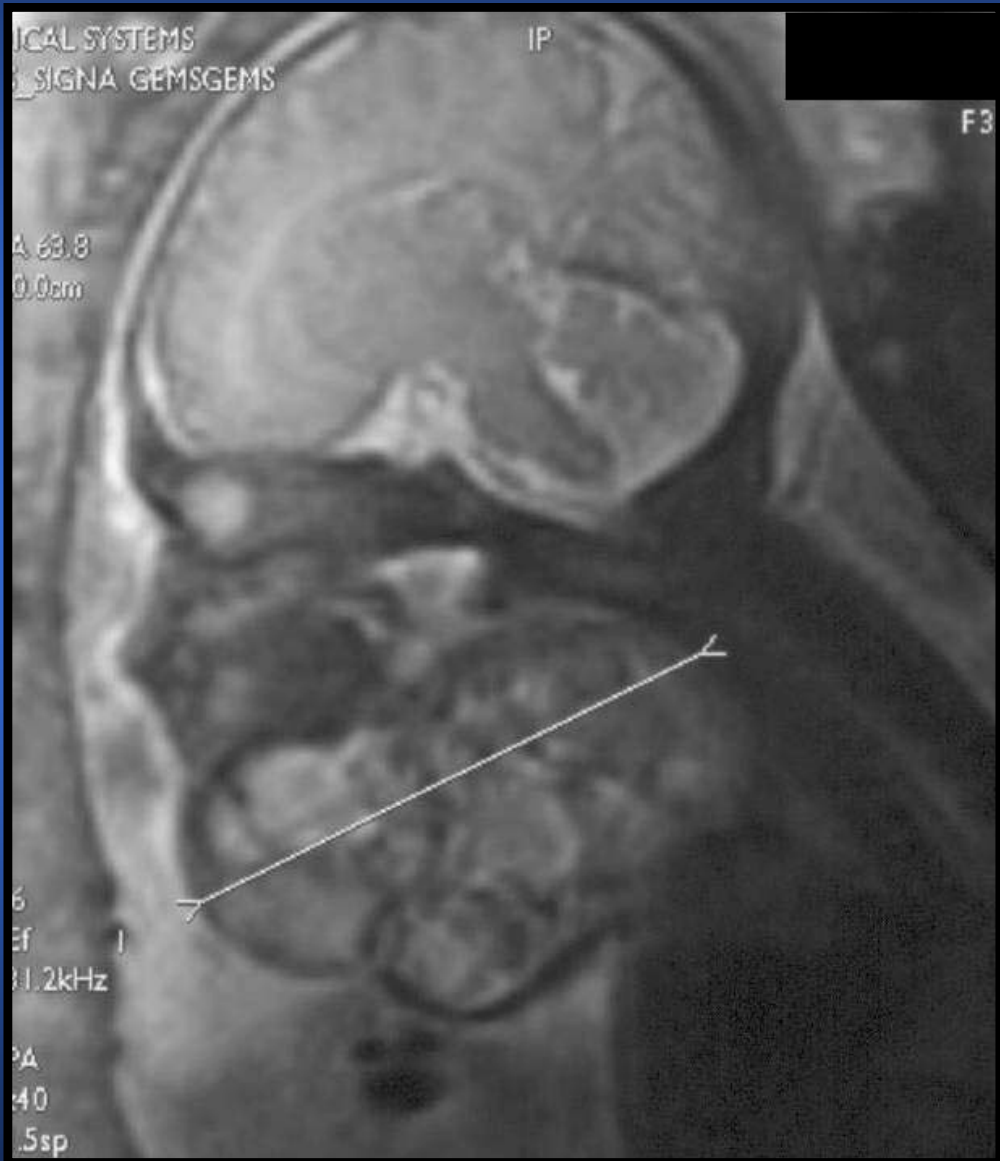

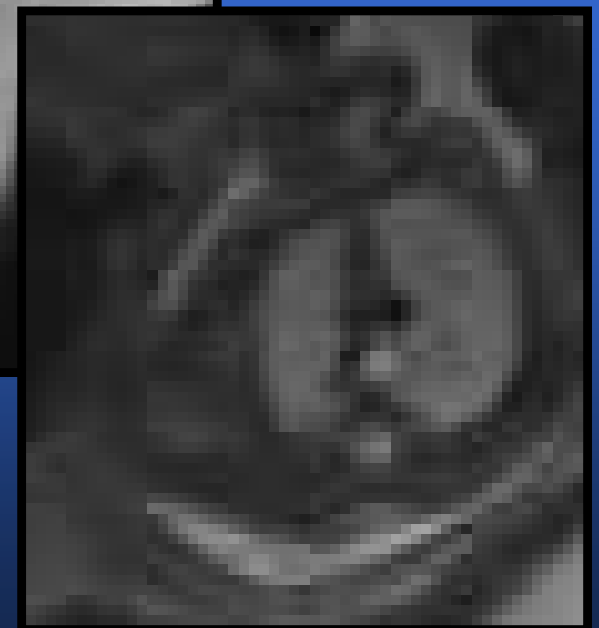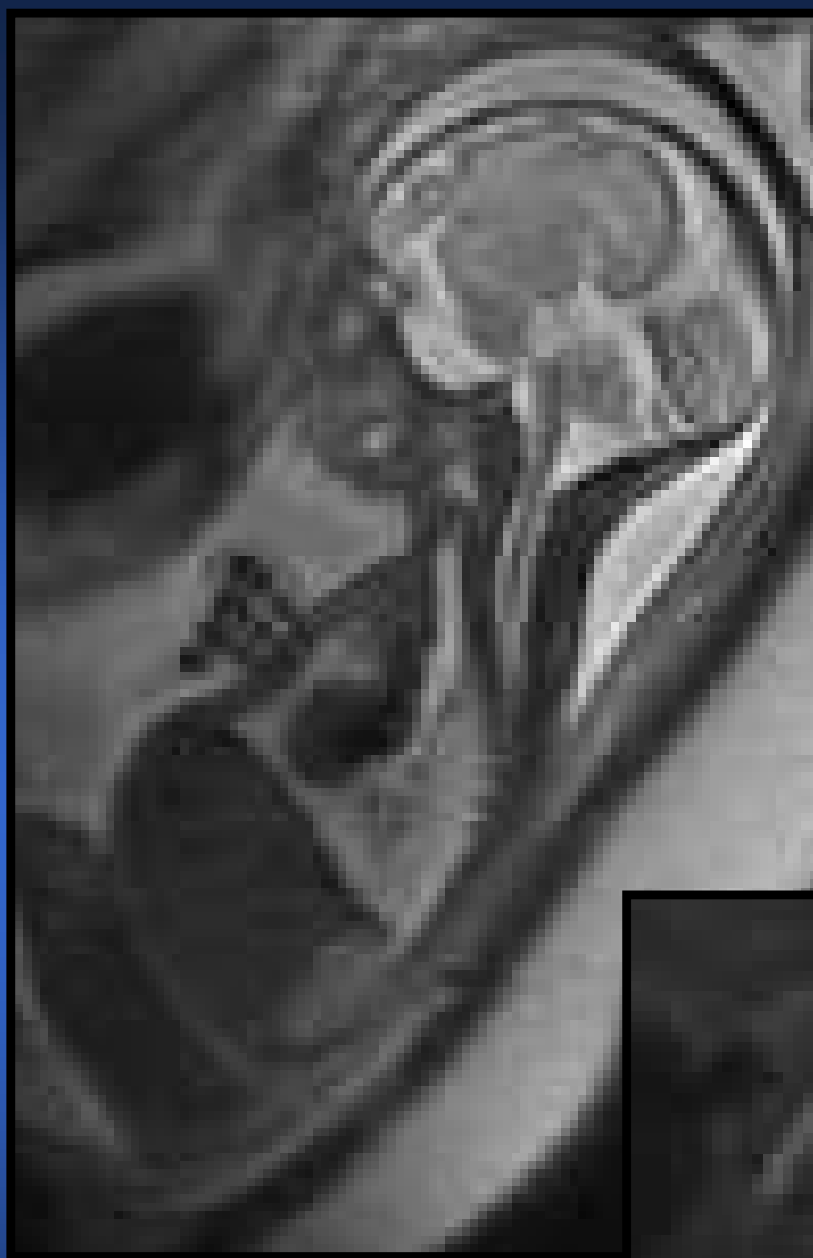


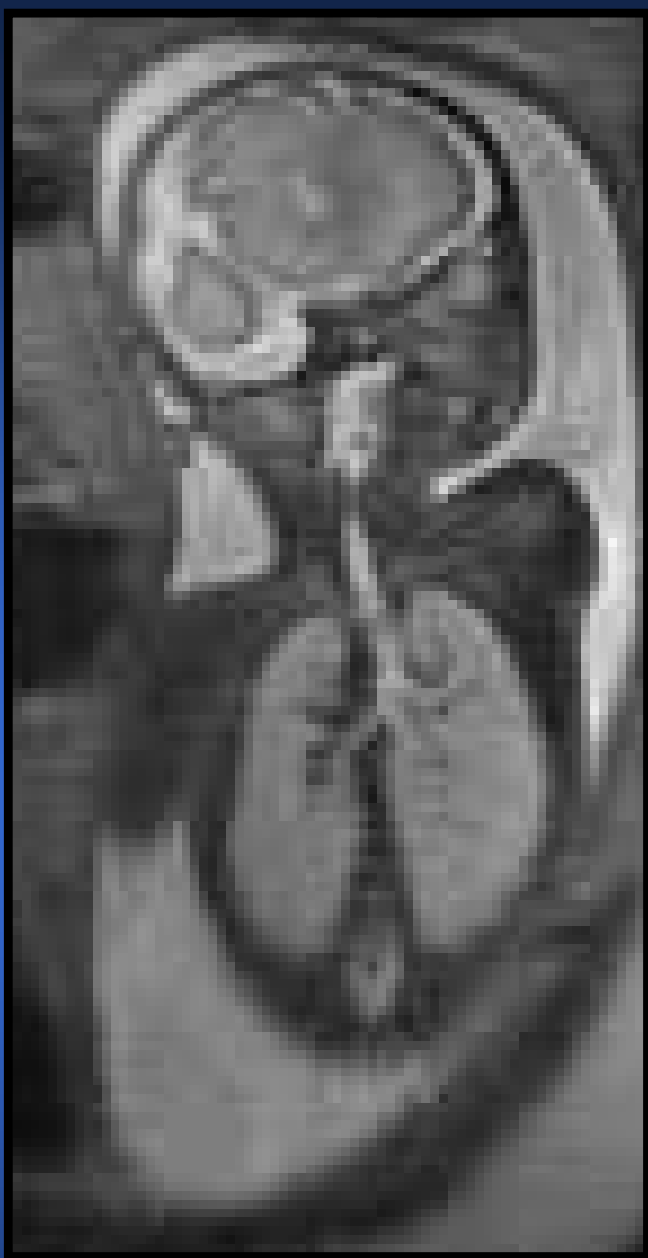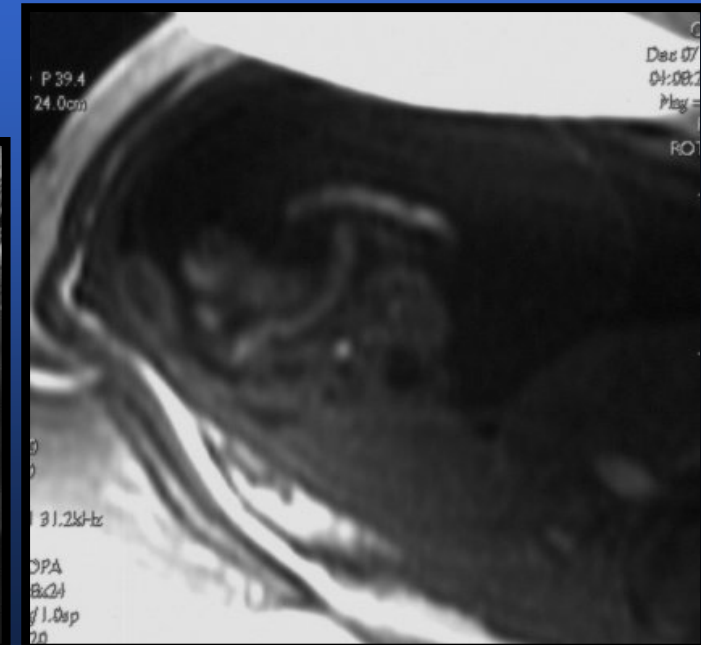
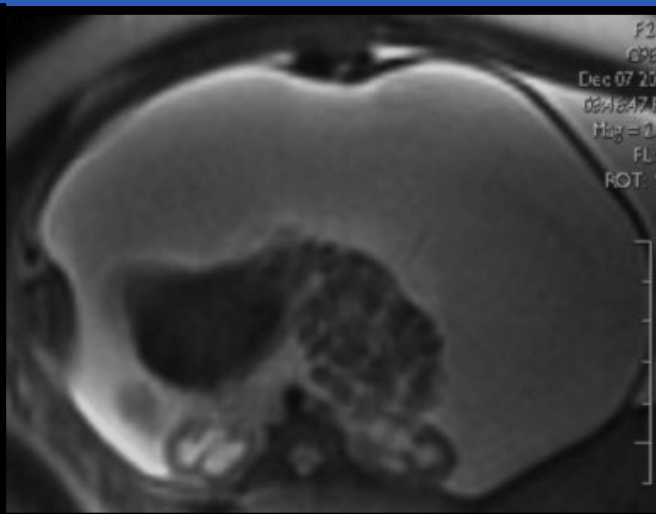
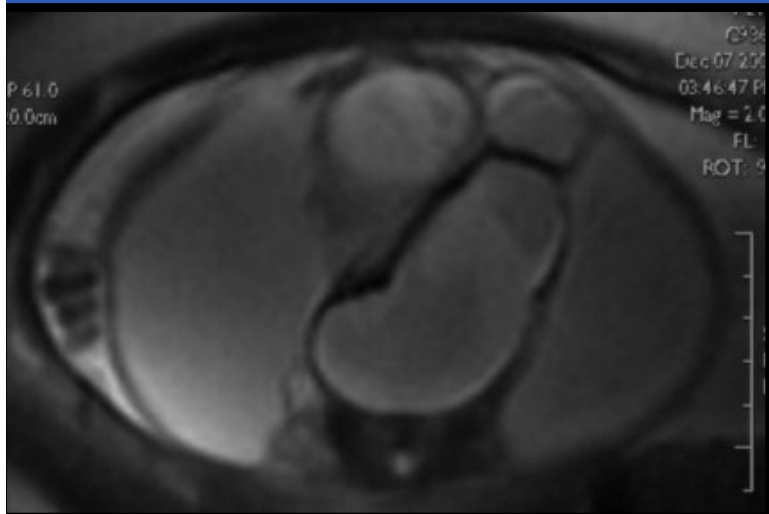
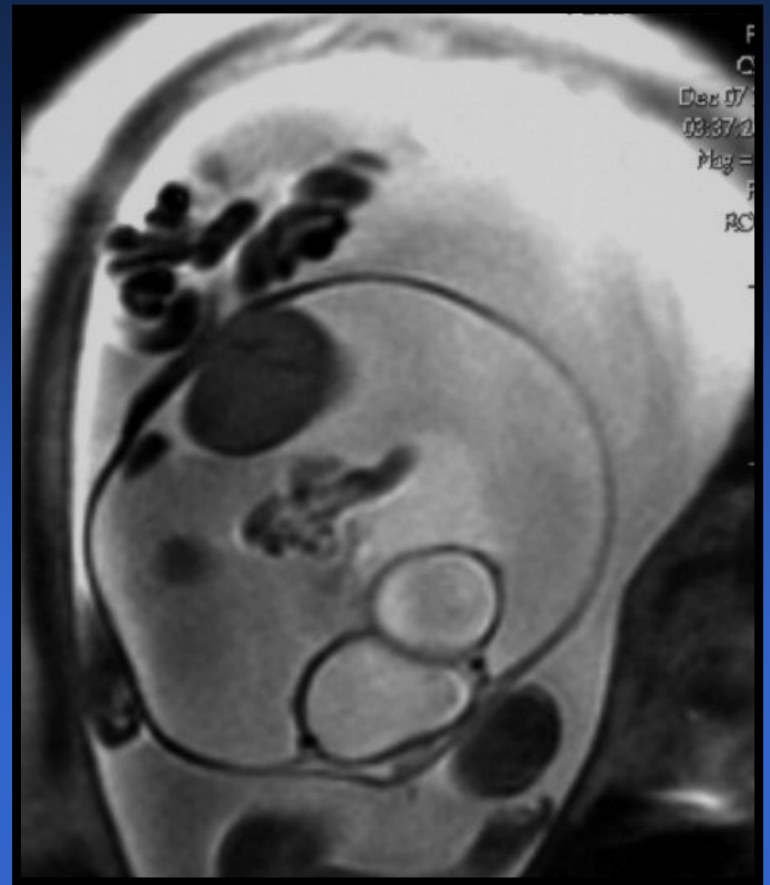
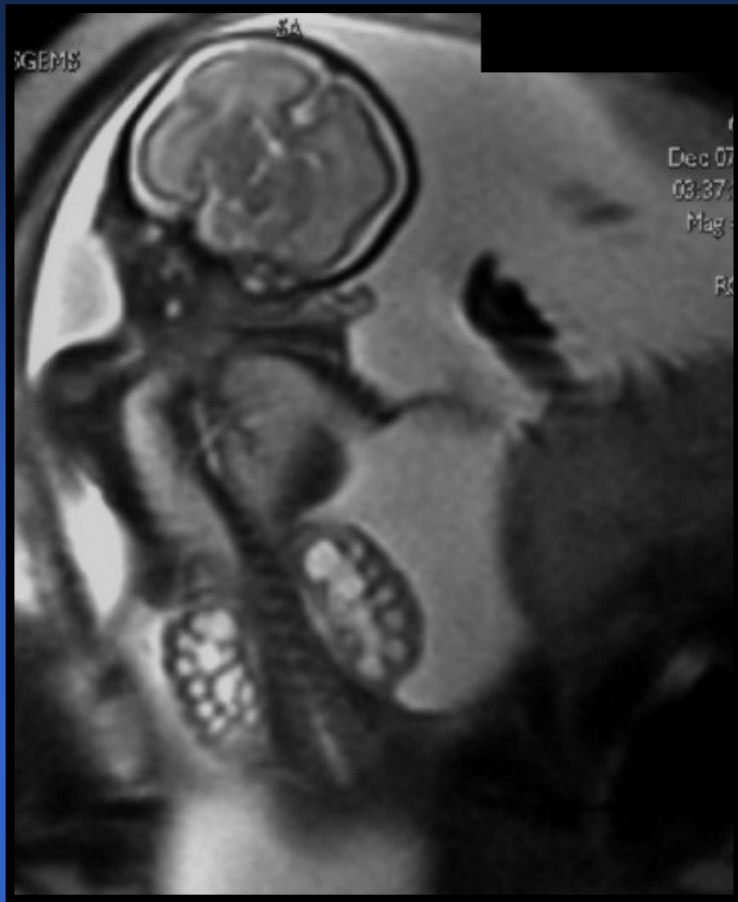


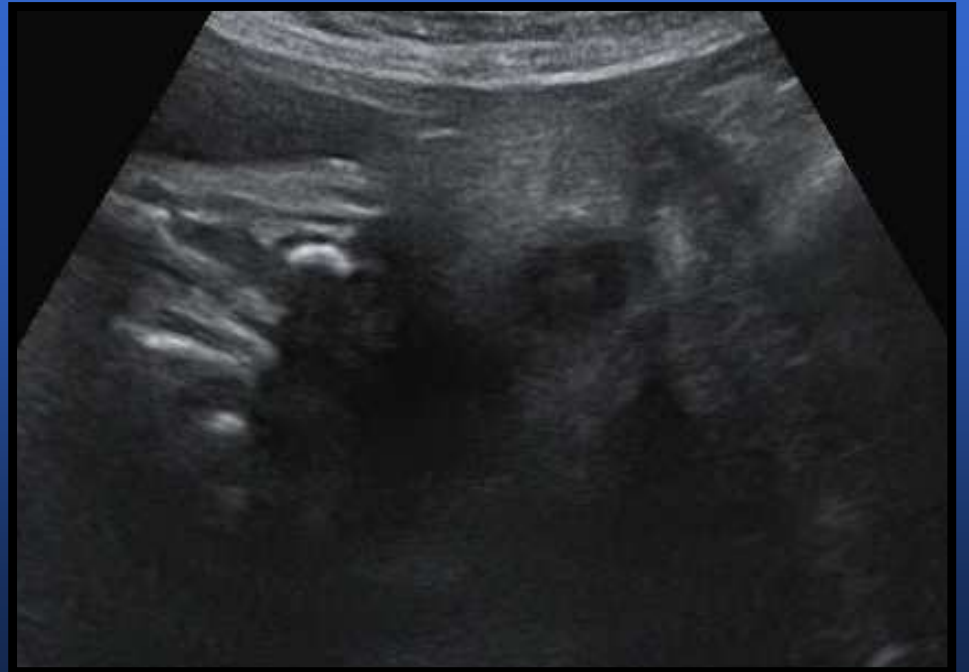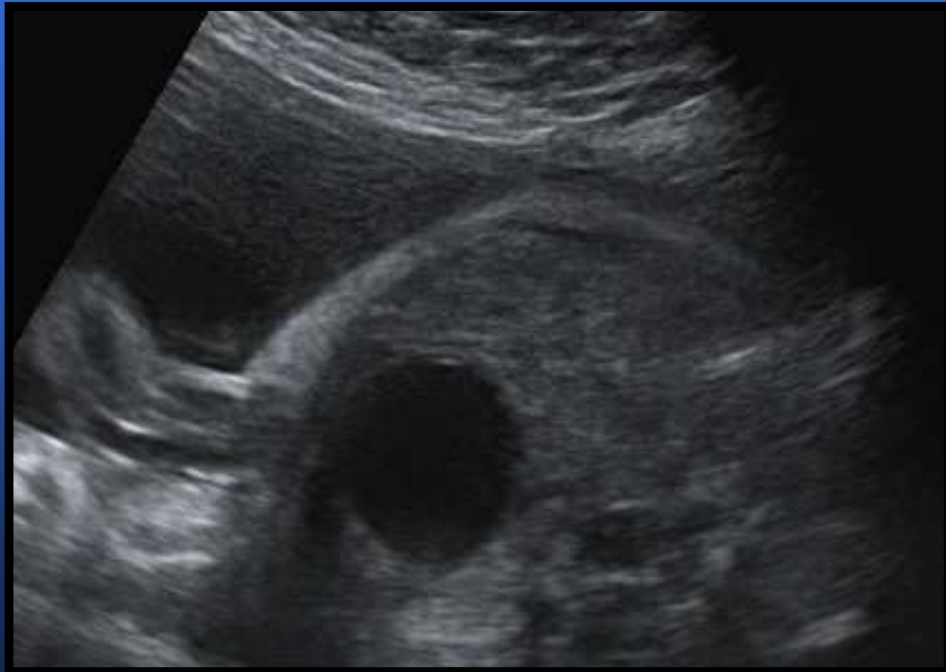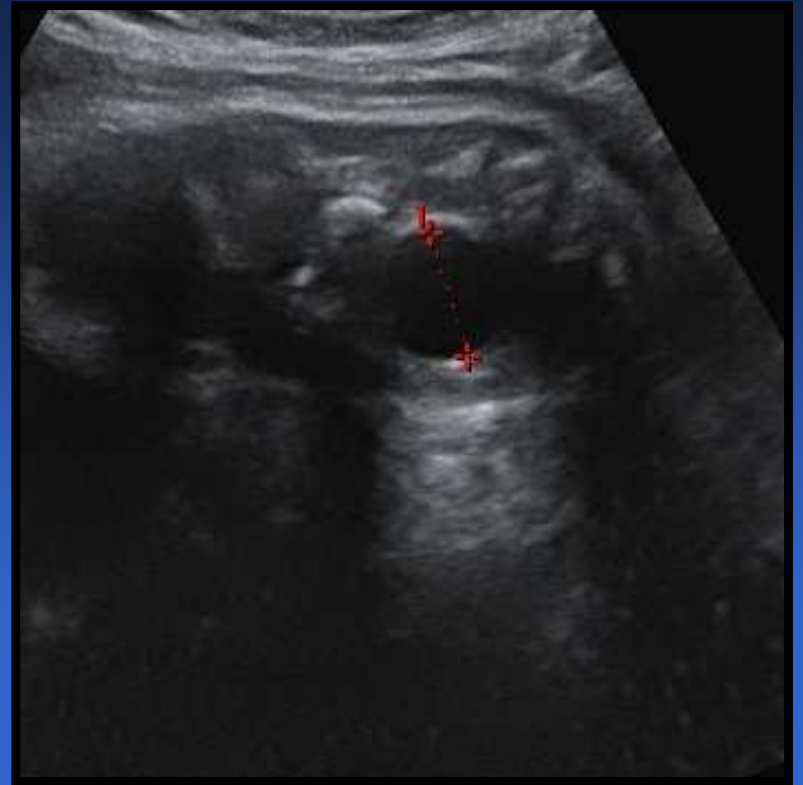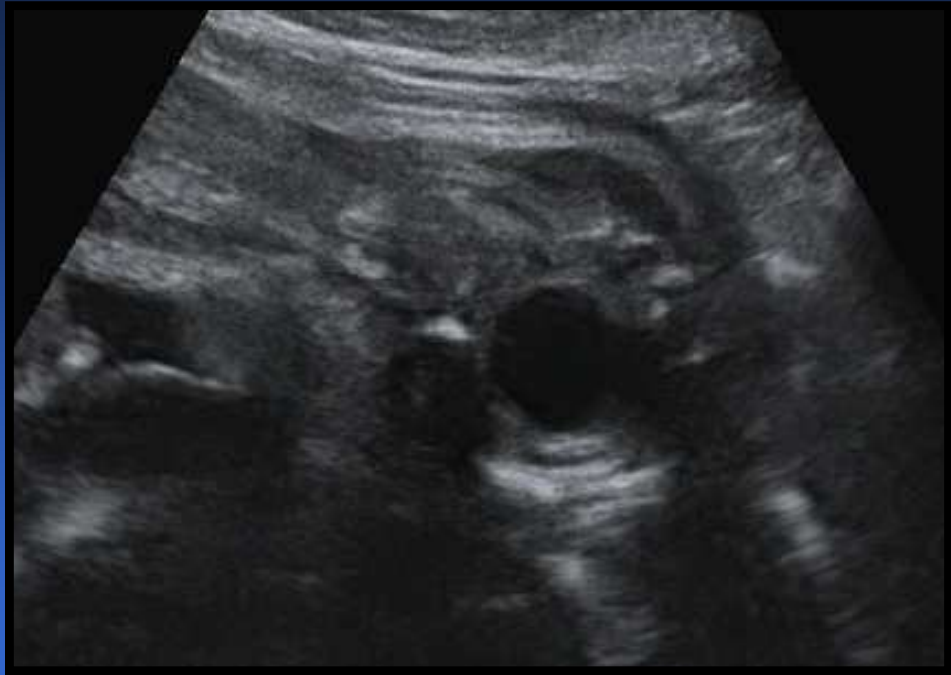Hernie diaphragmatique

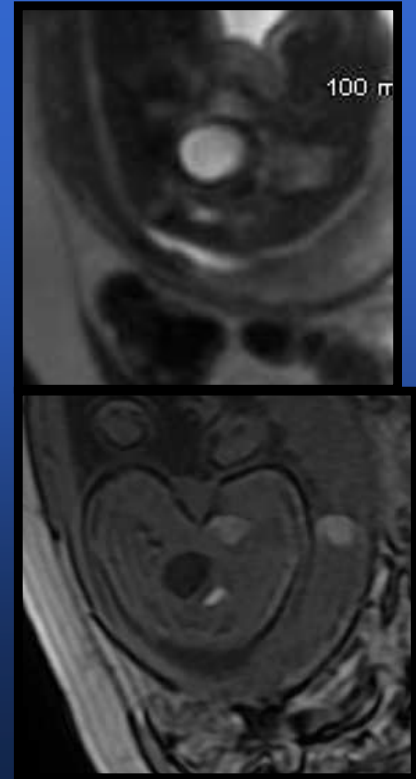
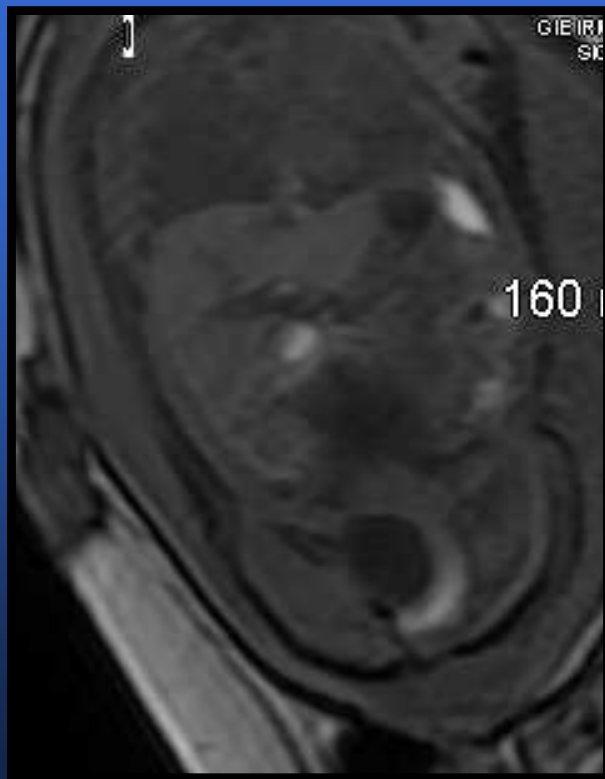
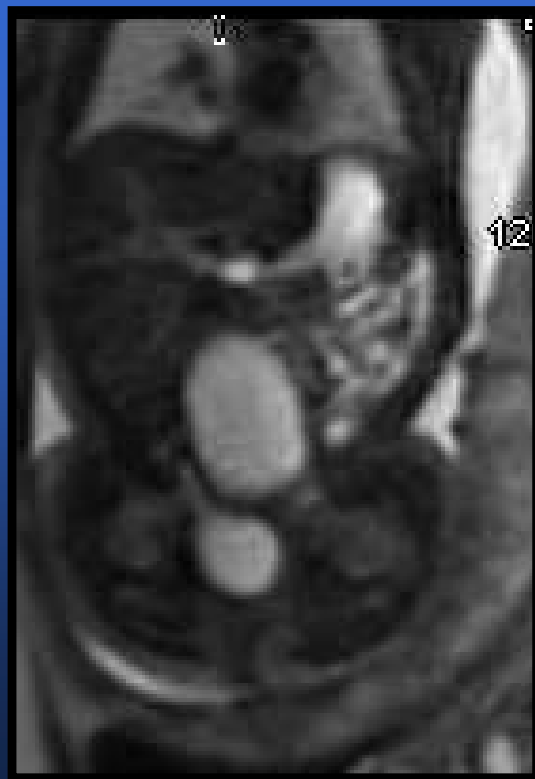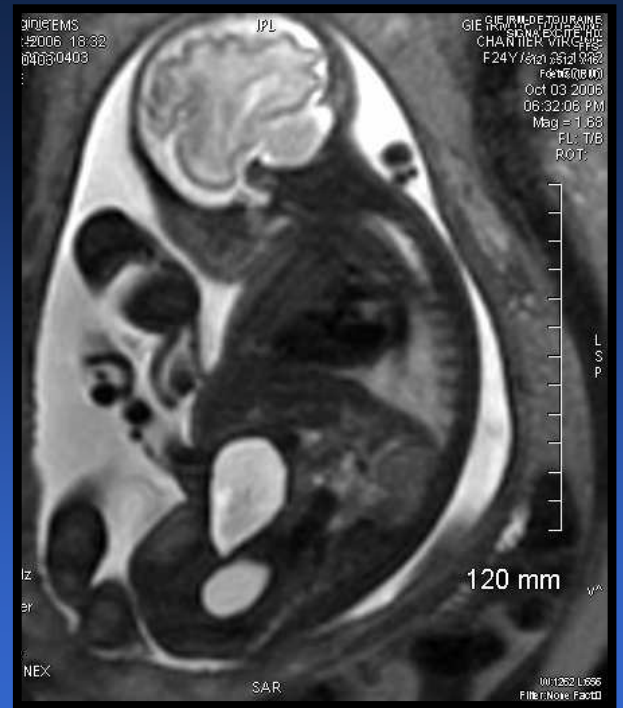
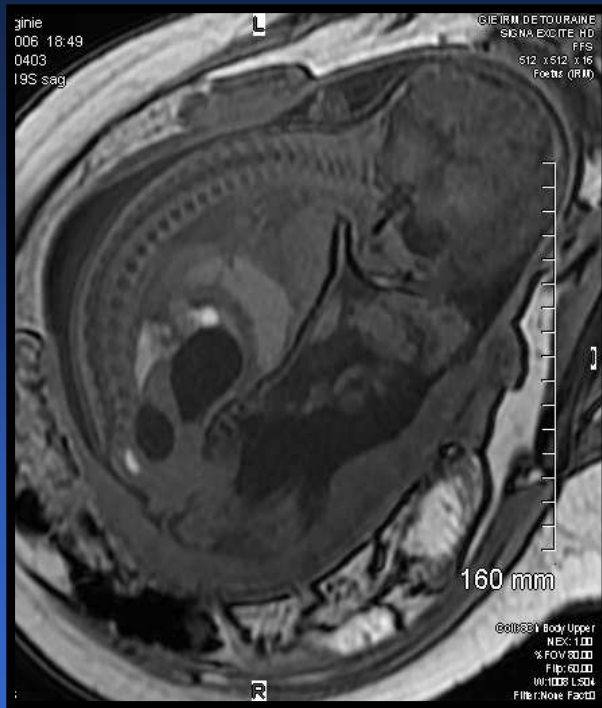

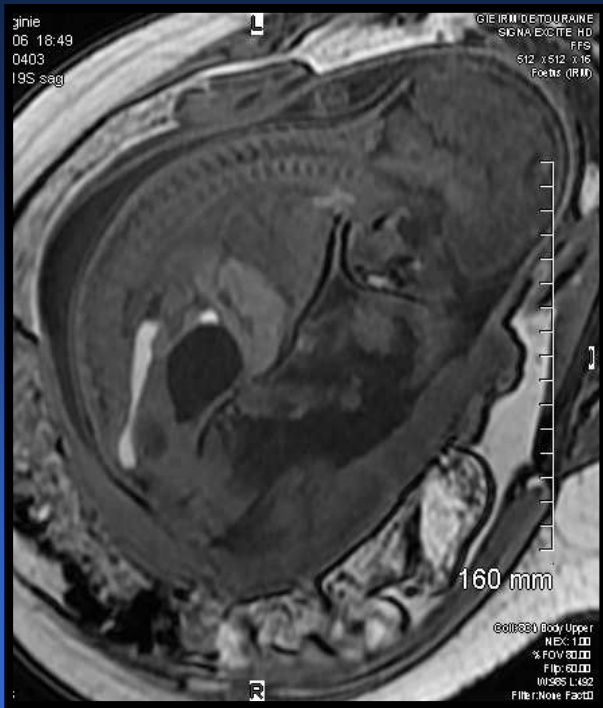
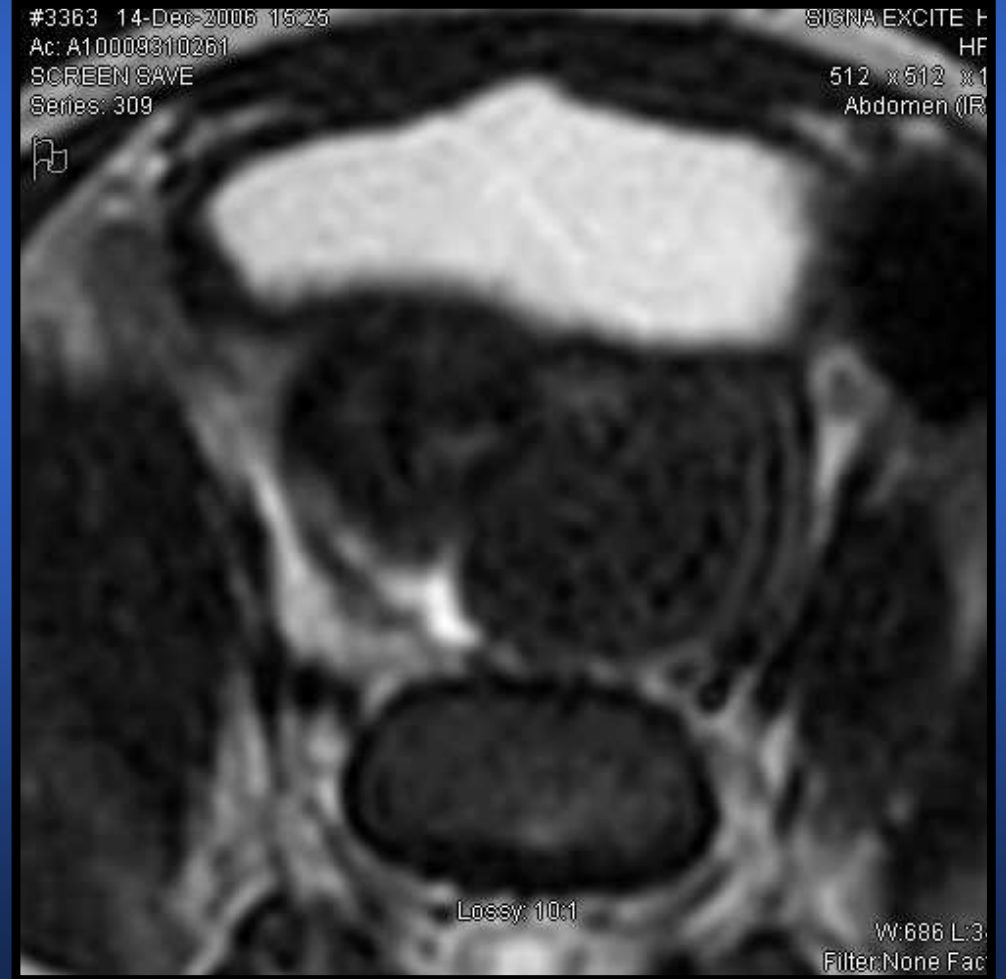
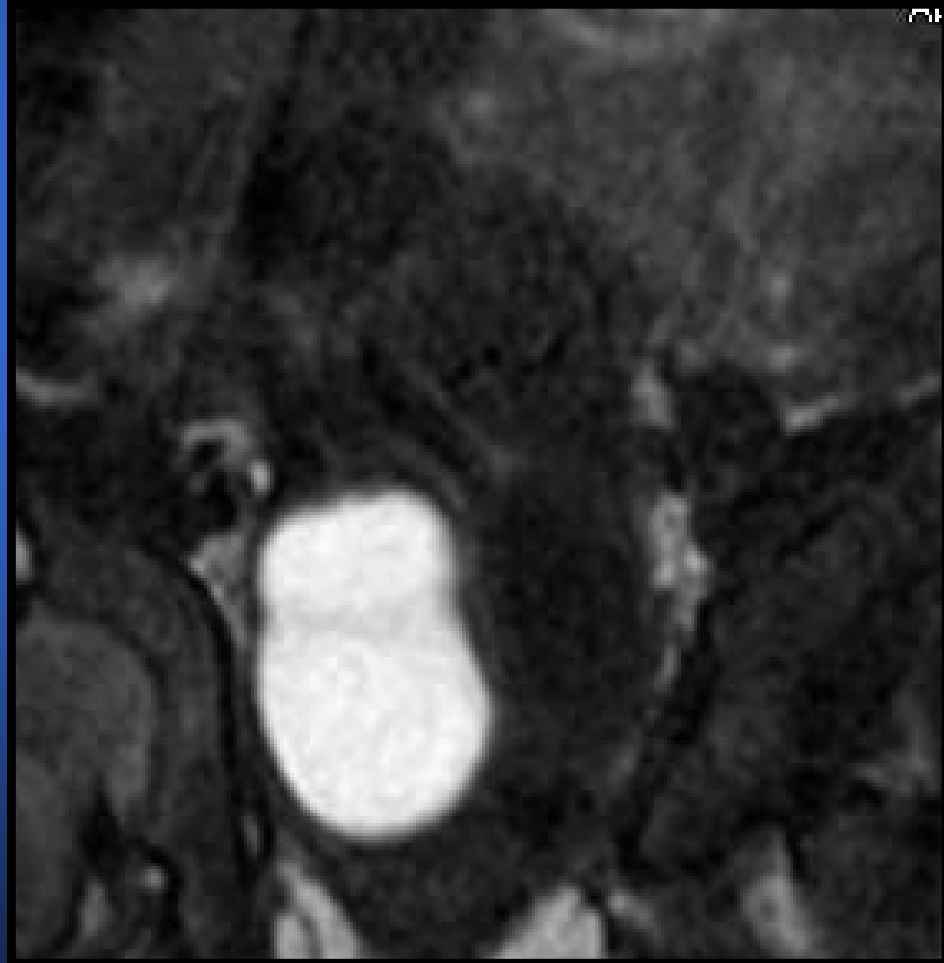
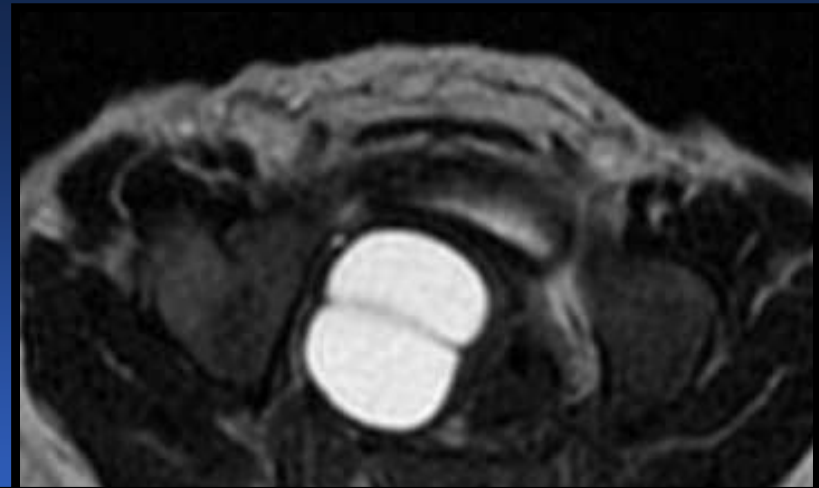
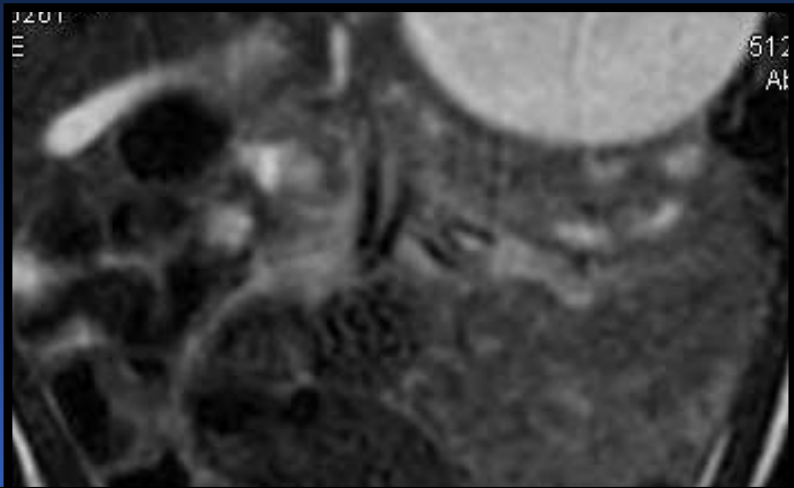


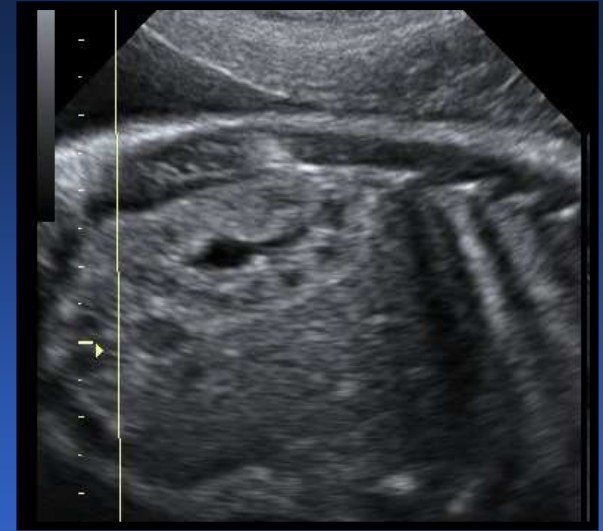
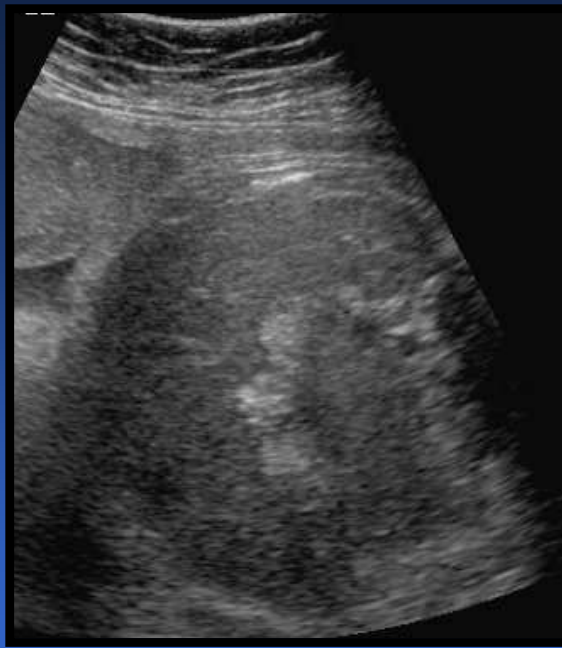


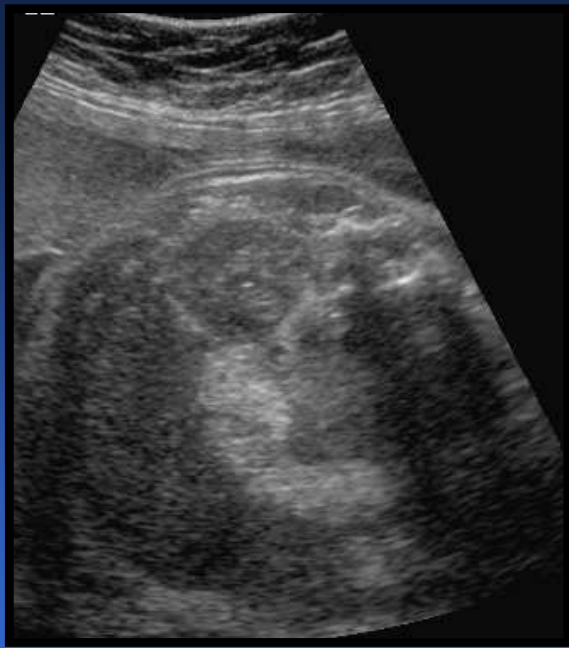

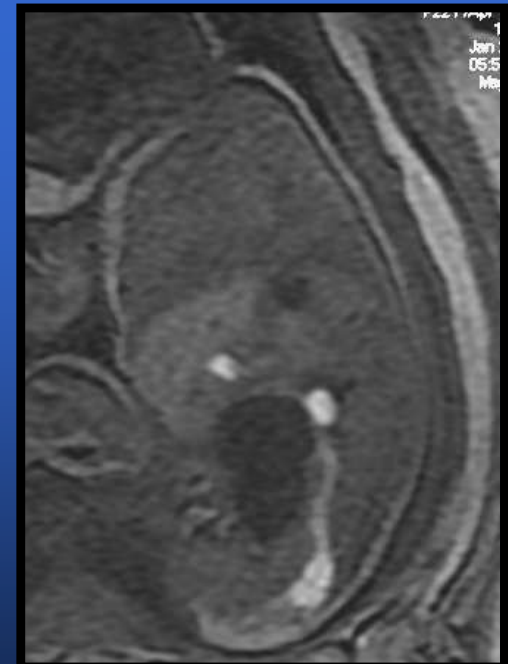
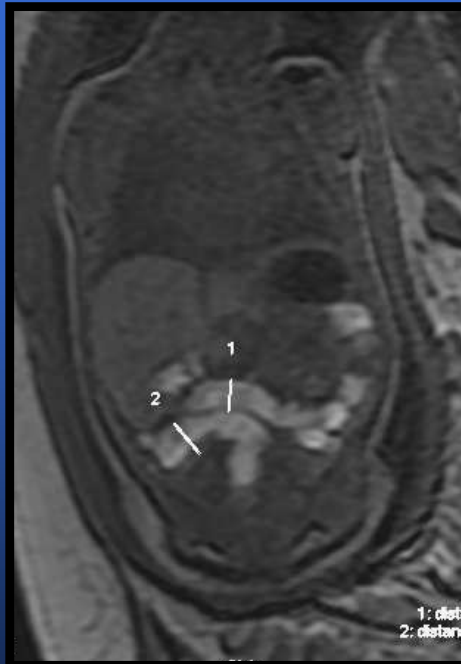


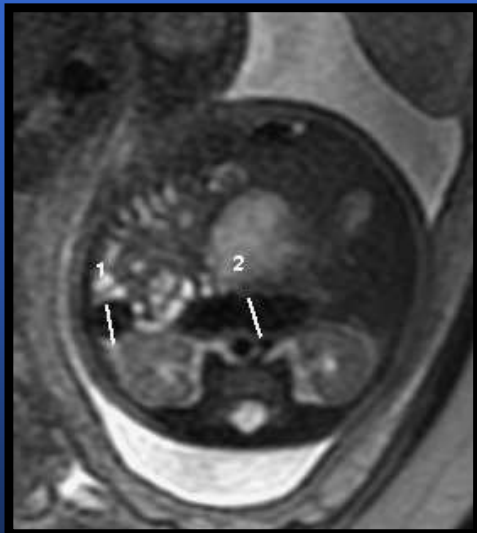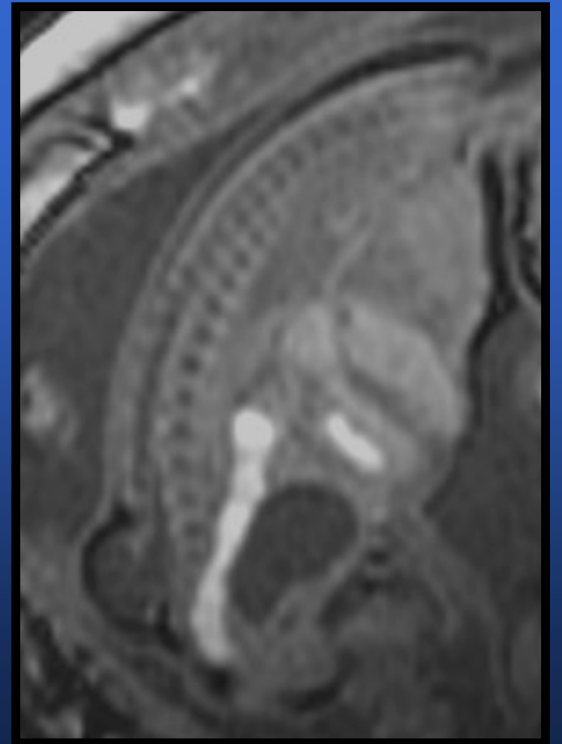
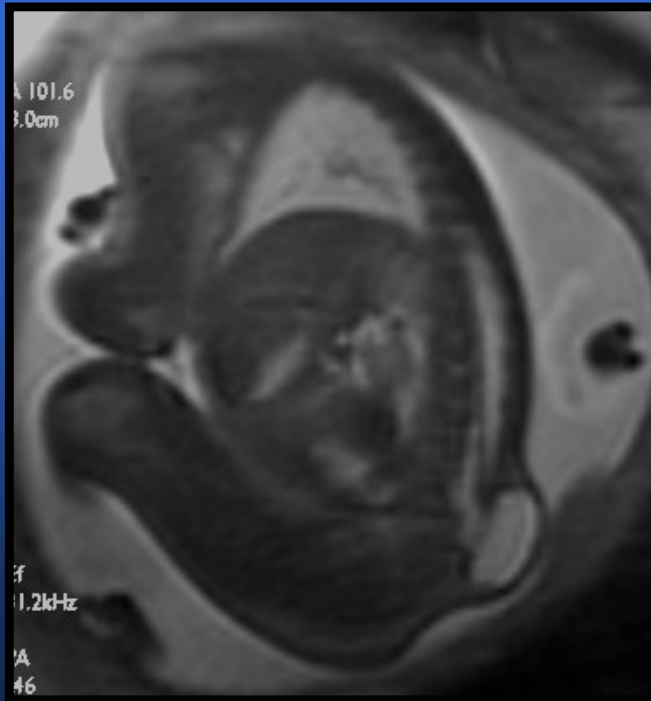




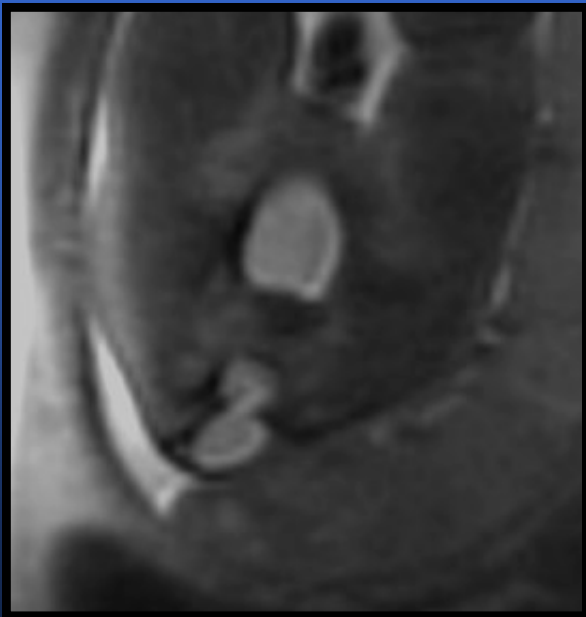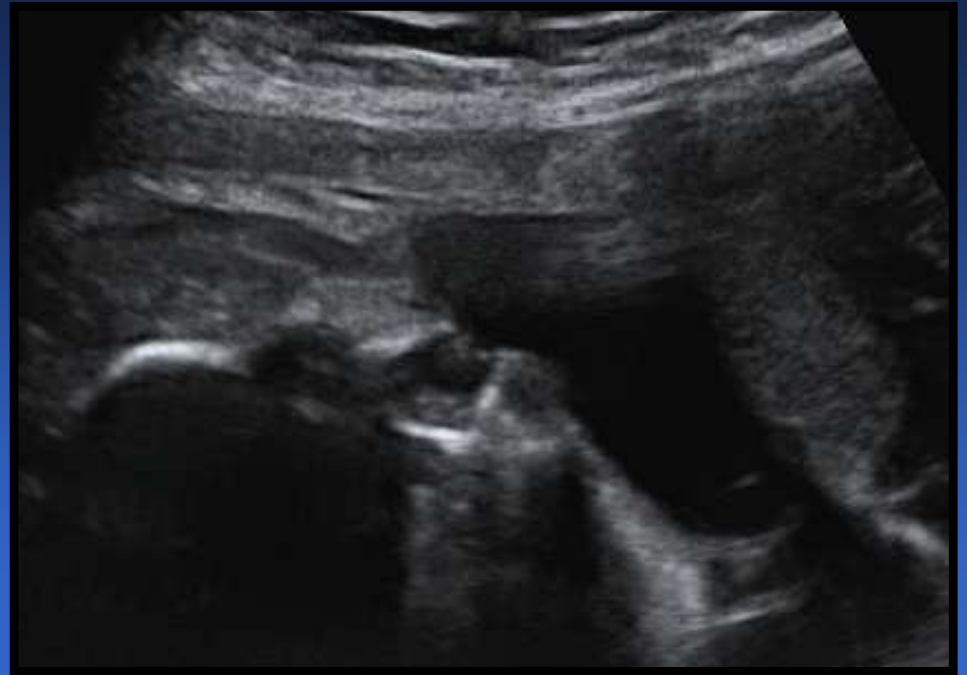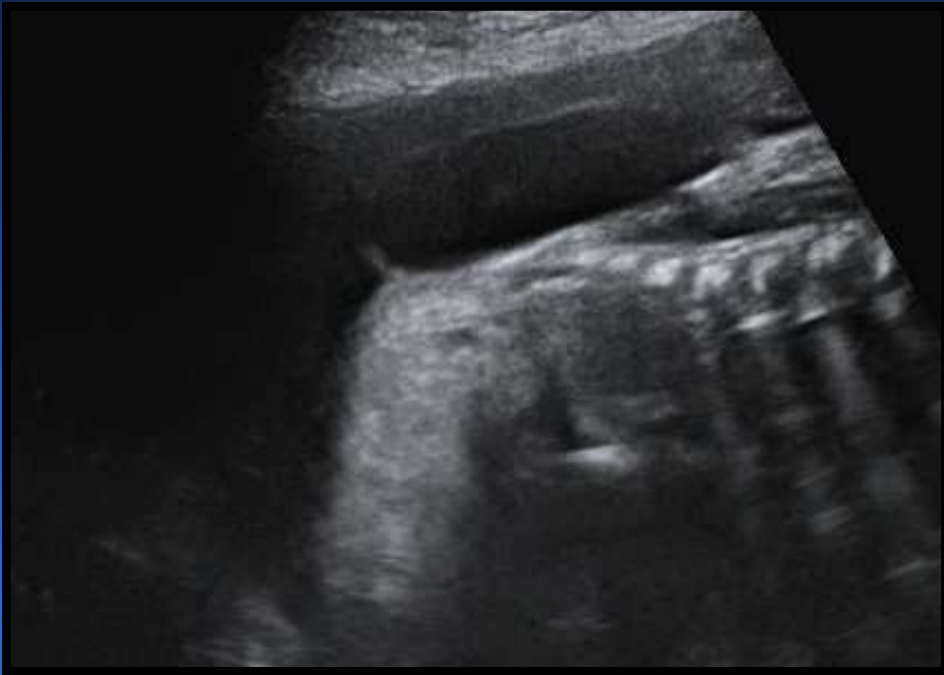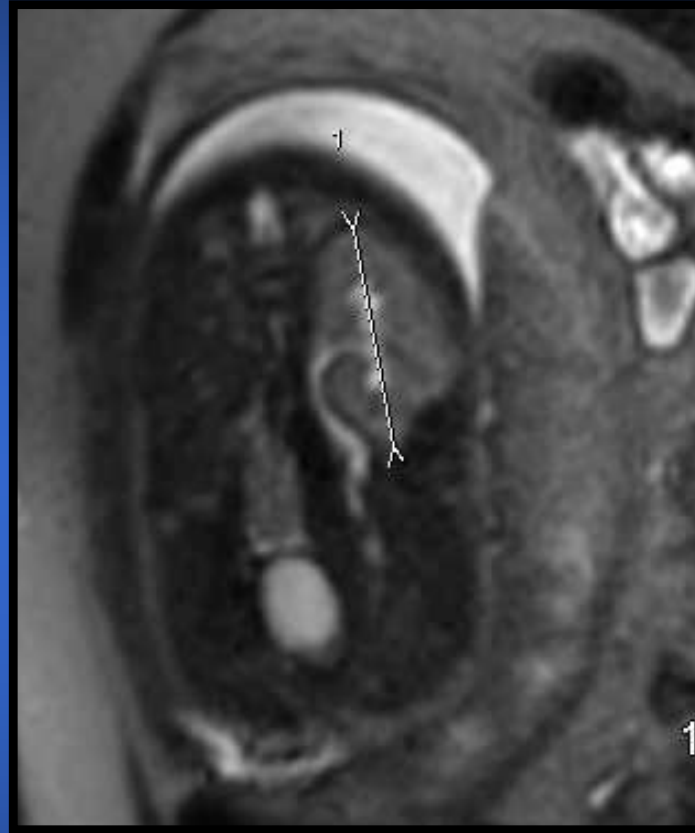


Hyper-échogénicité colique



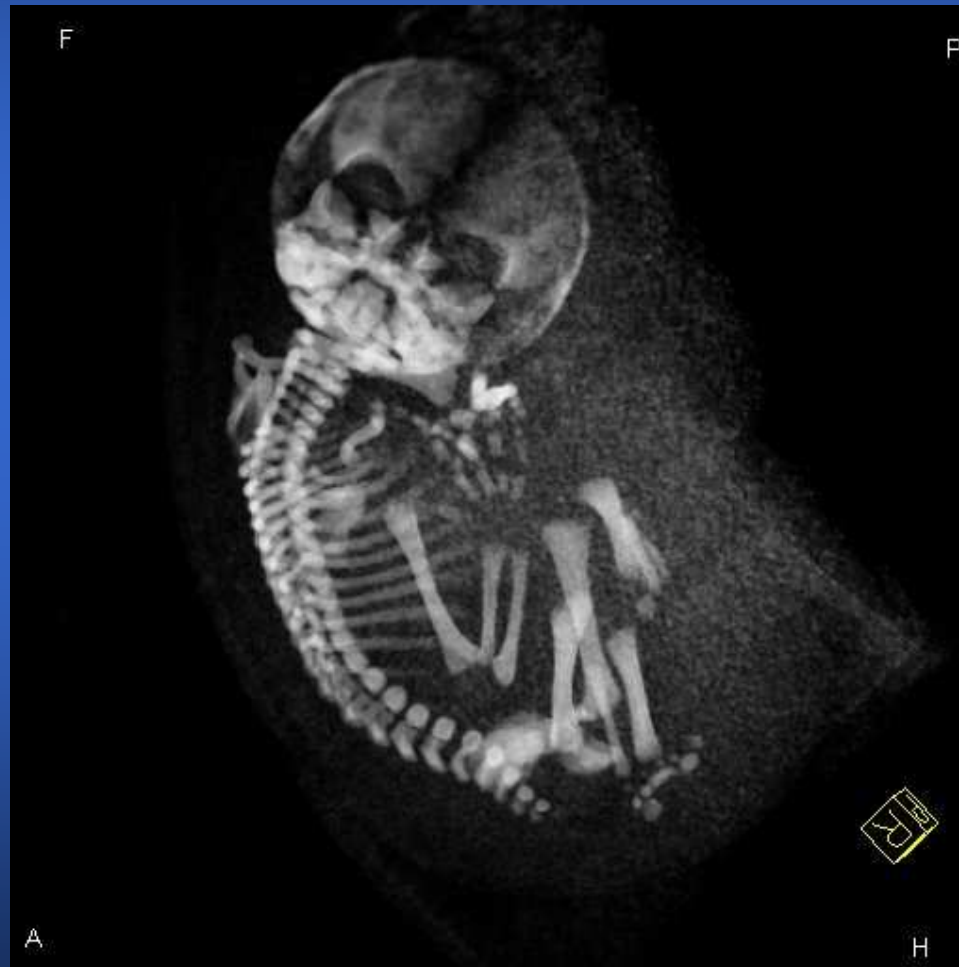

CONCLUSION



- **Examen de plus en plus fréquent**
- **Augmentation des indications**
- **Amélioration technique**

Scanner du squelette fœtal



Technique

- Irradiation la plus faible possible
- Pas de topogramme
- Acquisition hélicoïdale de la symphyse pubienne jusqu'en haut du fœtus (surveillance visuelle des coupes)

Irradiation

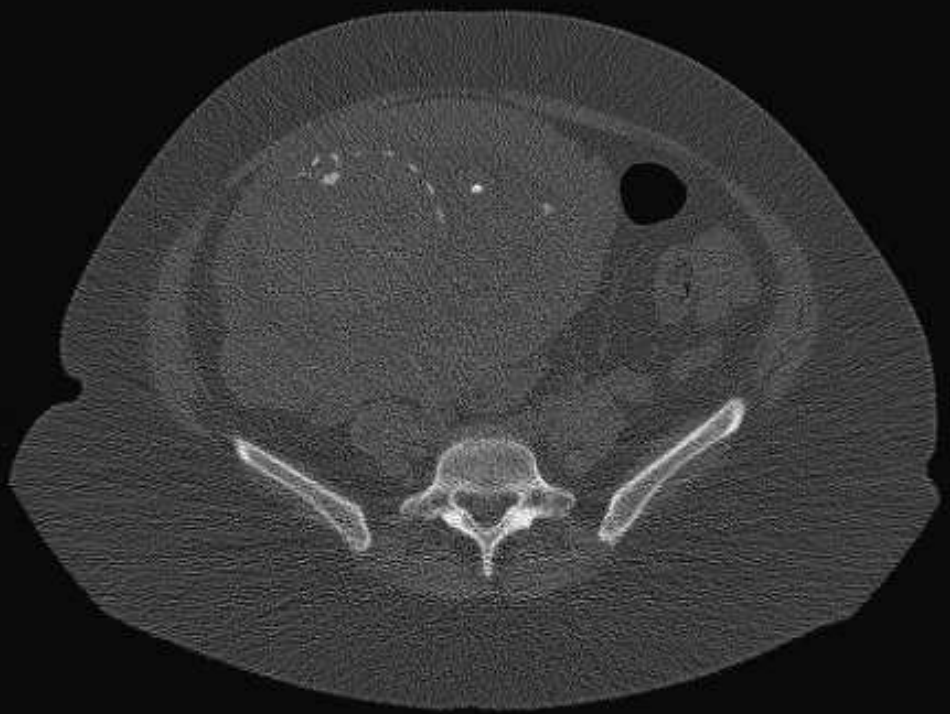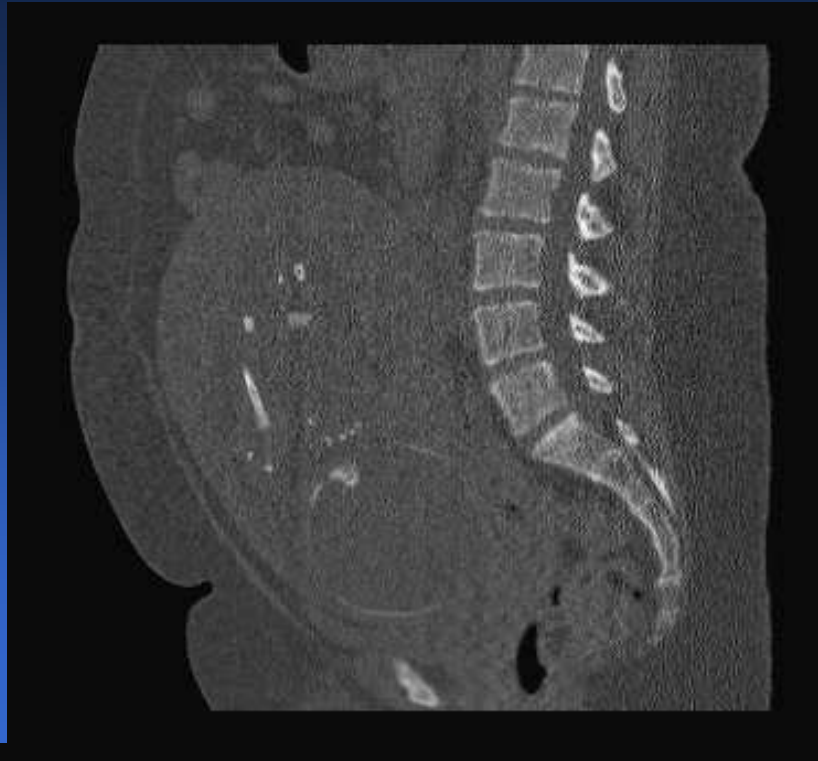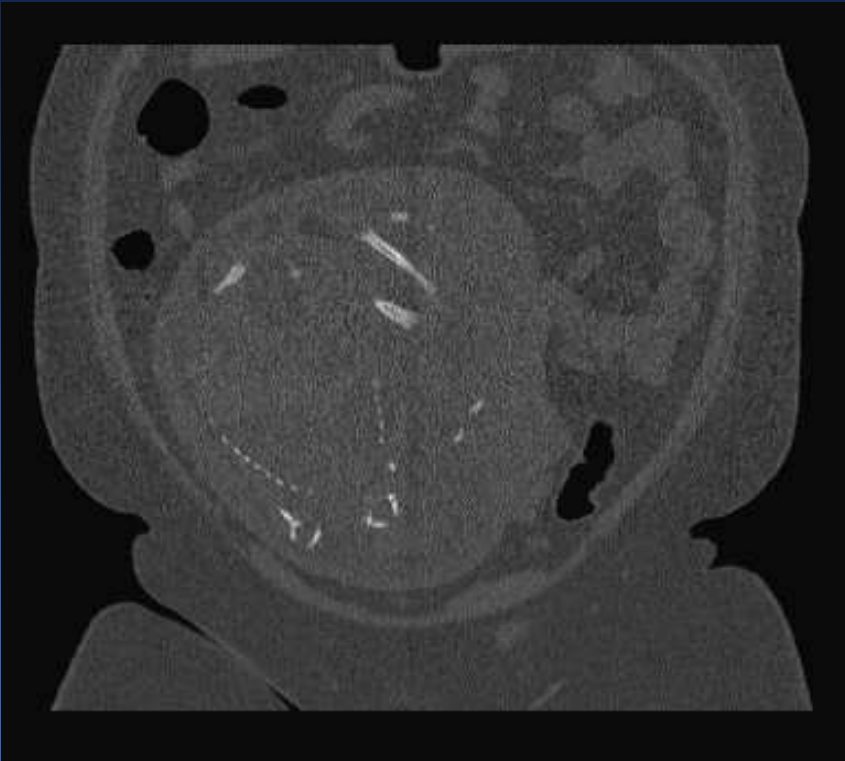
- **CTDI = 6 mGy pour 120mas 100 KV
soit 2 clichés de contenu utérin environ**

Indications

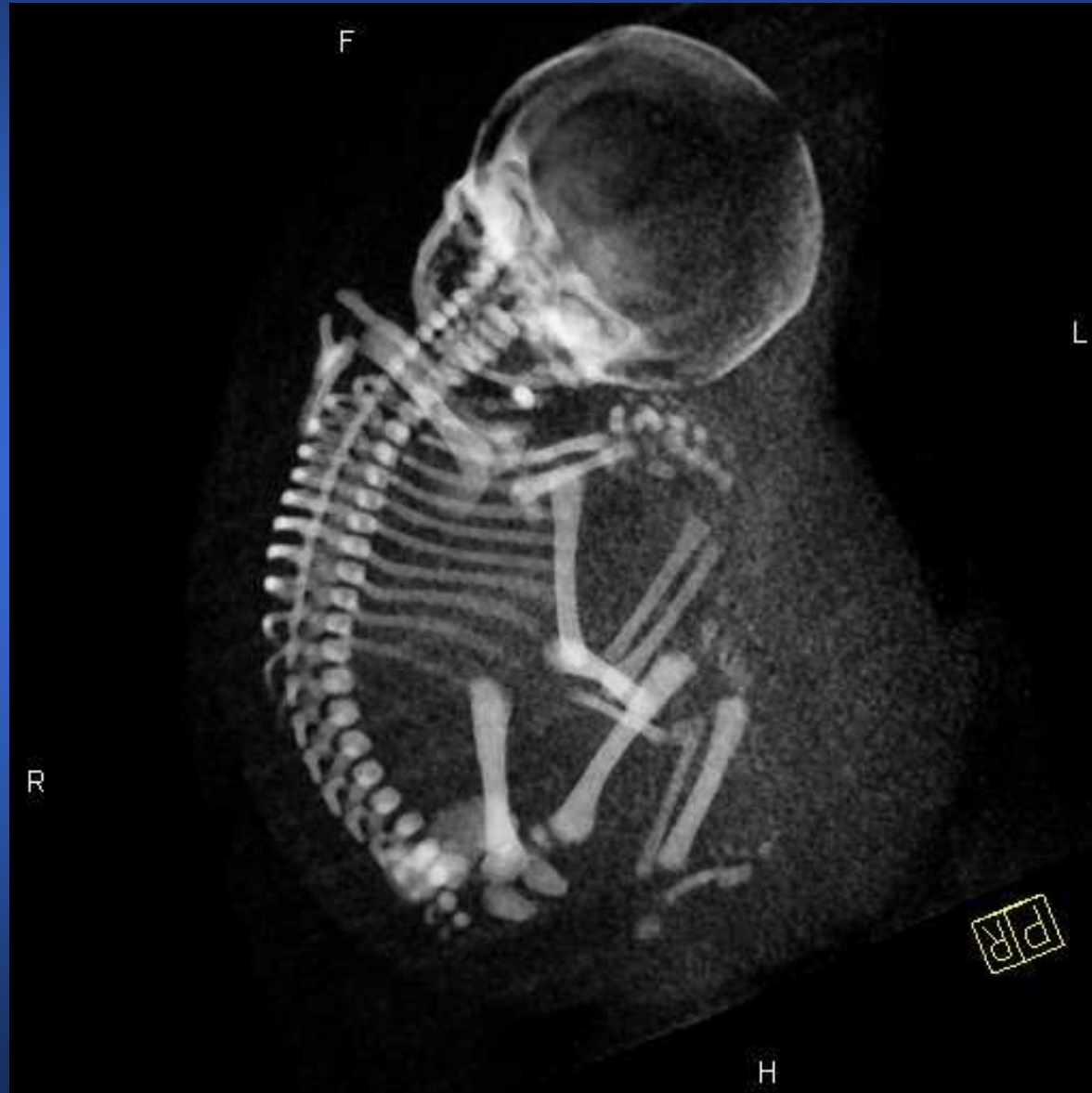- **Pathologies osseuse :**
 - **Malformations**
 - **Chondrodysplasies**
- **Terme de réalisation : ossification suffisante**
- **Etude de la structure osseuse difficile**

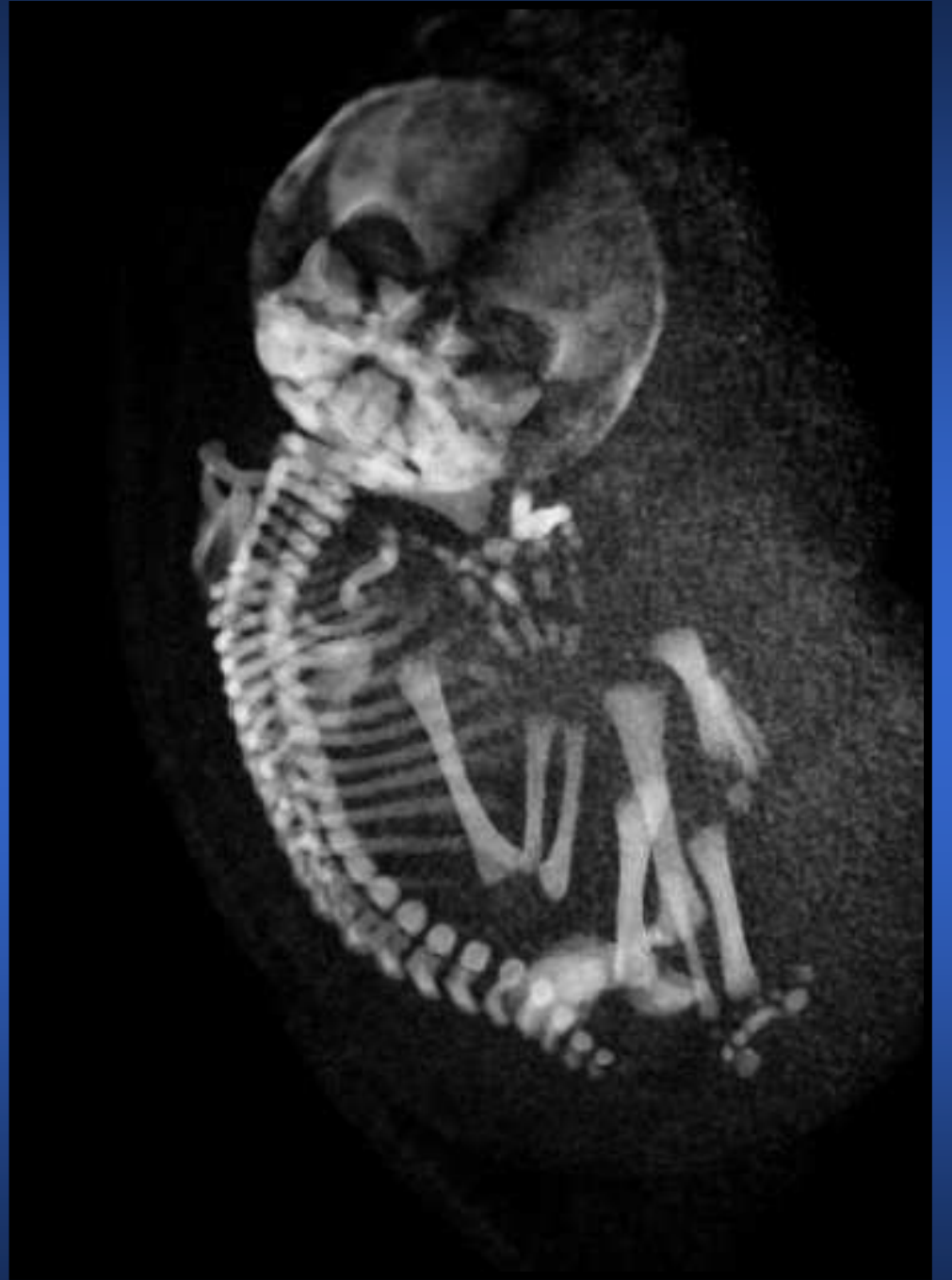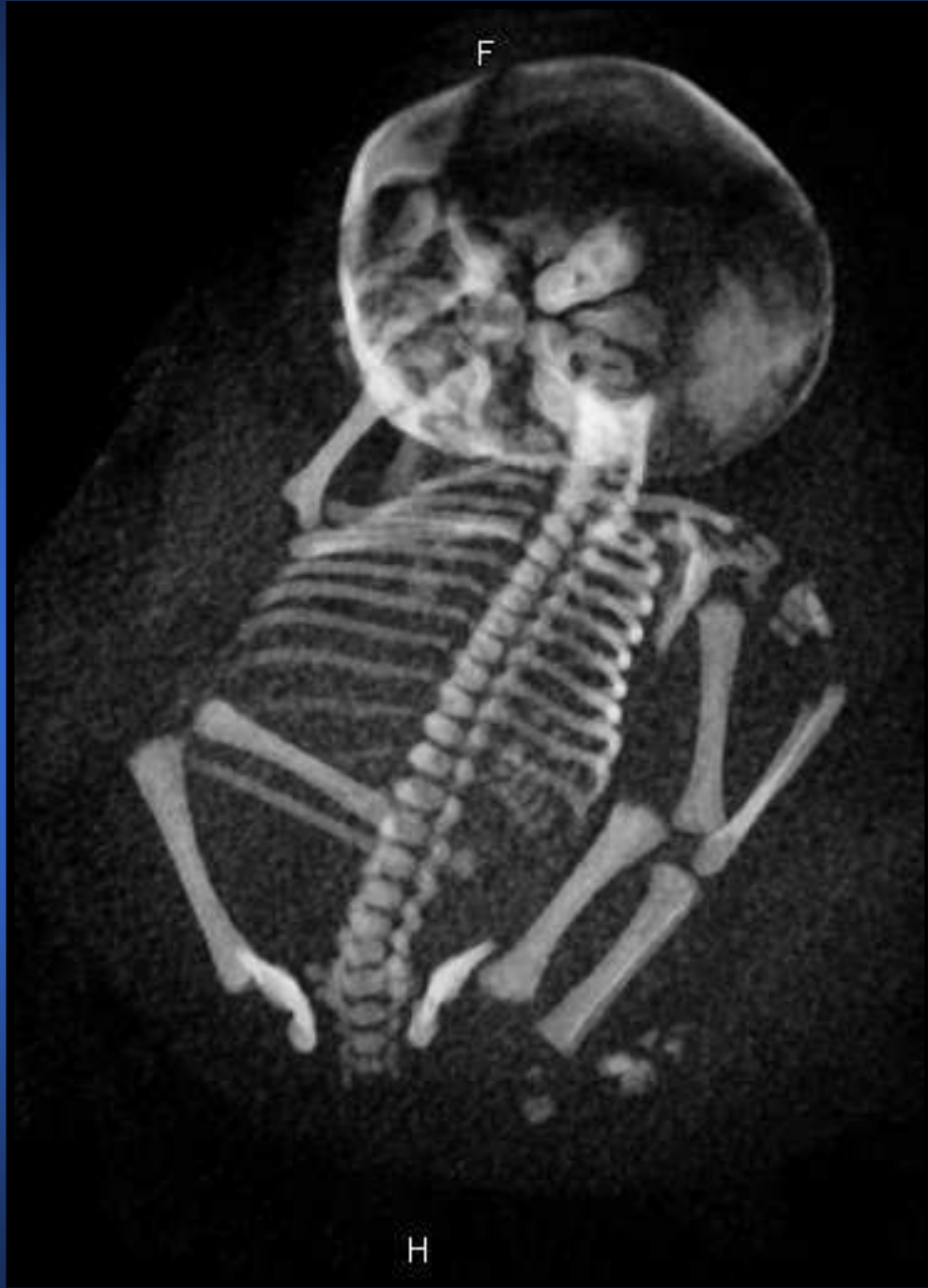Travail des images

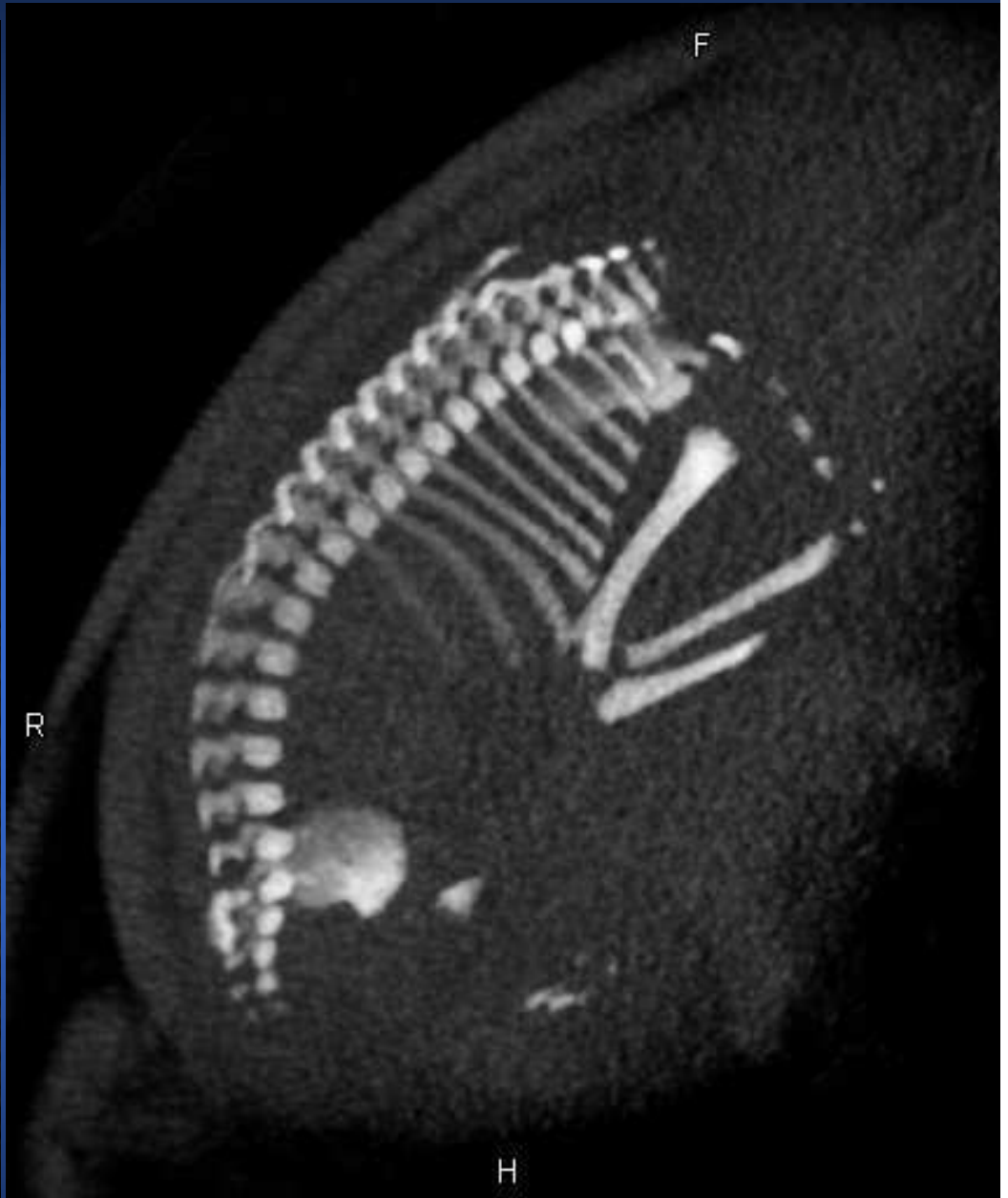
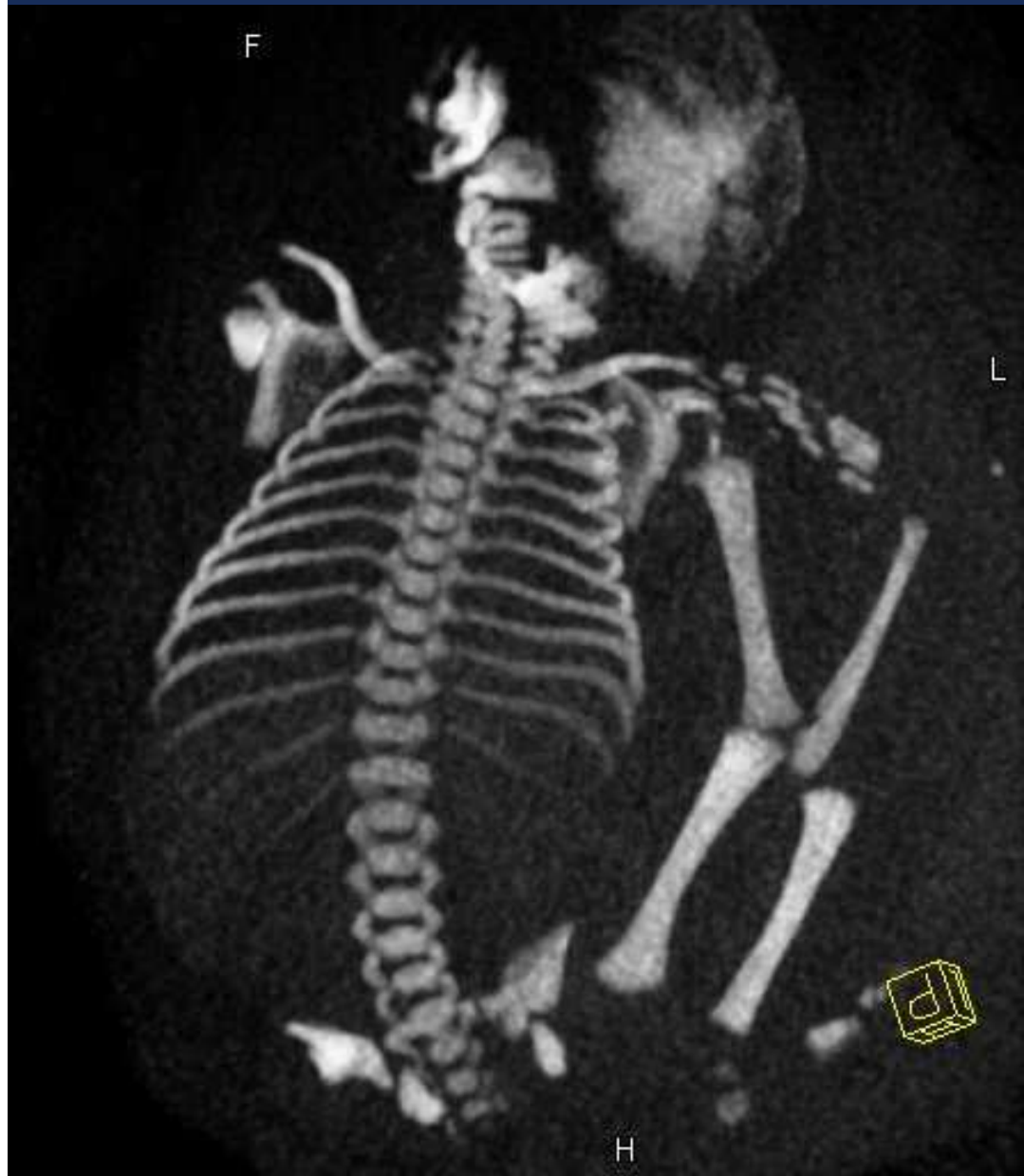
- Par le radiologue
- Travail dans le **volume**
- En rendu de volume (inspace)
- Travail des images en coupes pour d'éventuelles mesures

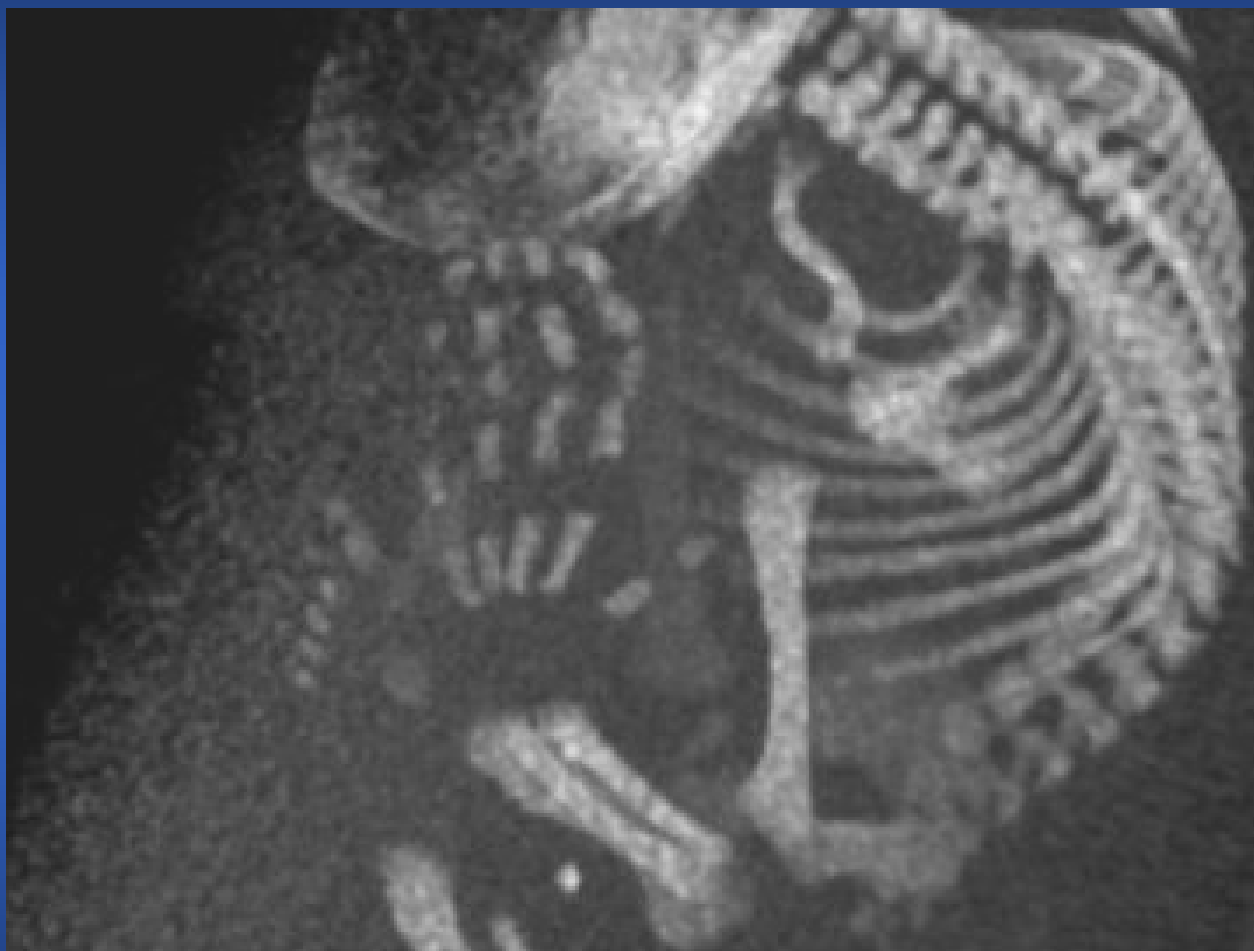


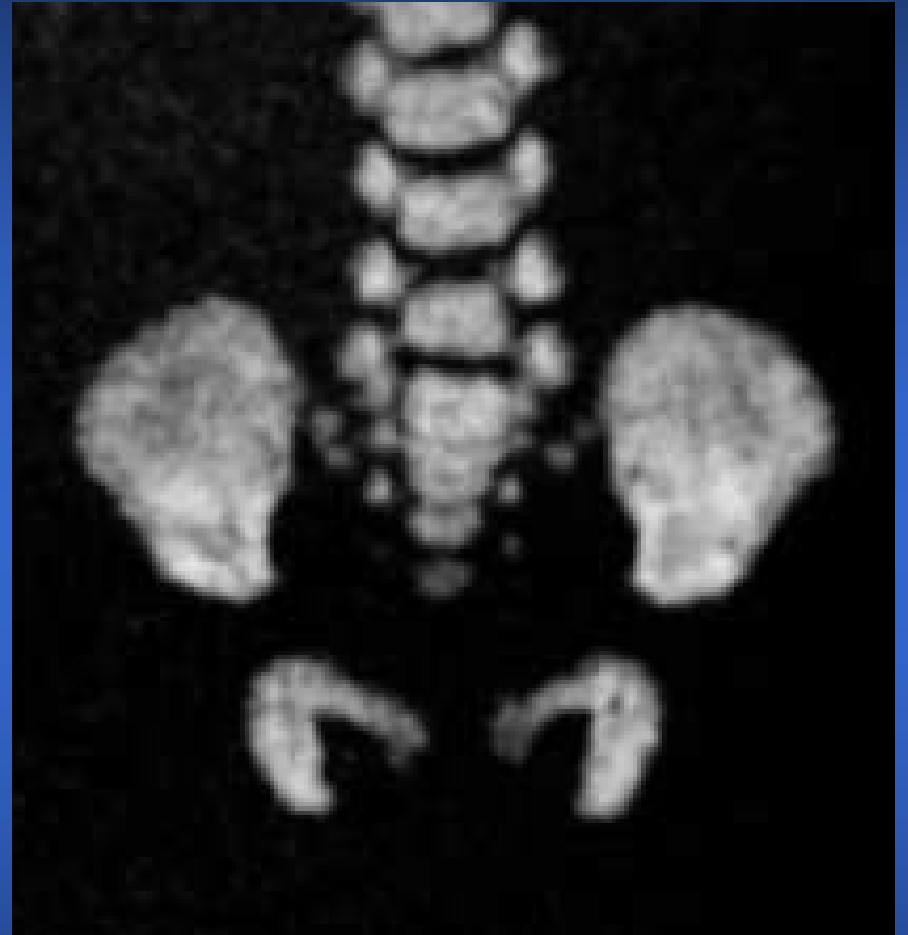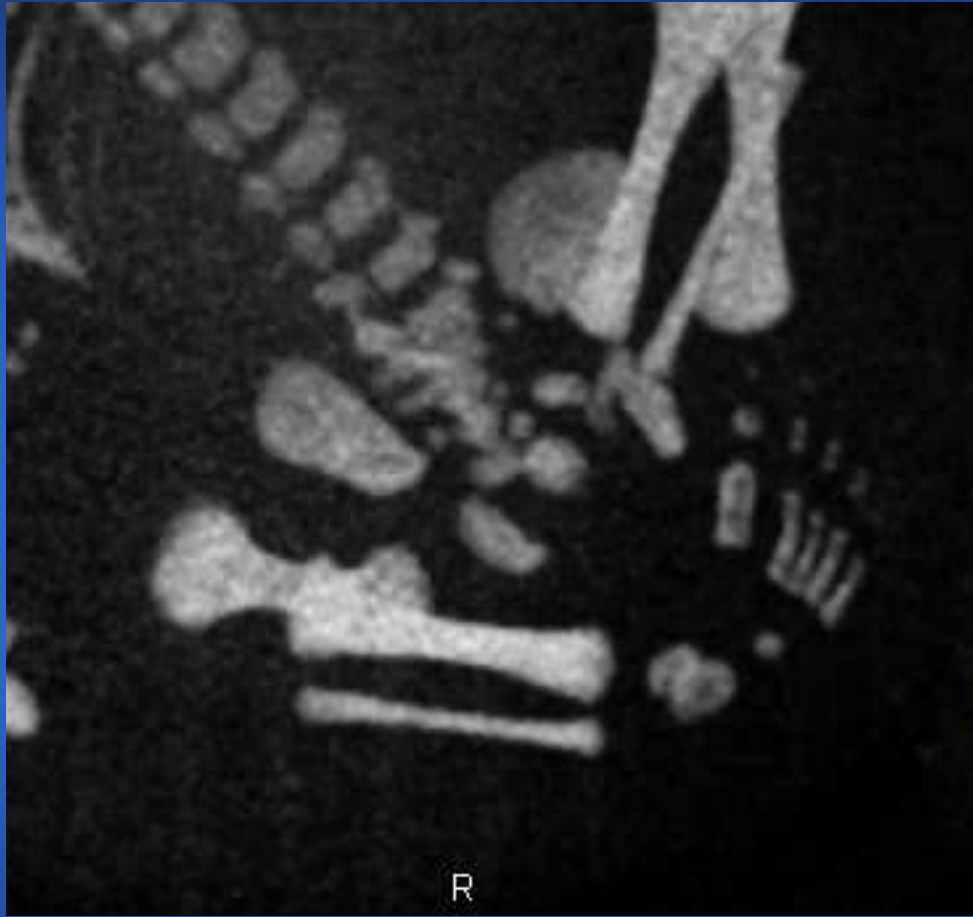
résultats

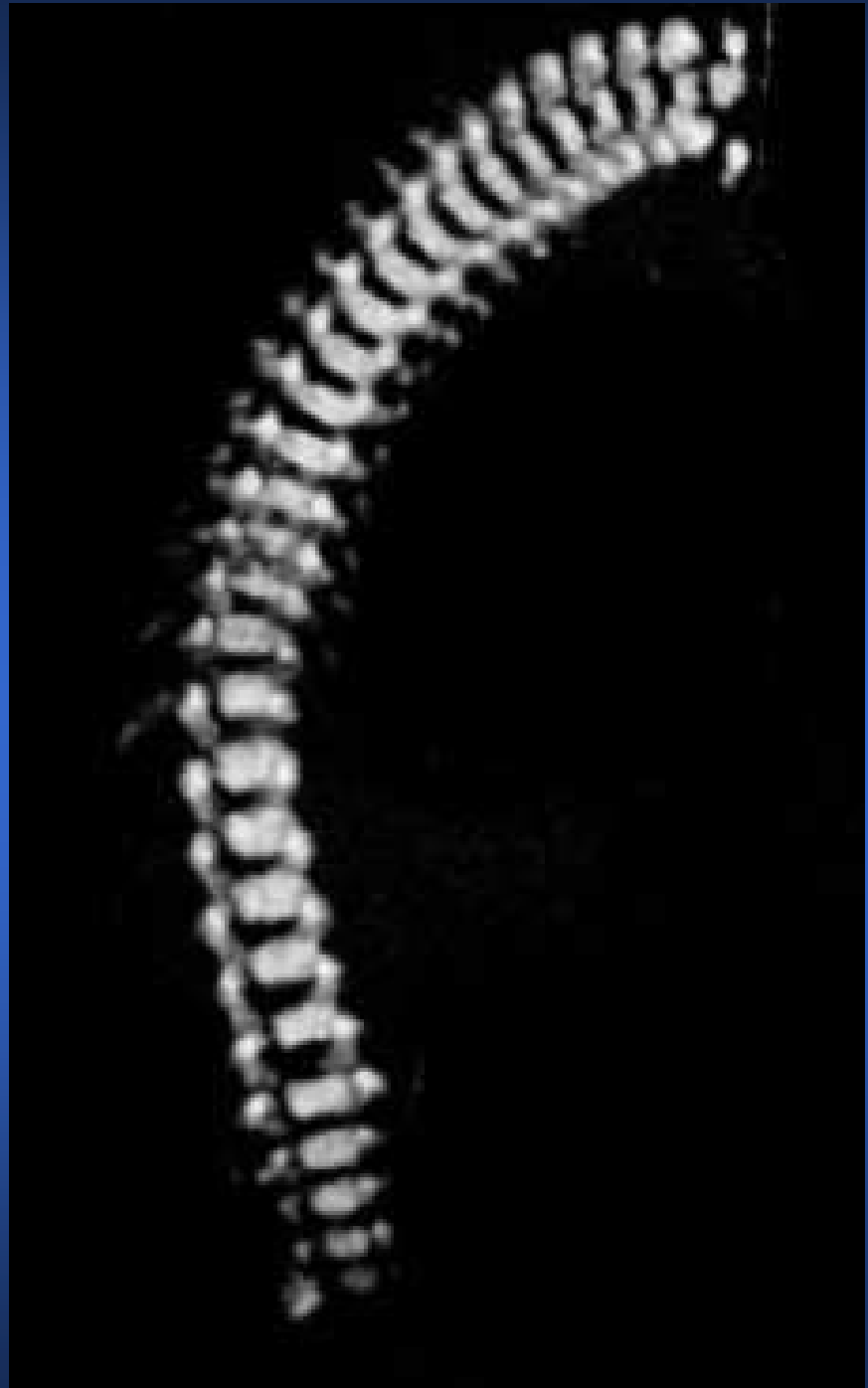
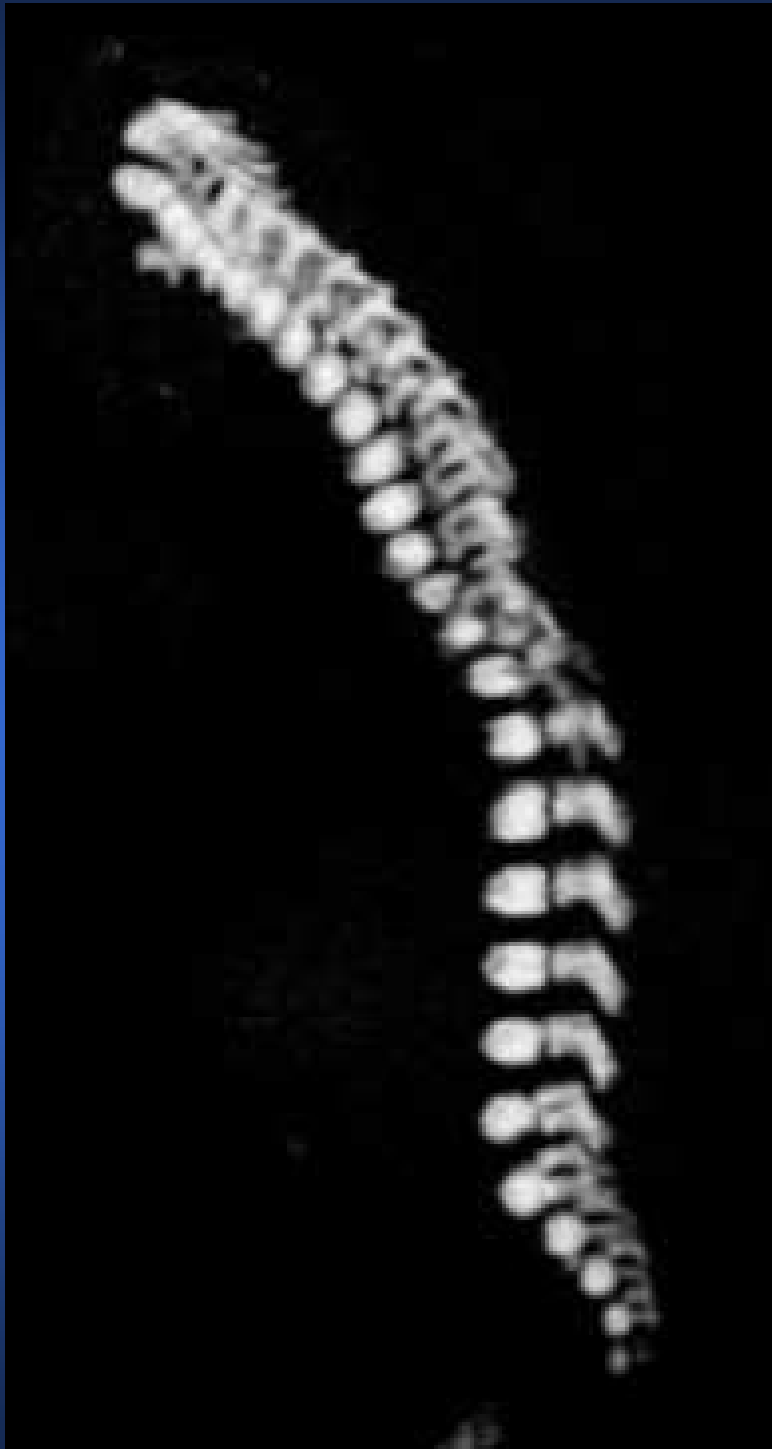
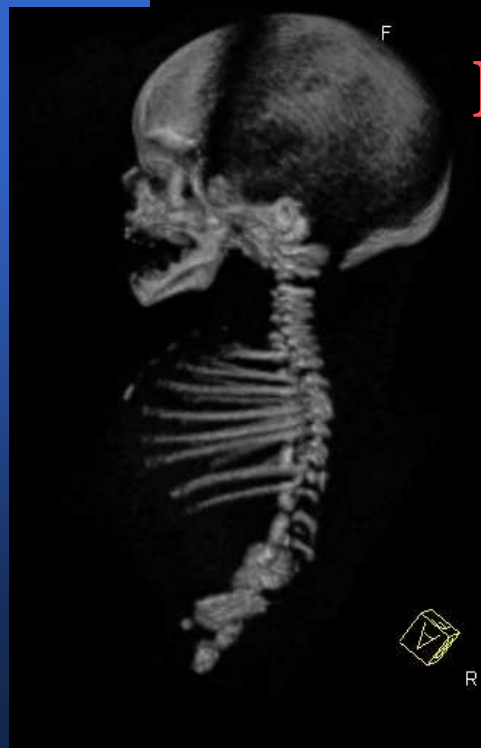


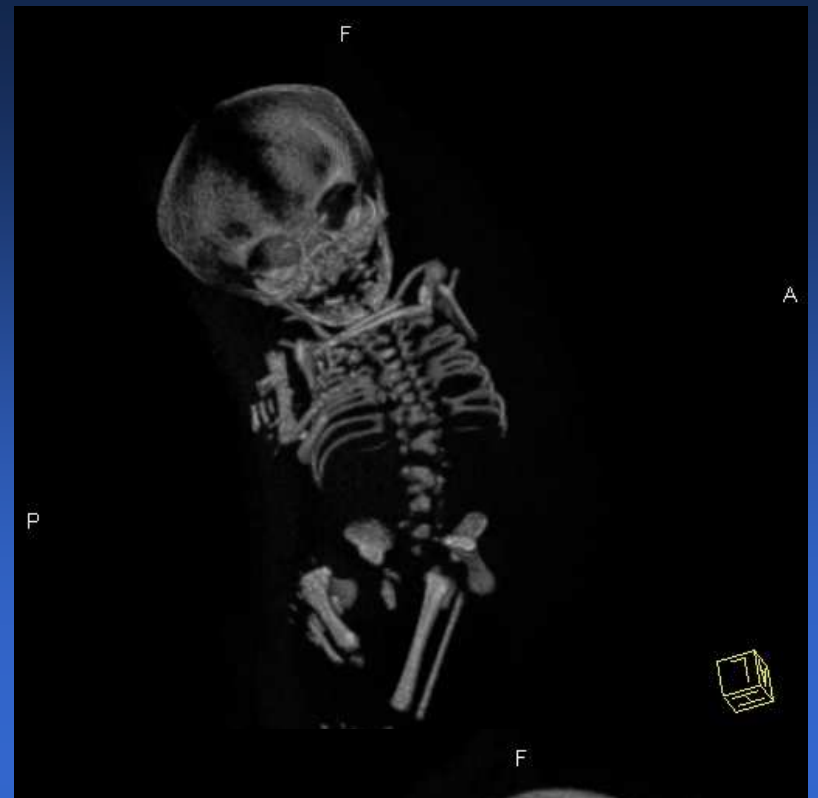
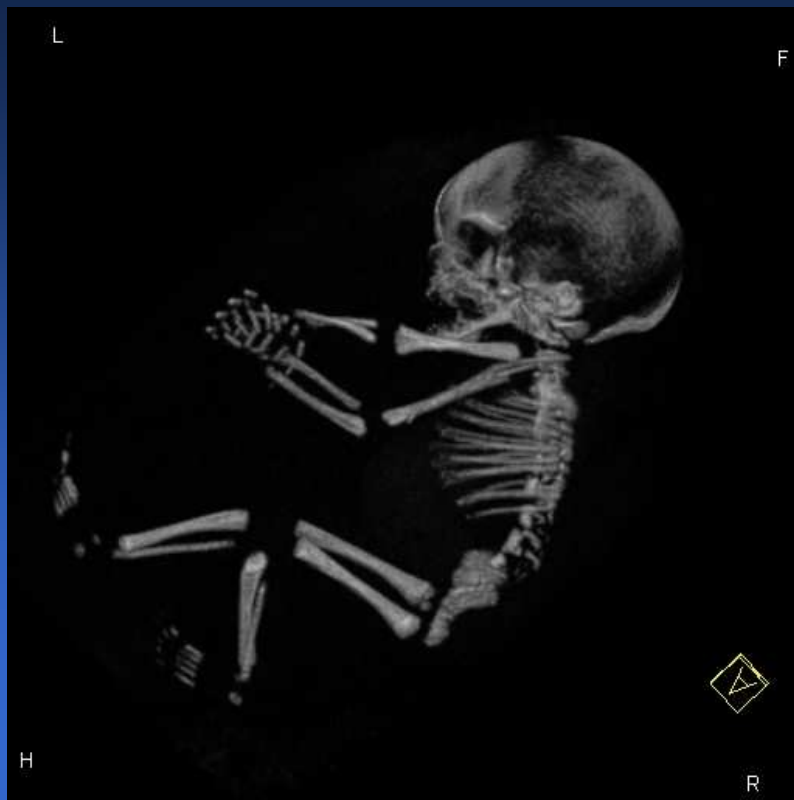




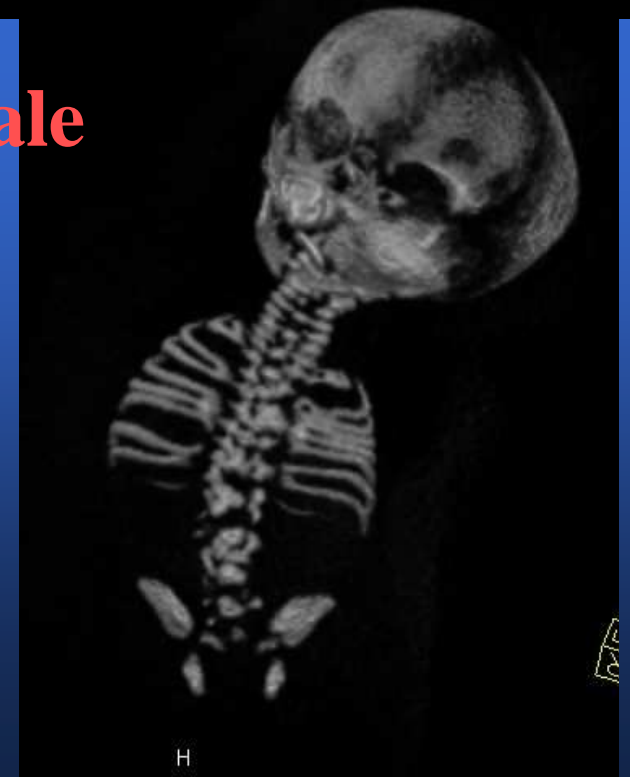



Dysostose spondylo-costale



conclusion

- **Indications : étude des pathologies osseuses**
- **Remplace le contenu utérin**
- **Irradiation = 2 contenus utérins**

scanner

- **Examen irradiant:**
- **préférer d'autres techniques**
 - **écho,**
 - **IRM**
- **Justification**
- **Optimisation**

scanner

- **Si utérus hors du faisceau primaire**
- **Pas de risque pour le foetus**

Scanner

- **Si utérés dans faisceau primaire**
- **Adapter la technique :**
 - **Pas de topogramme**
 - **Adapter les constantes**
 - **Une seule hélice**

Injection d'iode

La thyroïde fœtale capte l'iode après 11 SA

- **Injection toujours possible**
- **Avant 11 SA pas de conséquence**
- **Après 11 SA risque d'hypothyroïdie**
- **Suivi particulier à l'écho recherche du goitre**
- **Bilan thyroïdien après la naissance**

IRM

- Pas d'effet tératogène connu
- Toujours possible pendant la grossesse
- précaution : éviter au premier trimestre

Personnel travaillant à l'IRM

- Travail toujours possible
- Par précaution éviter de faire entrer les femmes enceintes au cours du premier trimestre

gadolinium

- **Passage placentaire**
- **Filtration par le rein fœtal**
- **Accumulation dans le liquide amniotique**

Injection de gadolinium

- **Non autorisée**
- **Pas d'anomalie signalée dans toutes les publications**
- **Pas d'Effet tératogène chez la femme
:effet chez le rat pour le**

Injection de gadolinium

- **Préférer**
- **Signaler**
- **Suivi normal de la grossesse**