

ECHOGRAPHIE TRANSFONTANELLAIRE

**Dr C Sembély-Taveau
CHU Tours**

PLAN

Généralités

Technique

Anatomie

Indications

Principales pathologies

ECHOGRAPHIE CEREBRALE : GENERALITES

- **Simple**
- **Transportable au lit ...*ou couveuse***
- **Reproductible**
- **Informative (à peu près égale à CT)**
- **Inférieure à IRM**

EXAMEN DE DEPISTAGE ET DE SUIVI

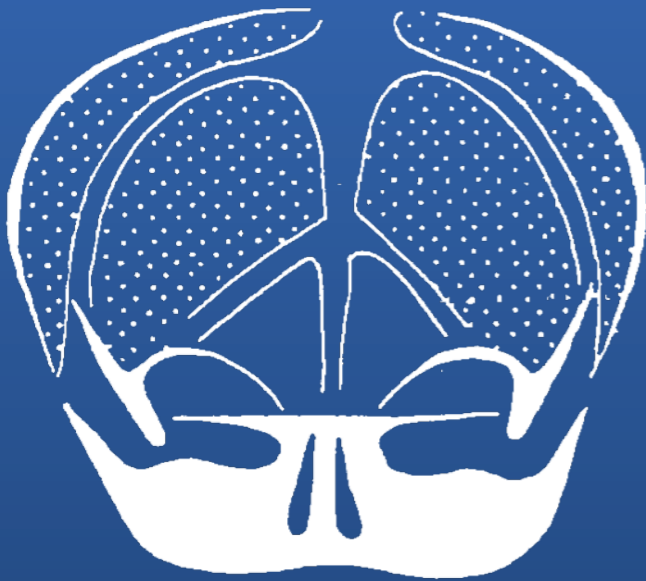TECHNIQUE

- **Sondes**
 - sectorielle 5 à 10 MHz
 - angle d'ouverture !!
 - linéaire 7-15 MHz
- **Étude bi dimensionnelle**
- **Doppler**

LES FONTANELLES ET SUTTURES

- **Voie d'abord**

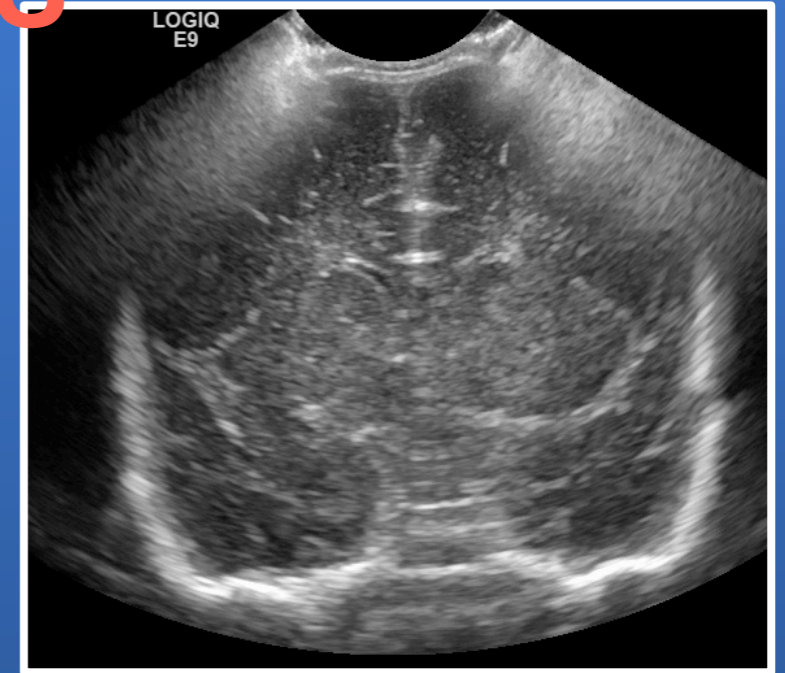
- **antérieure +++**
- **postérieure**
- **latérale**



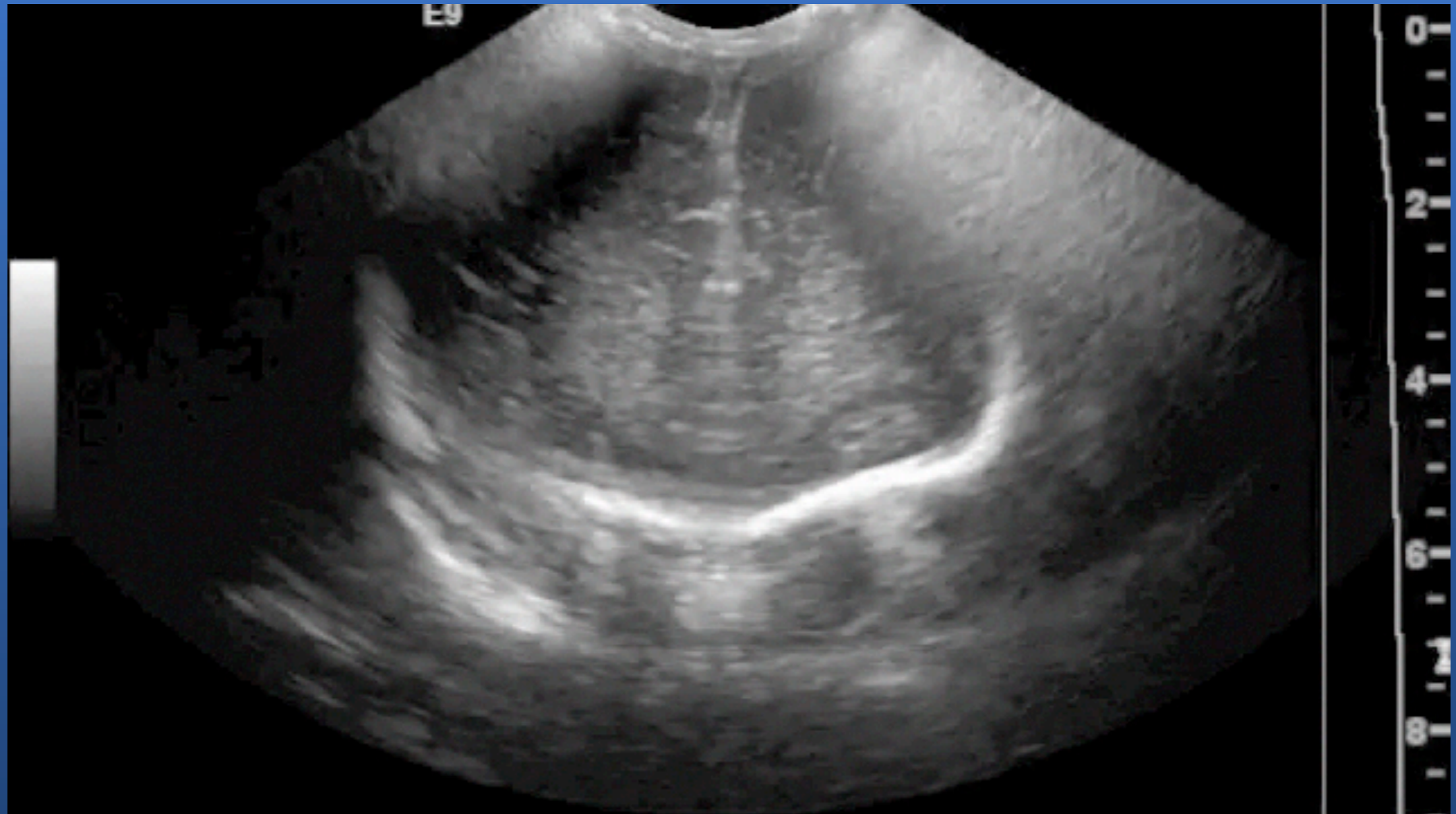
- **1ère année de vie**

BALAYAGE CORONAL: 5 COUPES FRONTALES

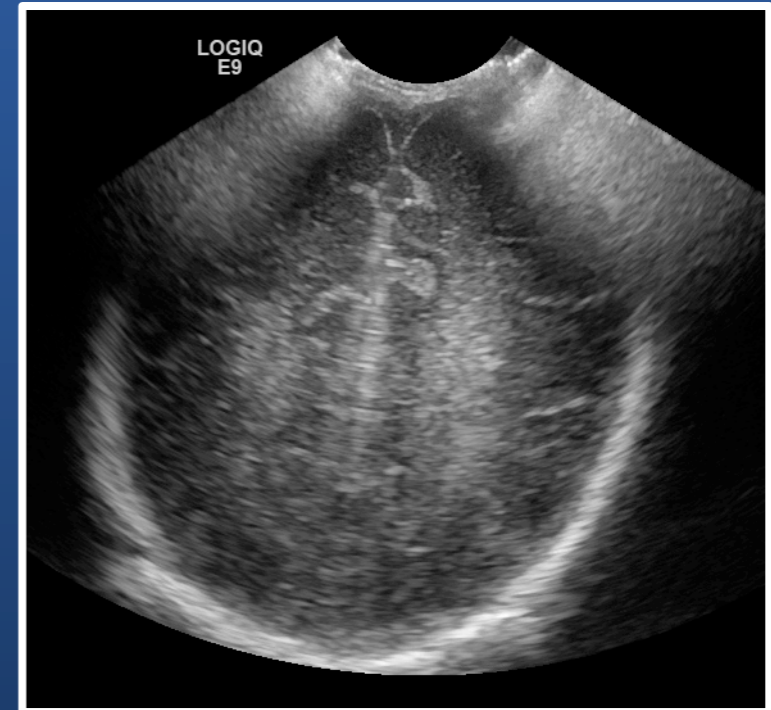
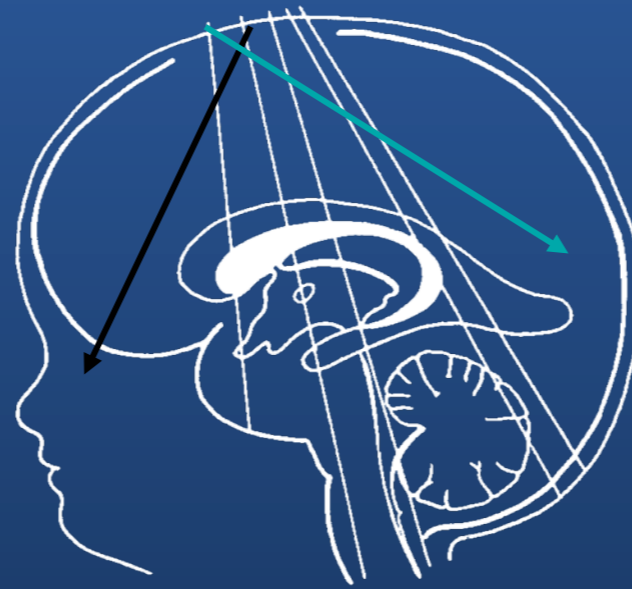
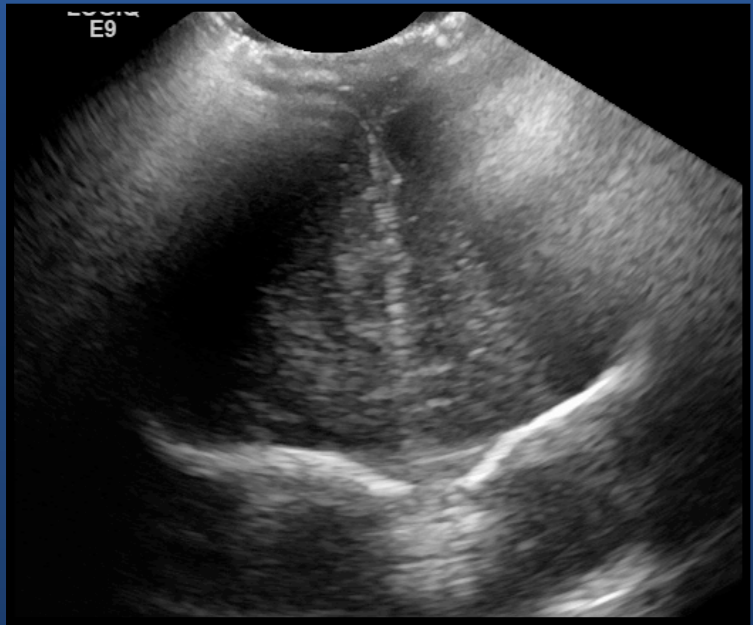
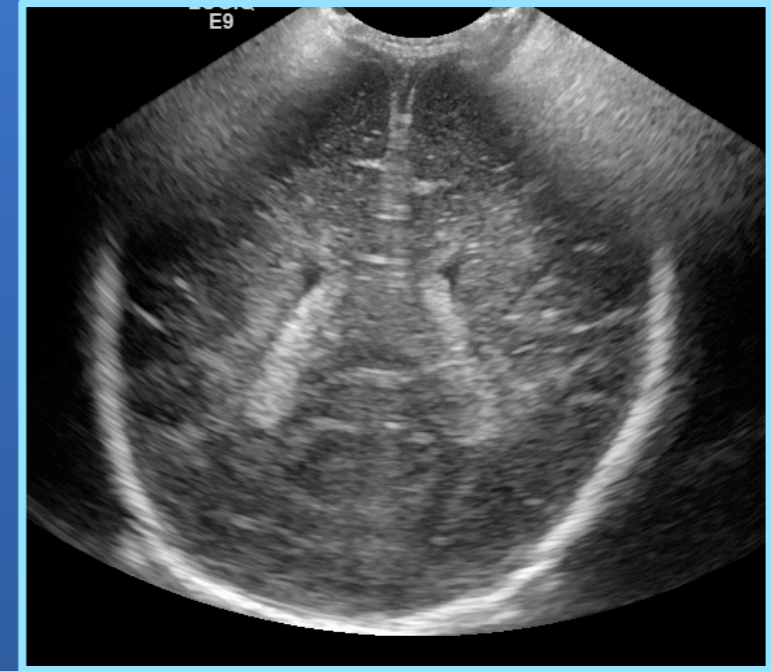
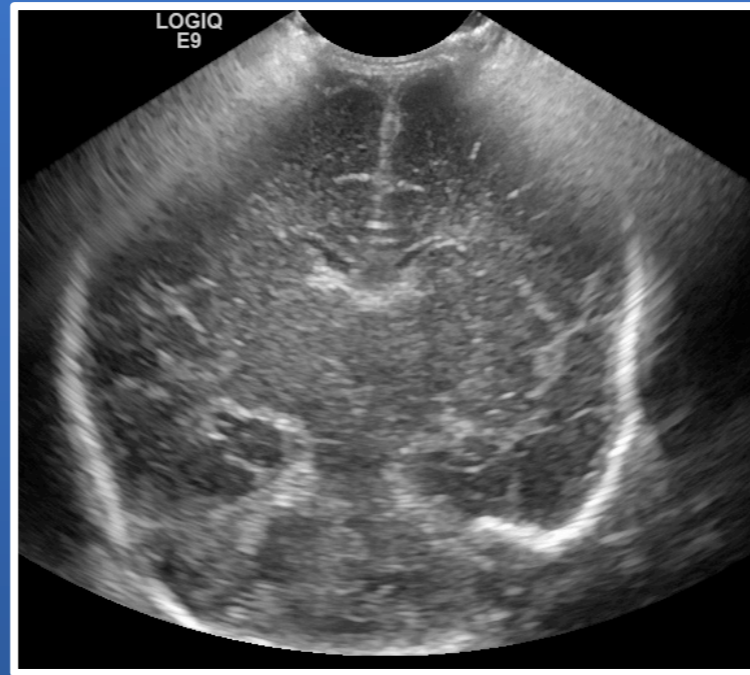
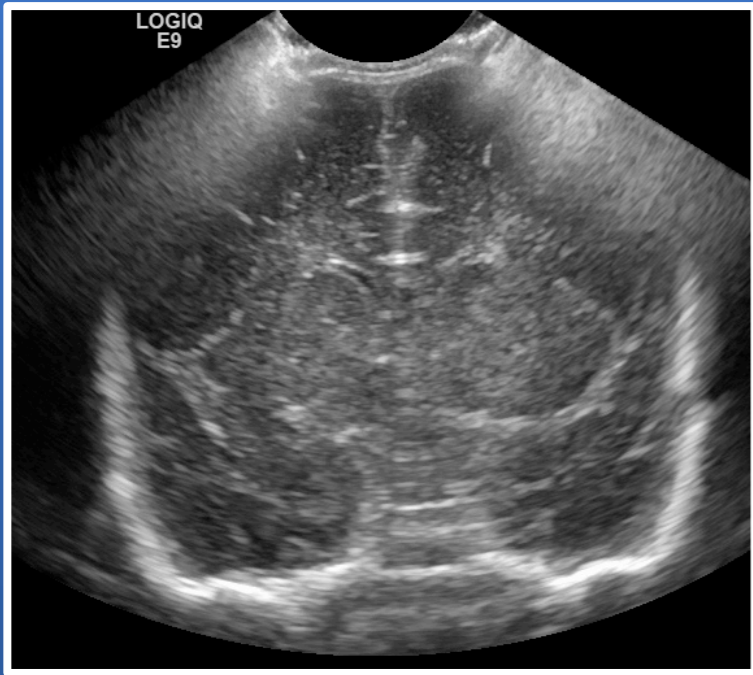
- **Antérieure : lobes frontaux**
- **Ventriculaires :**
 - Cornes frontales
 - Ventricules latéraux et foramen de Monro
 - Cornes occipitales et carrefour
- **Postérieure : lobes occipitaux**



BALAYAGE CORONAL

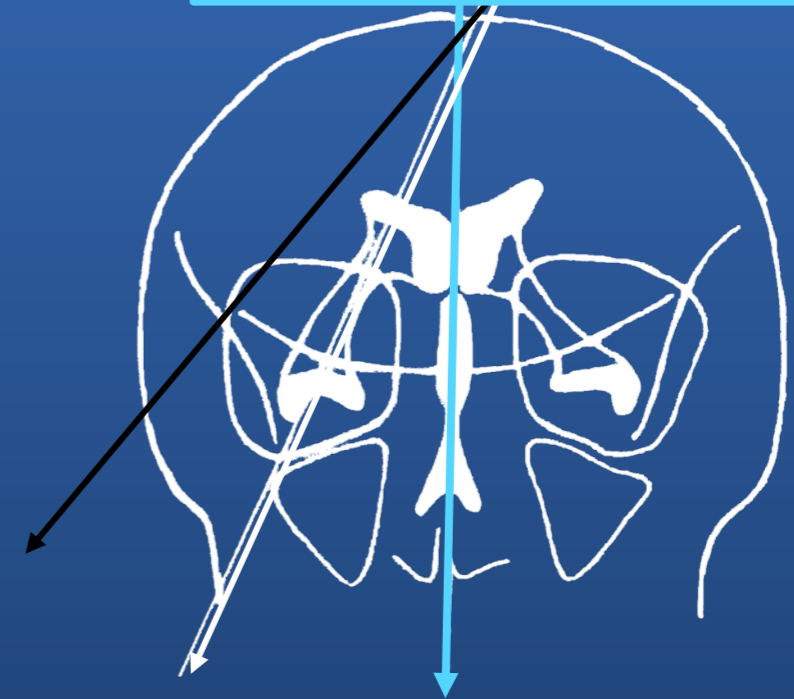
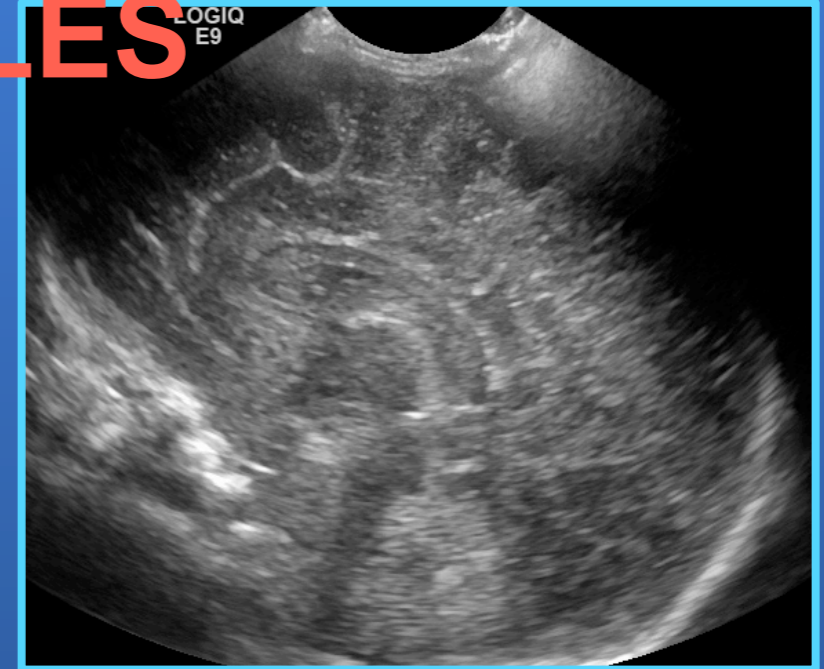


5 COUPES FRONTALES

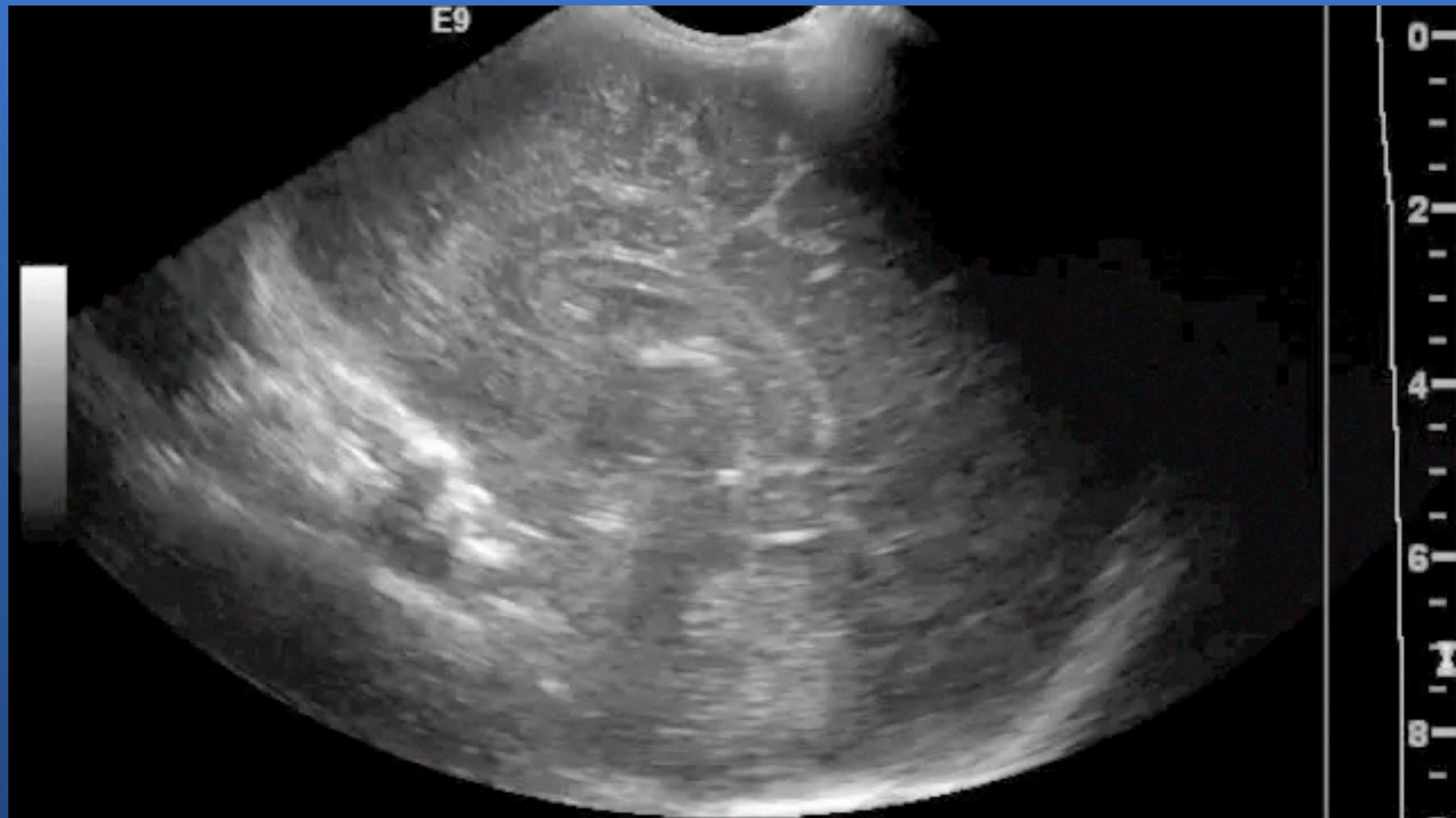


BALAYAGE SAGITTAL : 5 COUPES SAGITTALES

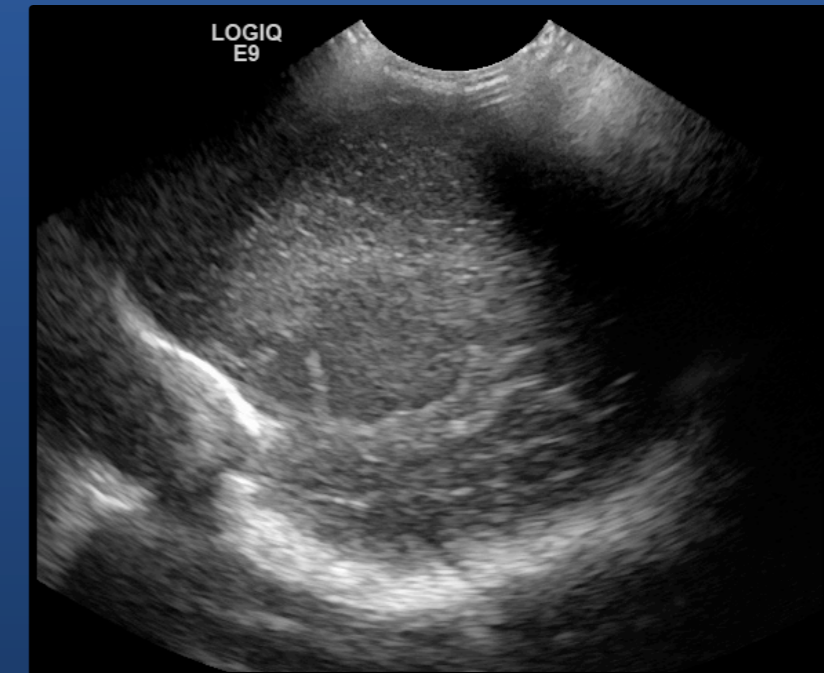
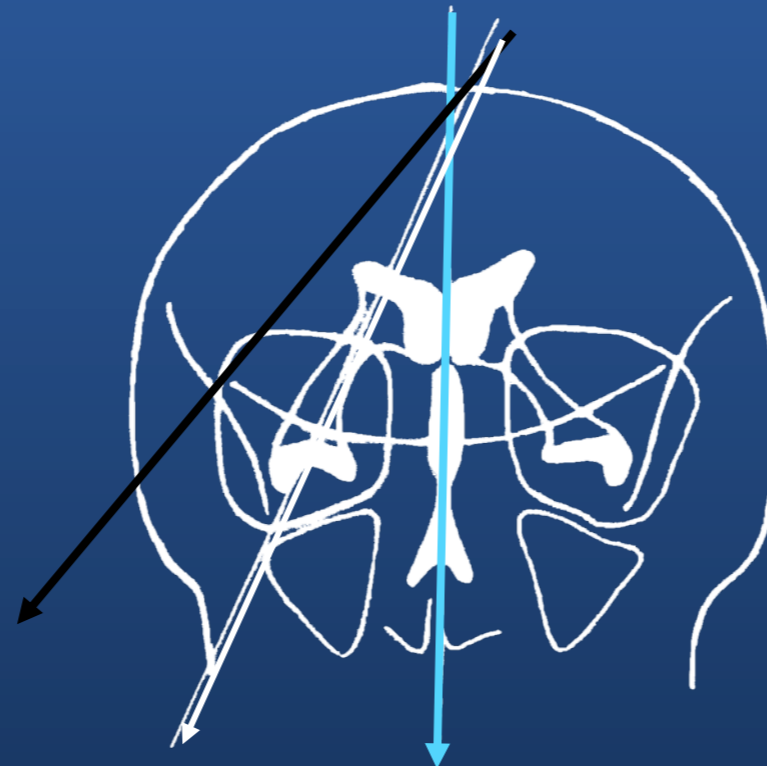
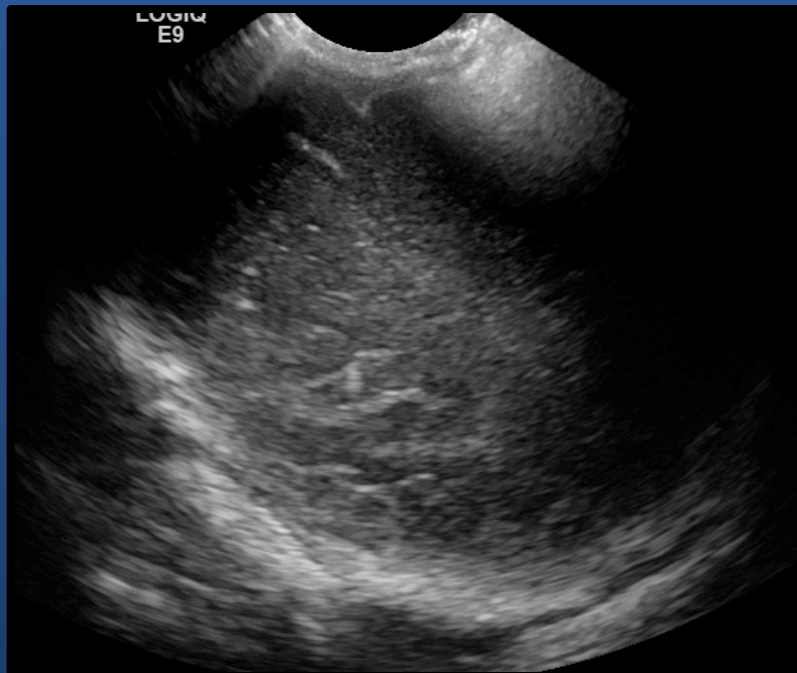
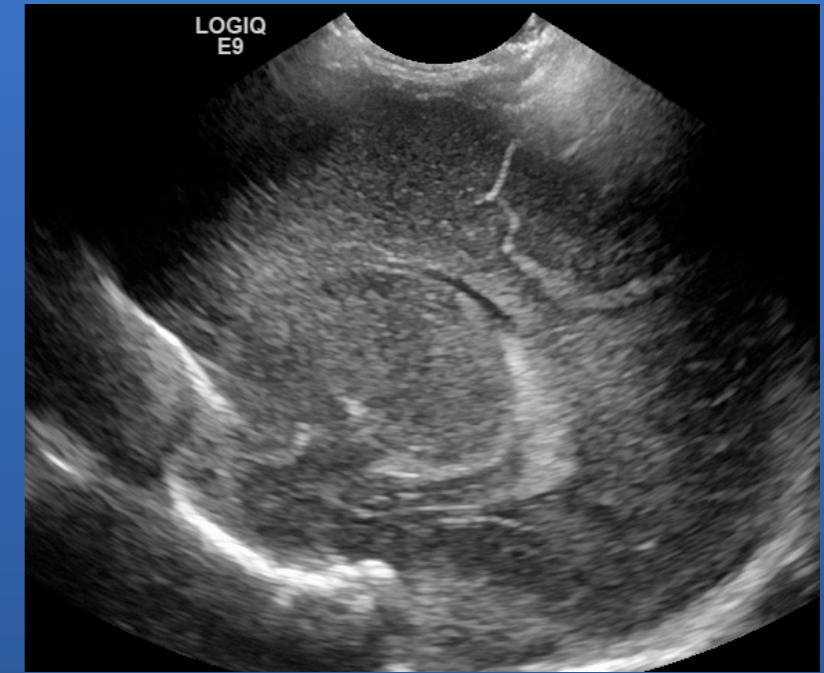
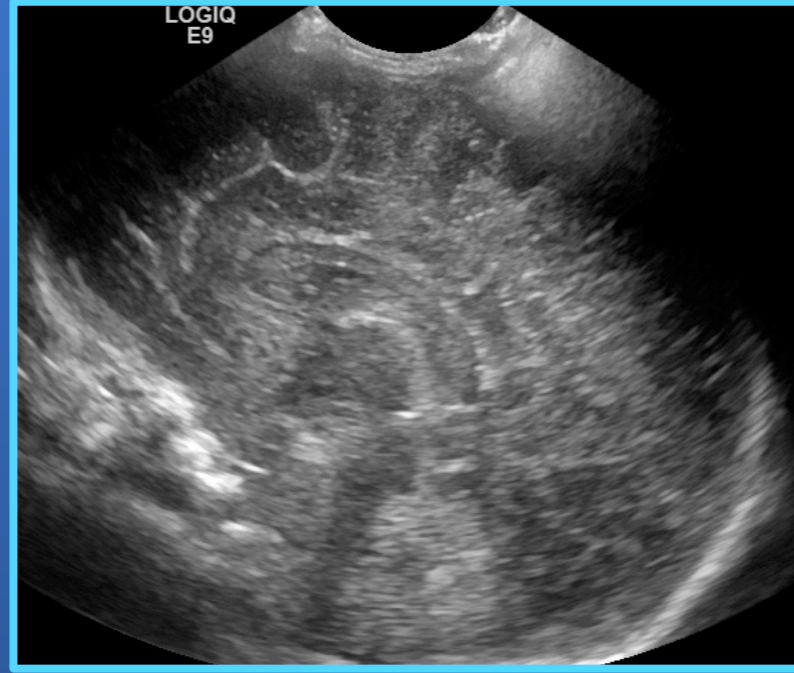
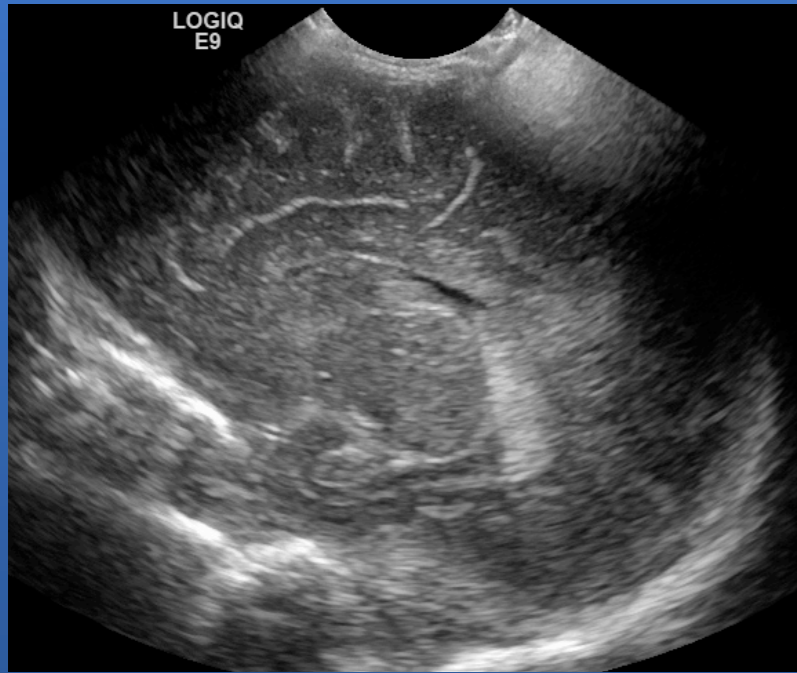
- **Sagittale médiane**
- **Parasagittales obliques (D et G)**
 - **Ventricule latéral**
 - **Vallée sylvienne**



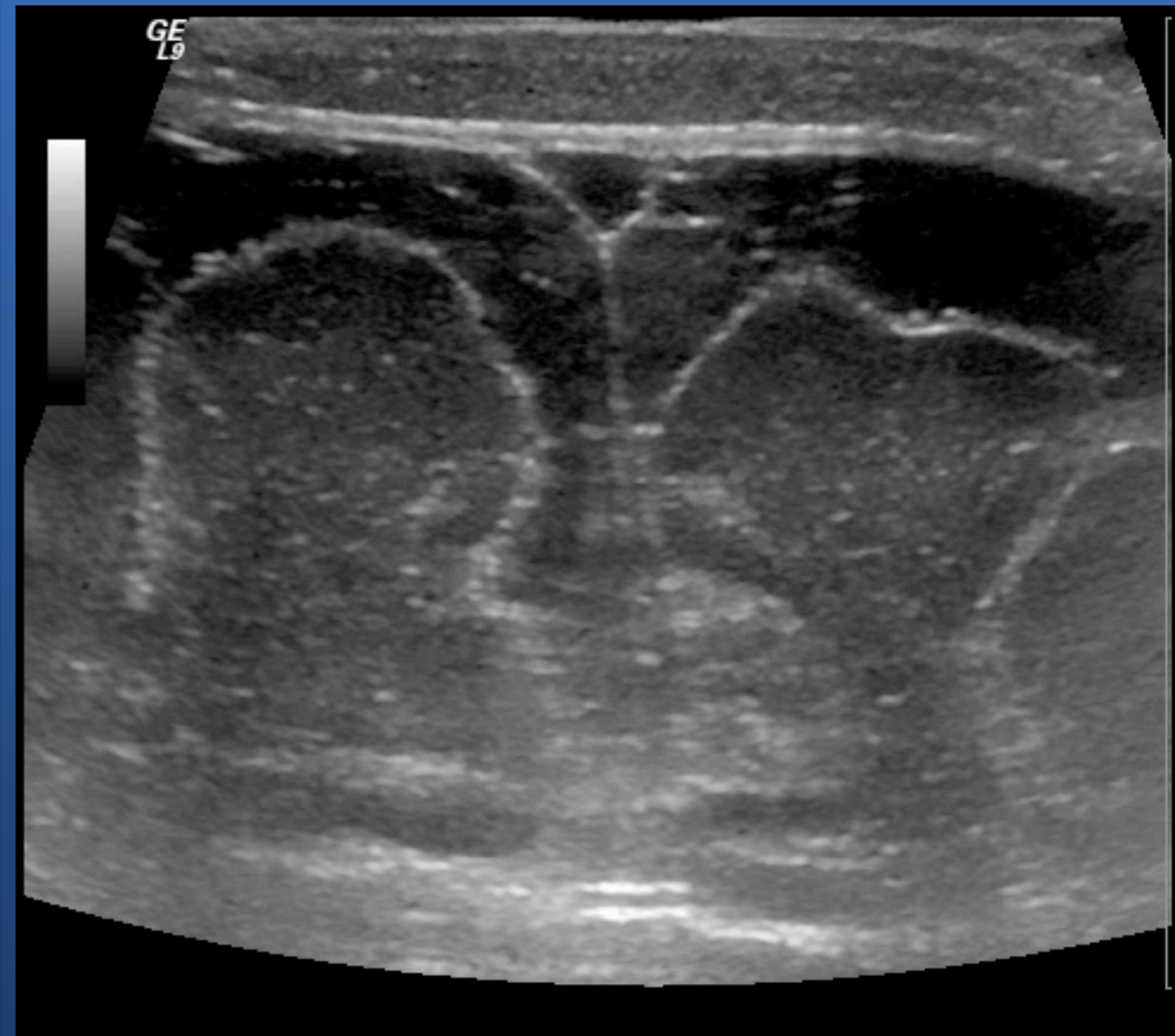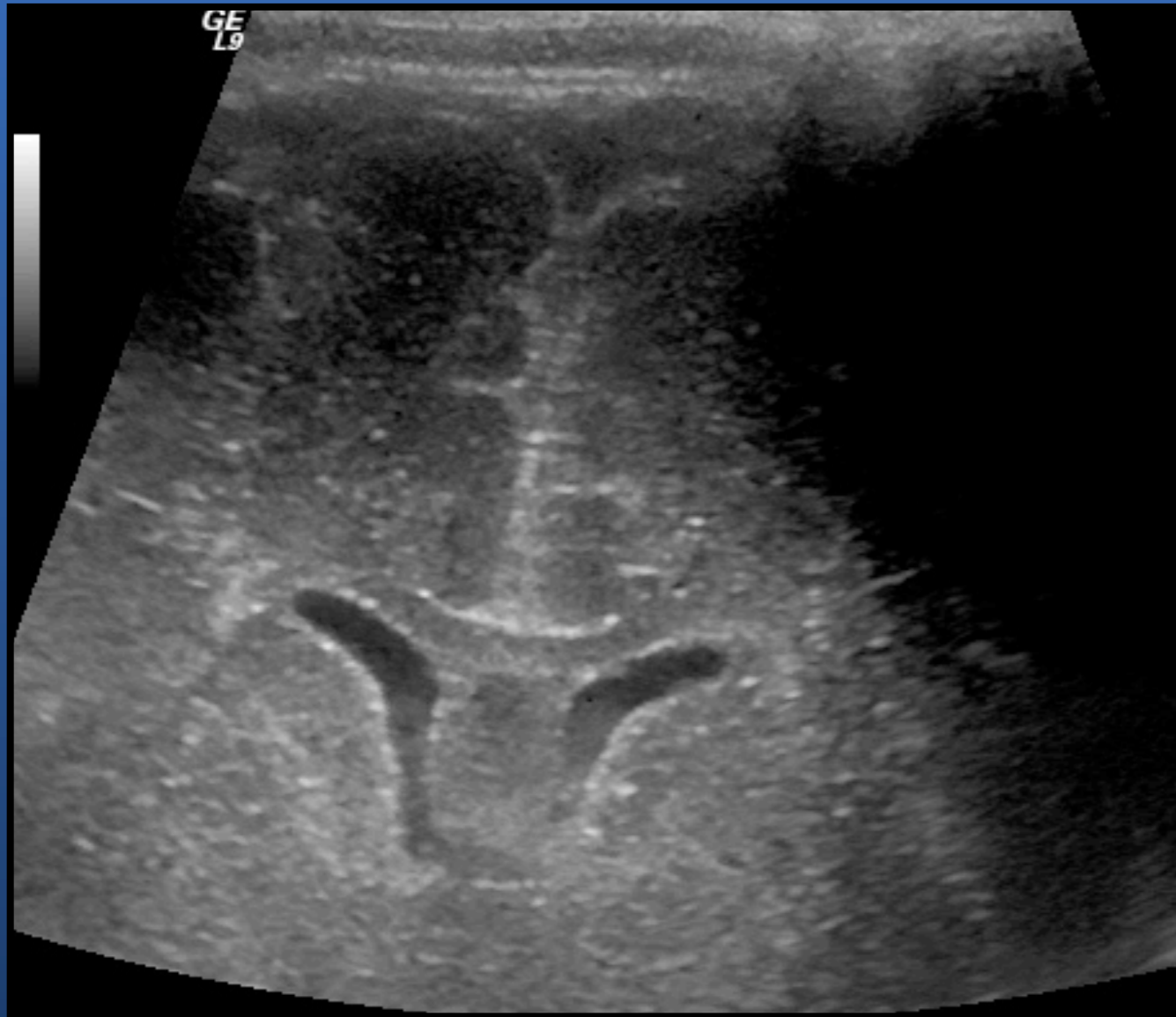BALAYAGE SAGITTAL



5 COUPES FRONTALES

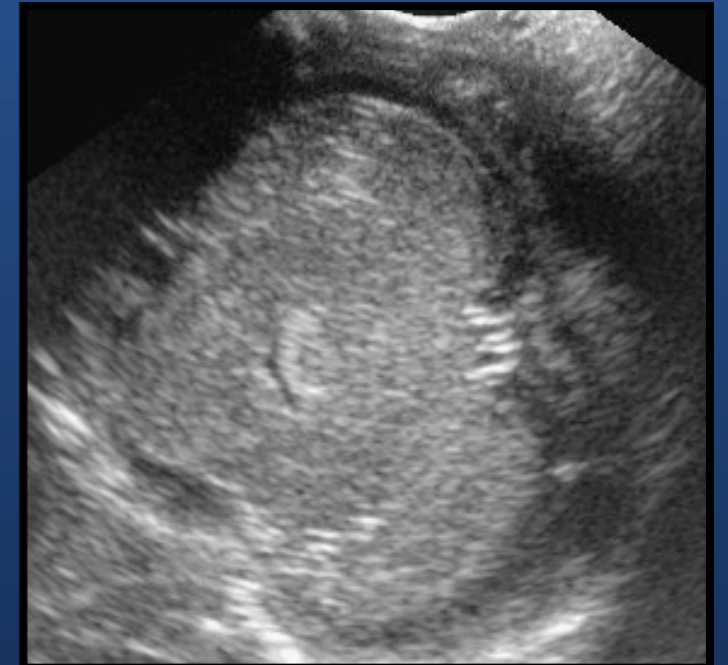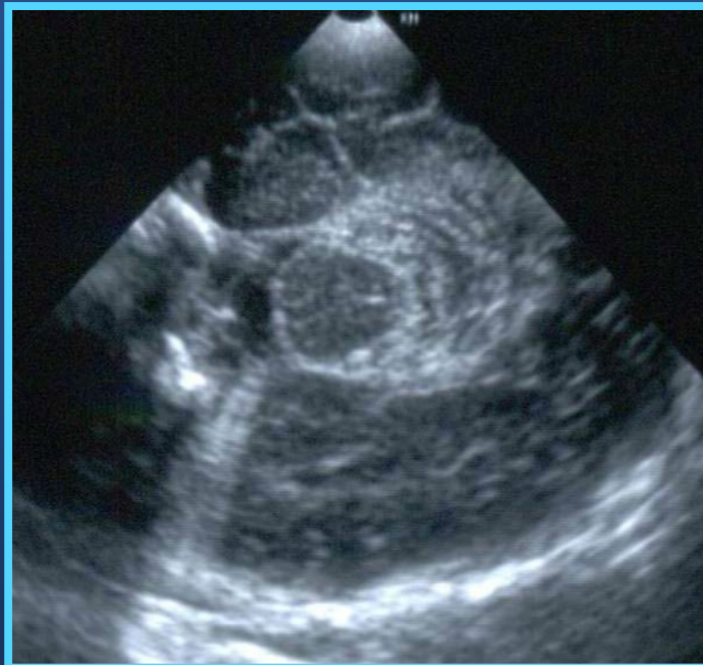



Sonde superficielle



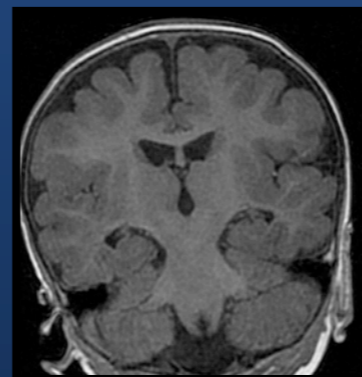
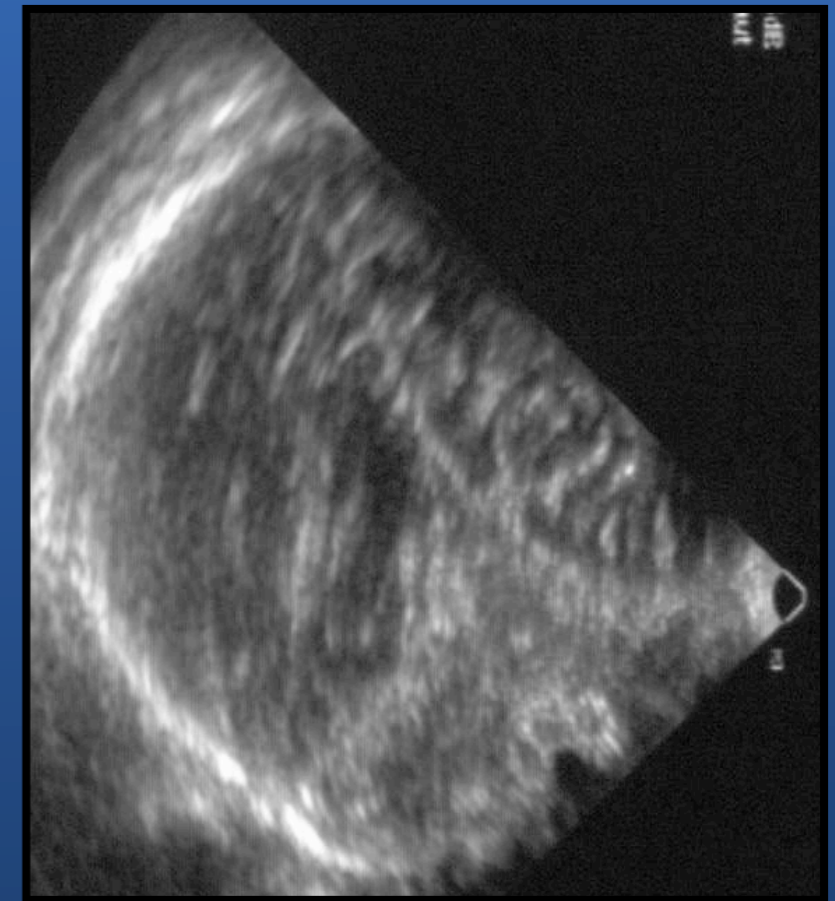
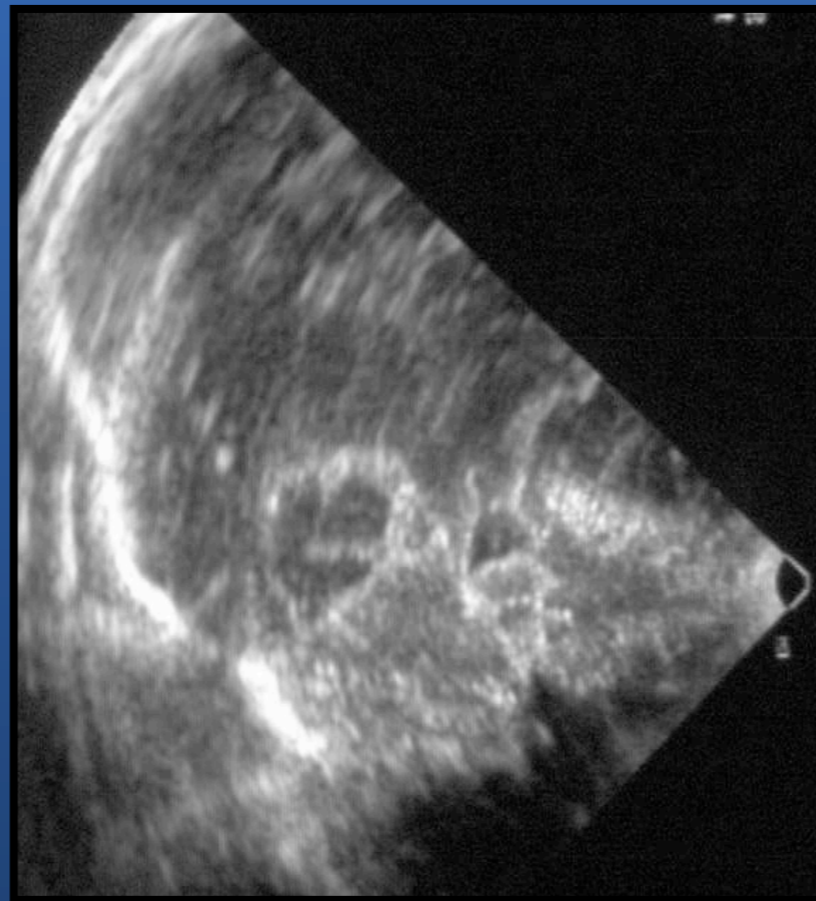
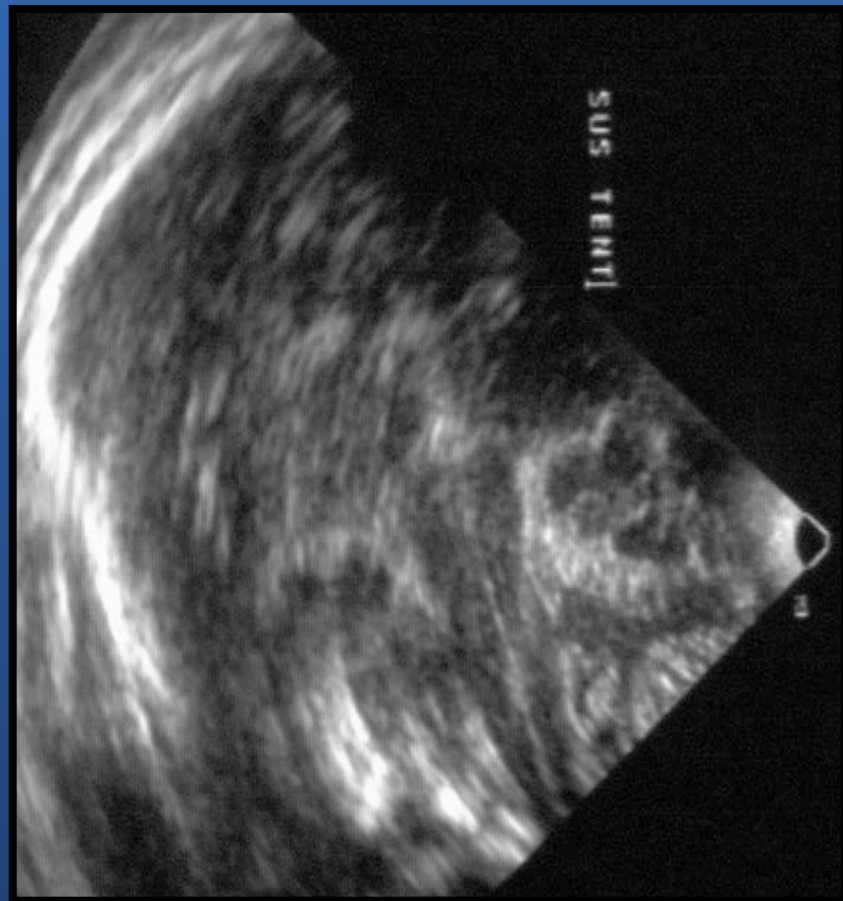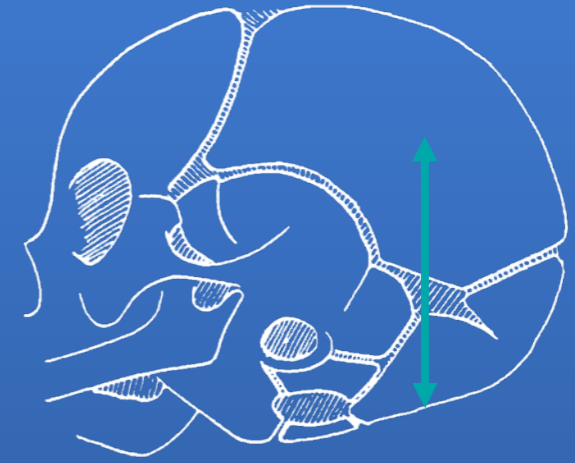
AUTRES VOIES D'ABORD

- Médiante fontanelle postérieure
 - coupes axiales et sagittales
 - sinus long. post
 - cornes occipitales
- Latérale temporale
 - Willis
- Latérale pariéto-occipitale
 - fosse postérieure

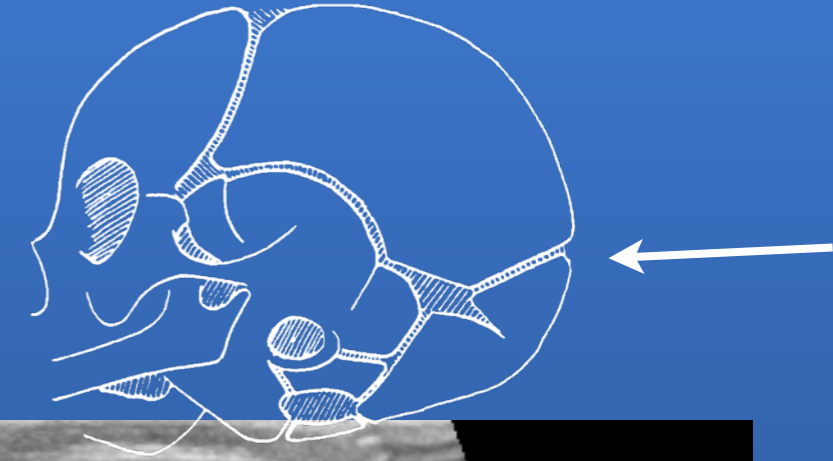

Voie postéro-latérale

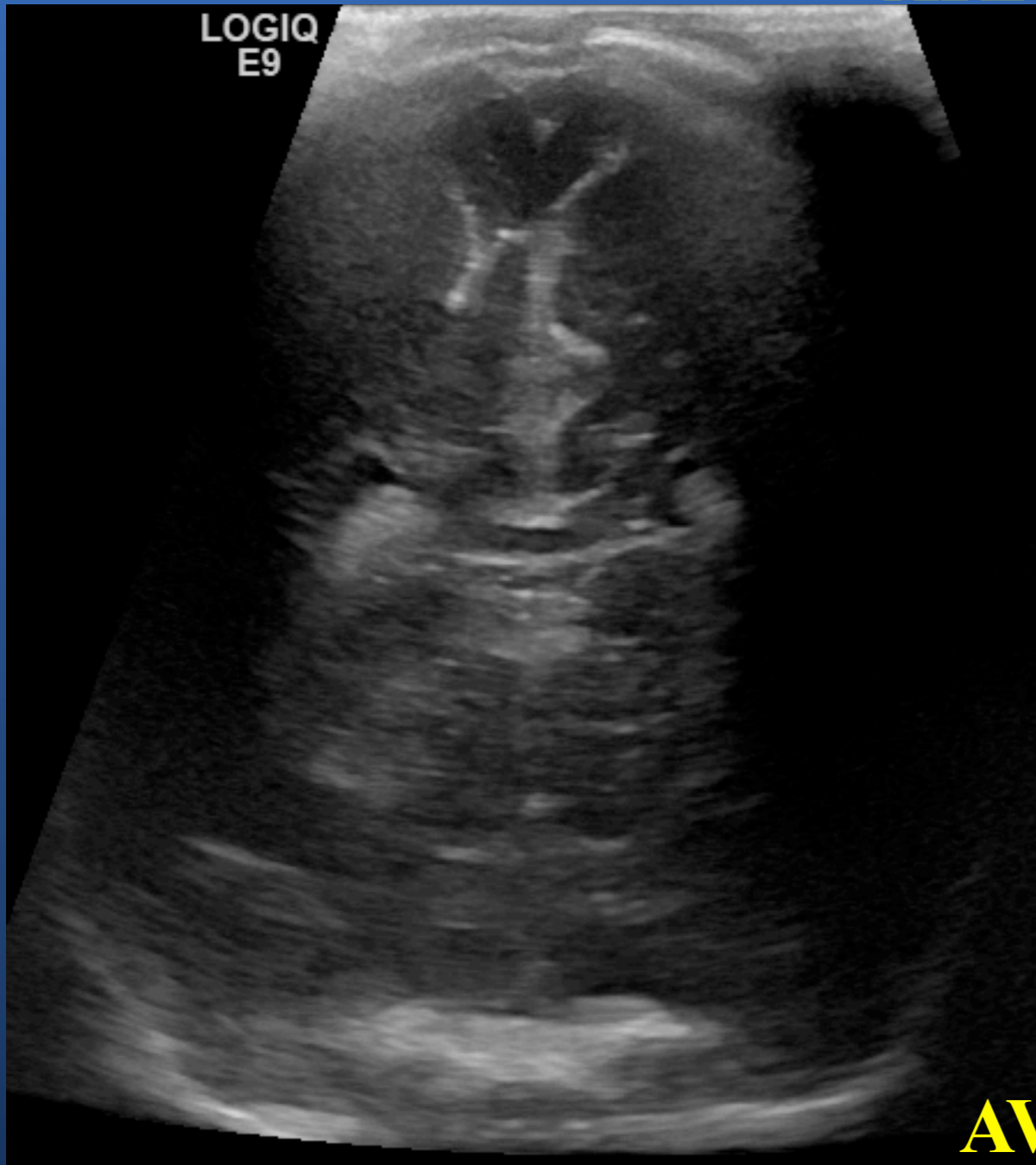coupes coronales



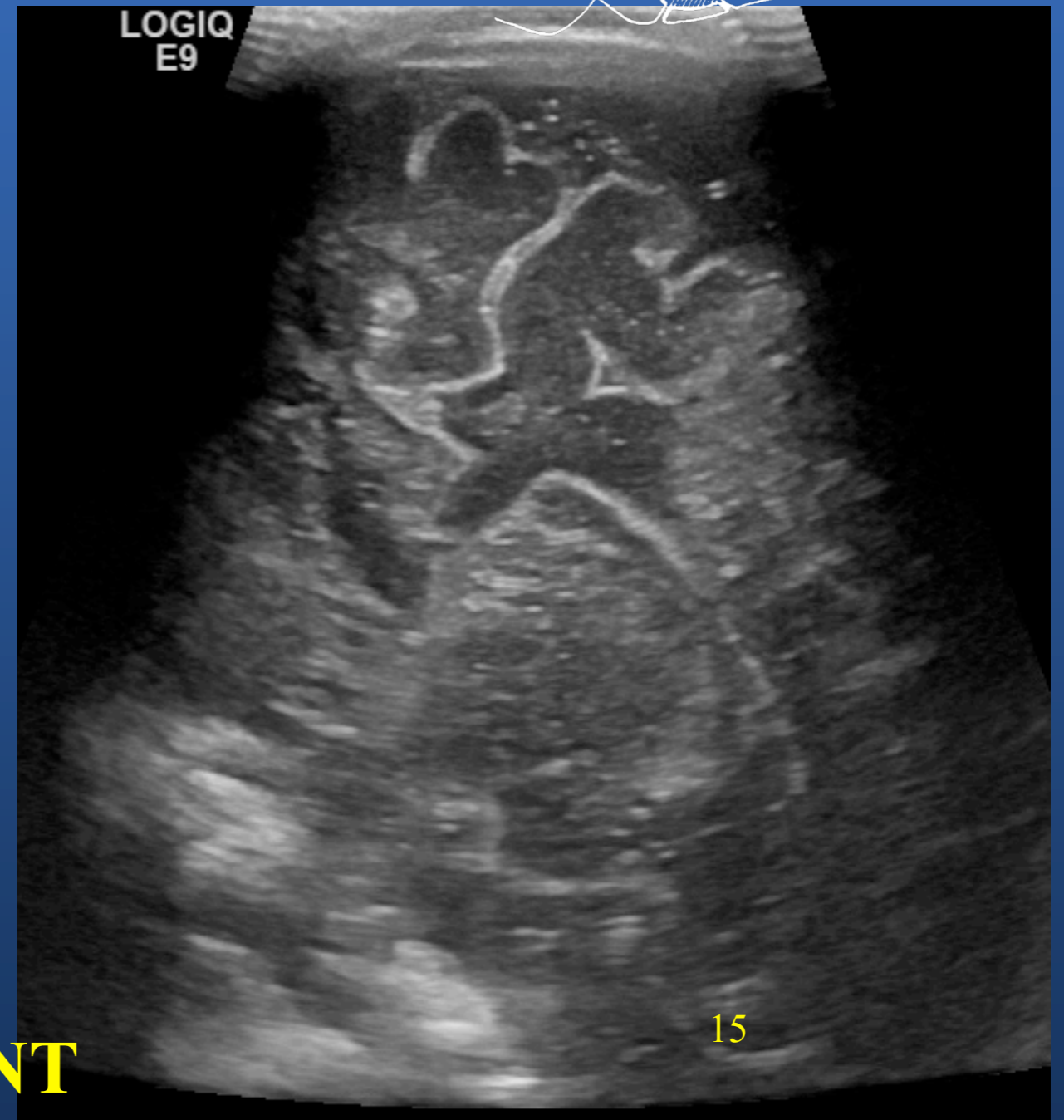
VOIE POSTERIEURE



ARRIERE



AVANT

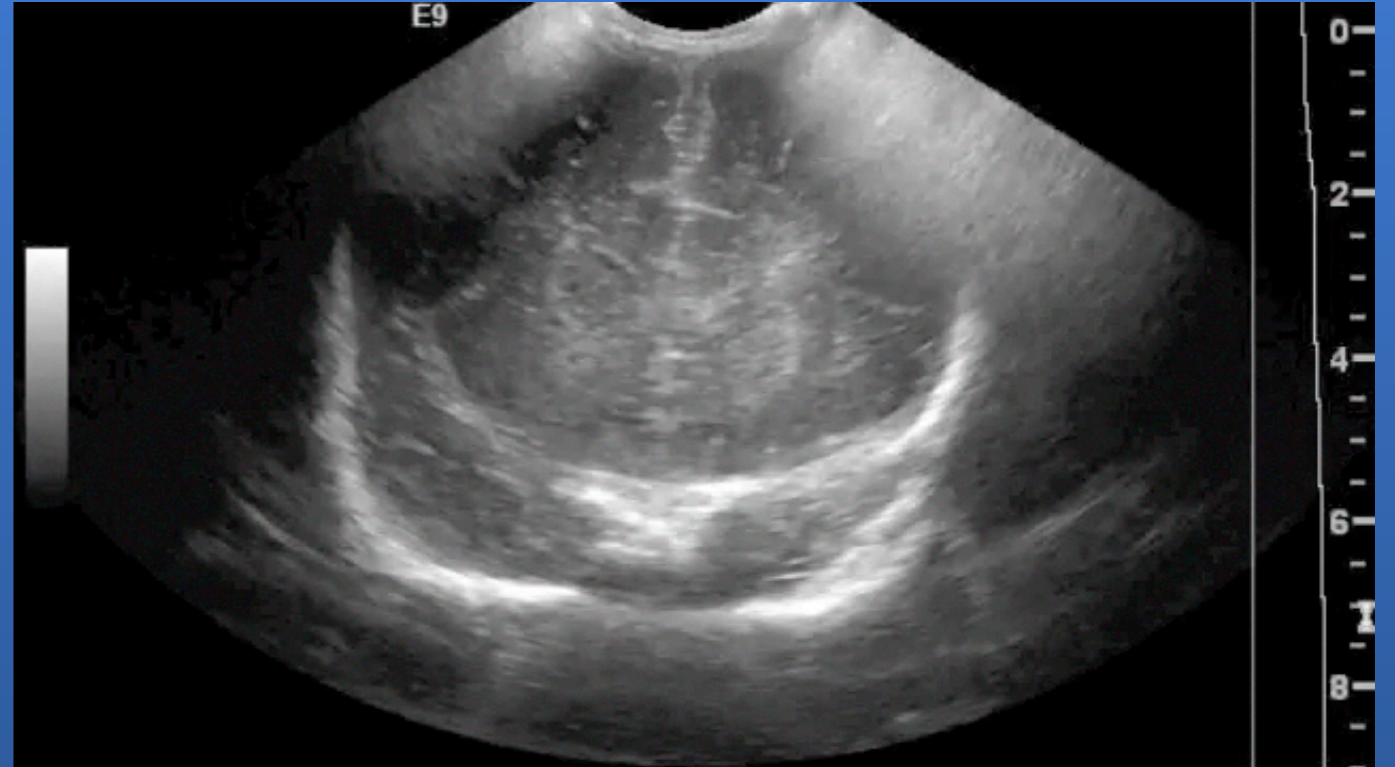


15

ARTERES CEREBRALES

- **Bidimensionnel :**
 - **Lumière rarement visible**
 - **Gros troncs : images pulsatiles dans le LCR**

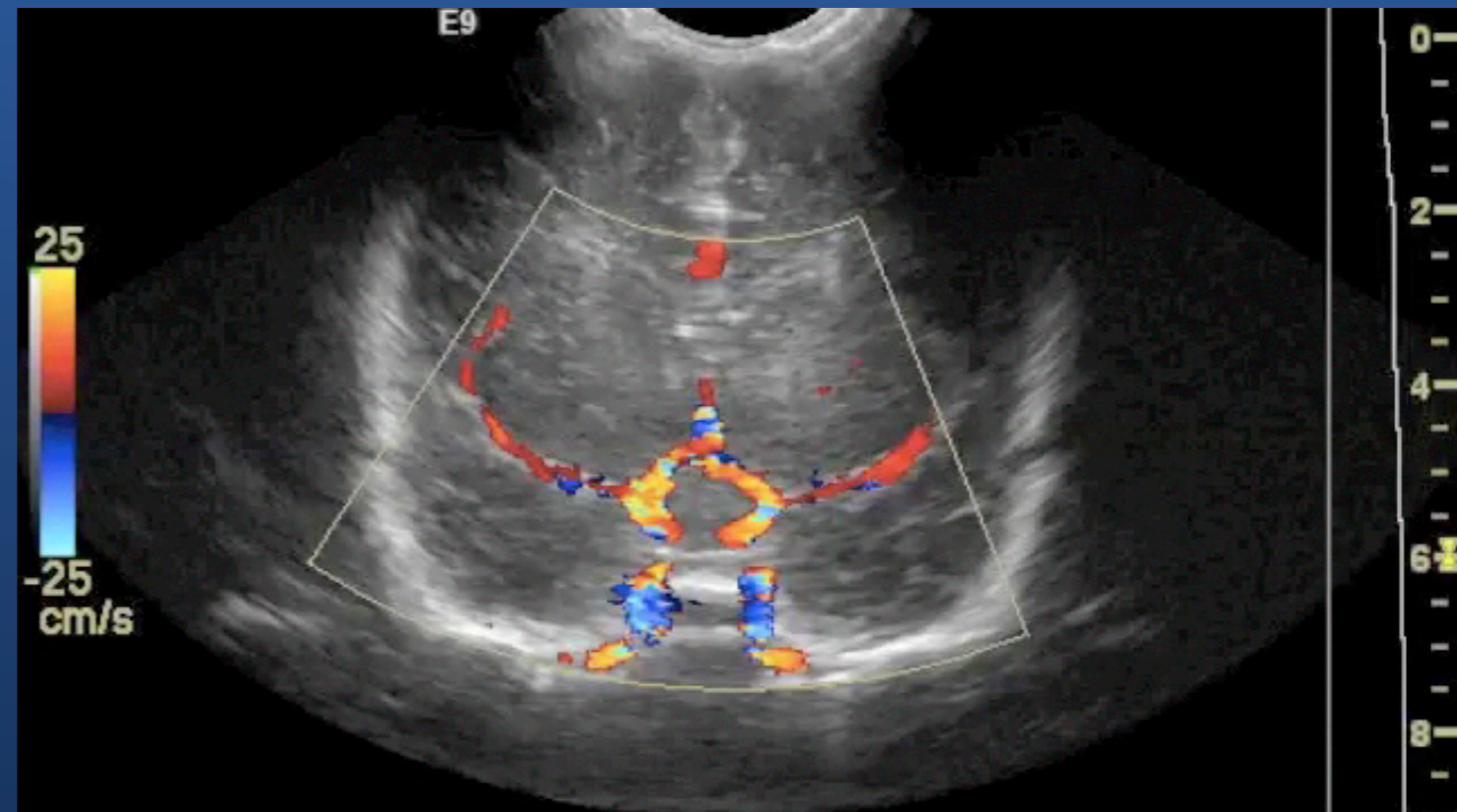
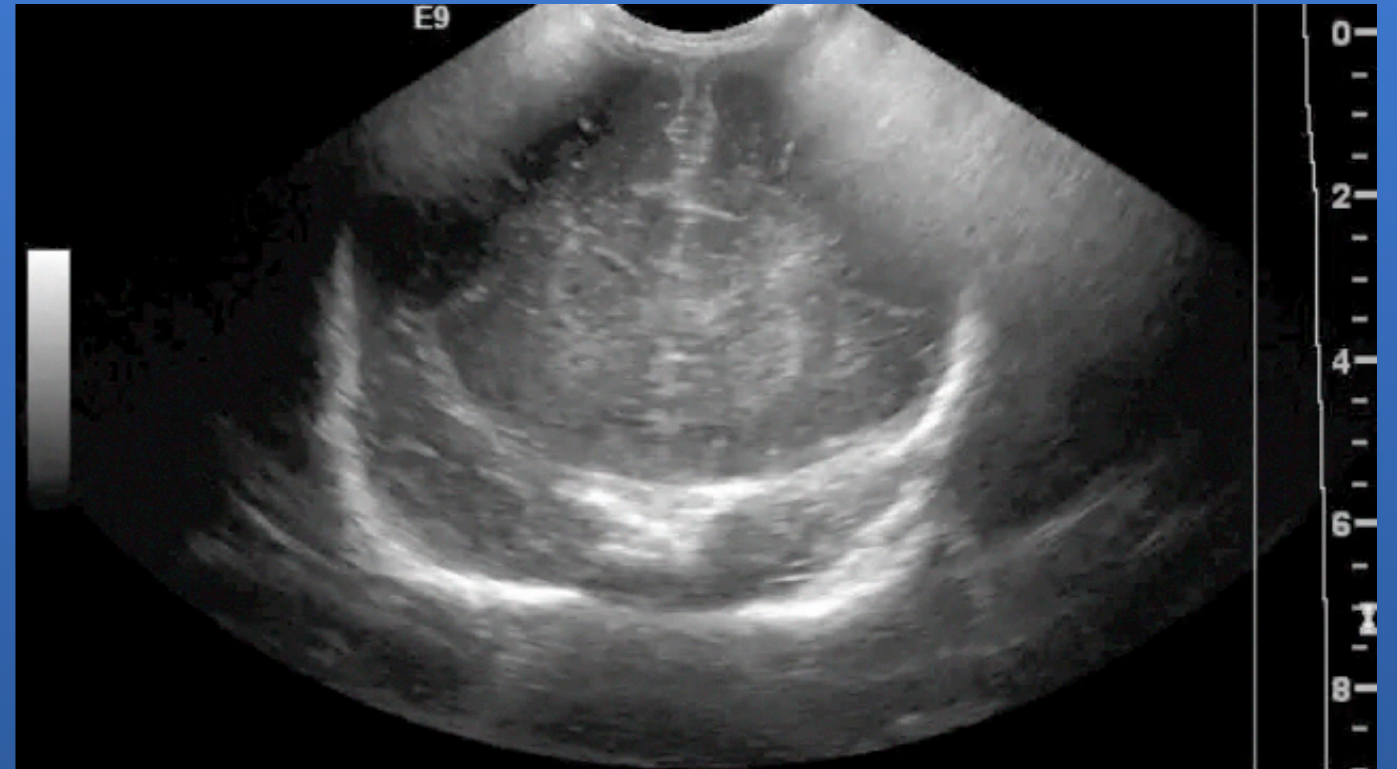
ARTERES CEREBRALES



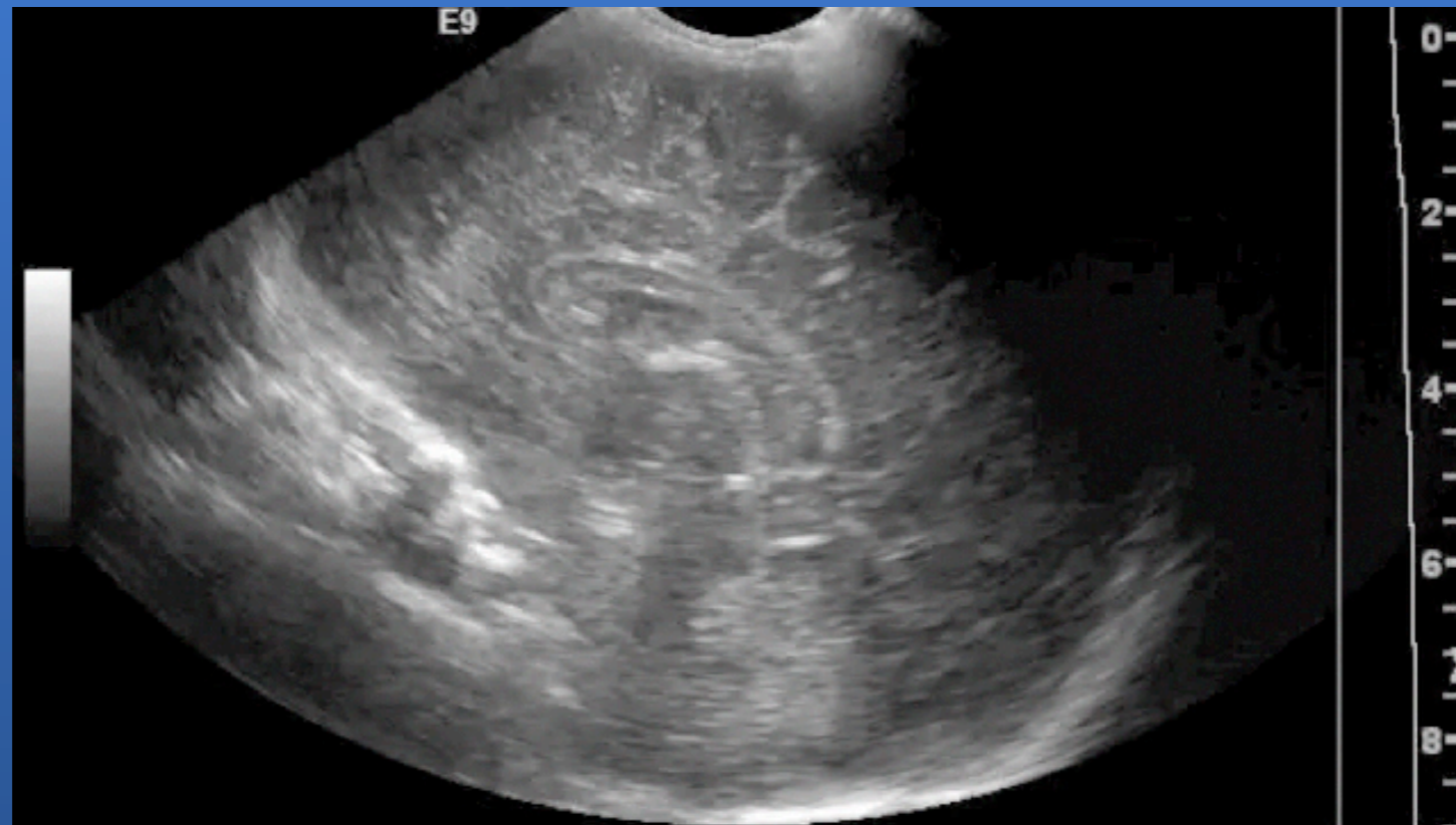
- **Bidimensionnel :**
 - Lumière rarement visible
 - Gros troncs : images pulsatiles dans le LCR

ARTERES CEREBRALES

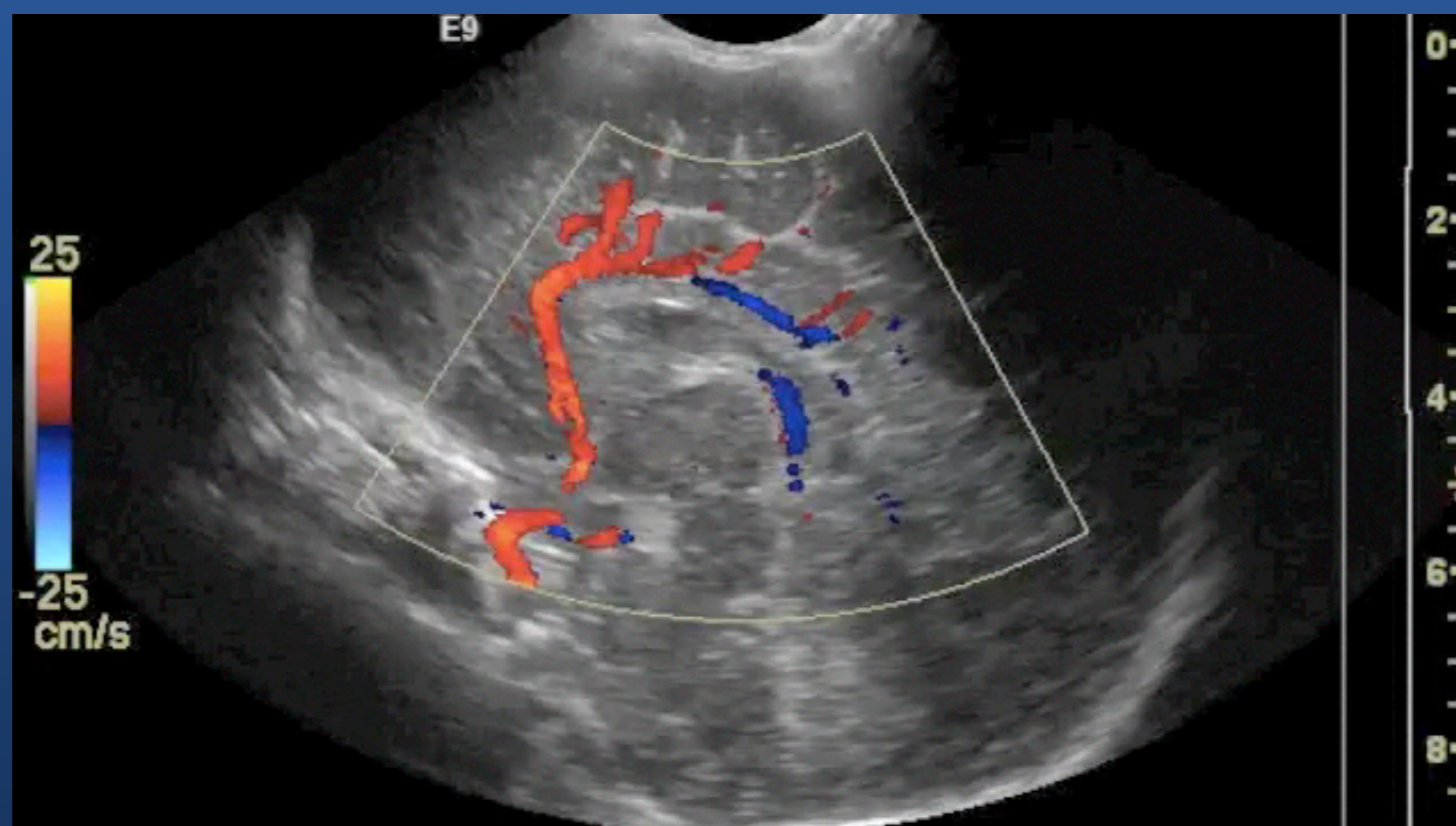
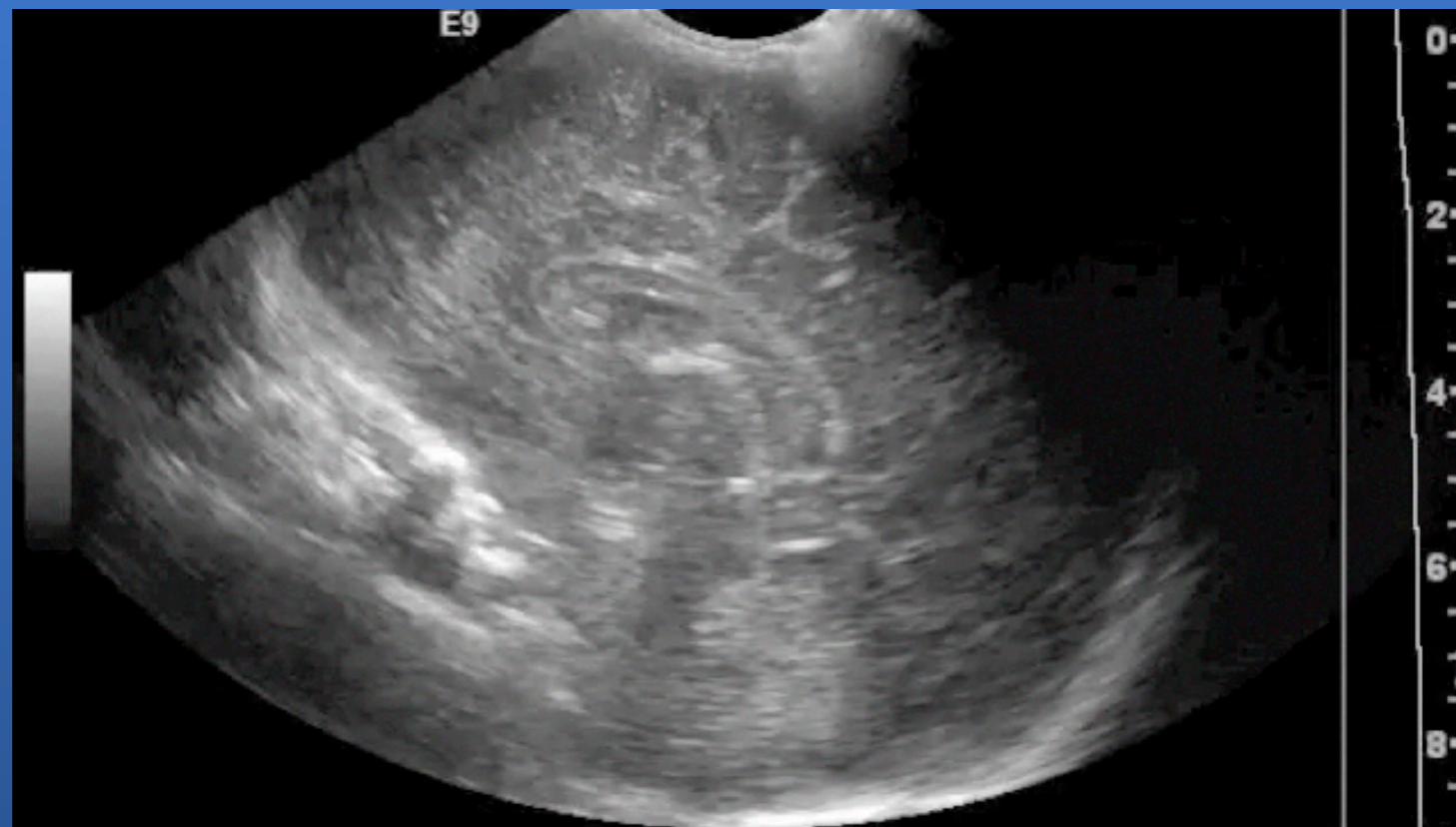
- **Bidimensionnel :**
 - Lumière rarement visible
 - Gros troncs : images pulsatiles dans le LCR



DOPPLER

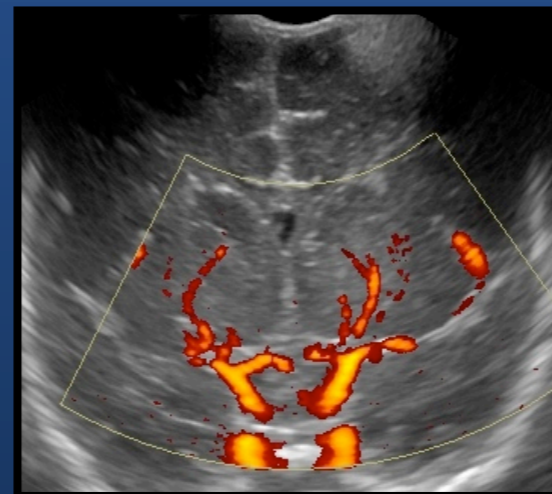
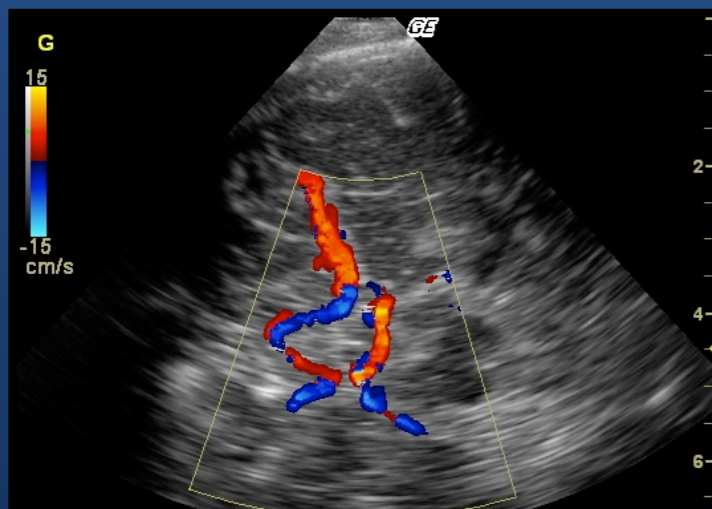
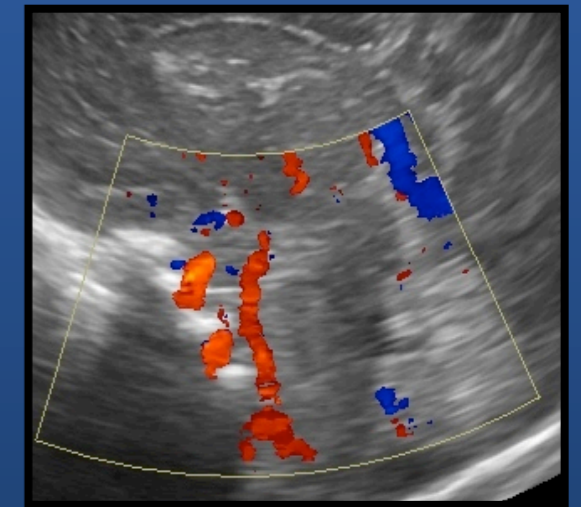
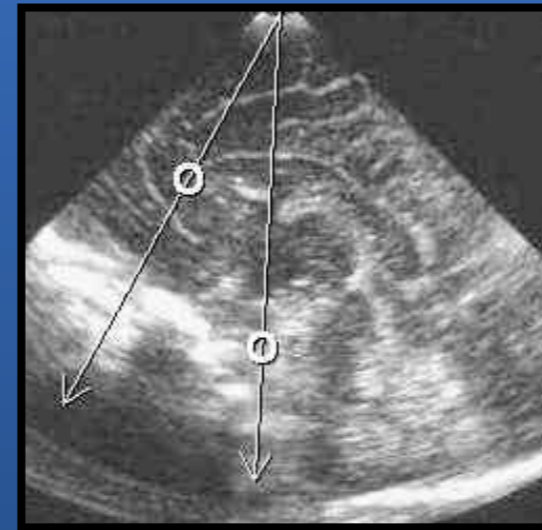
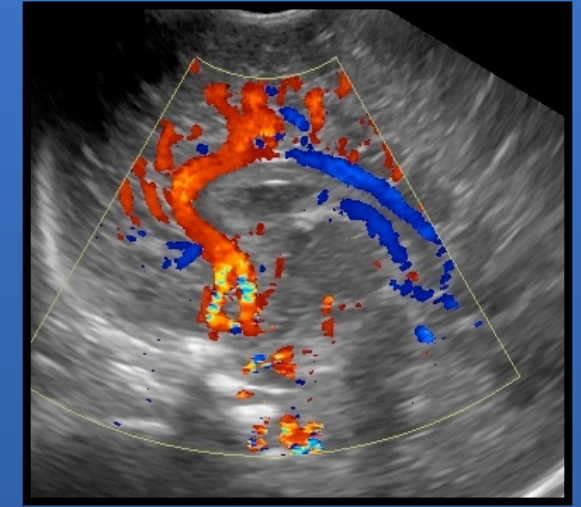


DOPPLER



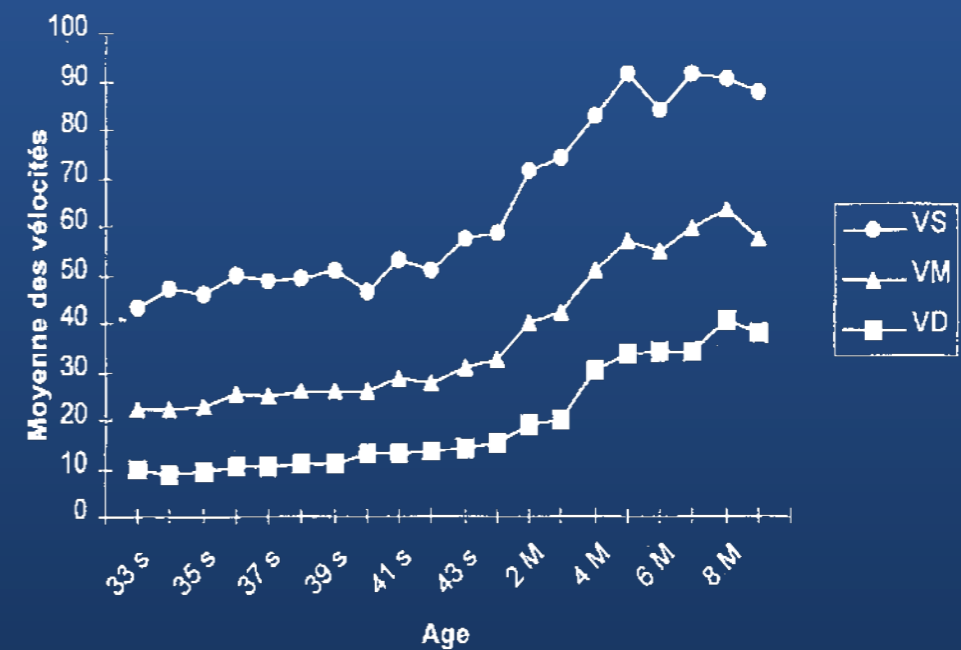
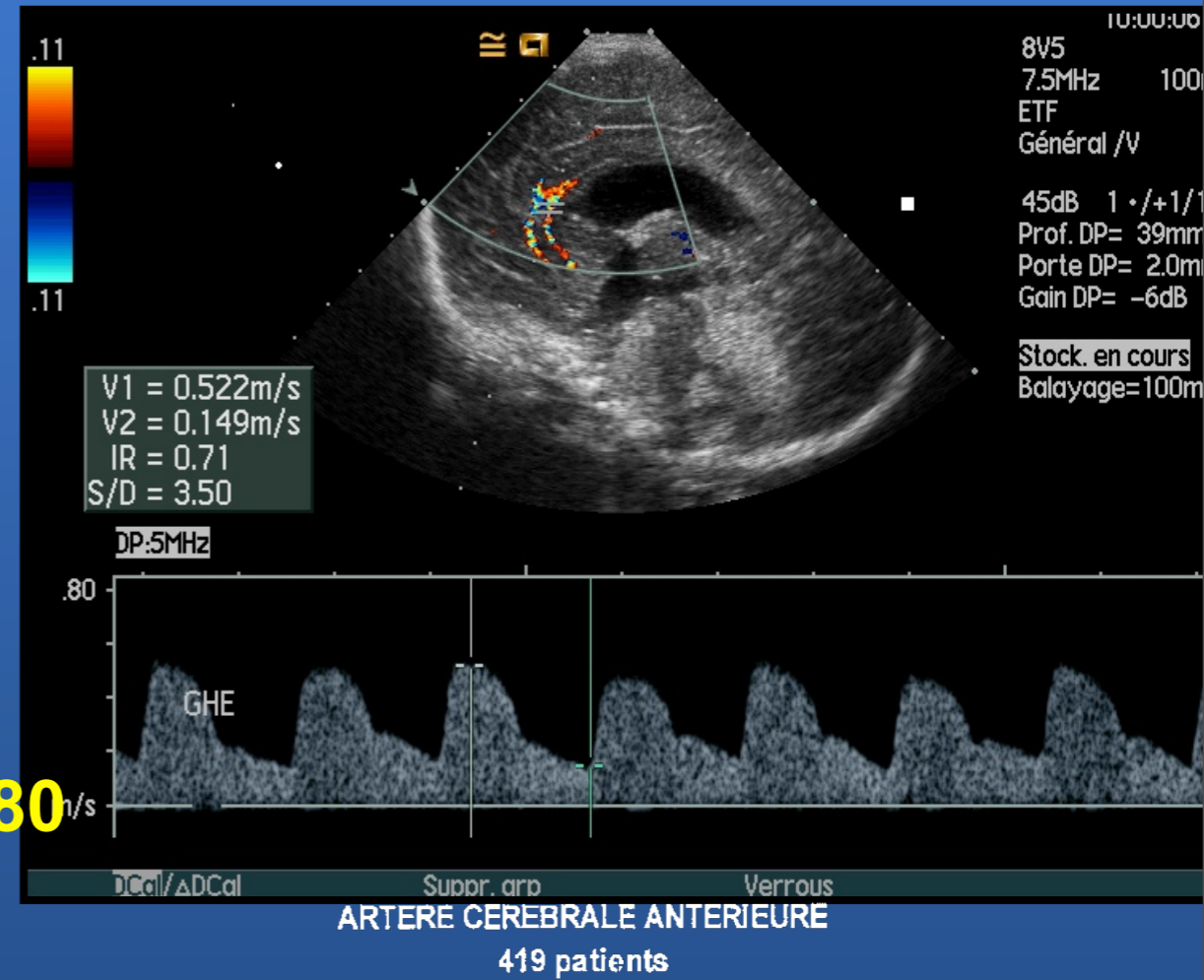
DOPPLER ARTERIEL

- Cérébrale antérieure :
 - fontanelle antérieure
- Sylvienne
 - Fontanelle antérieure
 - voie temporale
- Thalamo-striées
- Tronc basilaire
 - voie médiane



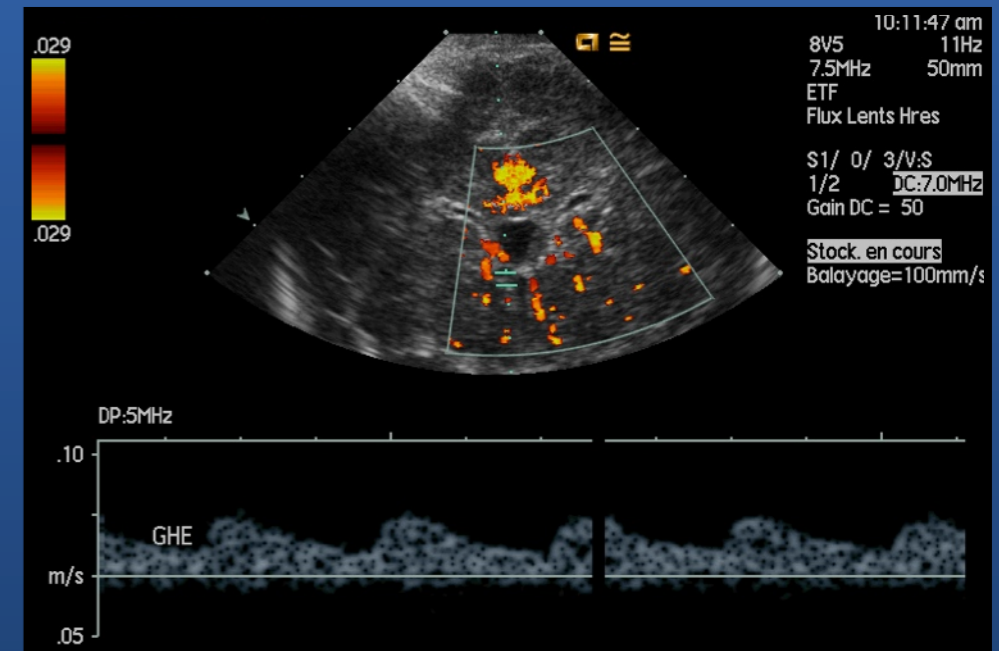
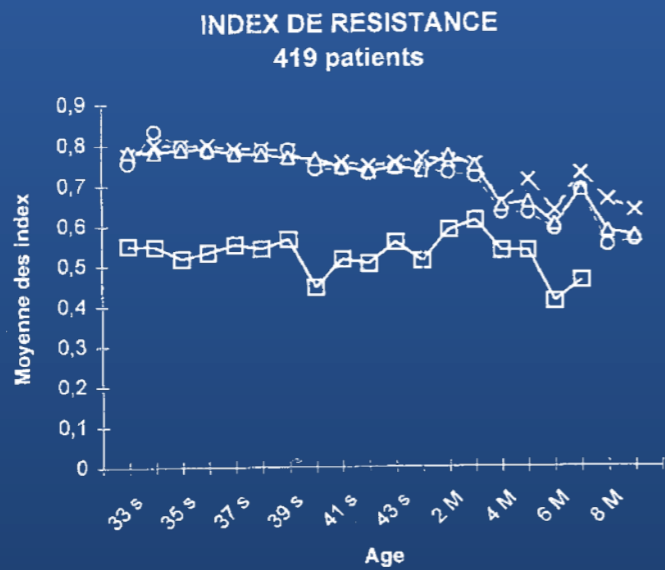
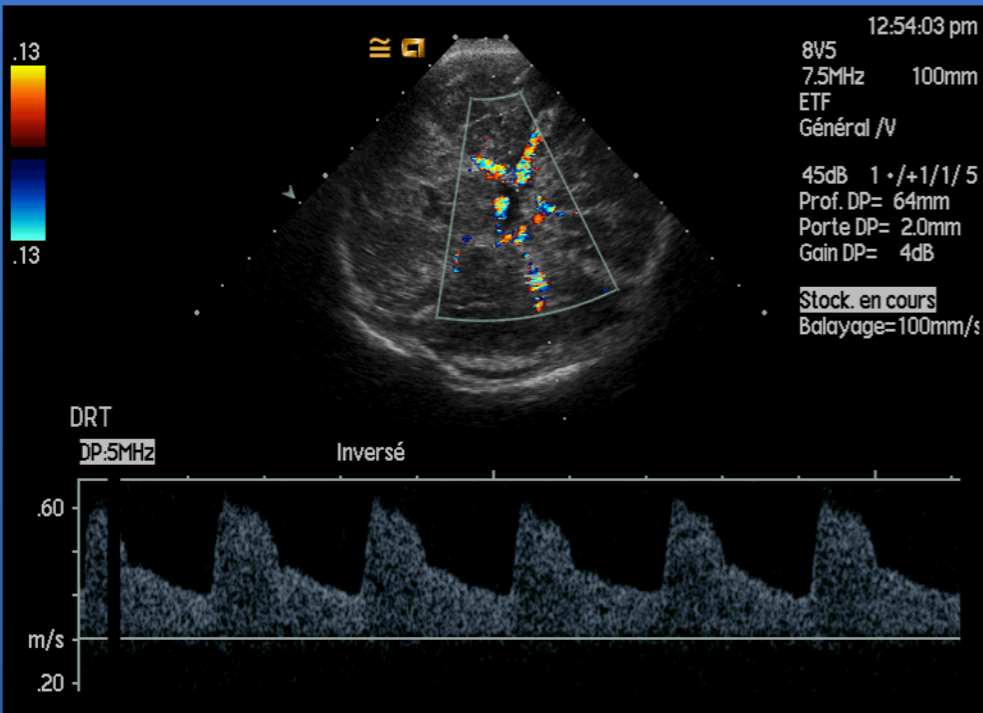
Artères cérébrales

- **Doppler couleur**
- **Doppler pulsé:**
 - __ basses résistances
 - __ Diastolique toujours présente
 - __ **Index de Pourcelot (S-D/S) : 0,60 à 0,80**
 - __ Variable dans le temps

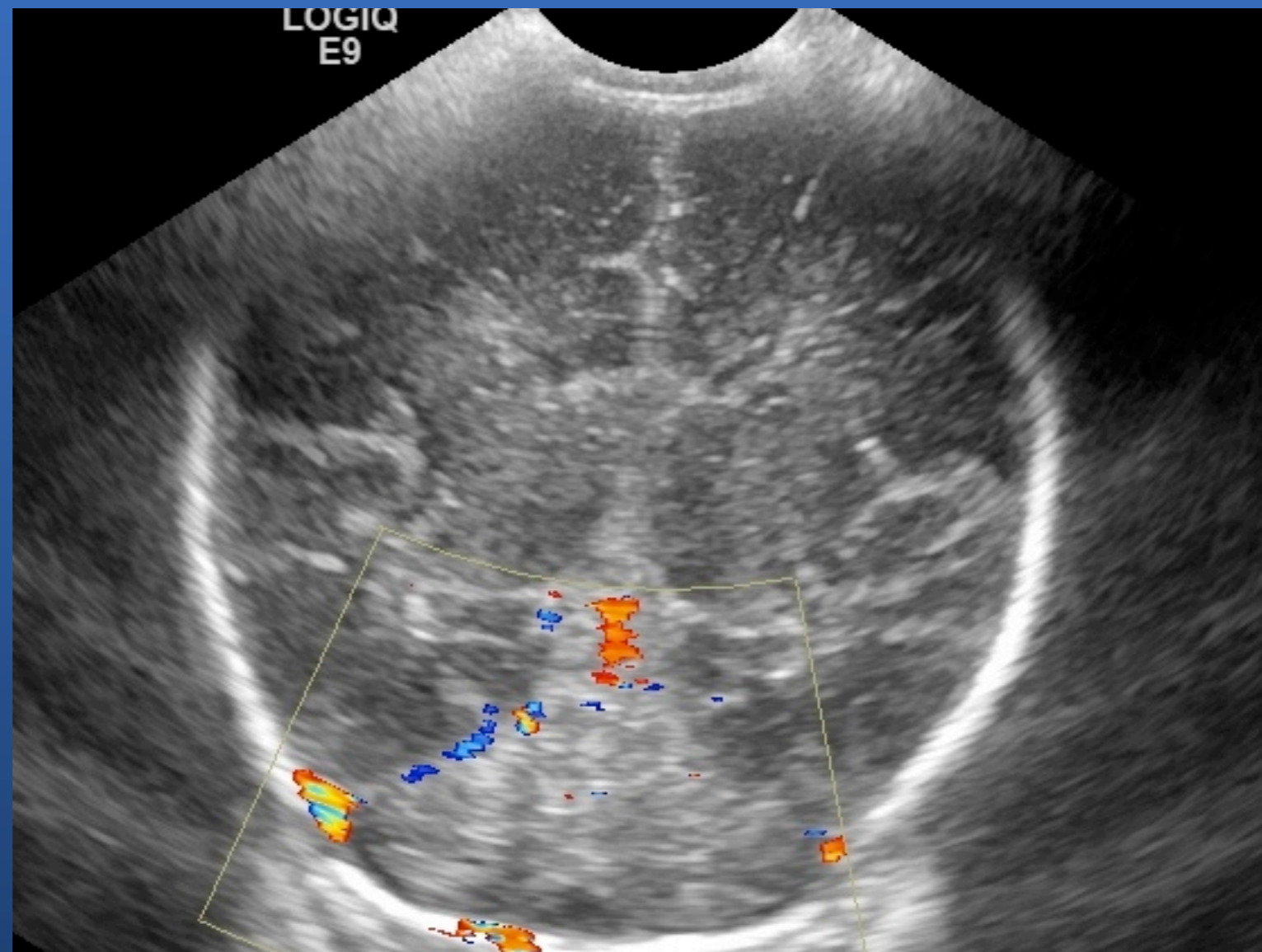


Sylvienne

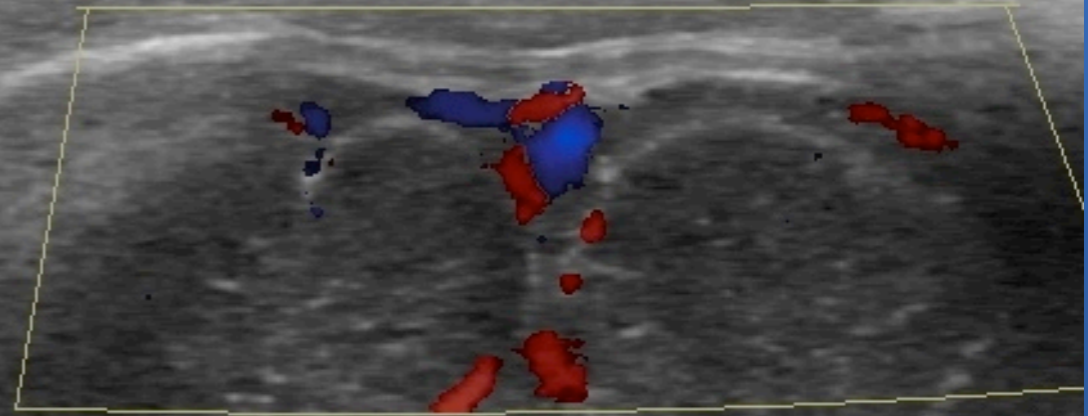
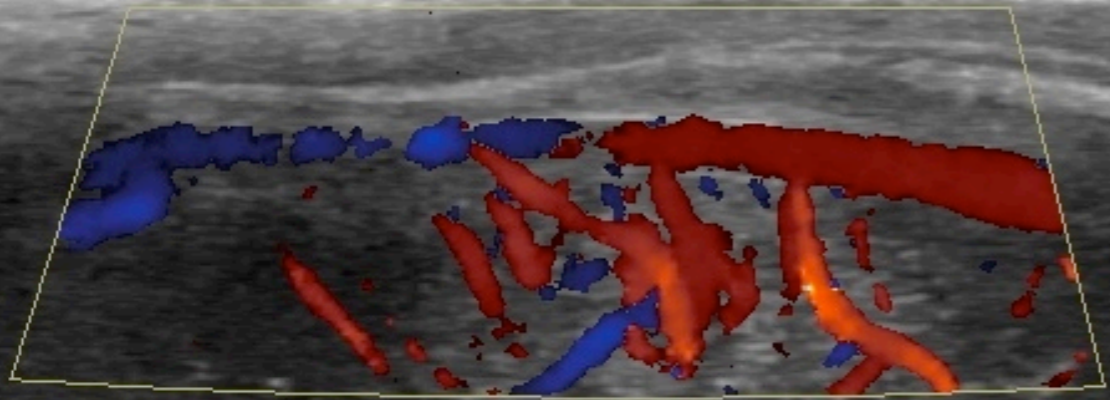
Thalamo-striée



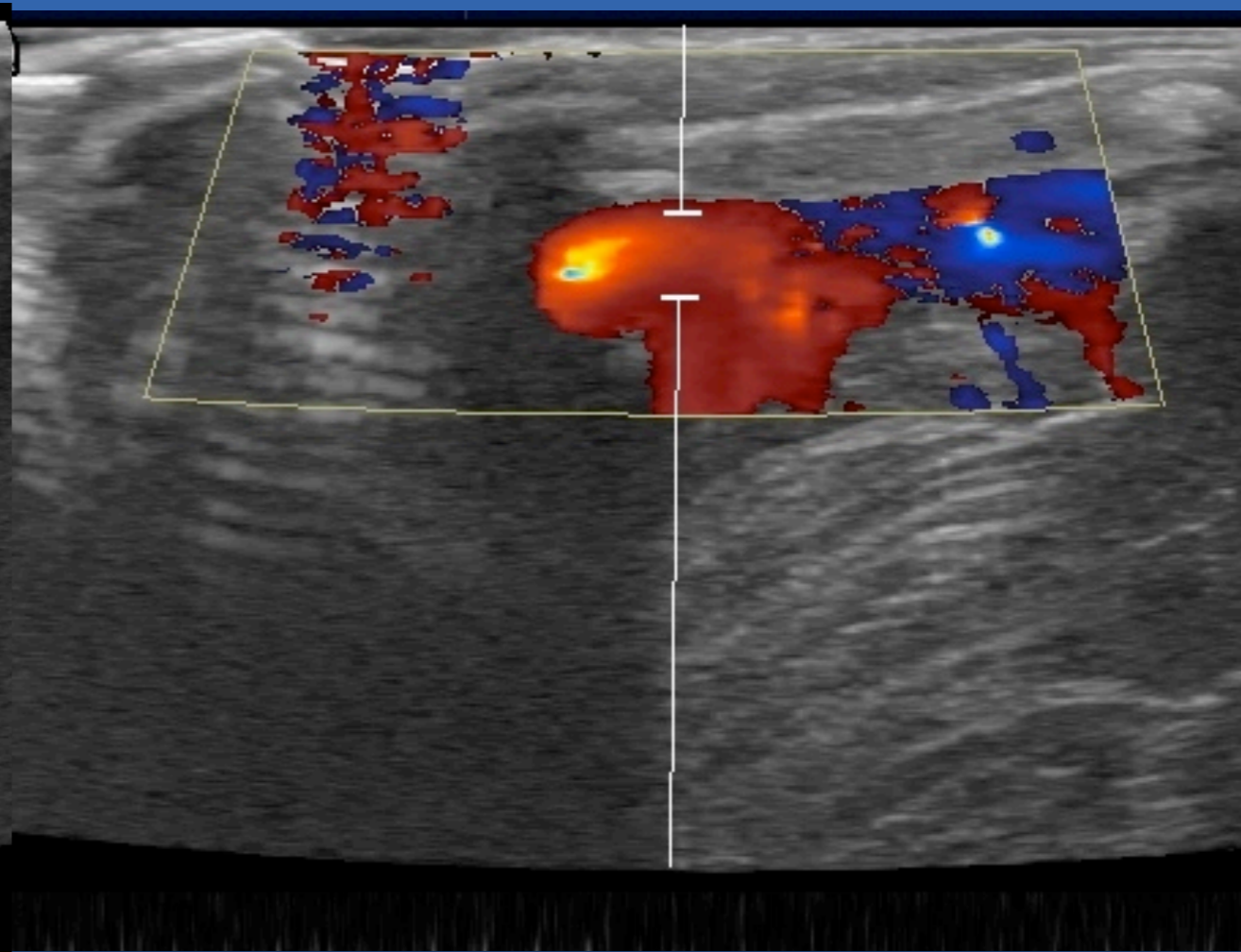
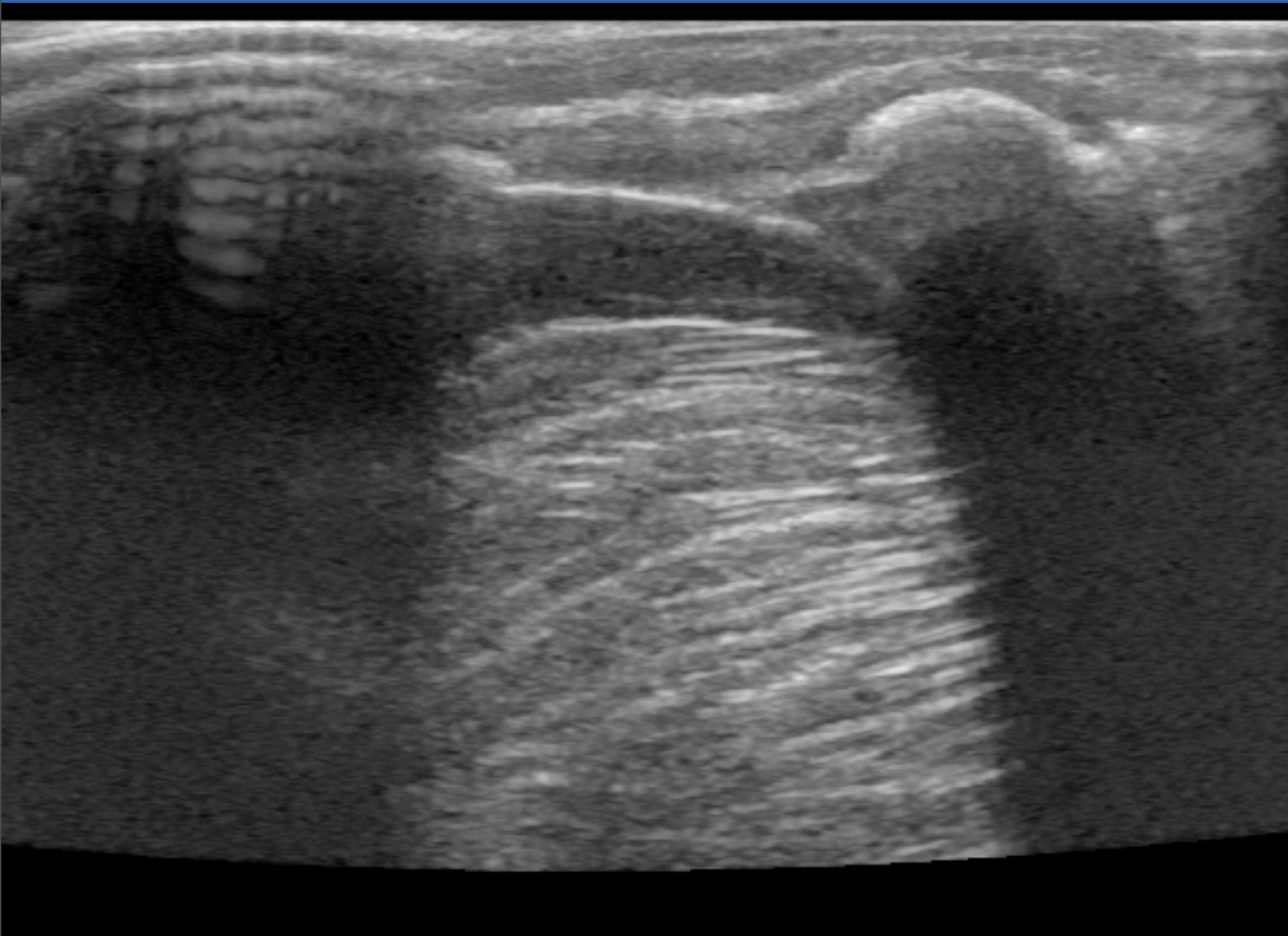
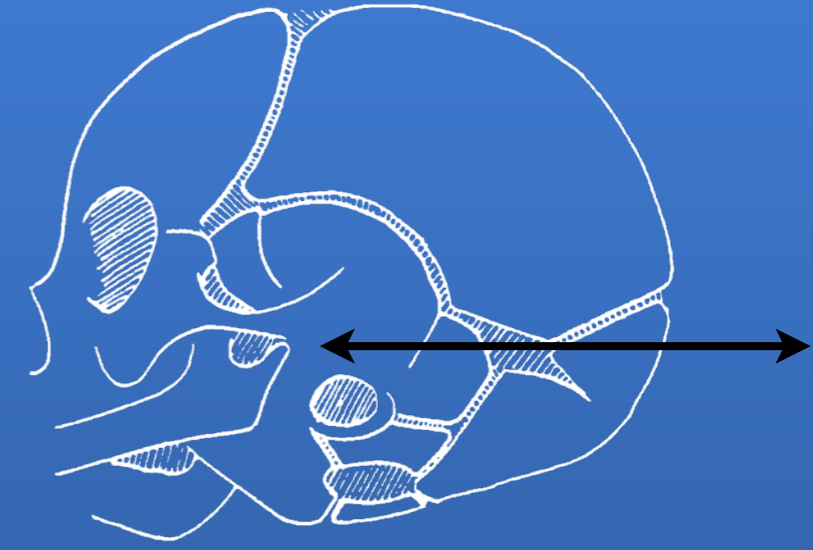
LES VEINES



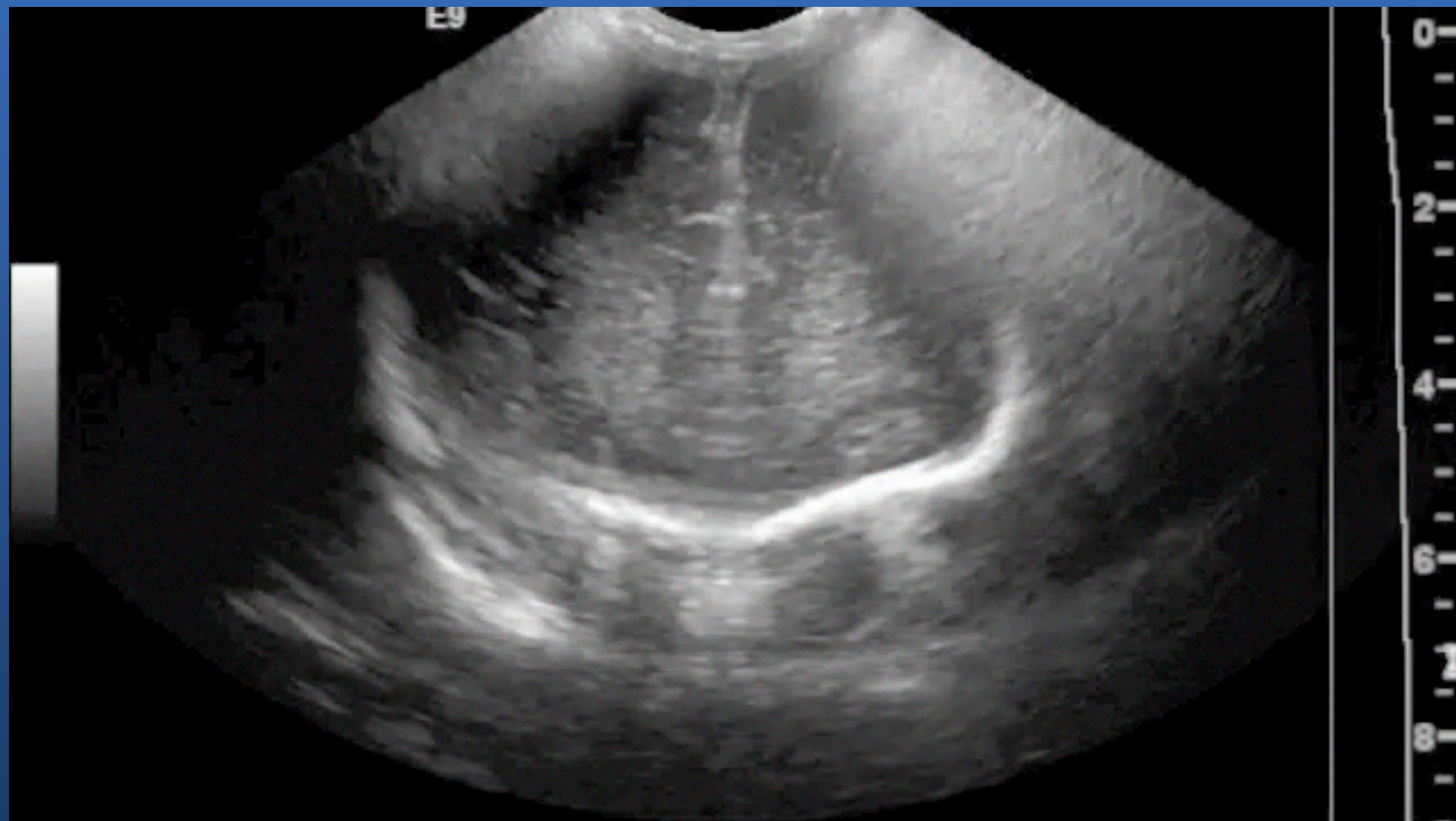LES VEINES



LES VEINES

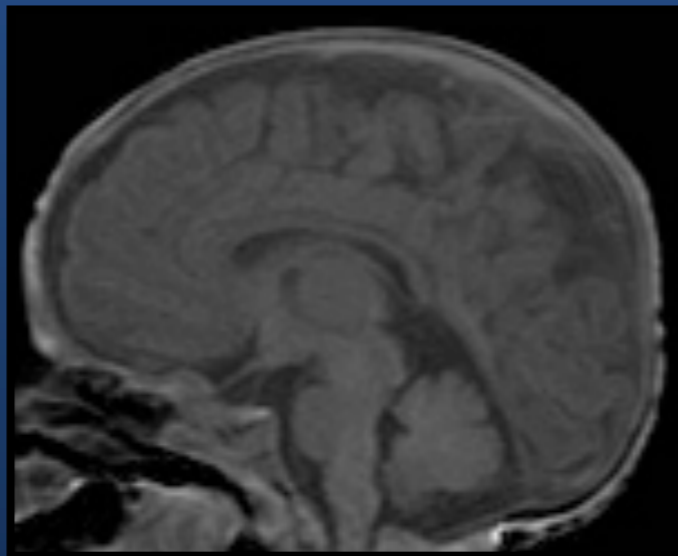
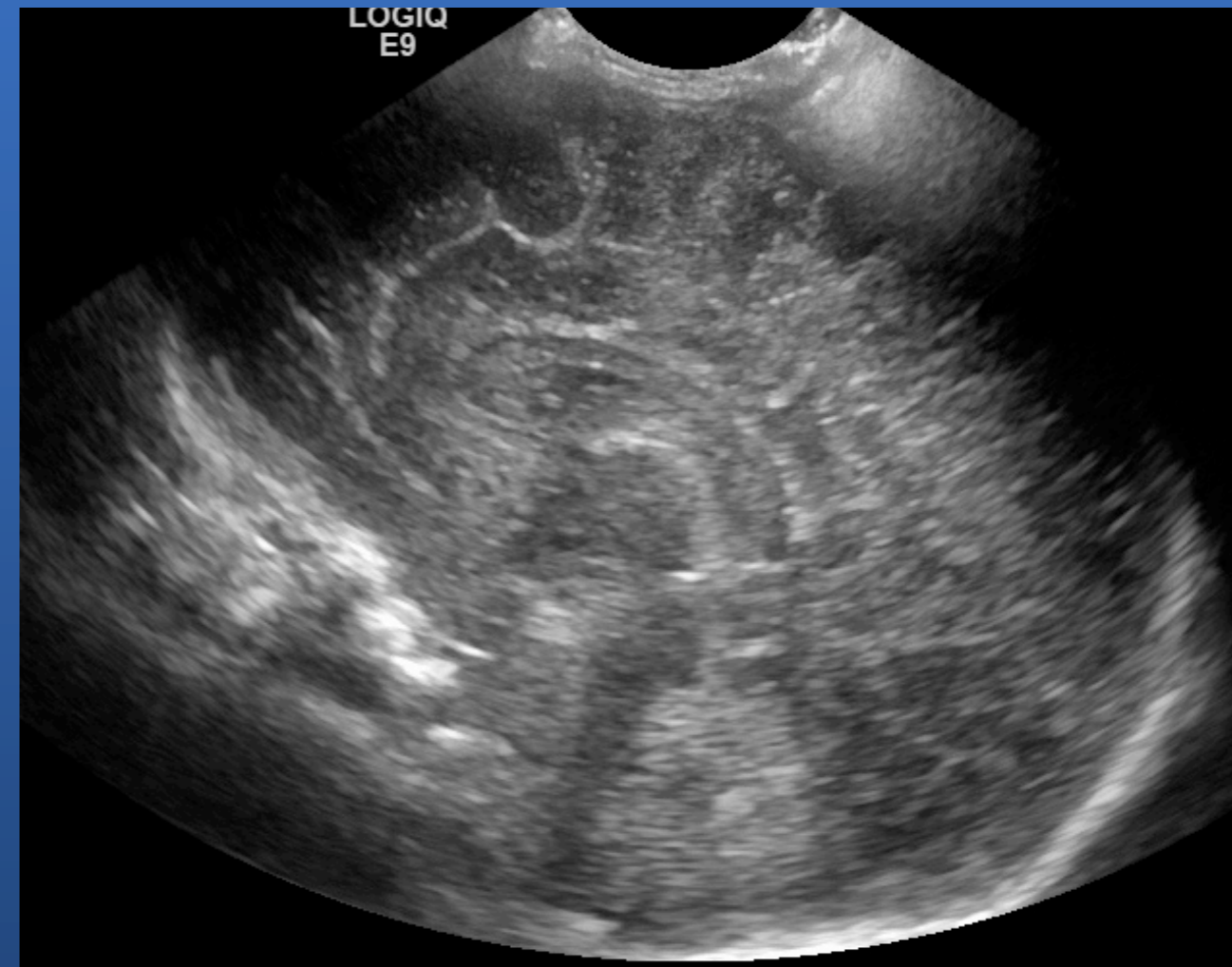


ANATOMIE NORMALE



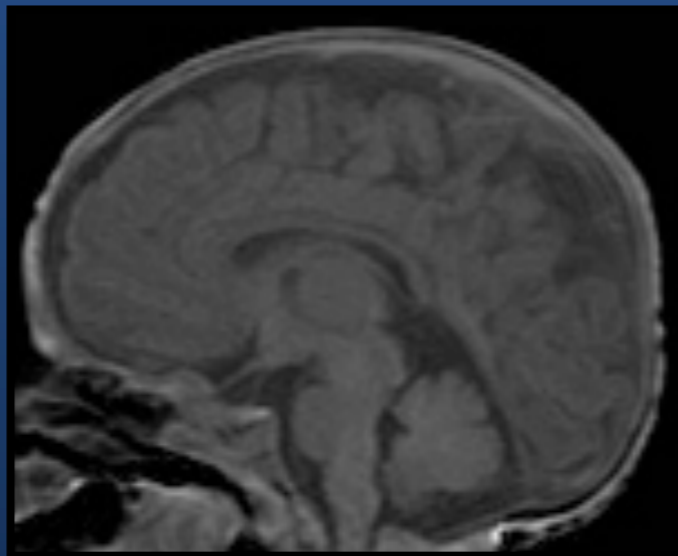
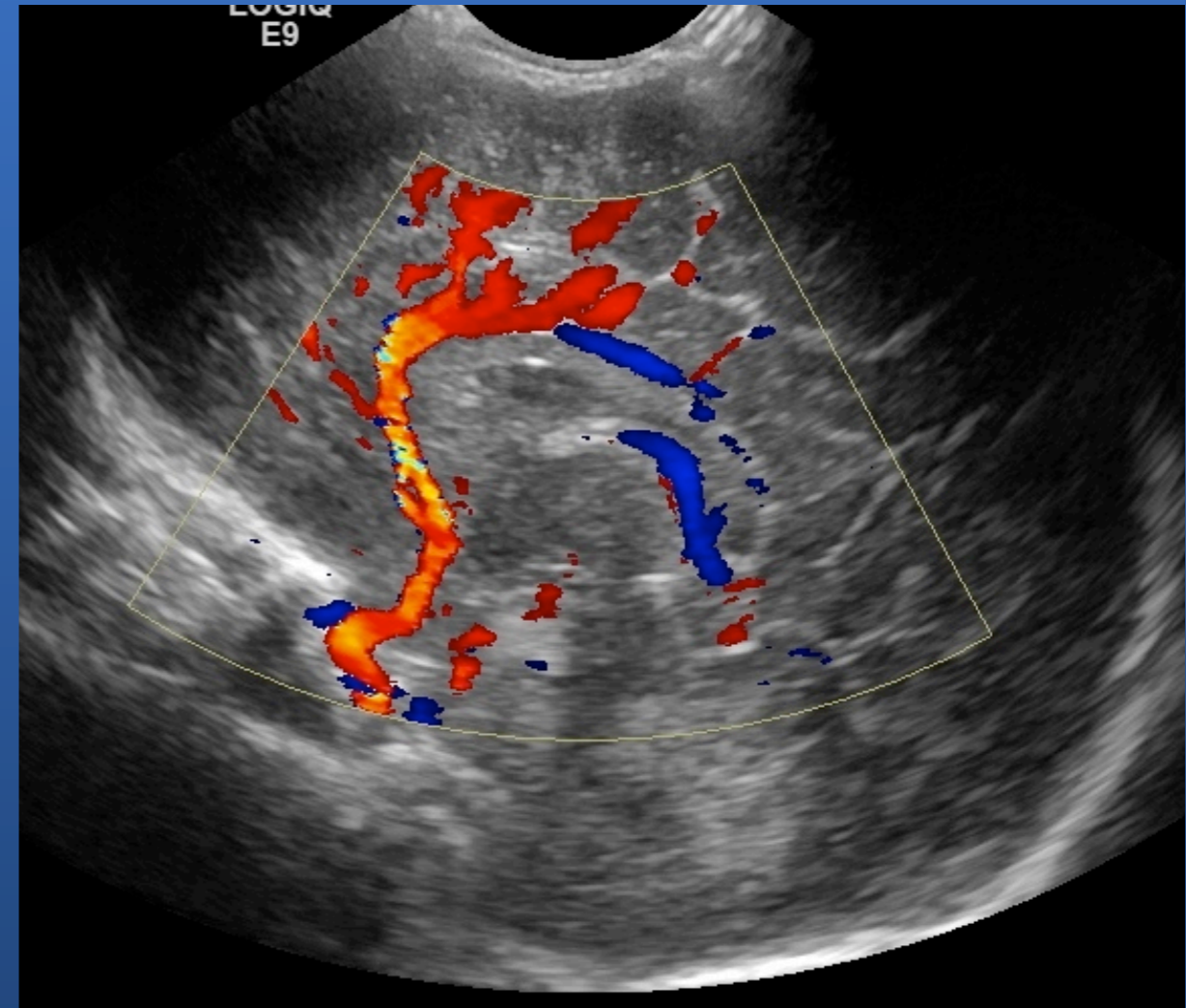
CORPS CALLEUX

- Coupe sagittale médiane
- **Commissure blanche inter hémisphérique**
 - **Concave en bas**
 - Surmonté par circonvolution pericalleuse
 - **Différentes portions**
 - **Bec, genou, corps, splenium**



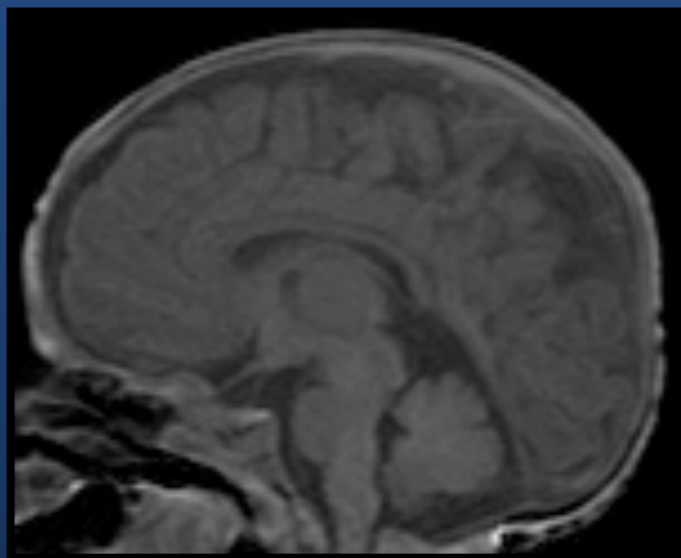
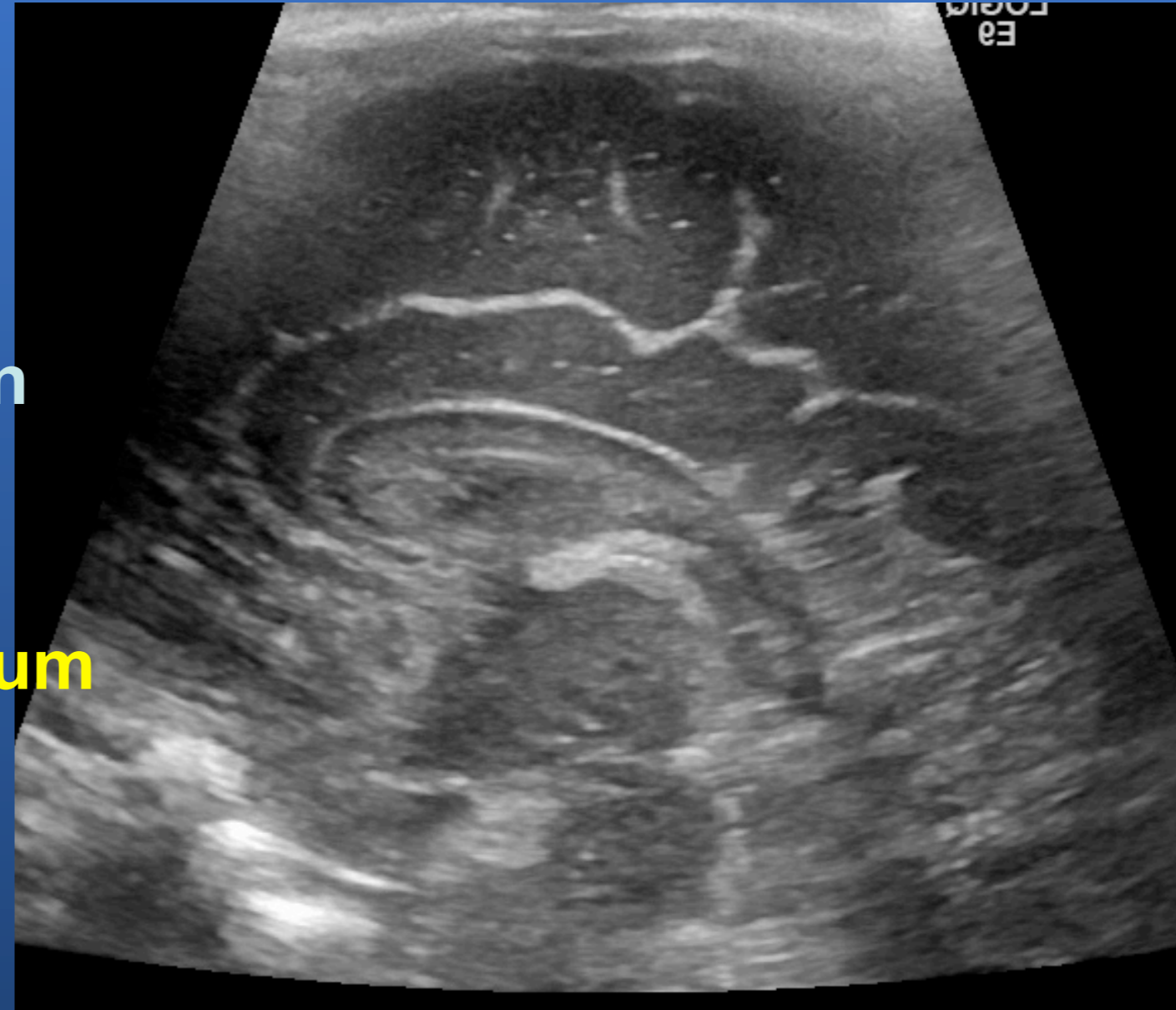
CORPS CALLEUX

- Coupe sagittale médiane
- **Commissure blanche inter hémisphérique**
 - **Concave en bas**
 - Surmonté par circonvolution pericalleuse
 - **Différentes portions**
 - **Bec, genou, corps, splenium**



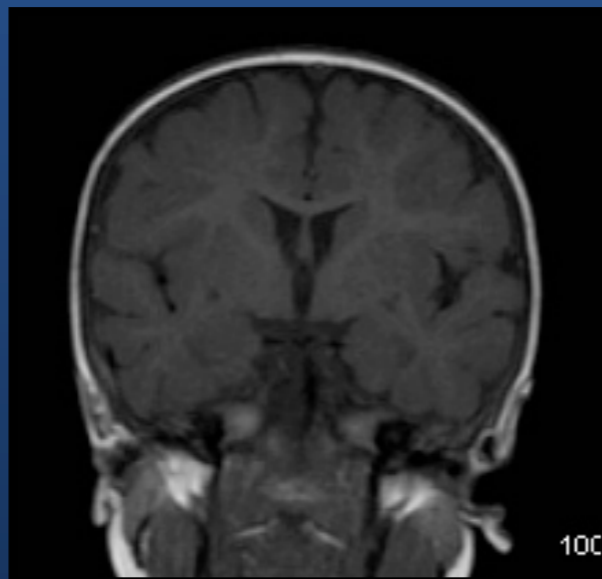
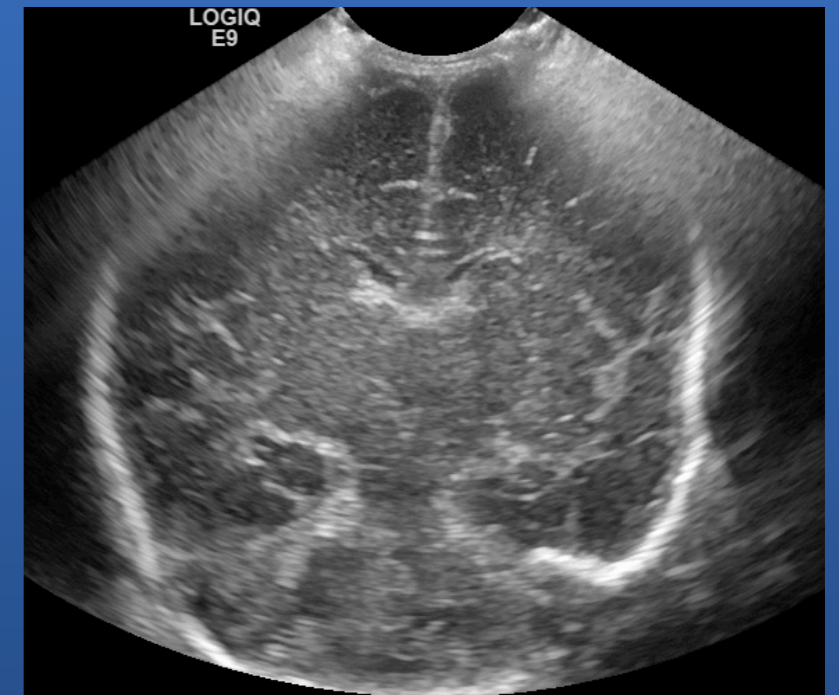
CORPS CALLEUX

- Coupe sagittale médiane
- **Commissure blanche inter hémisphérique**
 - **Concave en bas**
 - Surmonté par circonvolution pericalleuse
 - **Différentes portions**
 - **Bec, genou, corps, splenium**



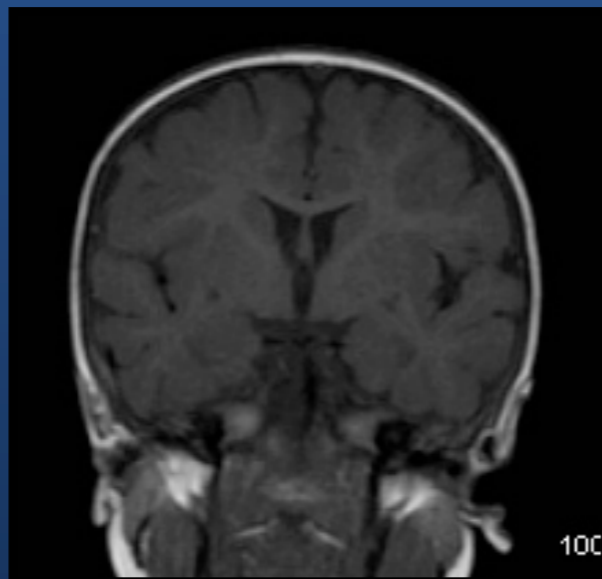
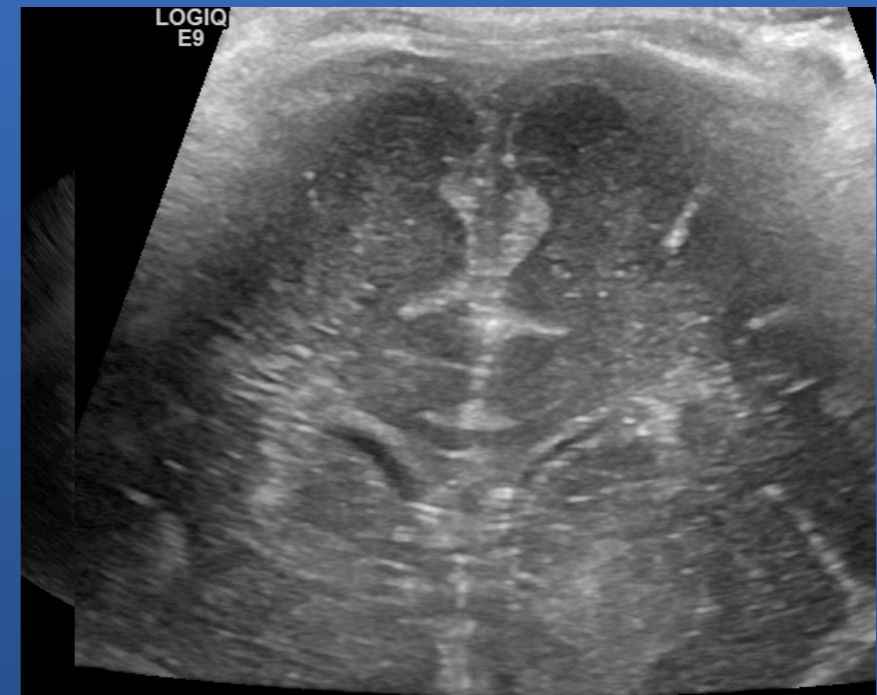CORPS CALLEUX

- **Coupes coronales :**
 - **Pied du sillon inter hémisphérique**
 - **Sus ventriculaire**



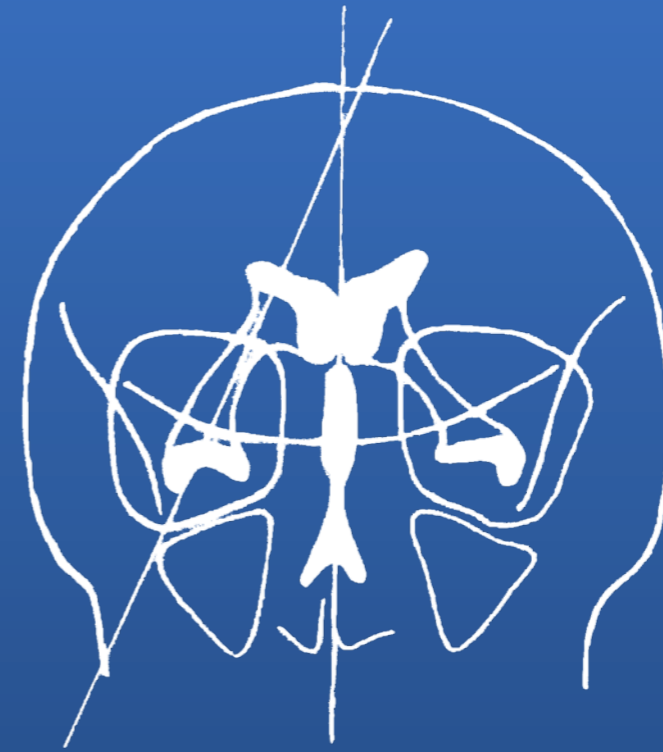CORPS CALLEUX

- **Coupes coronales :**
 - Pied du sillon inter hémisphérique
 - Sus ventriculaire

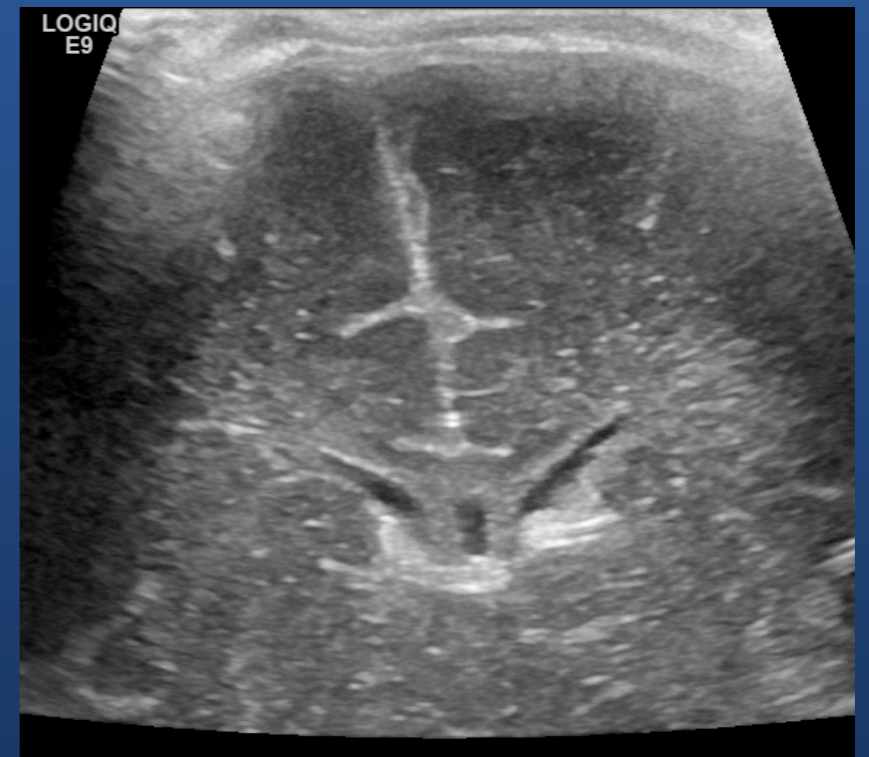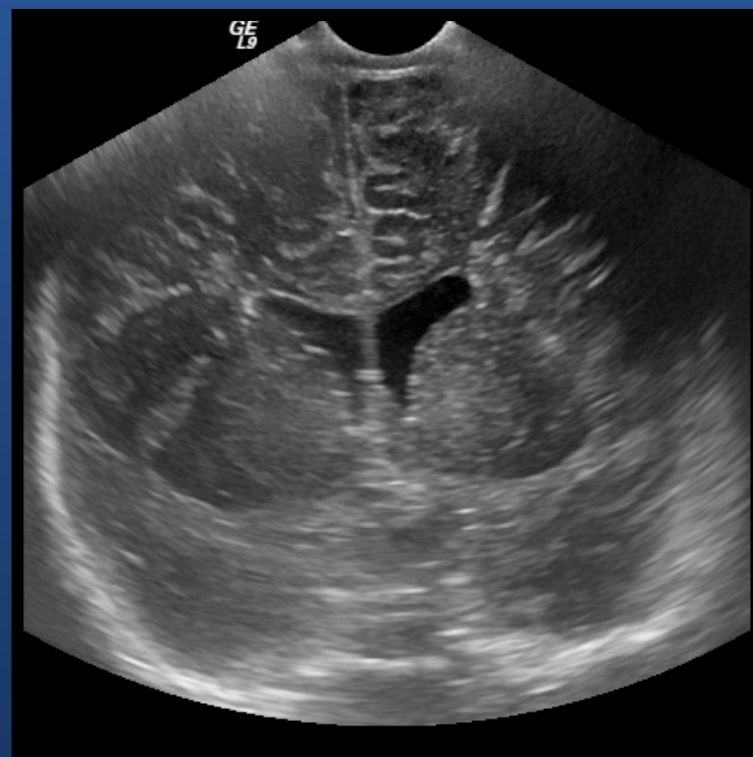
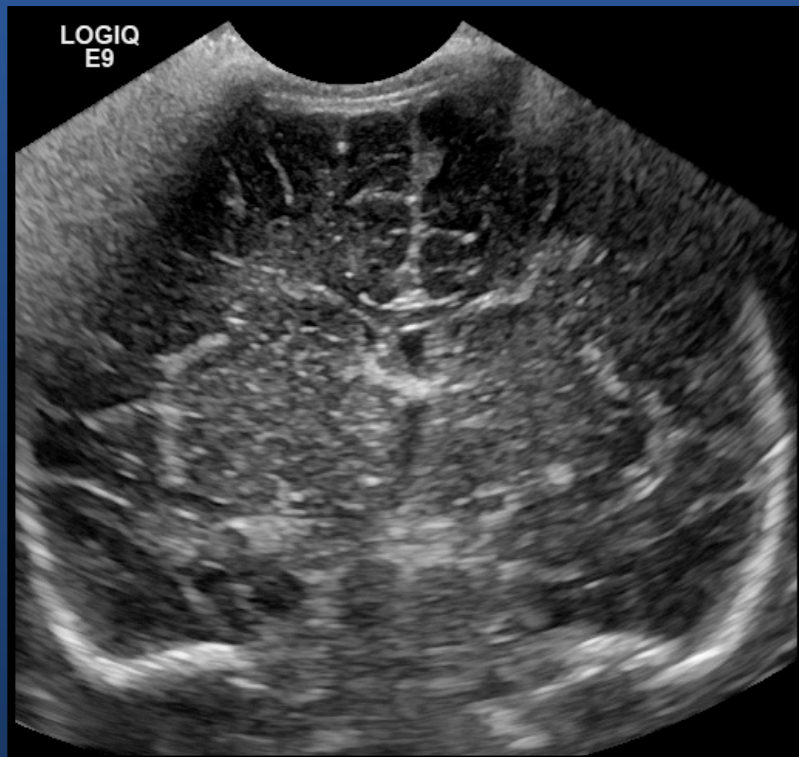
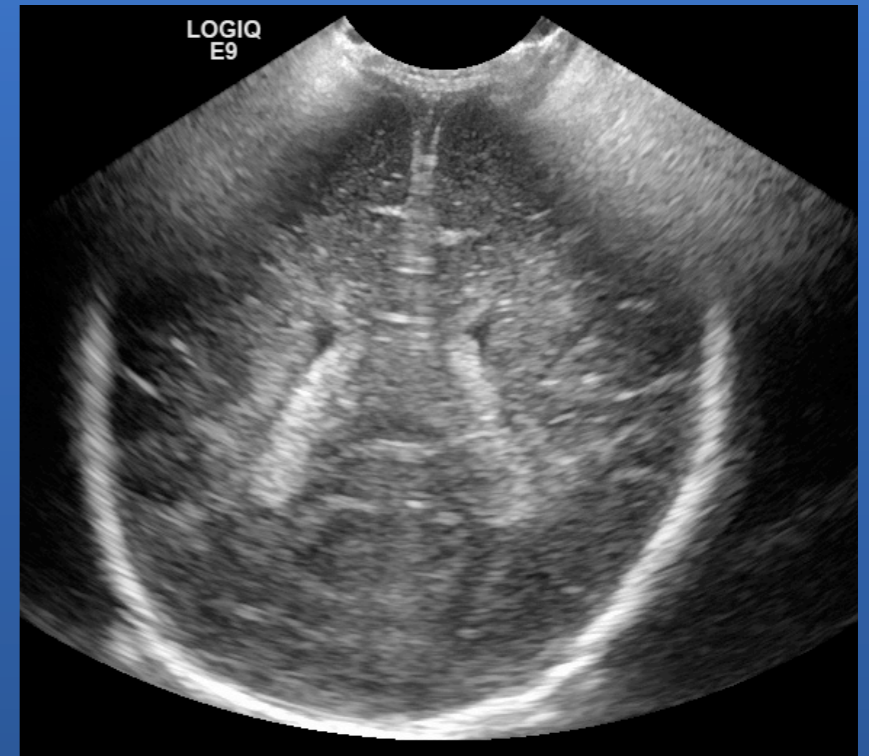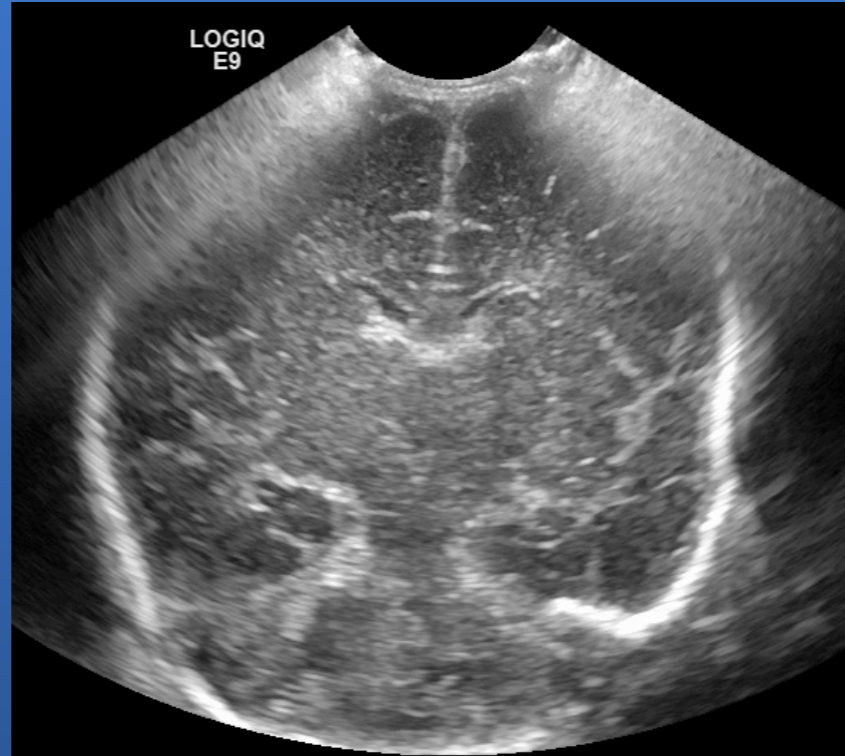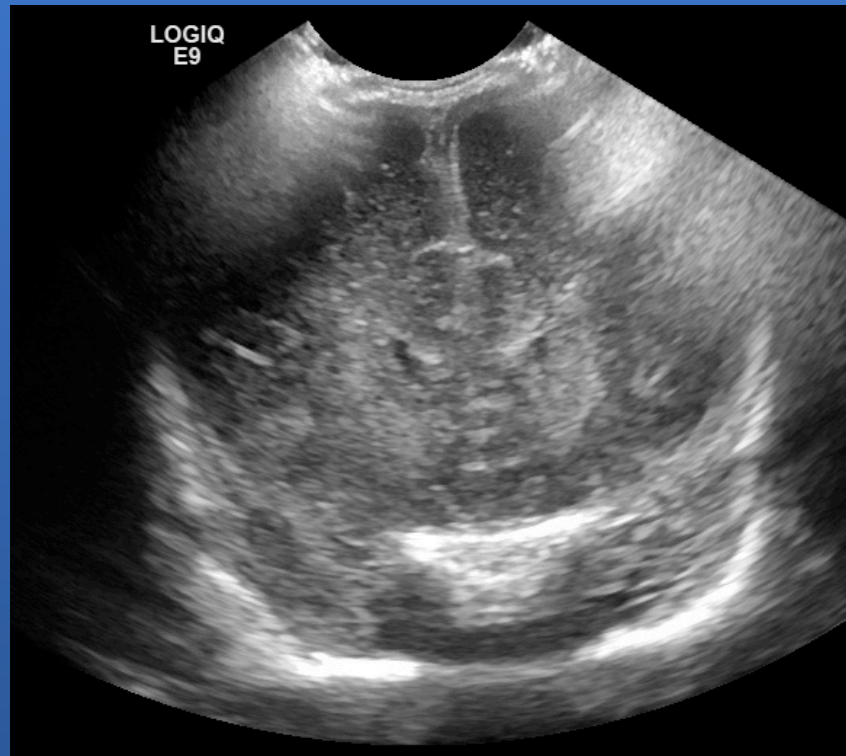


VENTRICULES

- **V. latéraux : triple obliquité**
 - Concavité externe
 - Noyau caudé
 - Contiennent les plexus choroïdes
- **3ème ventricule**
- **V4 : toujours visible**
- **Étude morphologique**
- **Surveillance biométrique**

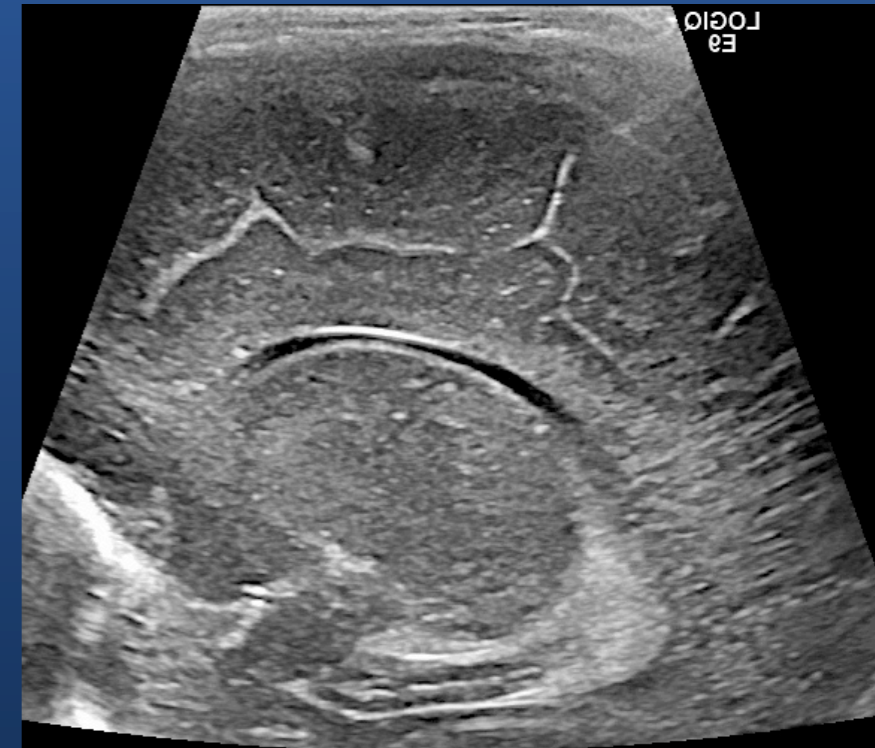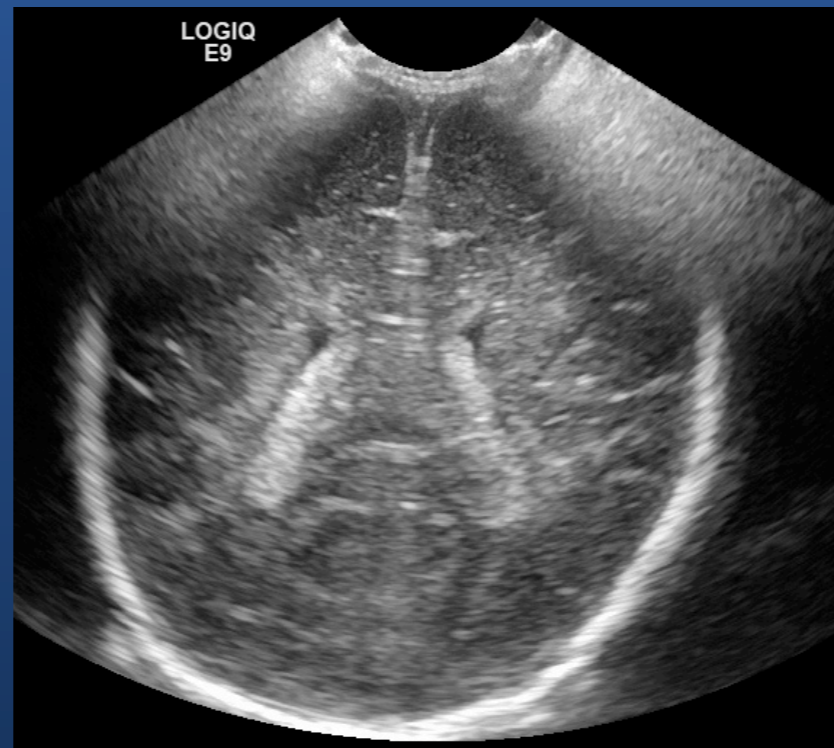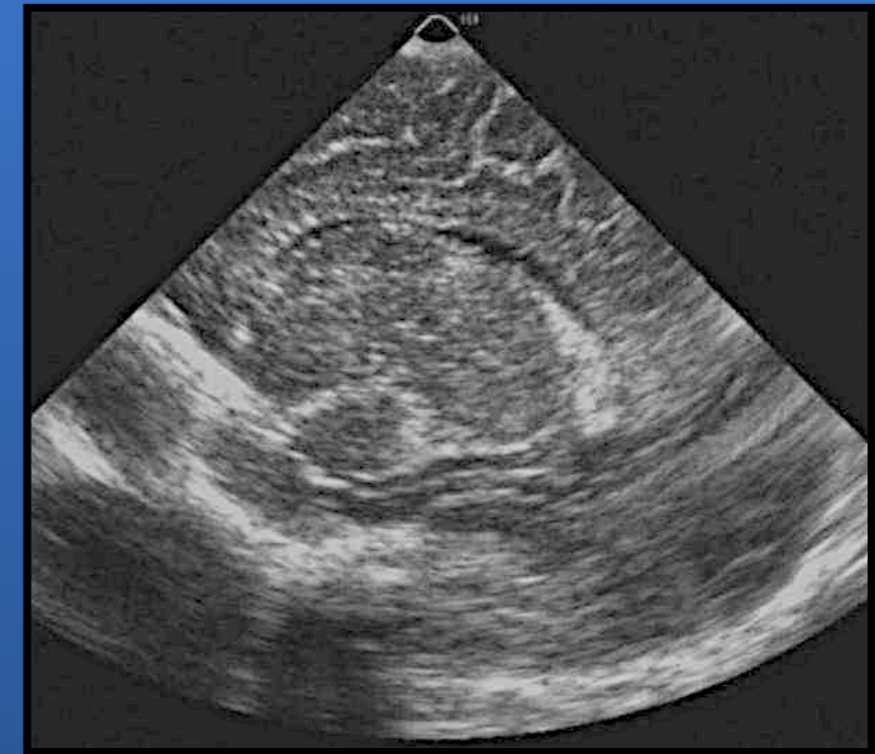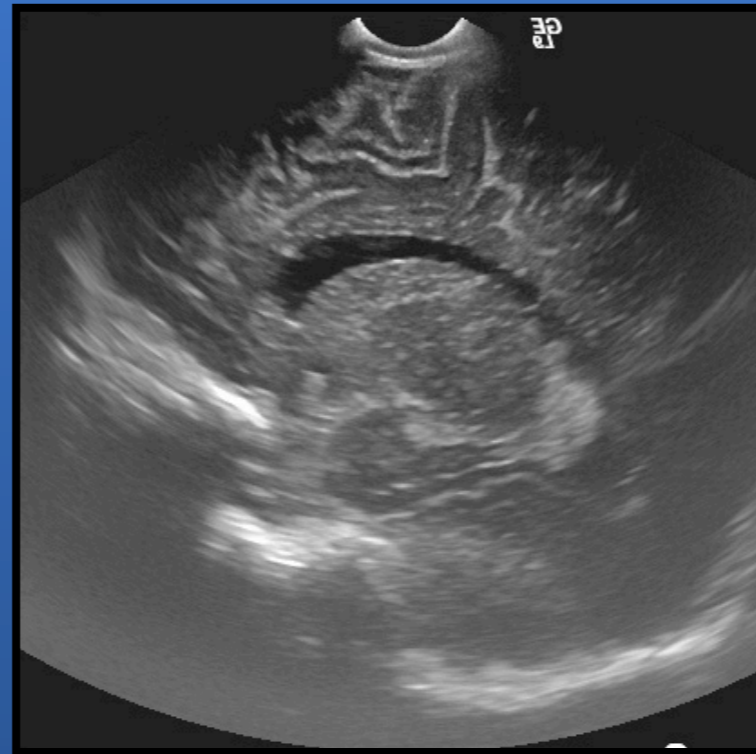


VENTRICLES



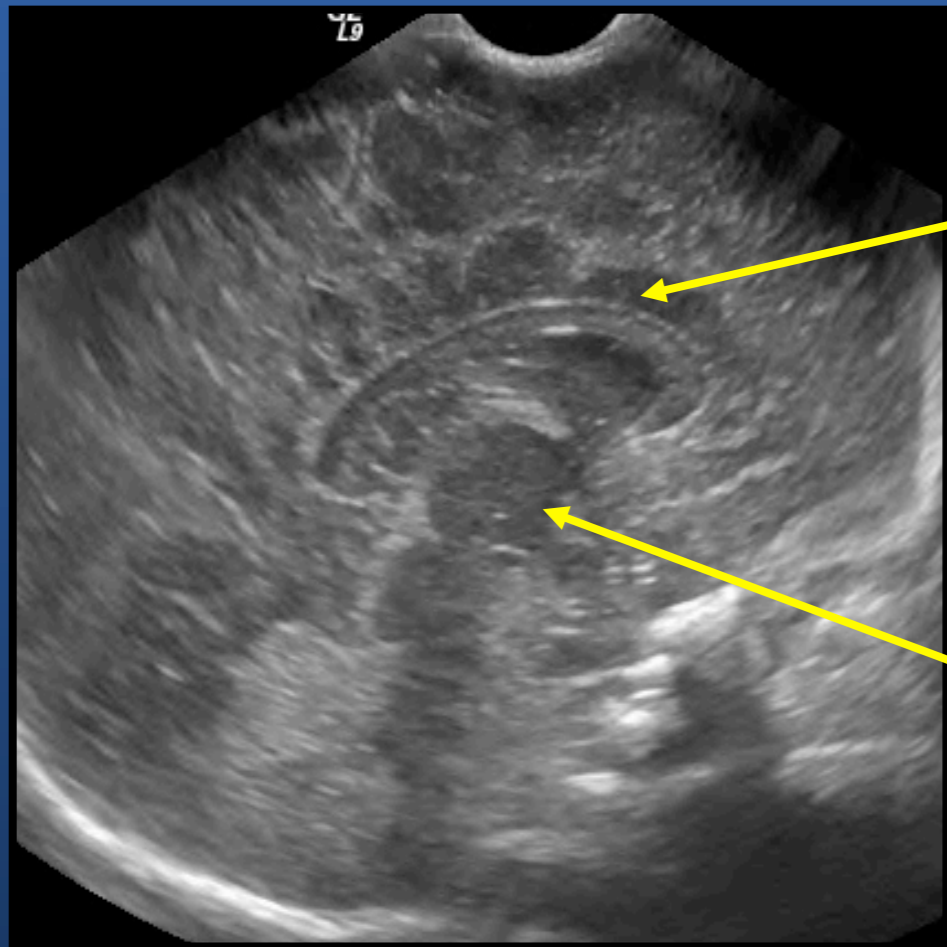
V. Latéral, plexus choroïdes

- Échogènes
- Vascularisés
- Taille variable
- Petits « kystes »
- V. latéraux
 - Trou de Monro
 - carrefour



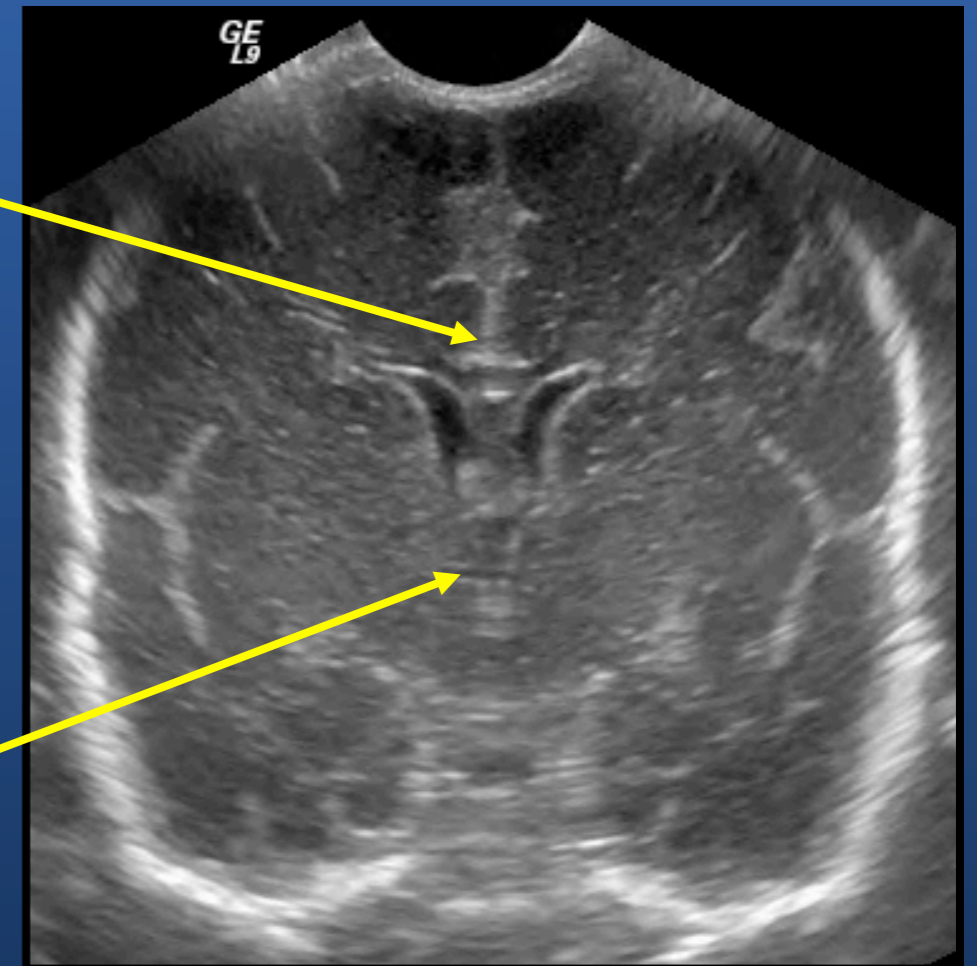
3ème VENTRICULE

- Coupe sagittale médiane
- Coupe transversale :
 - diamètre 5 mm maximum
- Commissure antérieure.

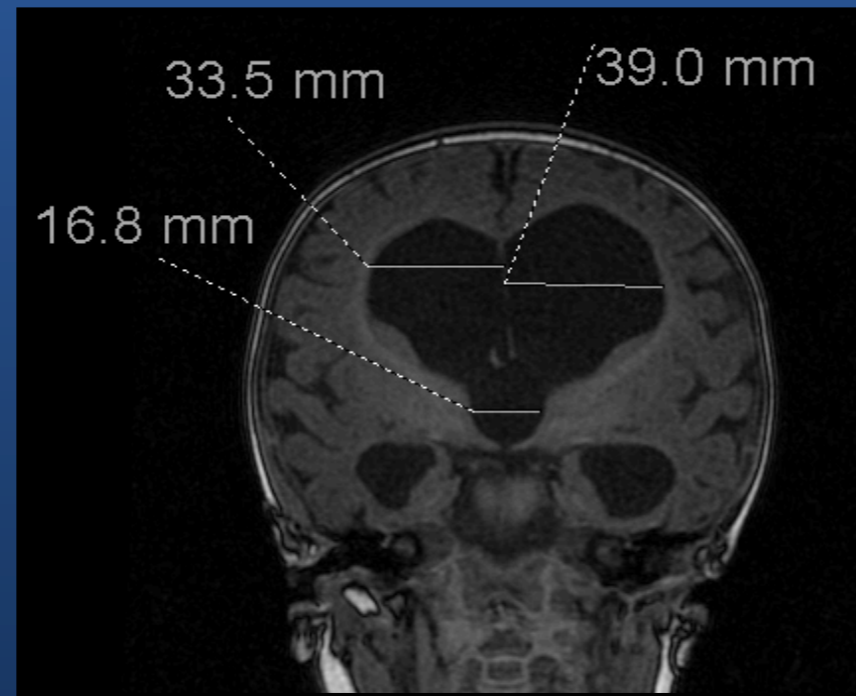
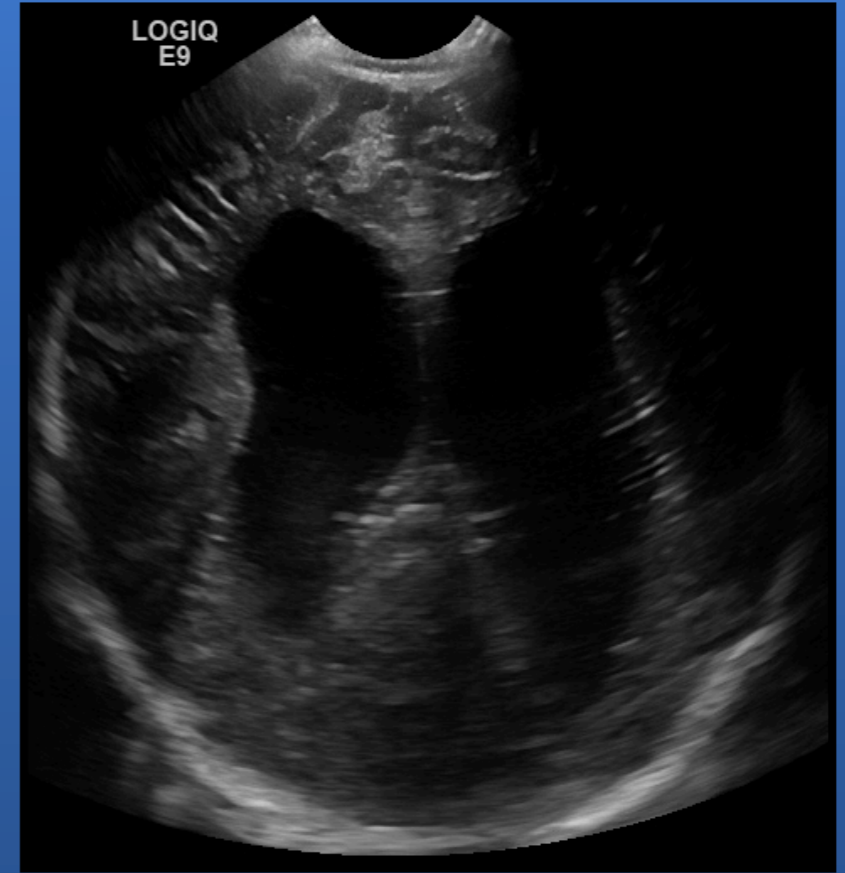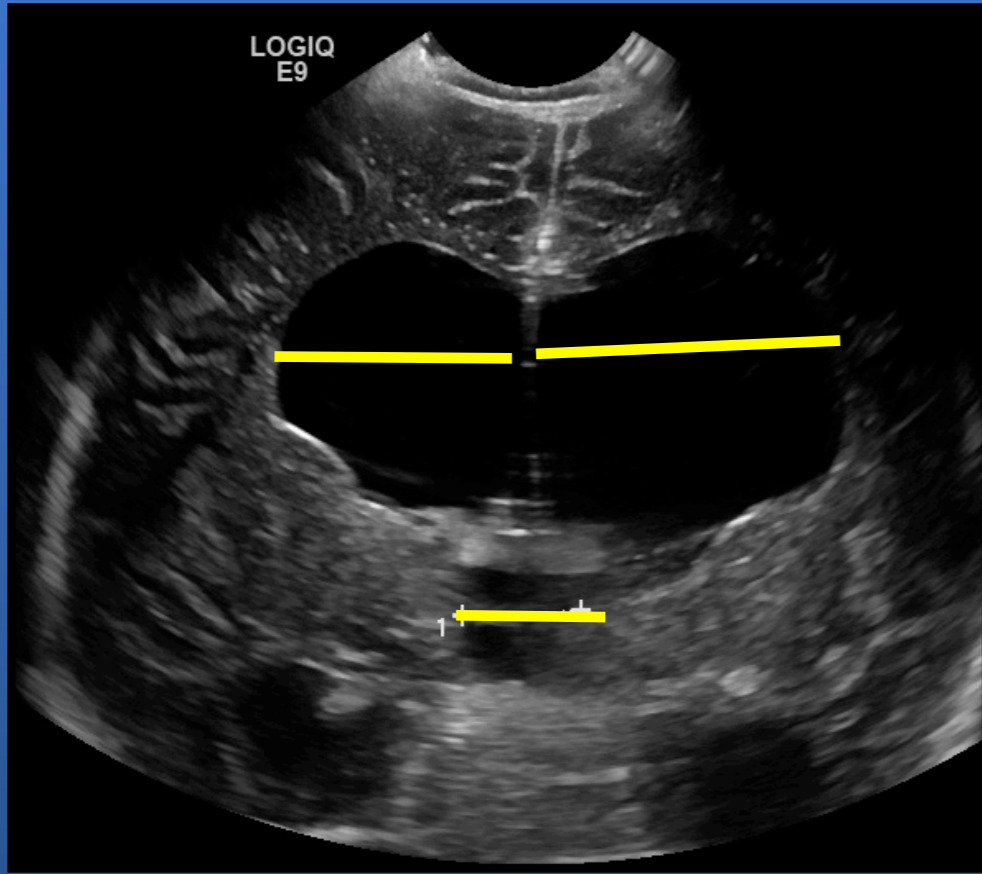


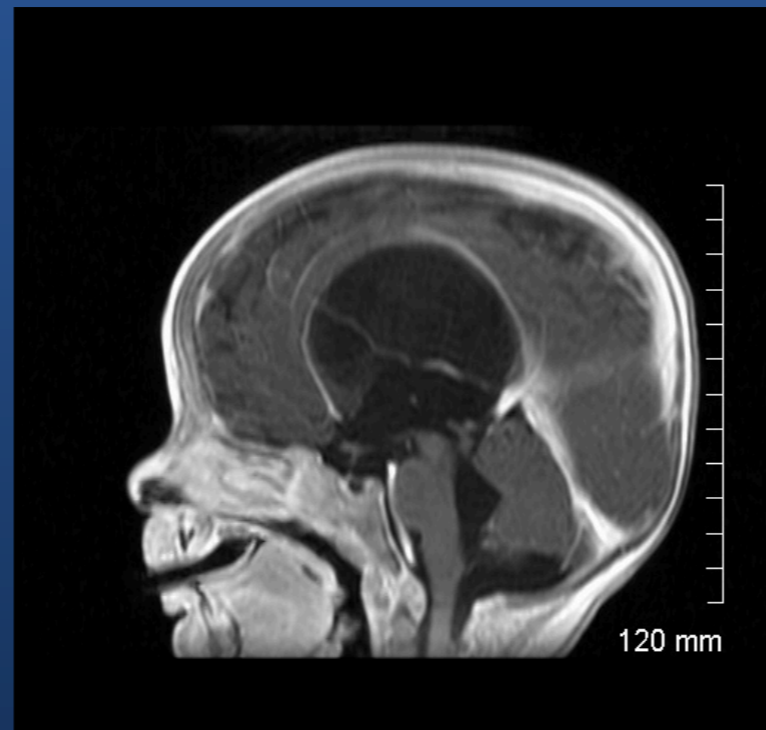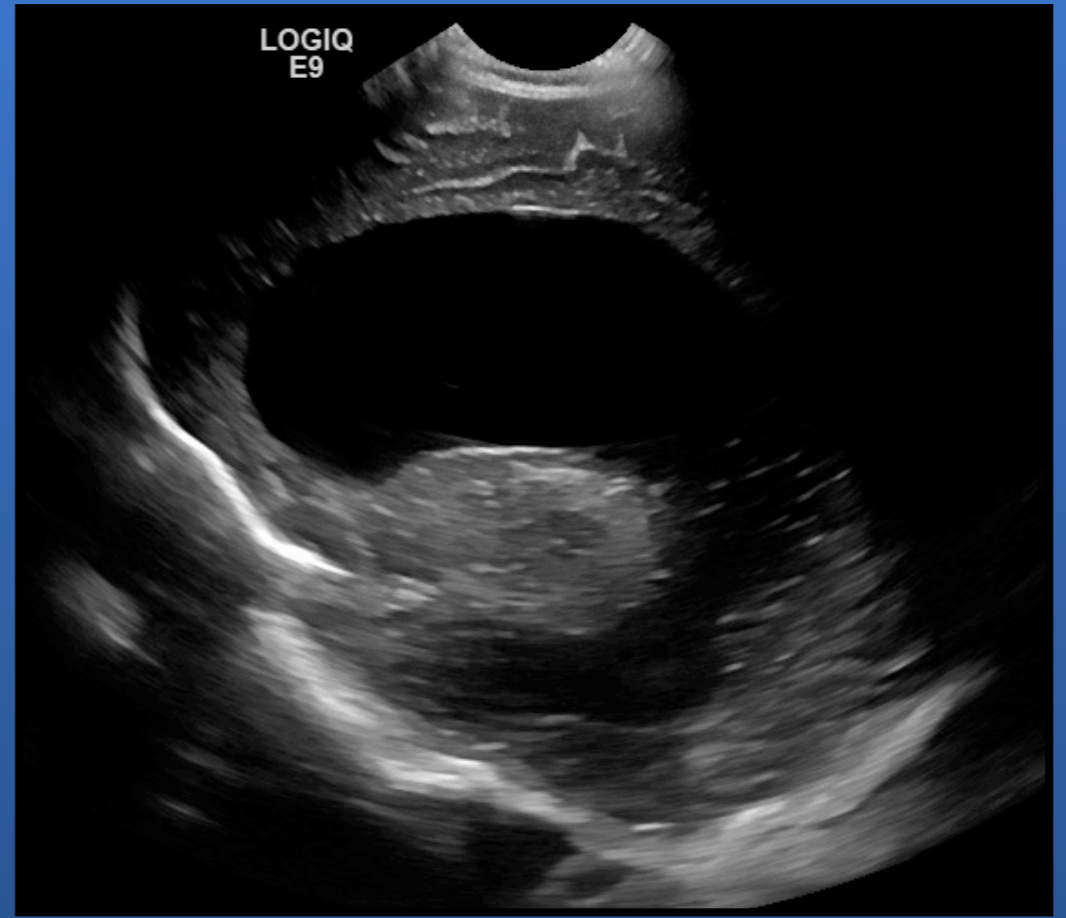
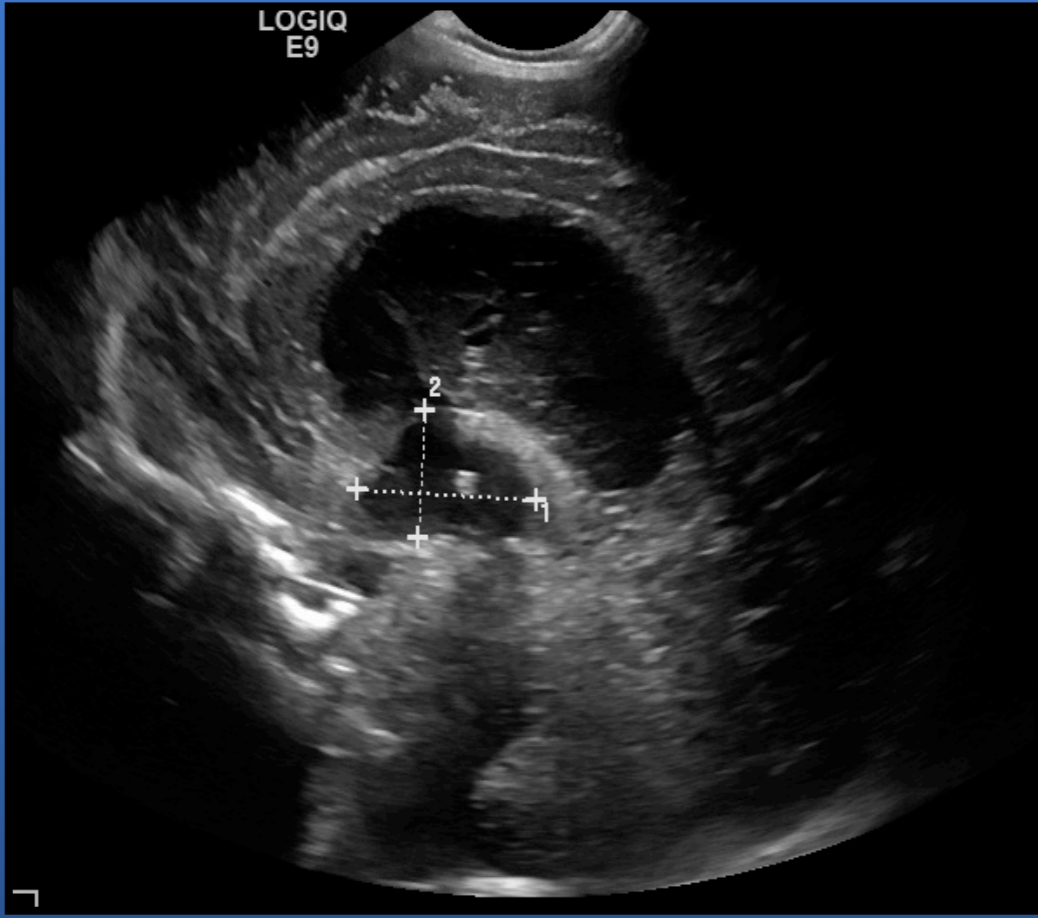
cc

v3



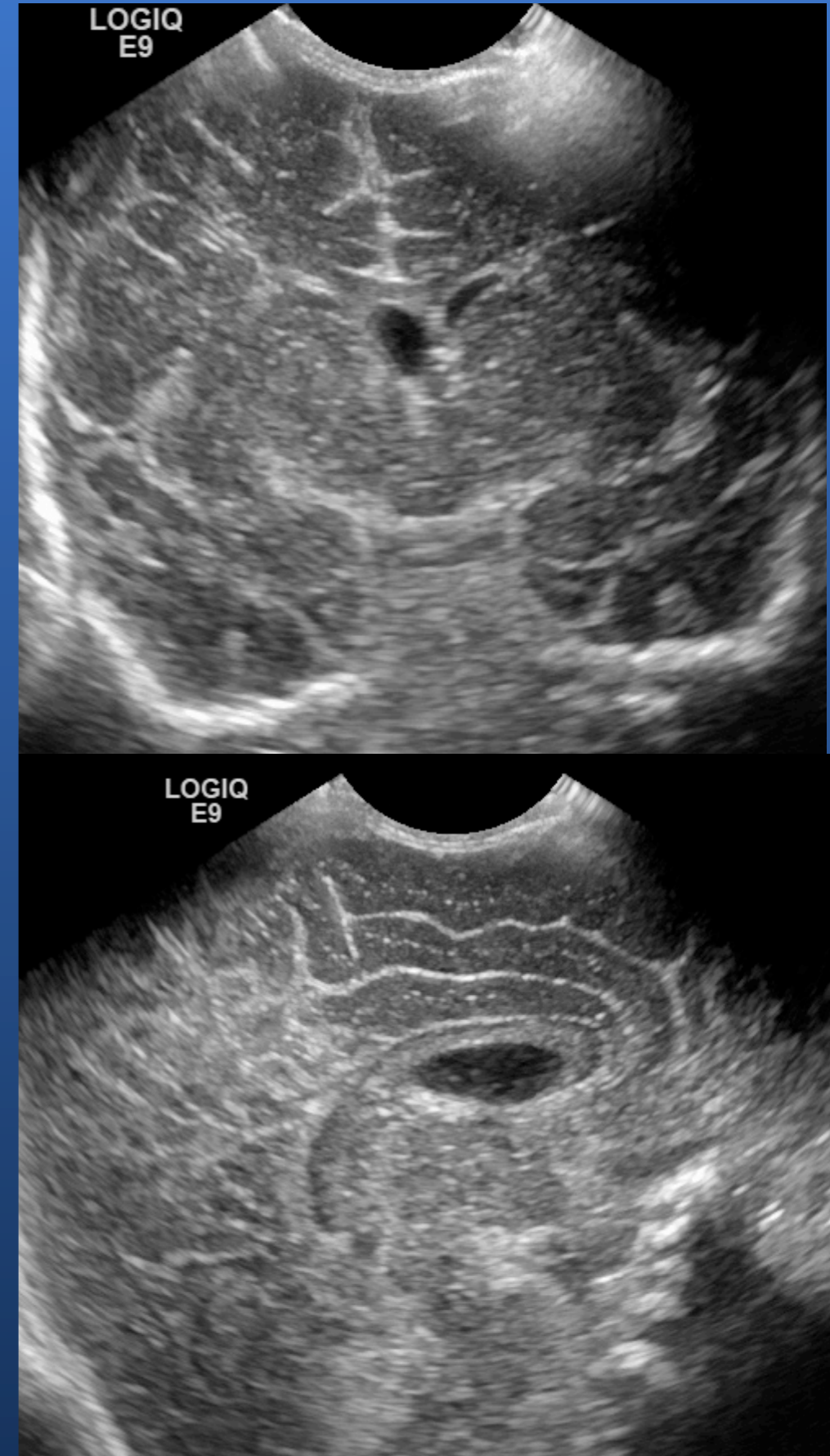DILATATION VENTRICULAIRE





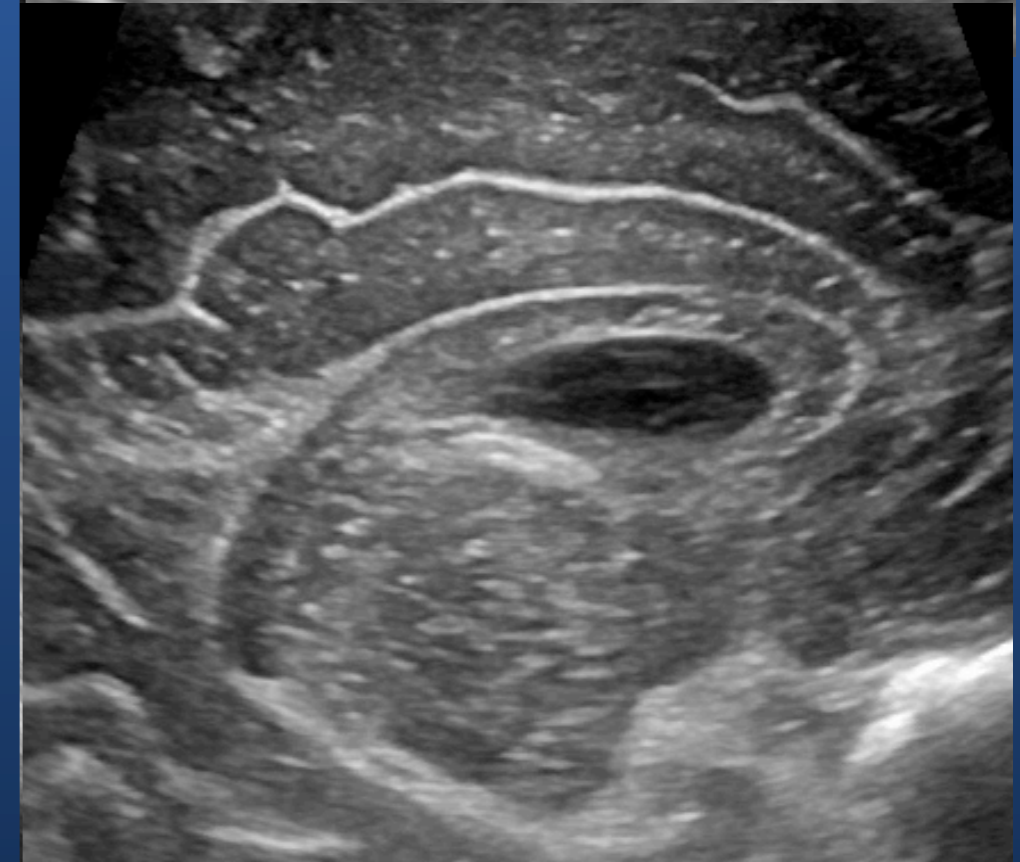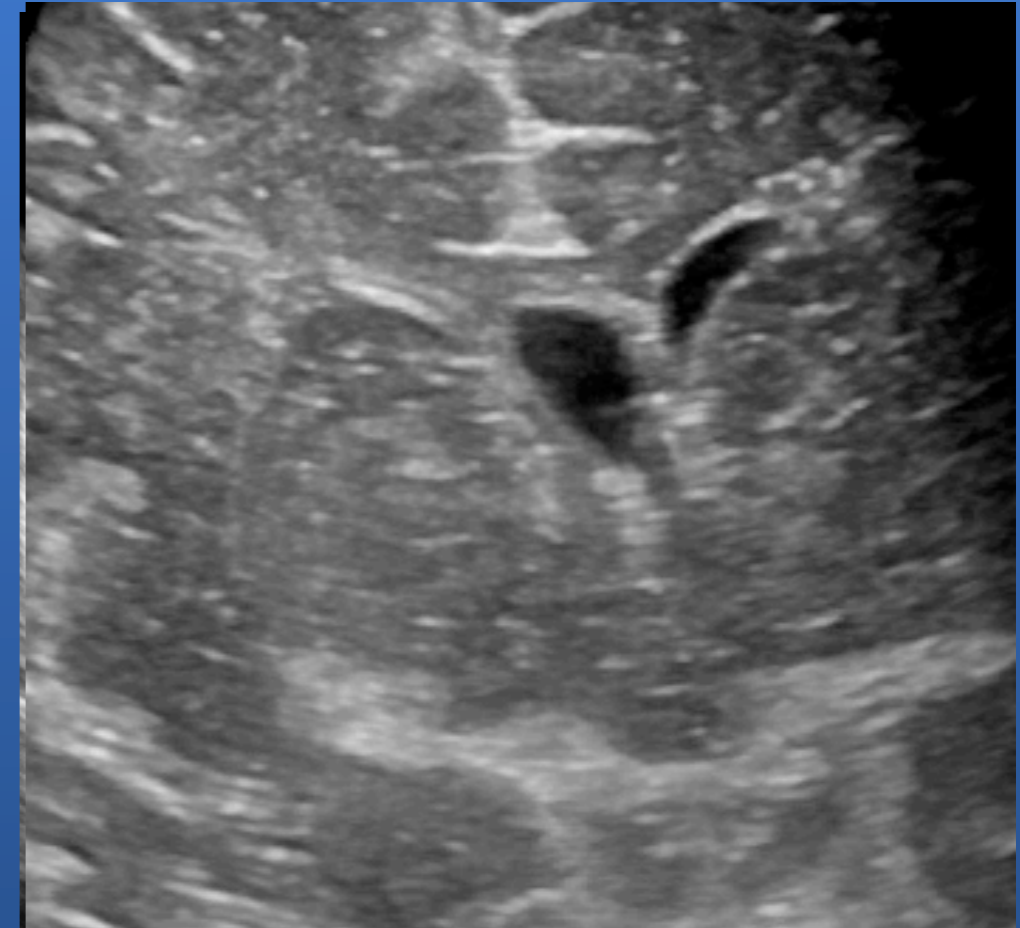KYSTE DU SEPTUM

- **Dédoubllement du septum lucidum**
 - Entre V3 et corps calleux
 - En DDS des V. latéraux
- **Physiologique, disparaît avec âge**
 - Prématuré : 100%
 - terme : 80%
 - 3 mois : 20%
- **Prolongement postérieur :**
 - Cavum vergae



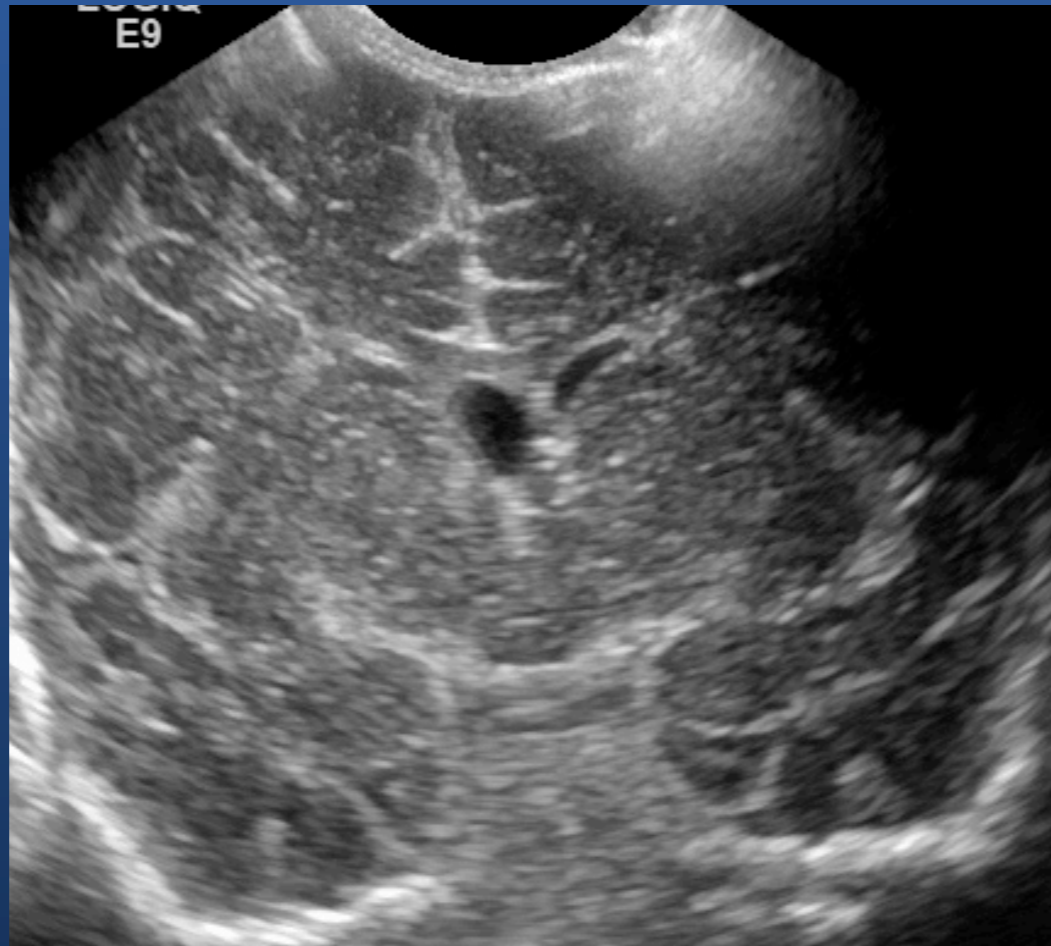
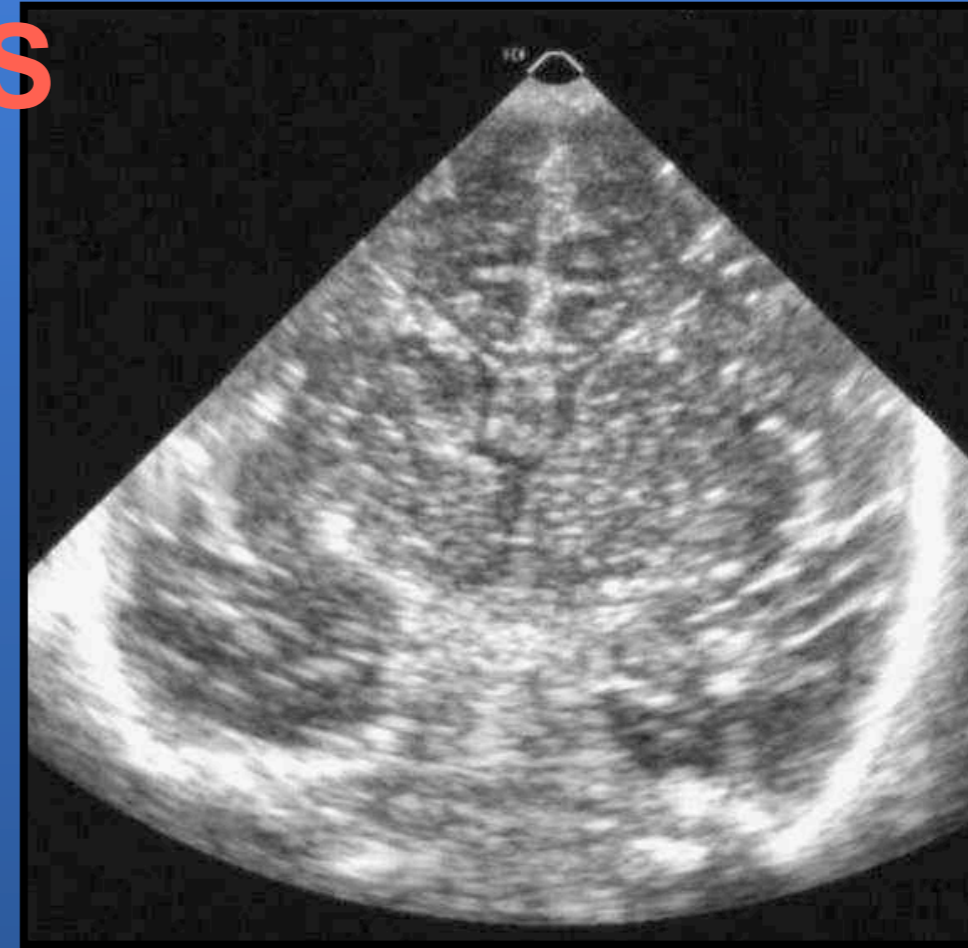KYSTE DU SEPTUM

- **Dédoubllement du septum lucidum**
 - Entre V3 et corps calleux
 - En DDS des V. latéraux
- **Physiologique, disparaît avec âge**
 - Prématuré : 100%
 - terme : 80%
 - 3 mois : 20%
- **Prolongement postérieur :**
 - Cavum vergae



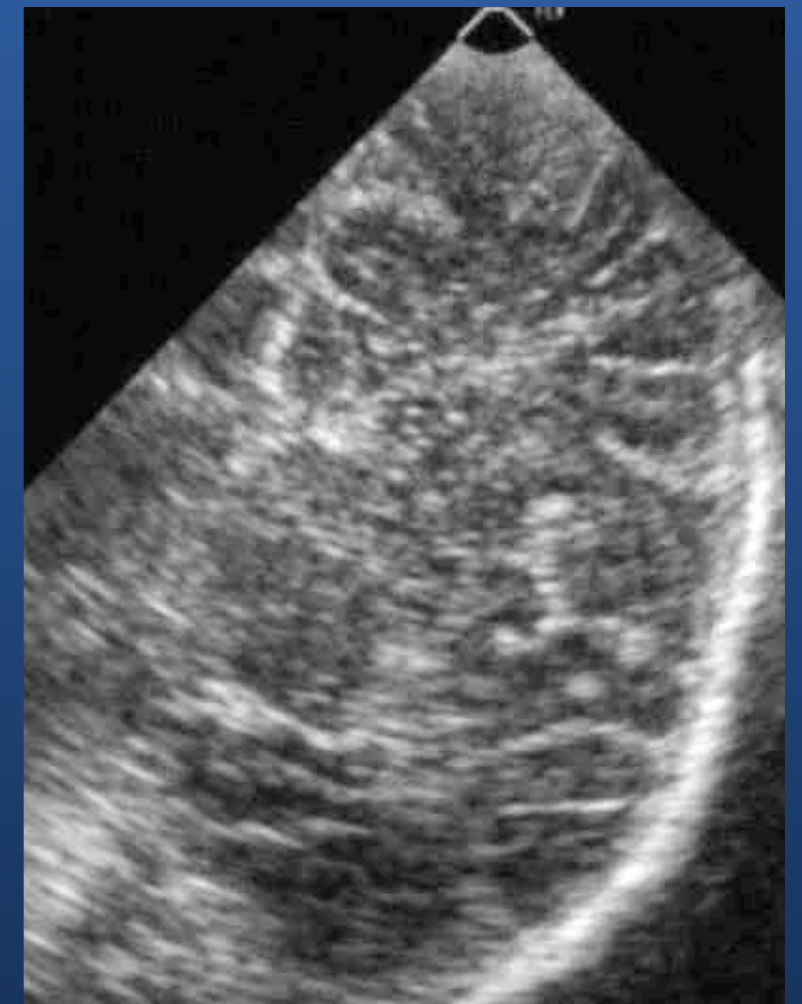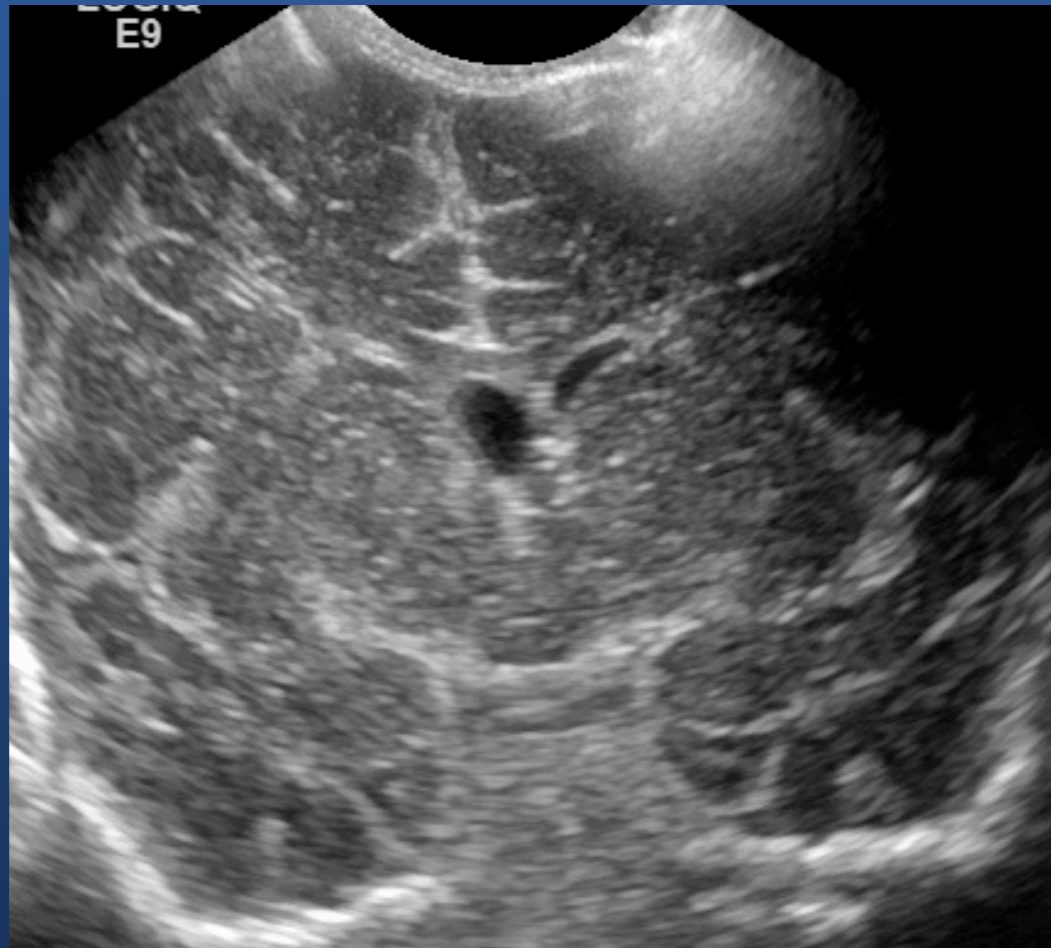
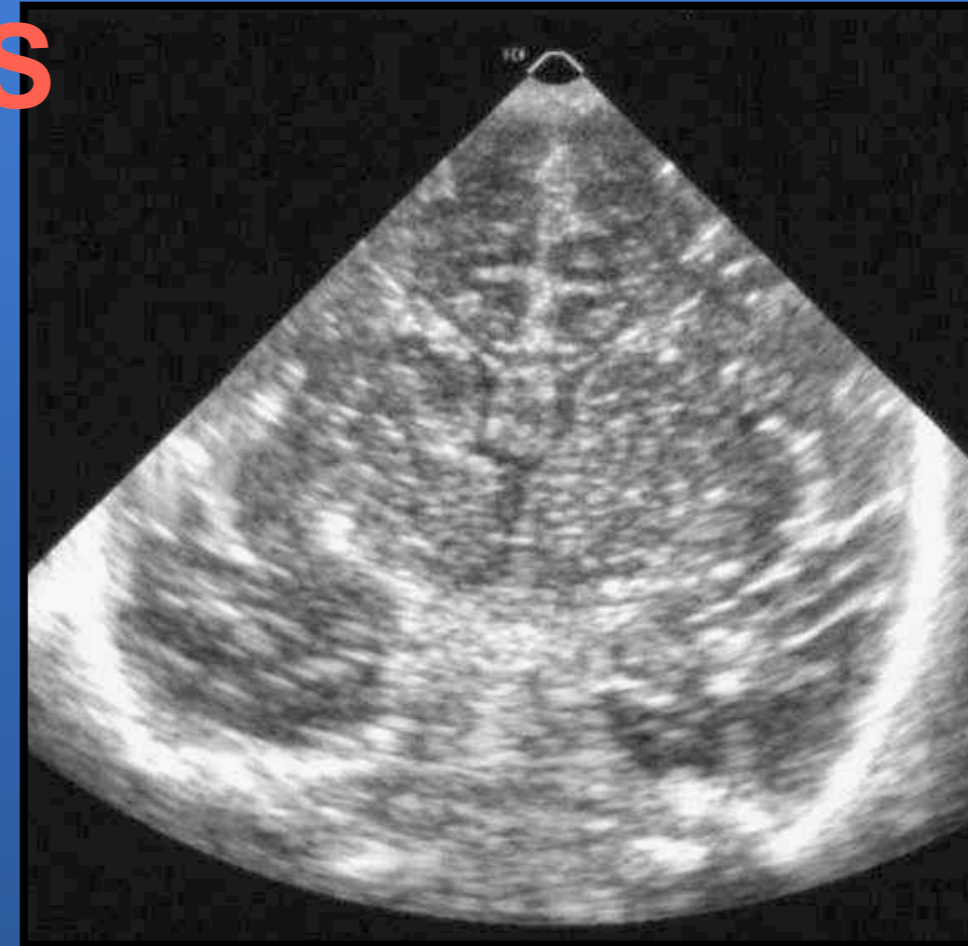HEMISPHERES

- **Étude morphologique**
 - Bilatérale et symétrique
 - Unilatérale : convexité
- **Lobes et circonvolutions**
- **Sillons variables avec maturation**
- **Différenciation substance blanche/ grise ?**

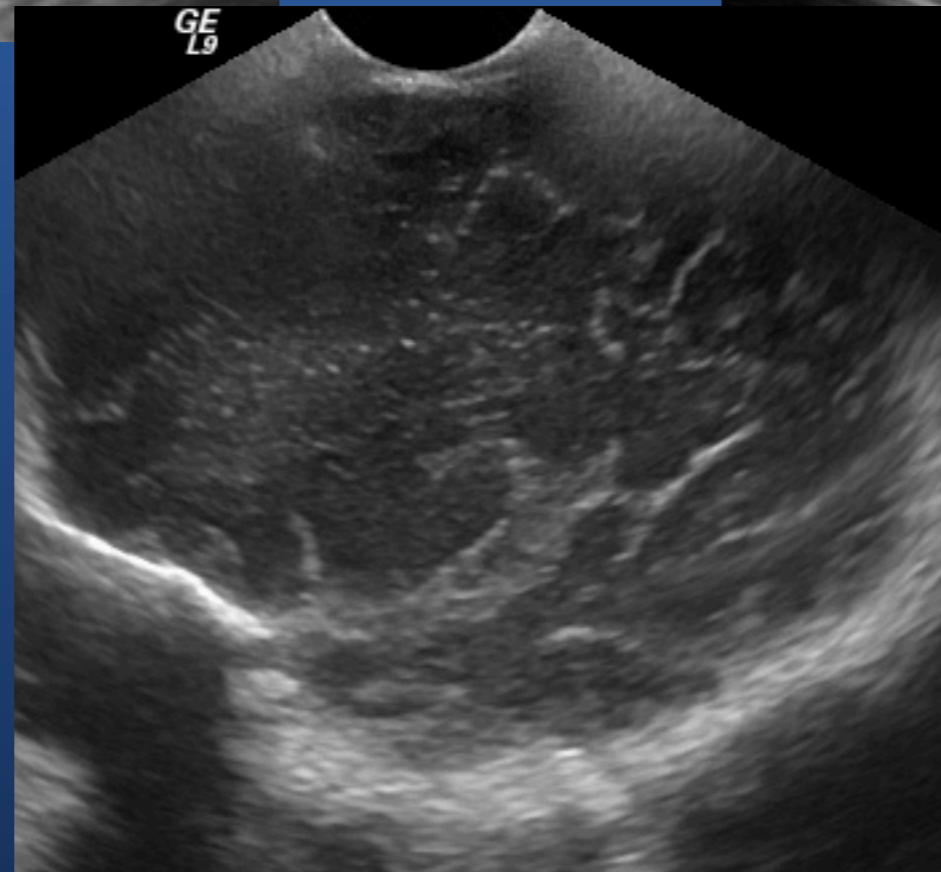
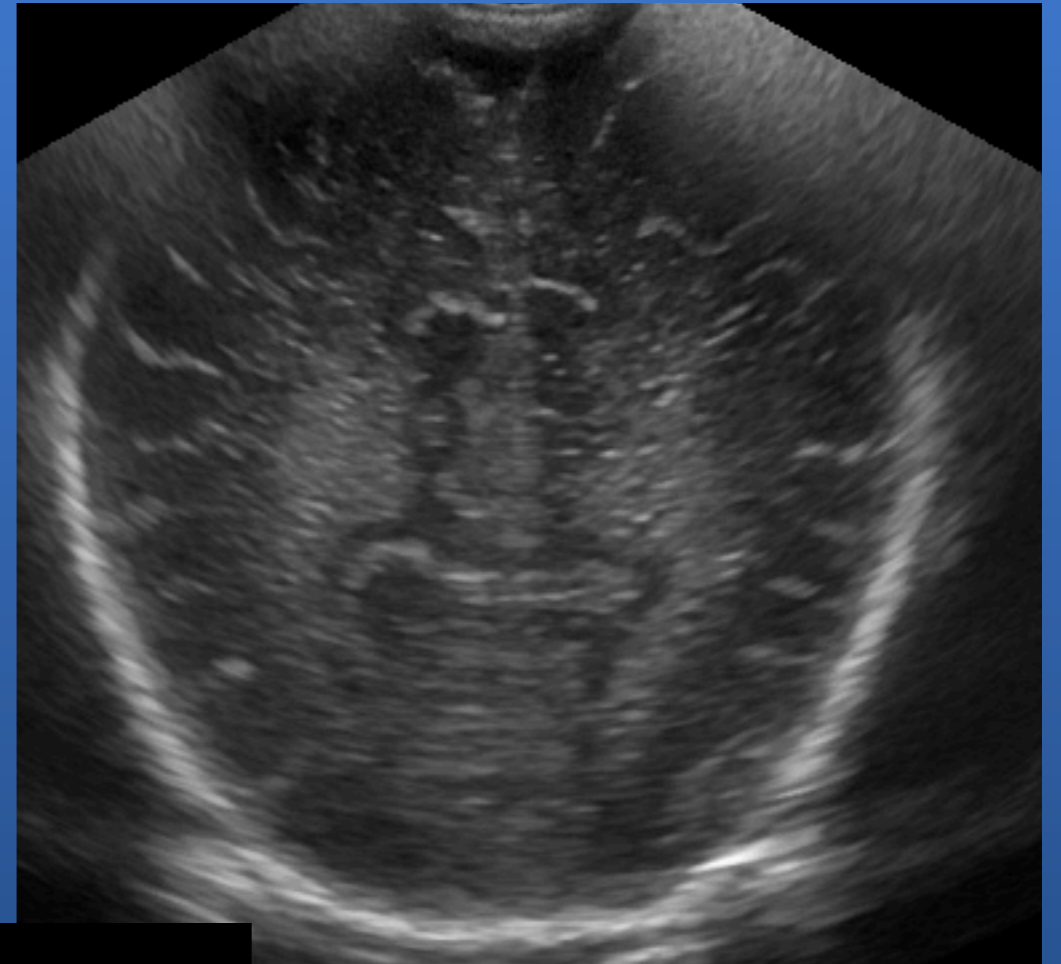
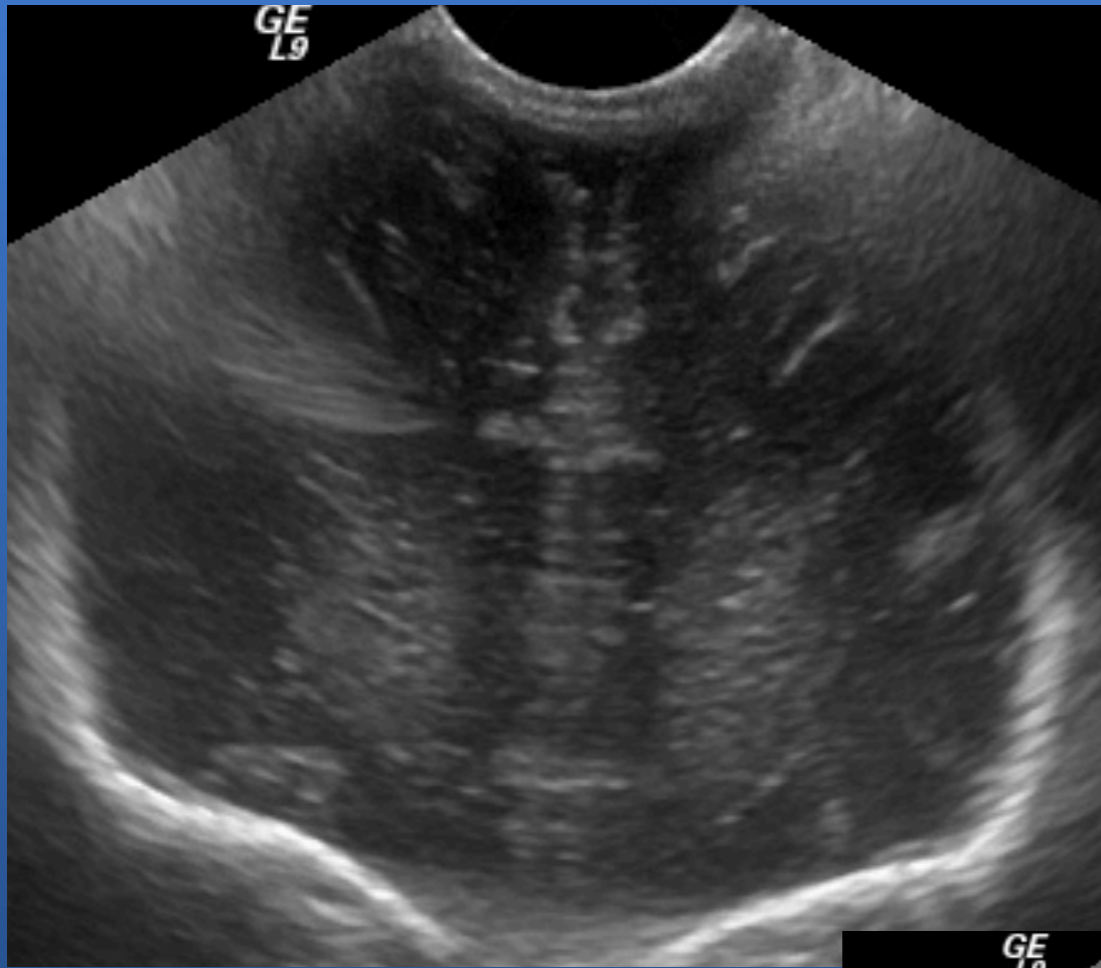


HEMISPHERES

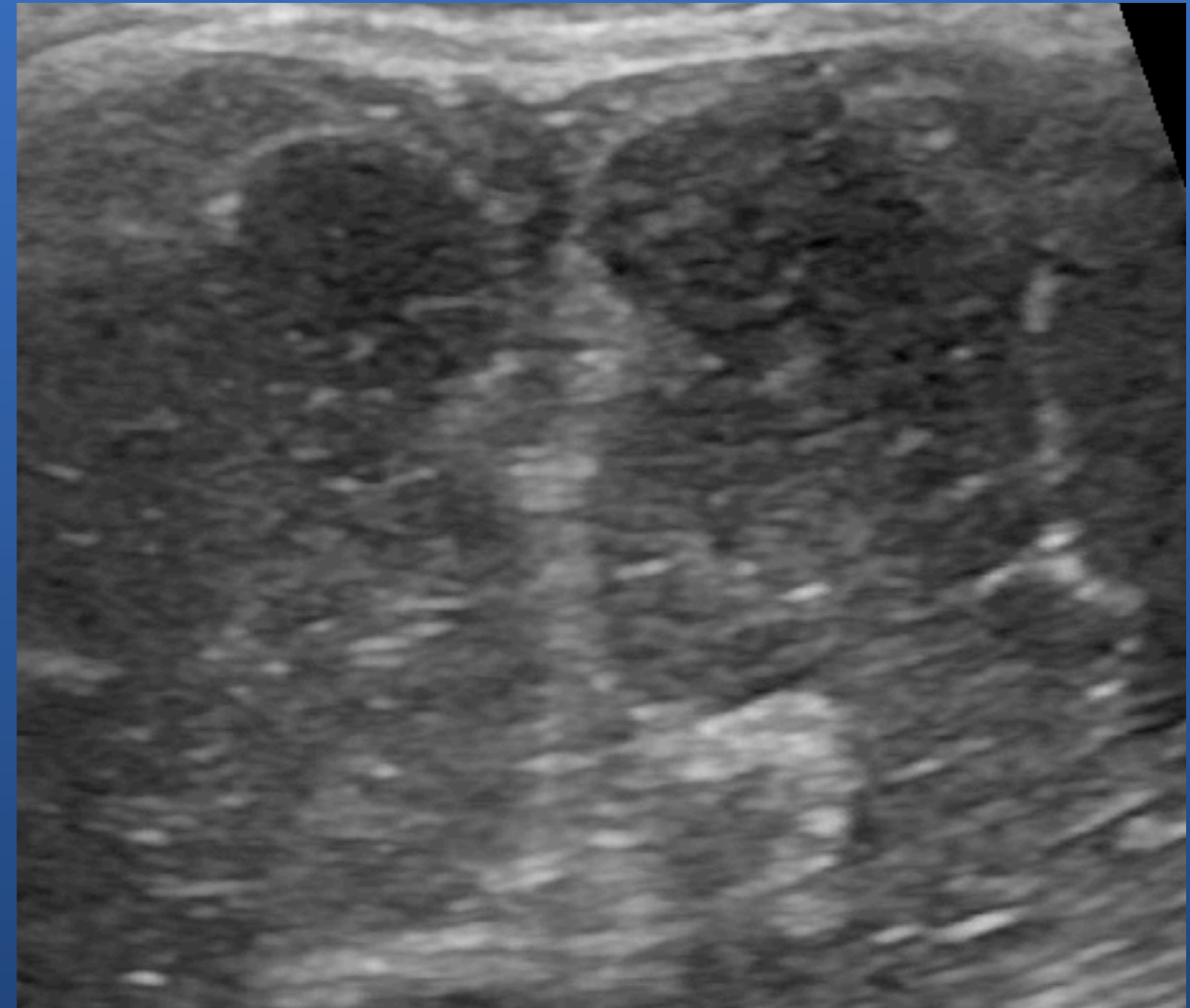
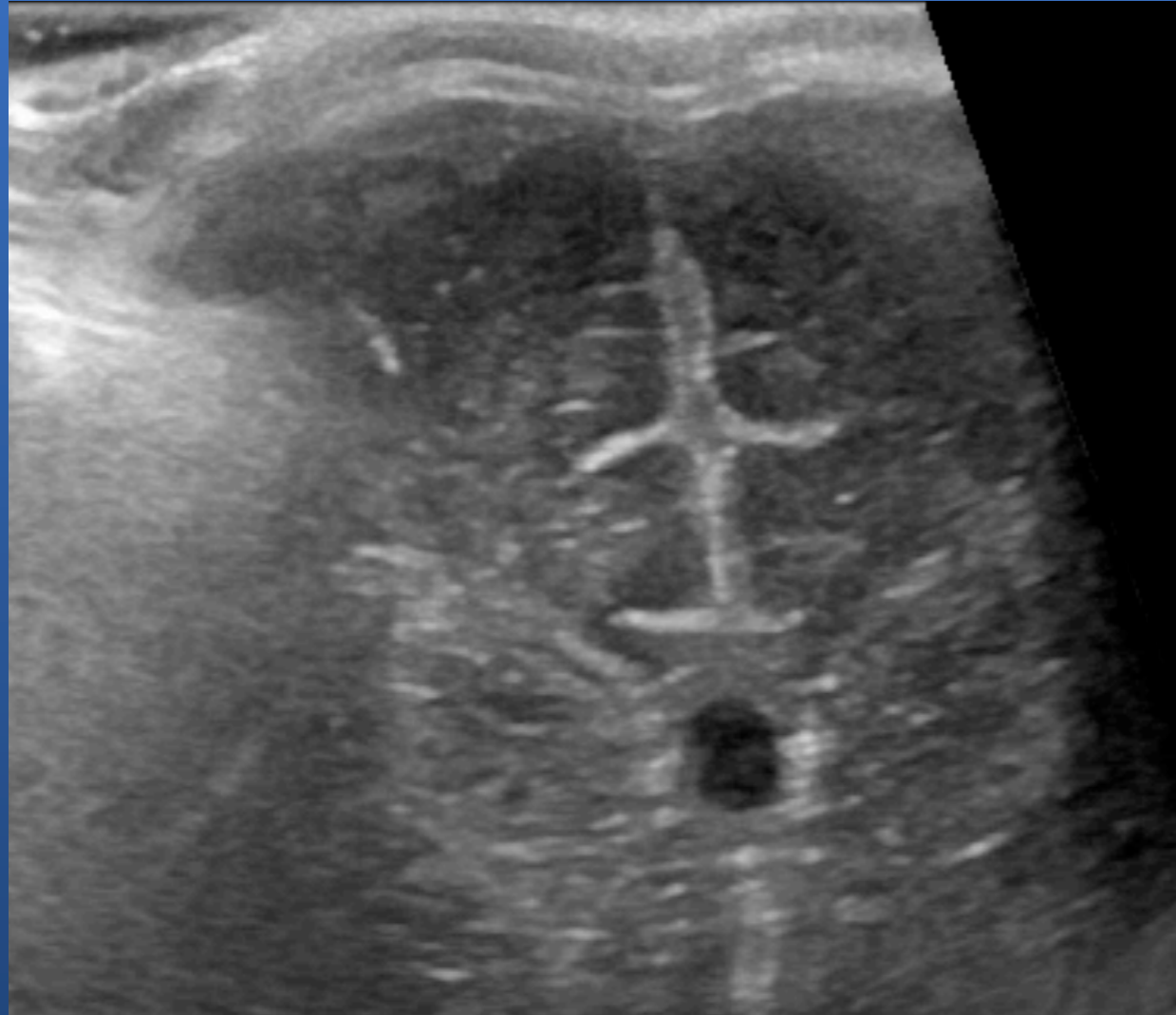
- **Étude morphologique**
 - Bilatérale et symétrique
 - Unilatérale : convexité
- **Lobes et circonvolutions**
- **Sillons variables avec maturation**
- **Différenciation substance blanche/ grise ?**



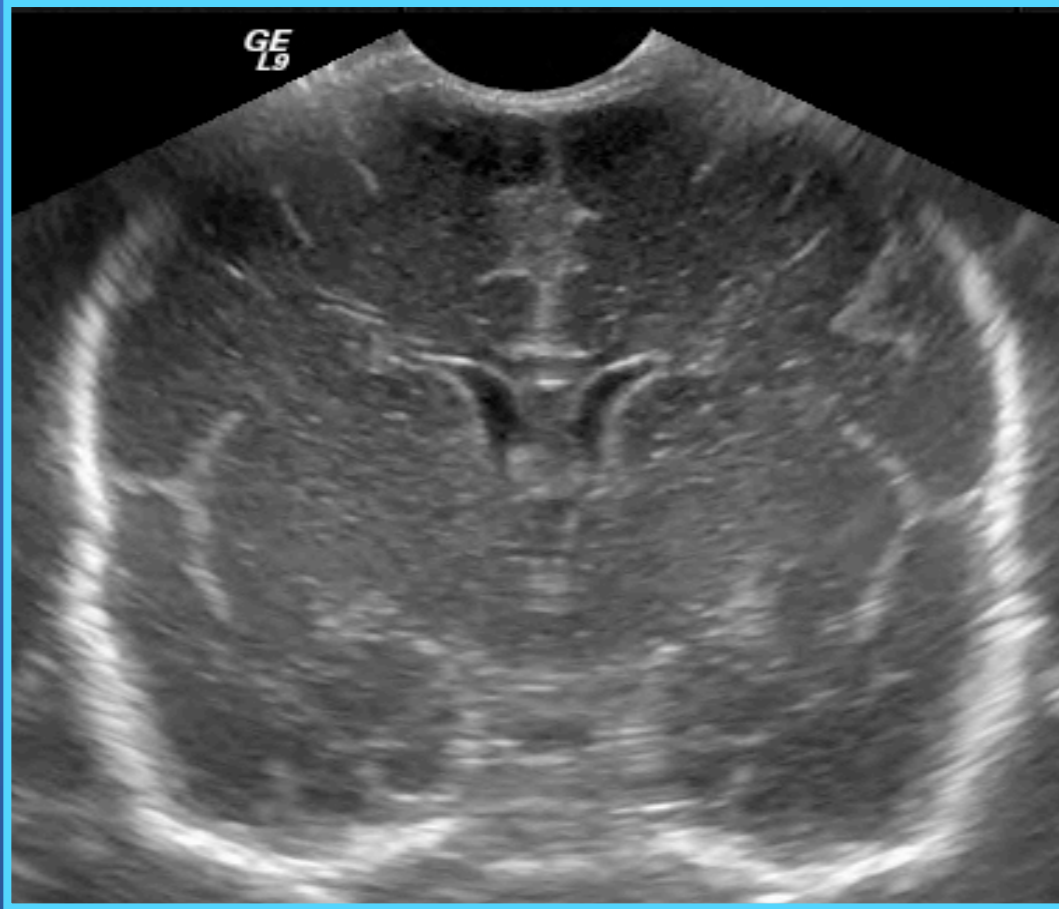
HEMISPHERES



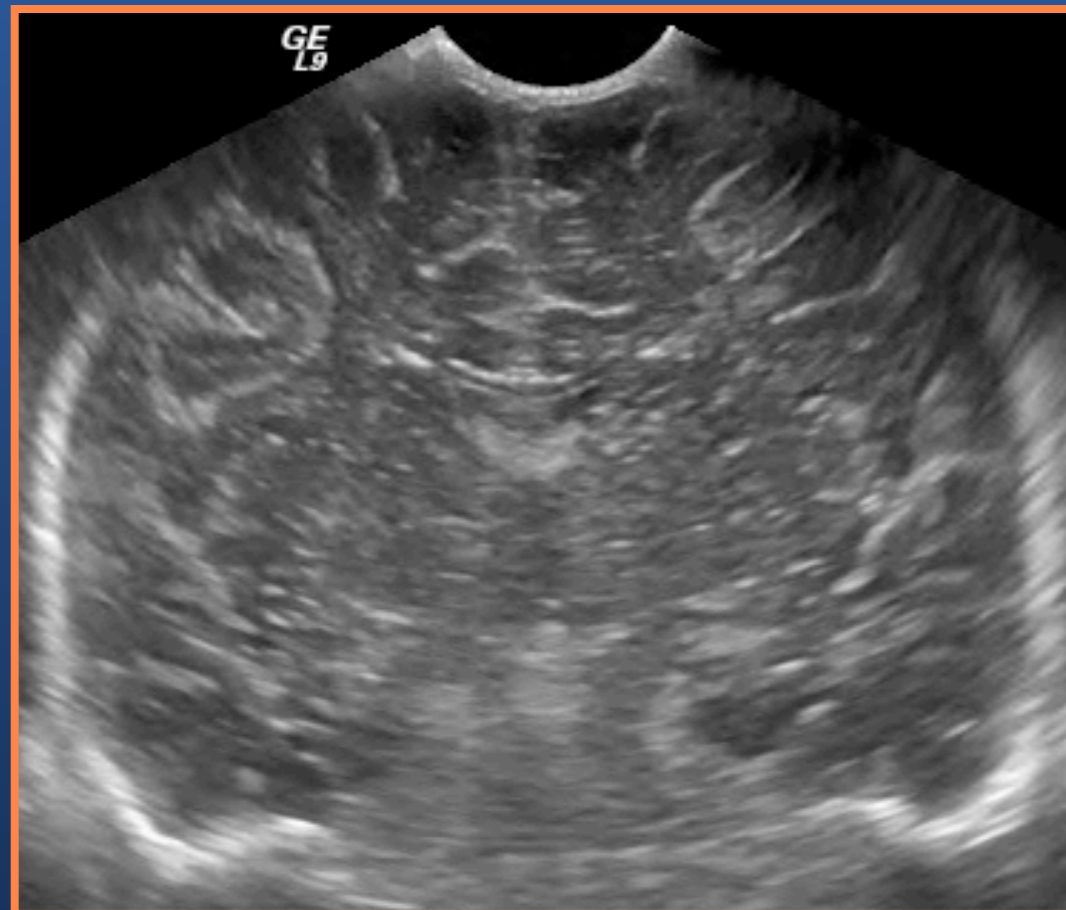
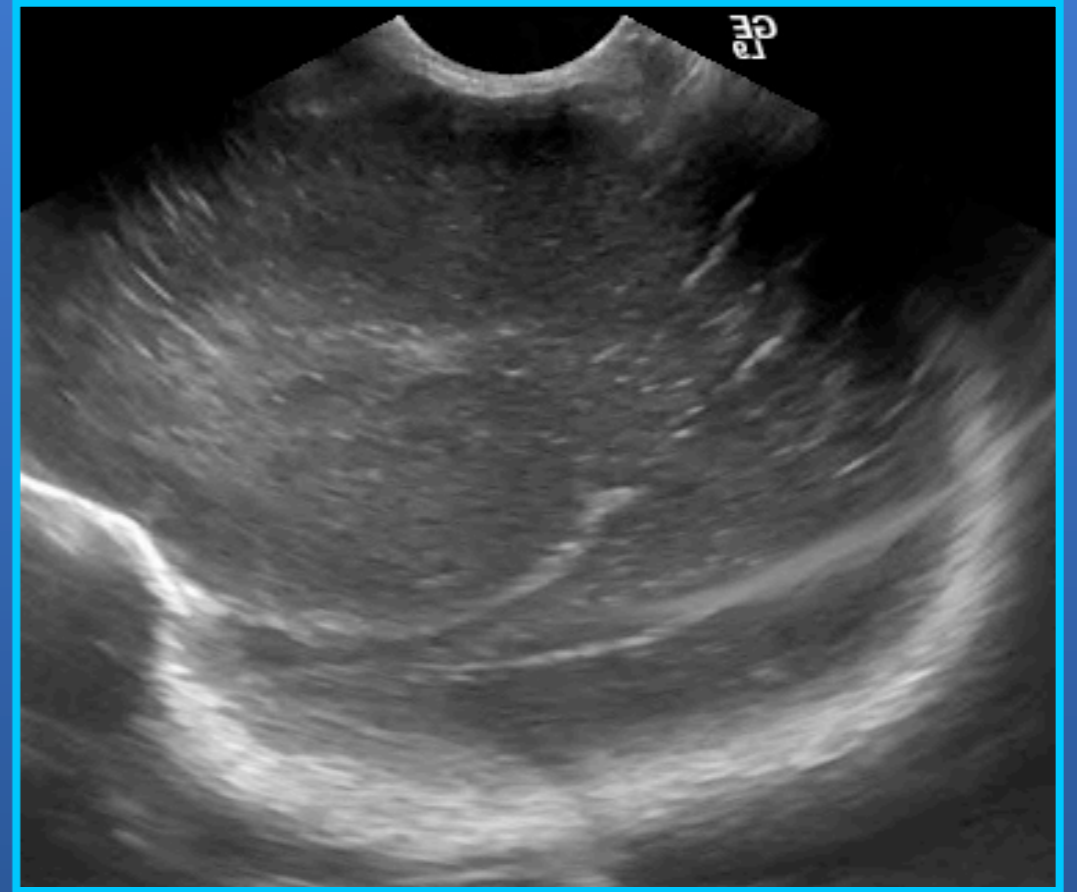
HEMISPHERES



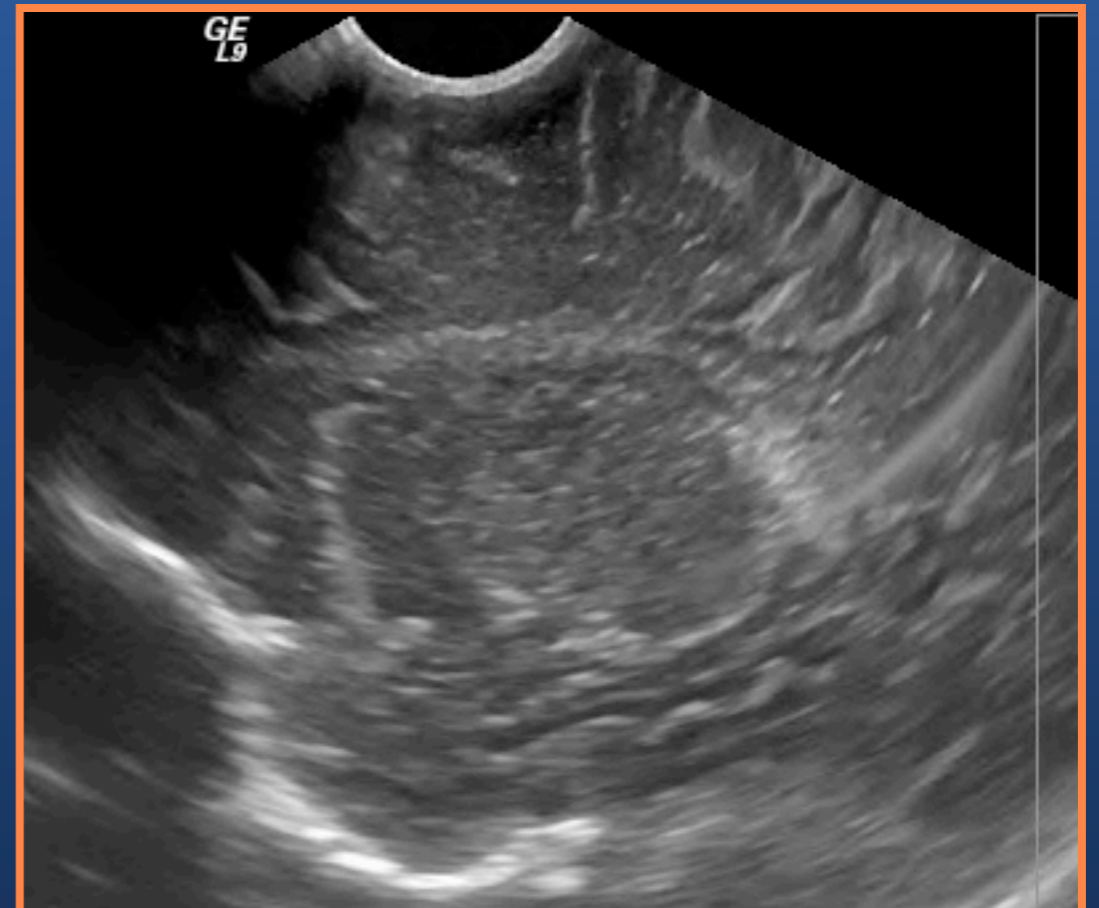
Maturation cérébrale



32 SA



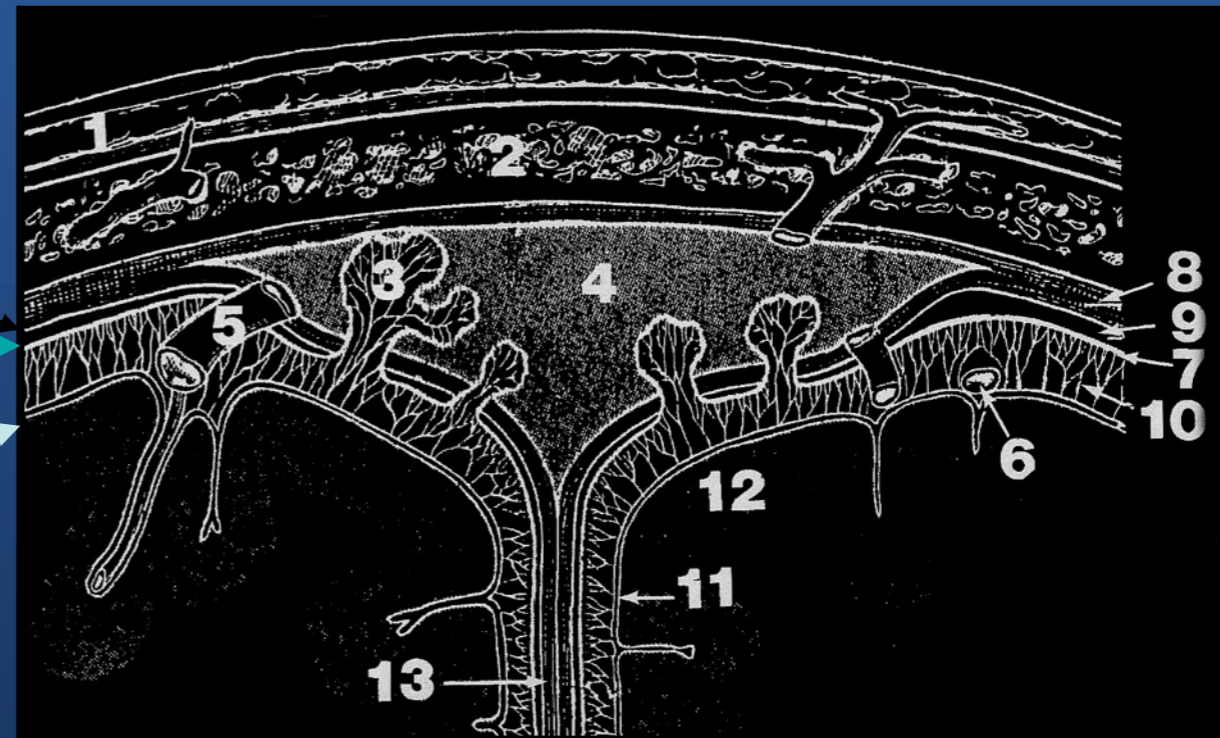
35 SA



ESPACES PERI-CEREBRAUX

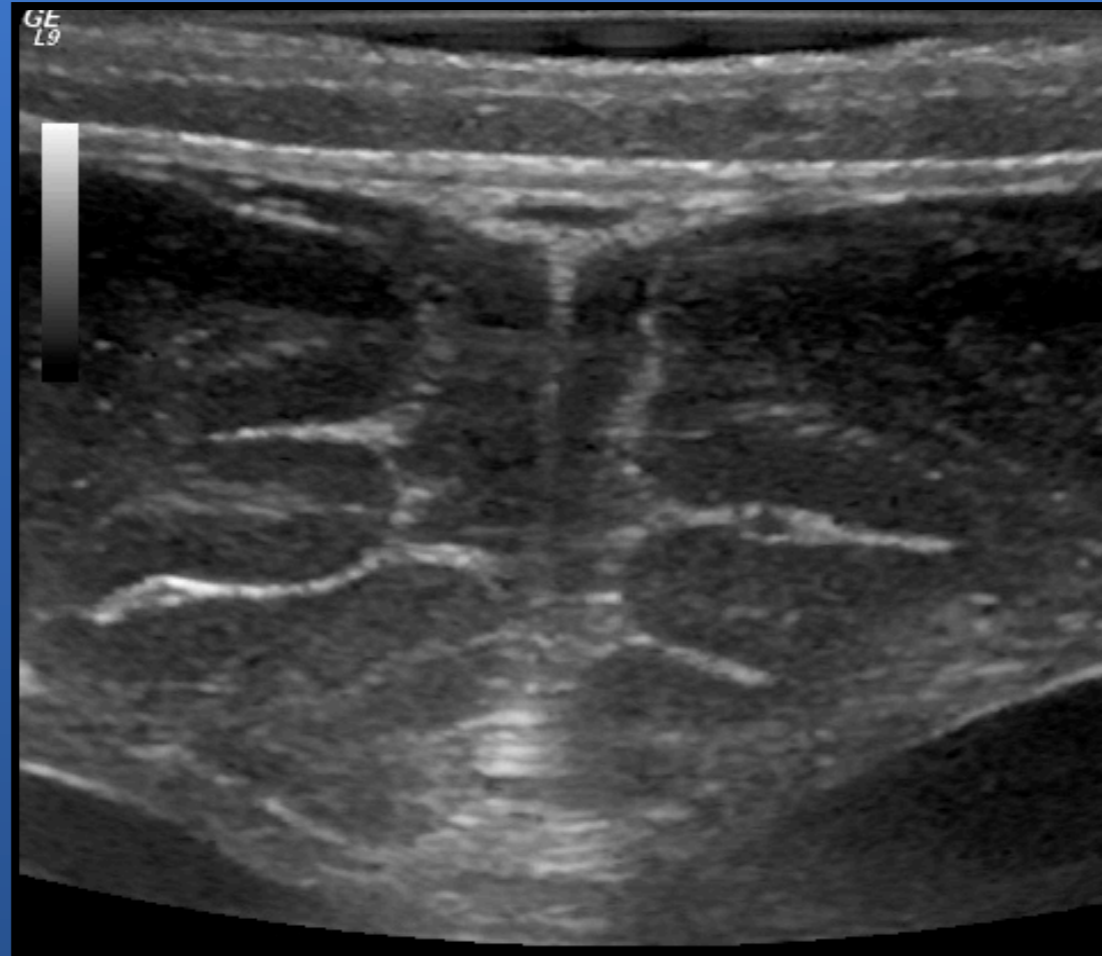- **Contiennent le LCR ,de taille variable**
cisternes,sillons
- **Cloisonnés par faux et tente**
- **Traversés par vaisseaux**

DM Extra
Sous dural
AR dural
Sous-
PM arachnoïdien



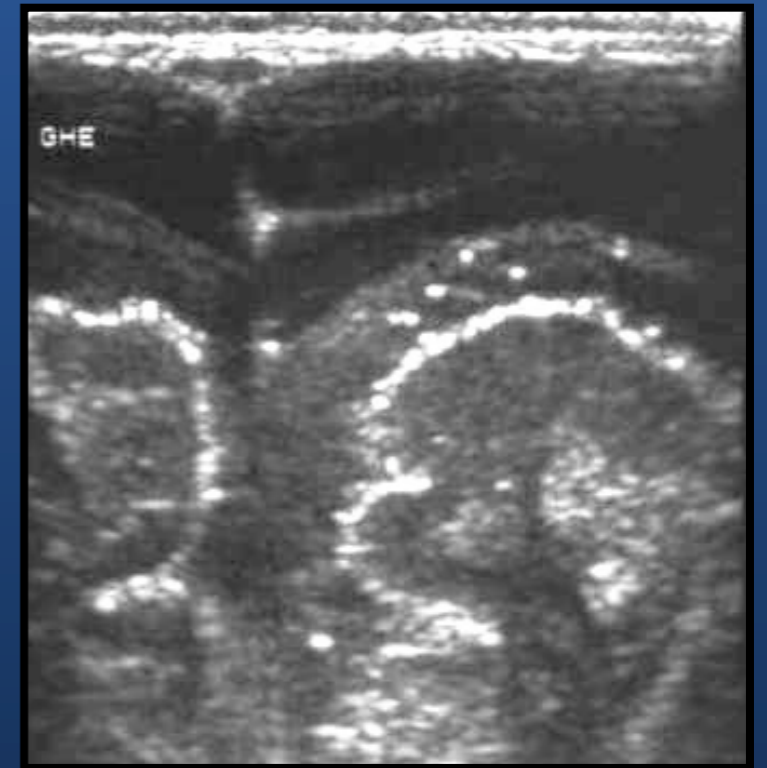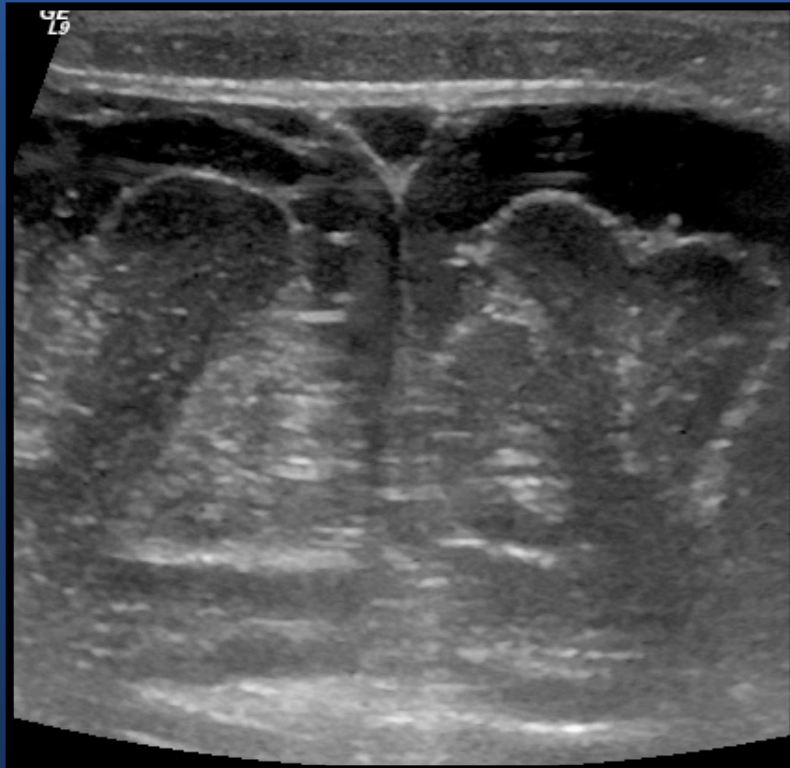ESPACES PERI-CEREBRAUX

Normal



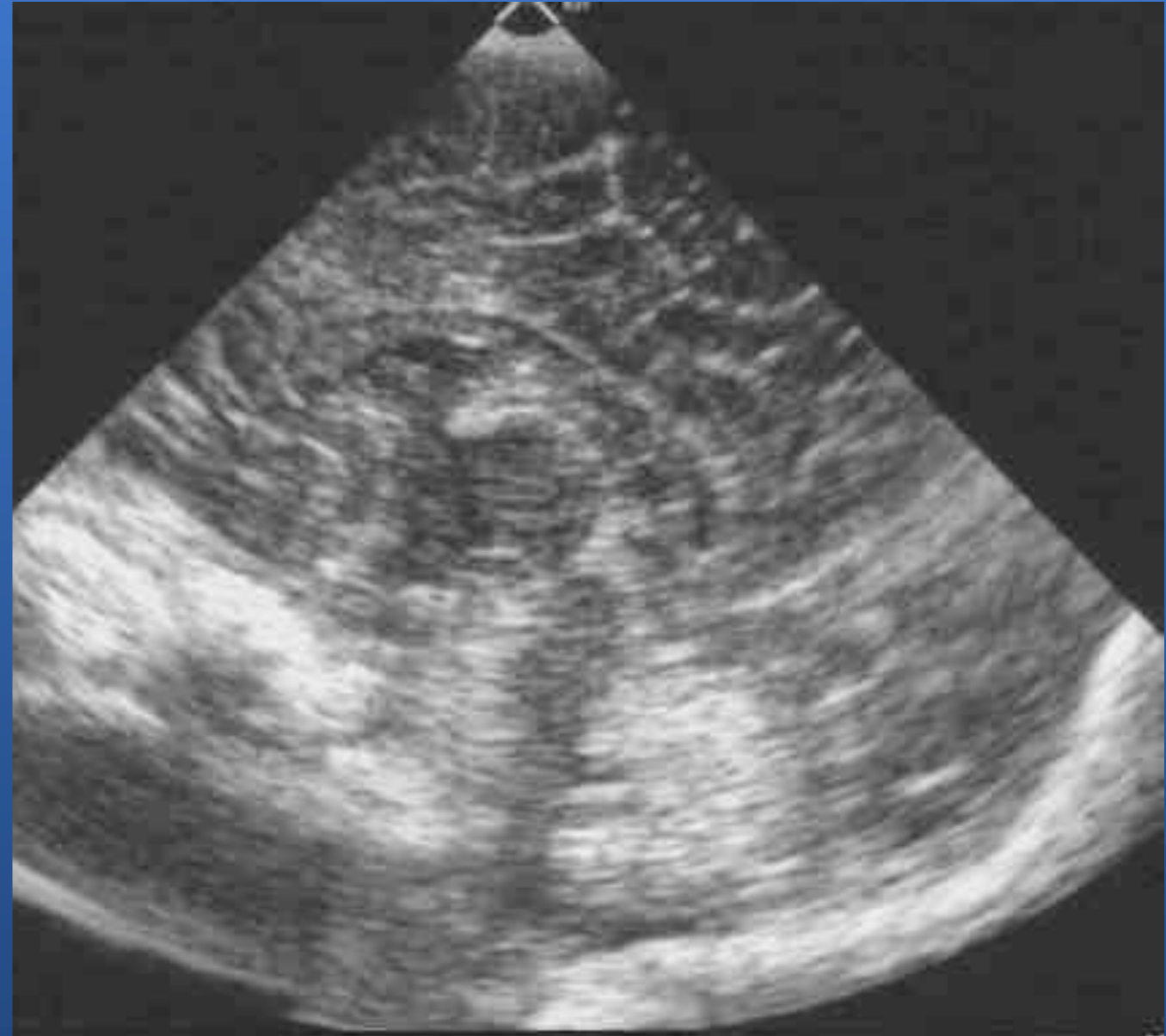Sous-arachnoïdien

Sous dural



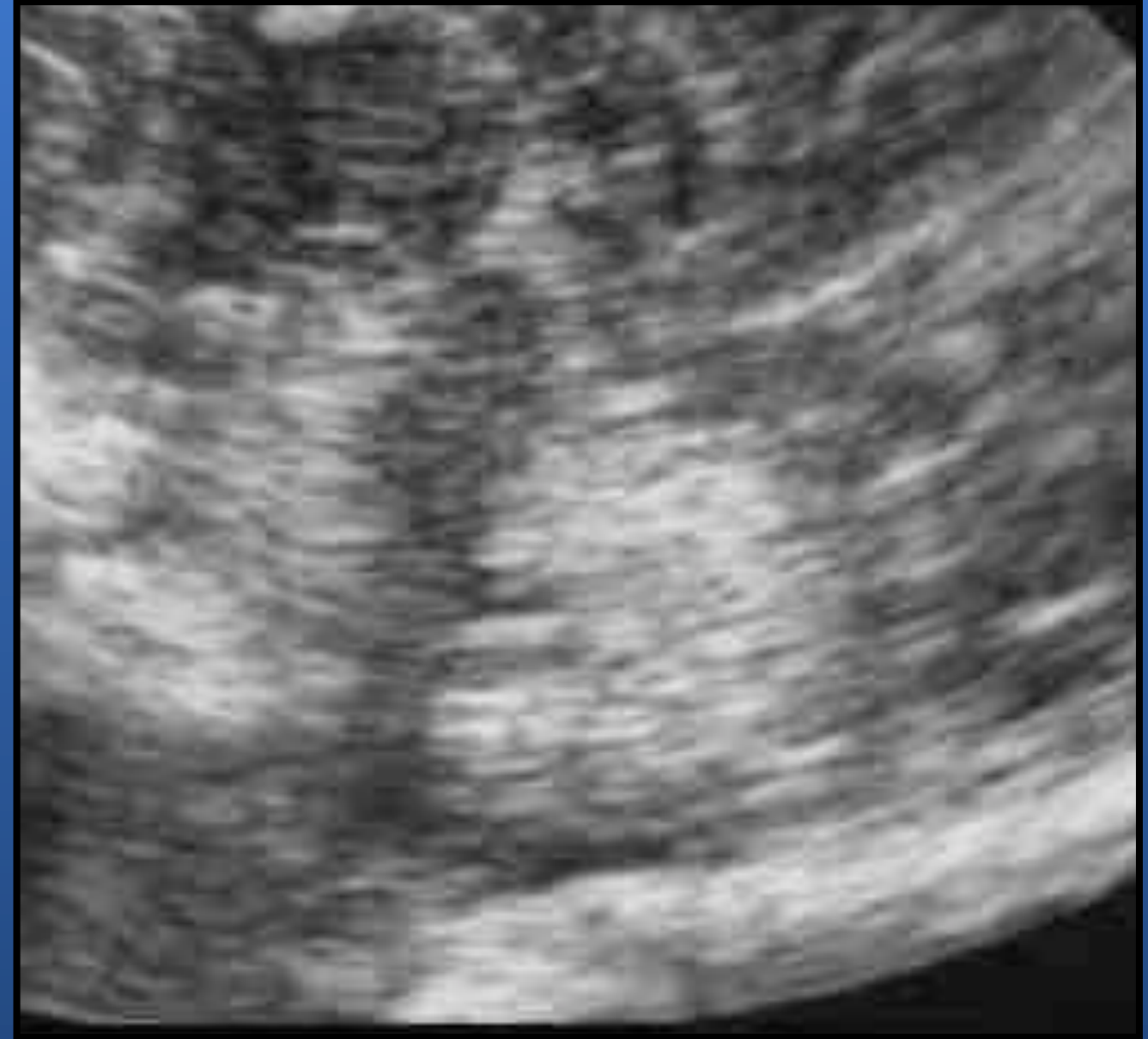FOSSE POSTERIEURE

- **Vermis hyperéchogène**
- **Tronc**
 - hyperéchogène en avant
 - hypoéchogène en arrière
- **4ème ventricule**
 - Médian, concavité post
- **Citernes**
 - grande citerne, pré-pontique
- **Orientation de la tente**



FOSSE POSTERIEURE

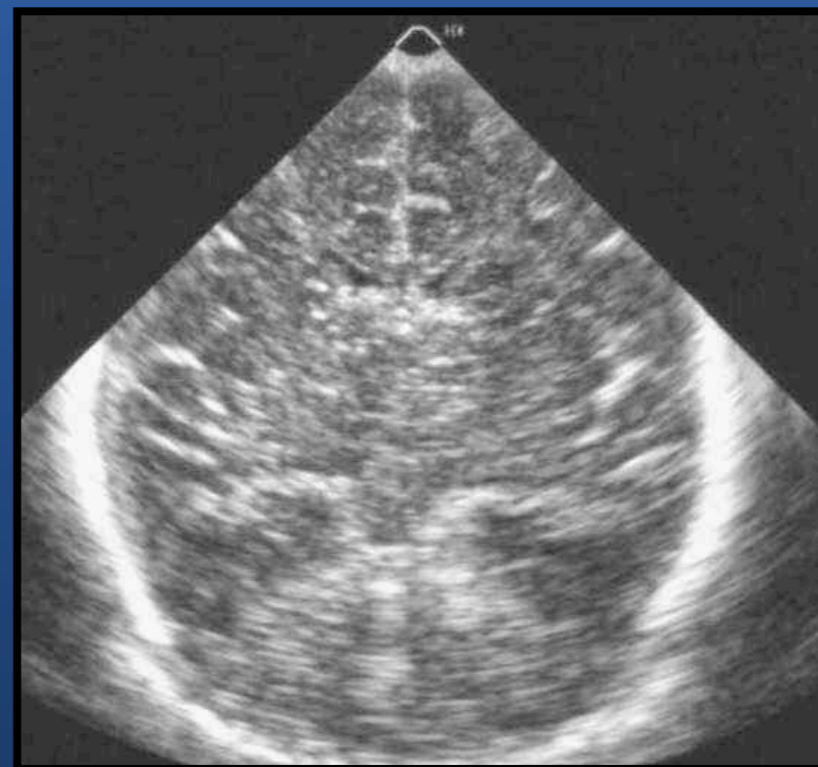
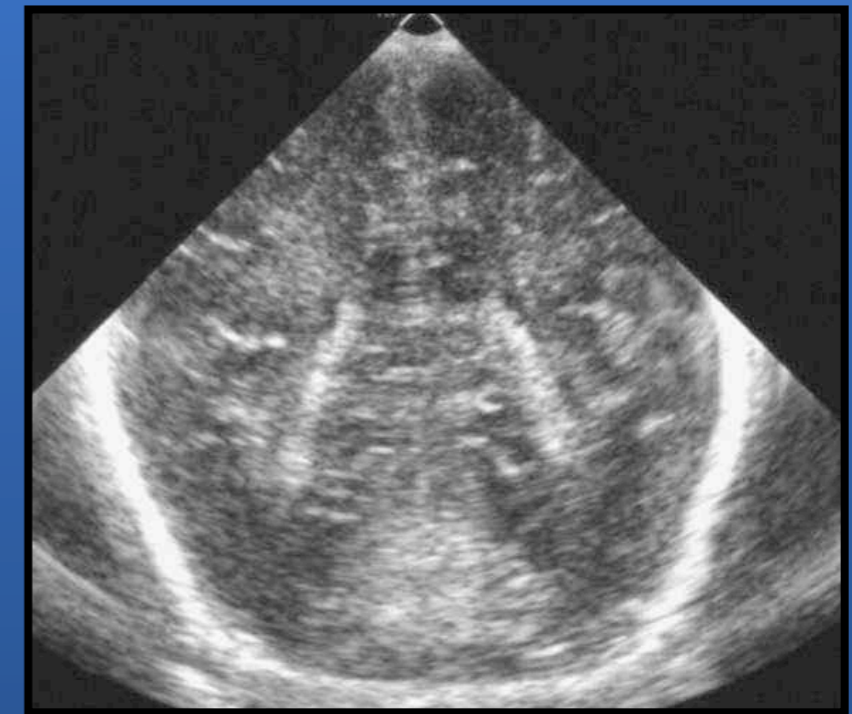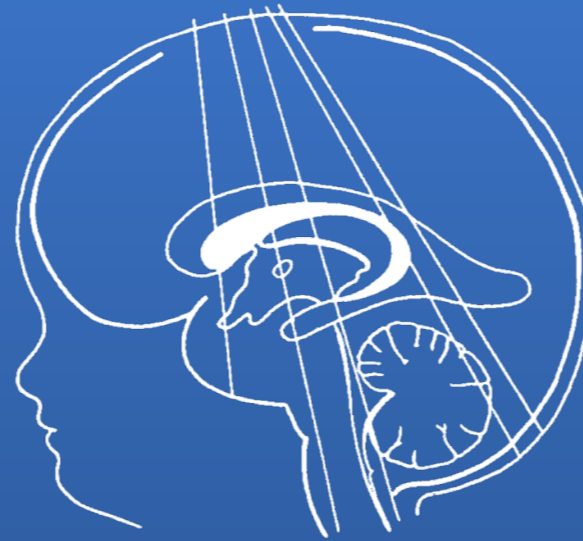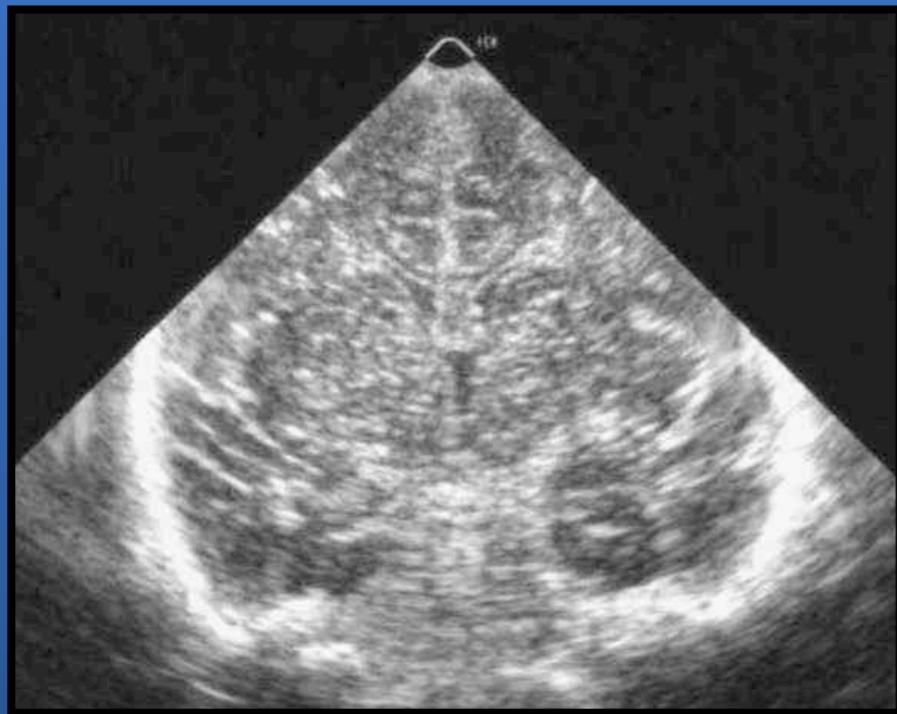- **Vermis hyperéchogène**
- **Tronc**
 - hyperéchogène en avant
 - hypoéchogène en arrière
- **4ème ventricule**
 - Médian, concavité post
- **Citernes**
 - grande citerne, pré-pontique
- **Orientation de la tente**



V4

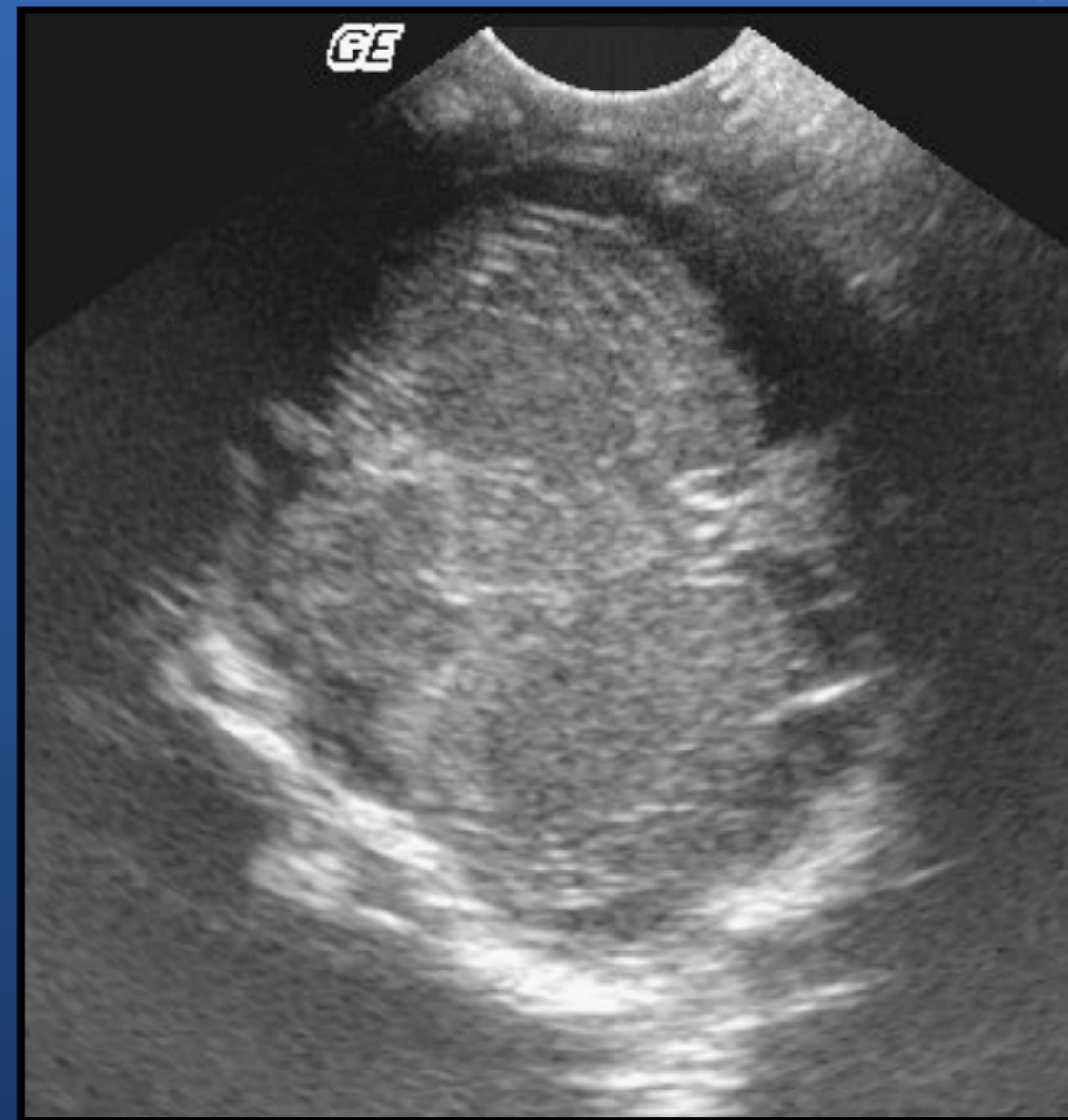
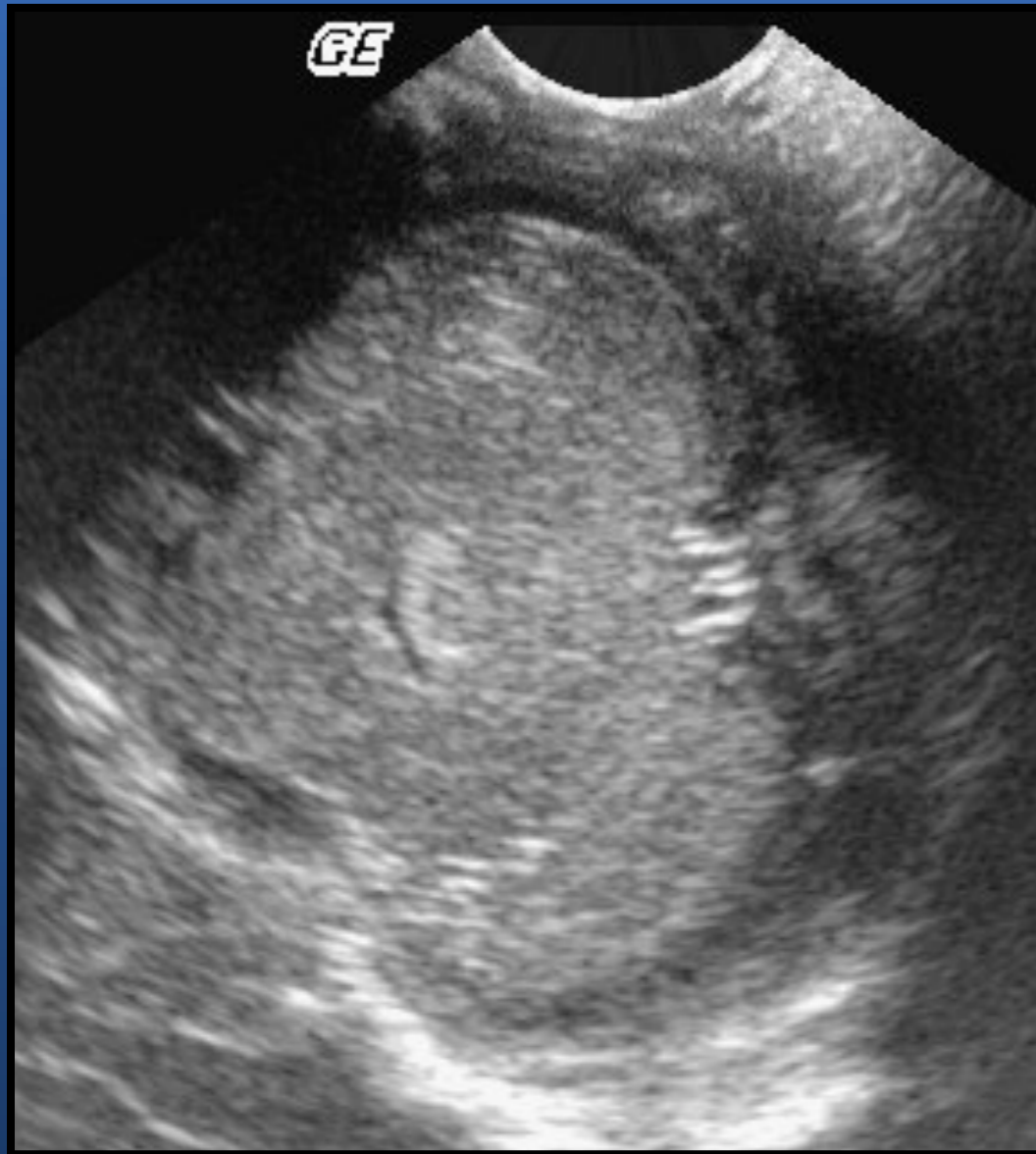
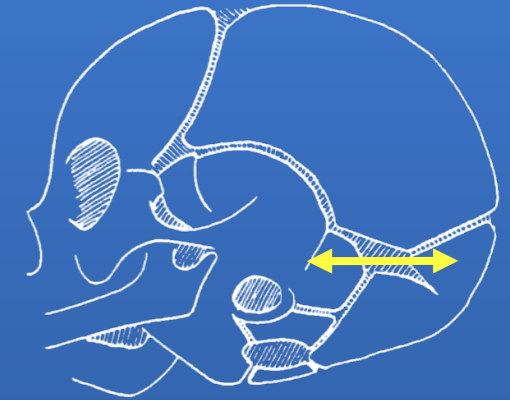
Gde citerne

Fosse postérieure : coupes coronales

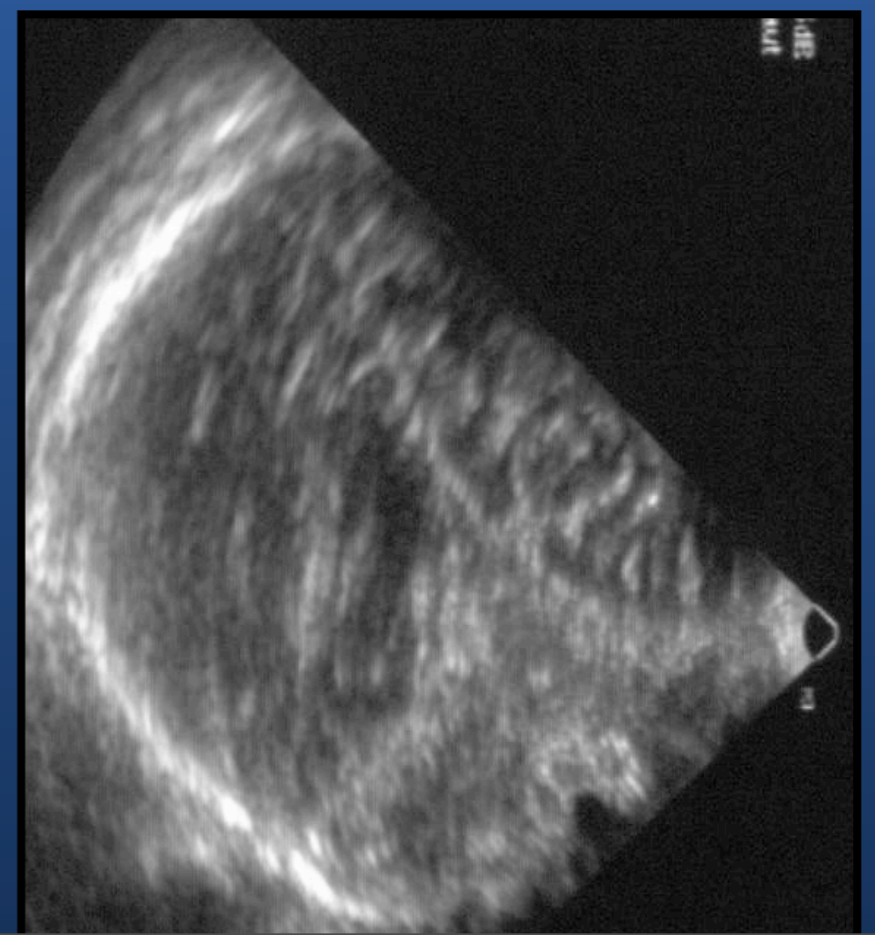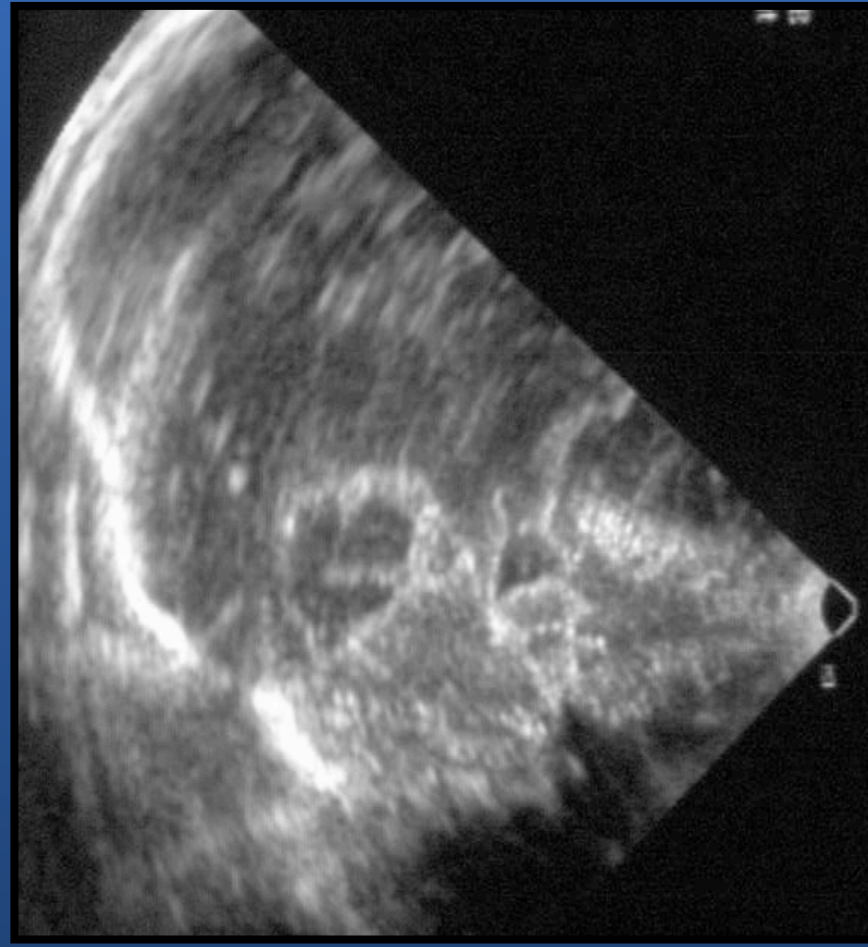
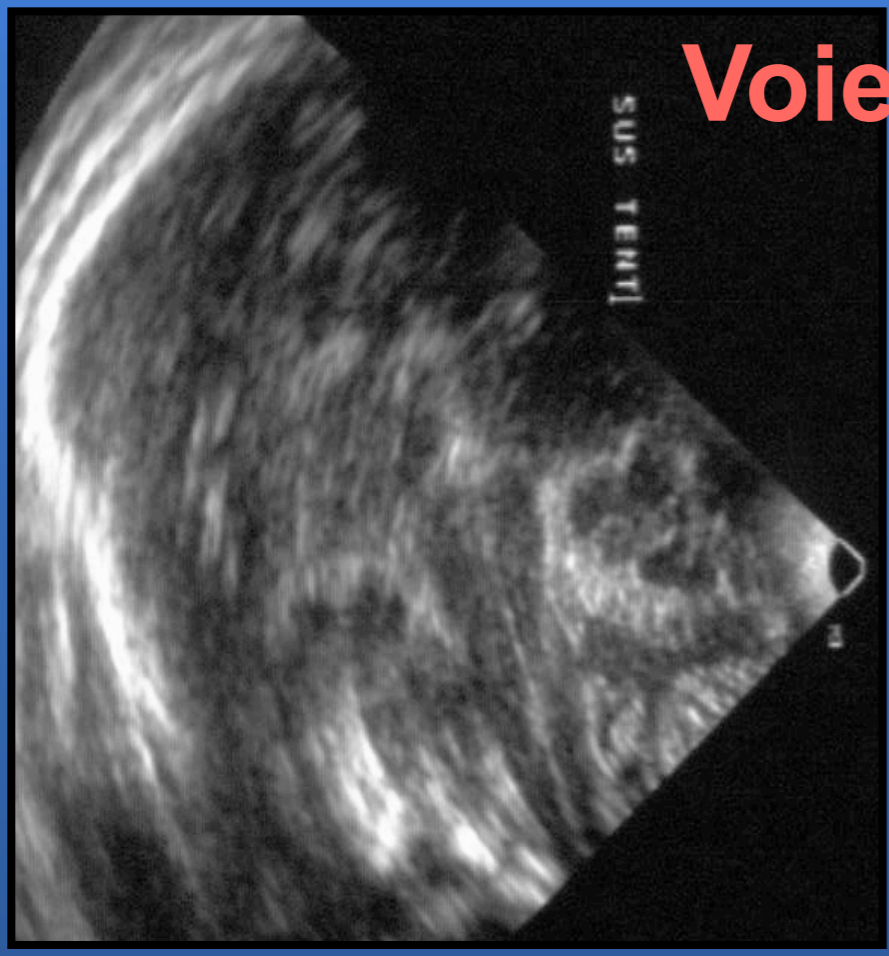
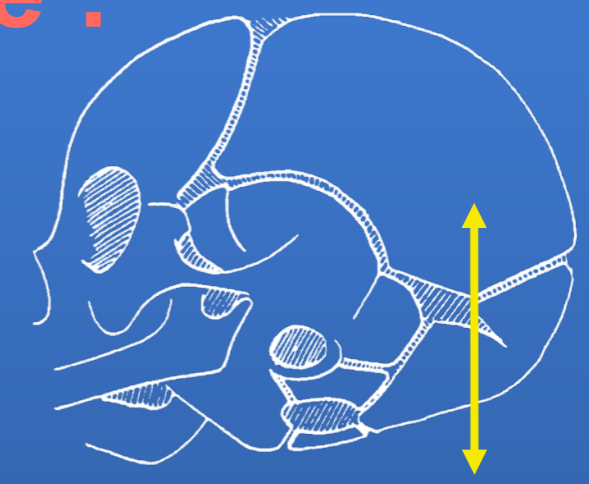


Ajuster fréquence focales et profondeur de champ

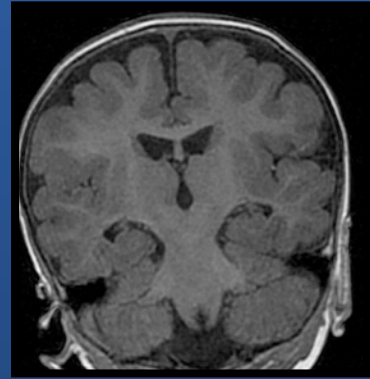
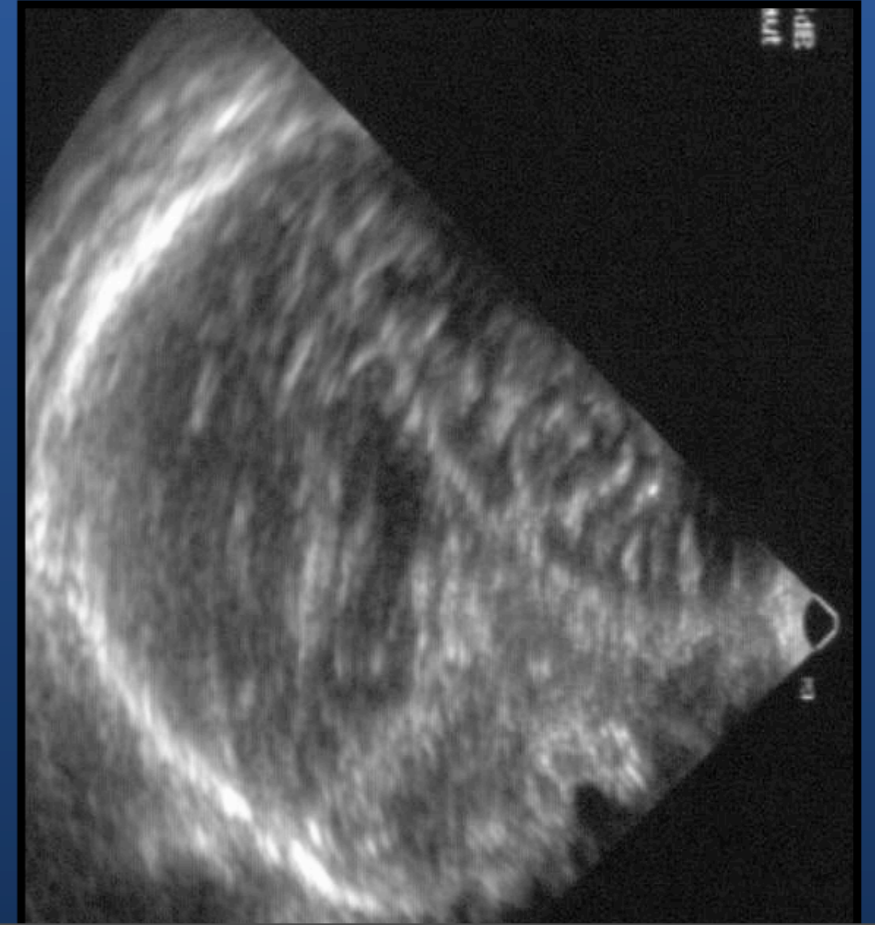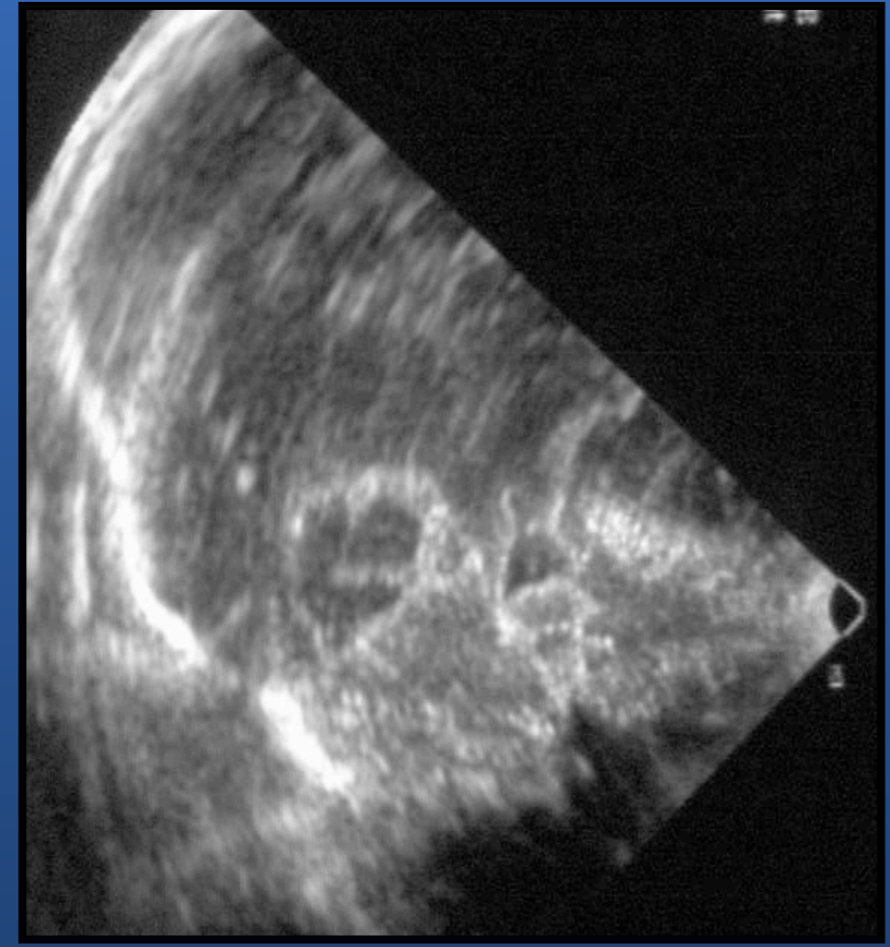
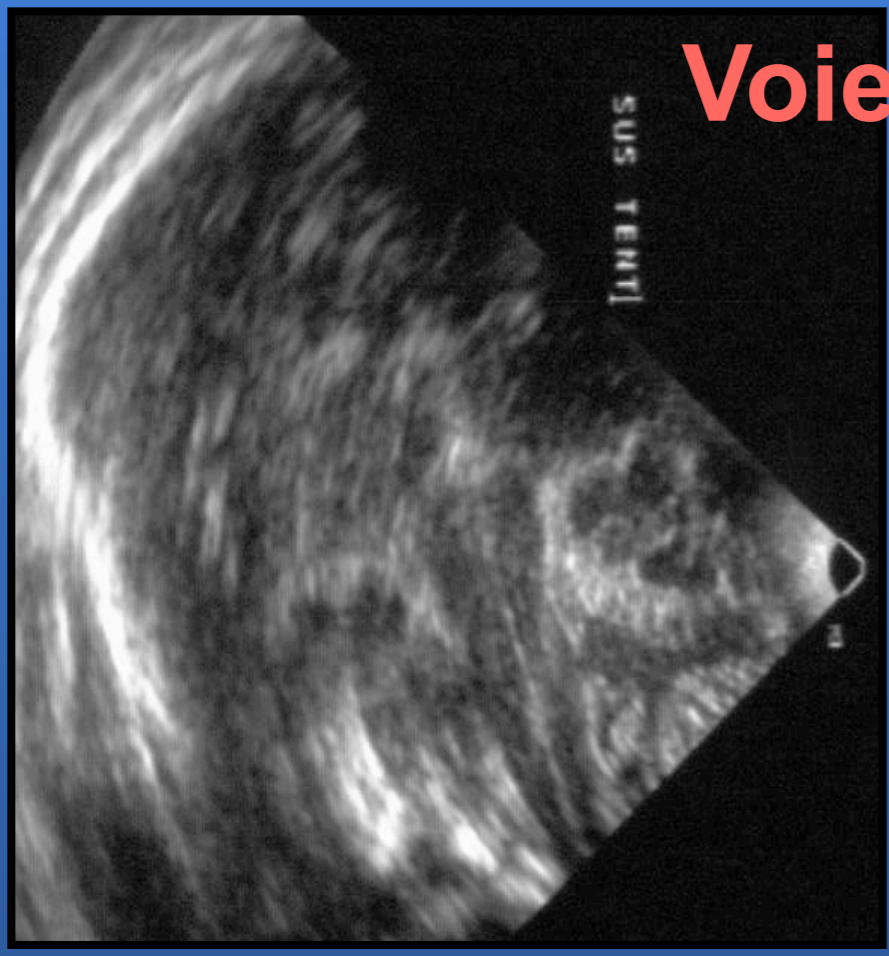
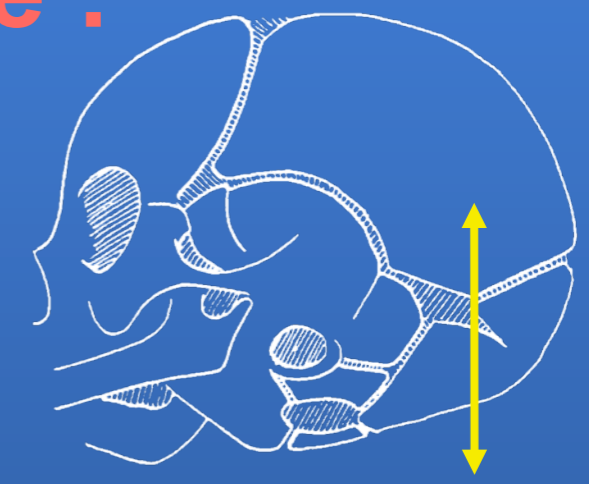
Voie d'abord postérieure : coupes axiales



Voie d'abord postérieure : coupes coronales

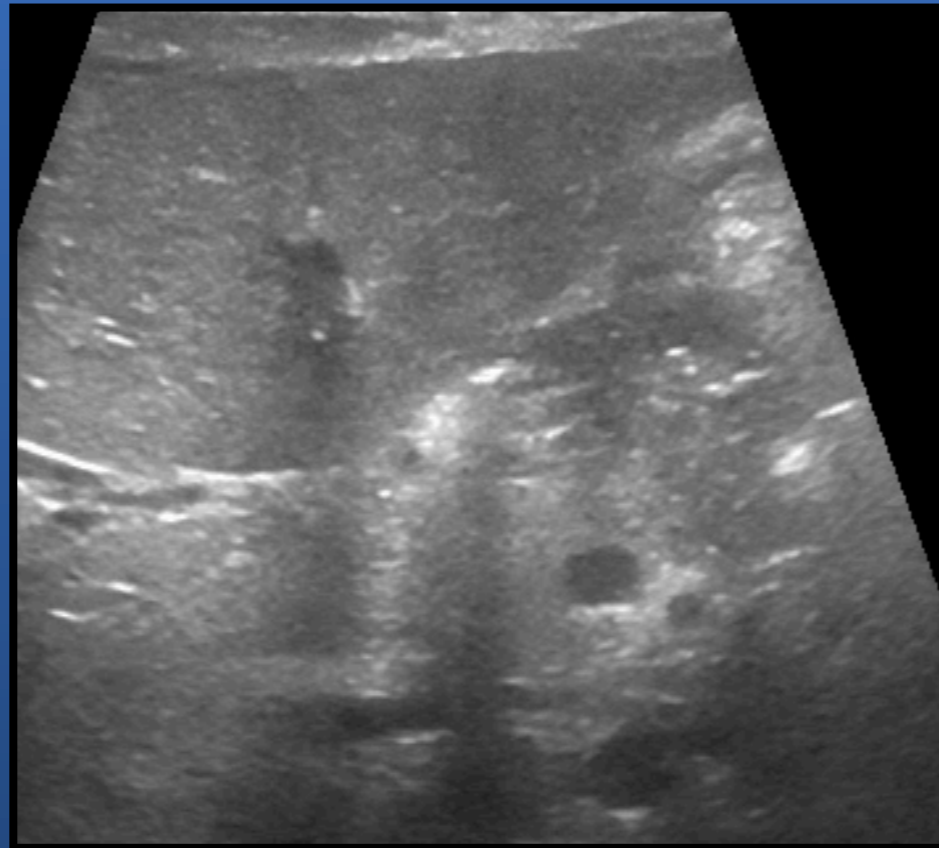


Voie d'abord postérieure : coupes coronales

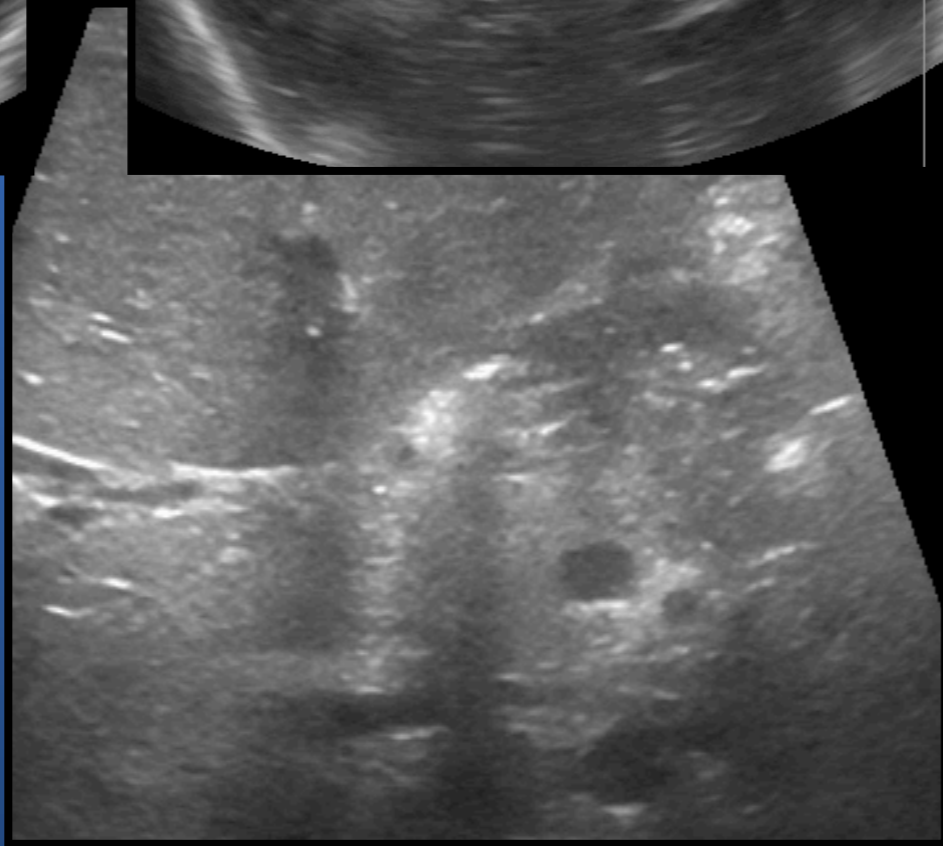
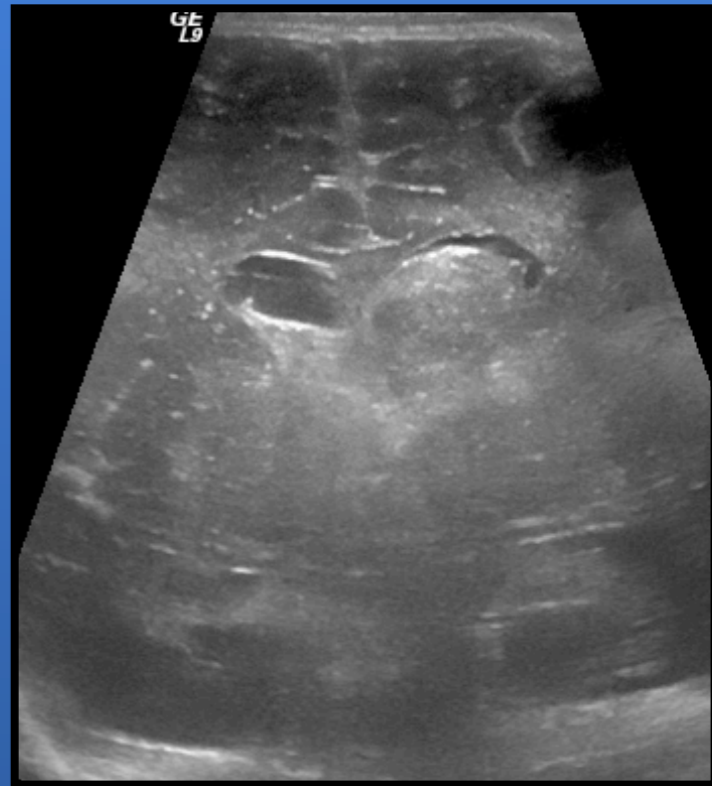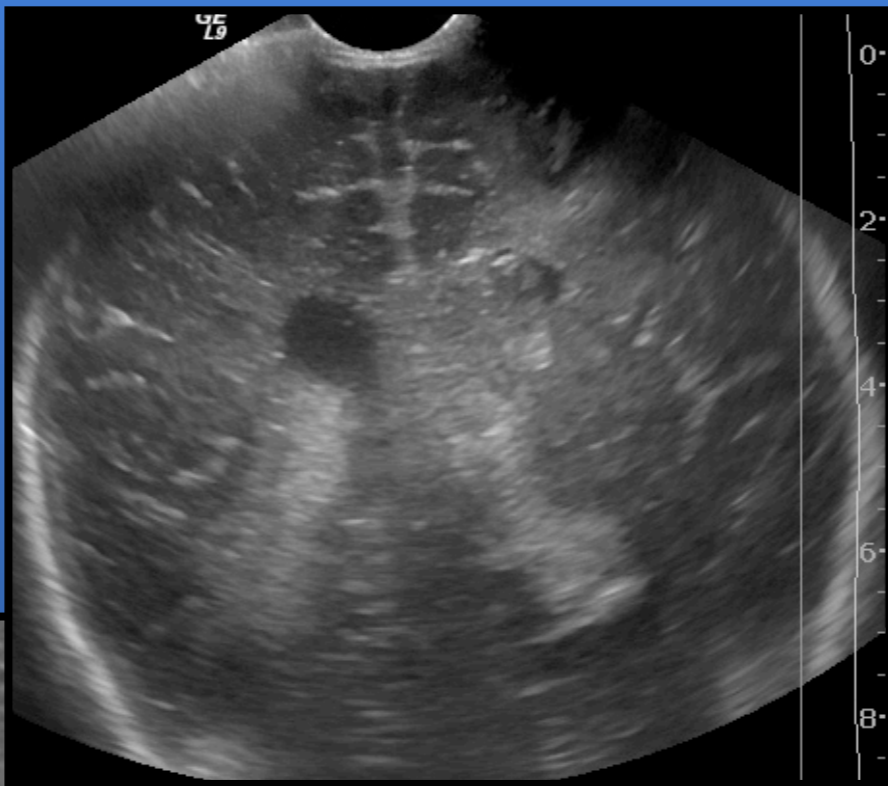

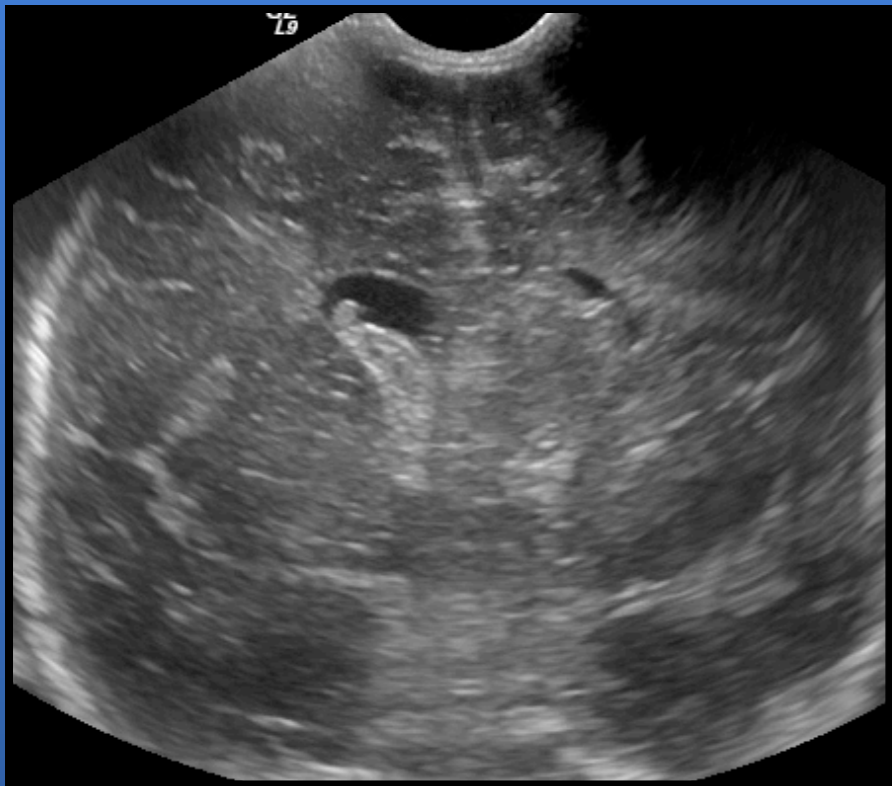
ETF : INDICATIONS

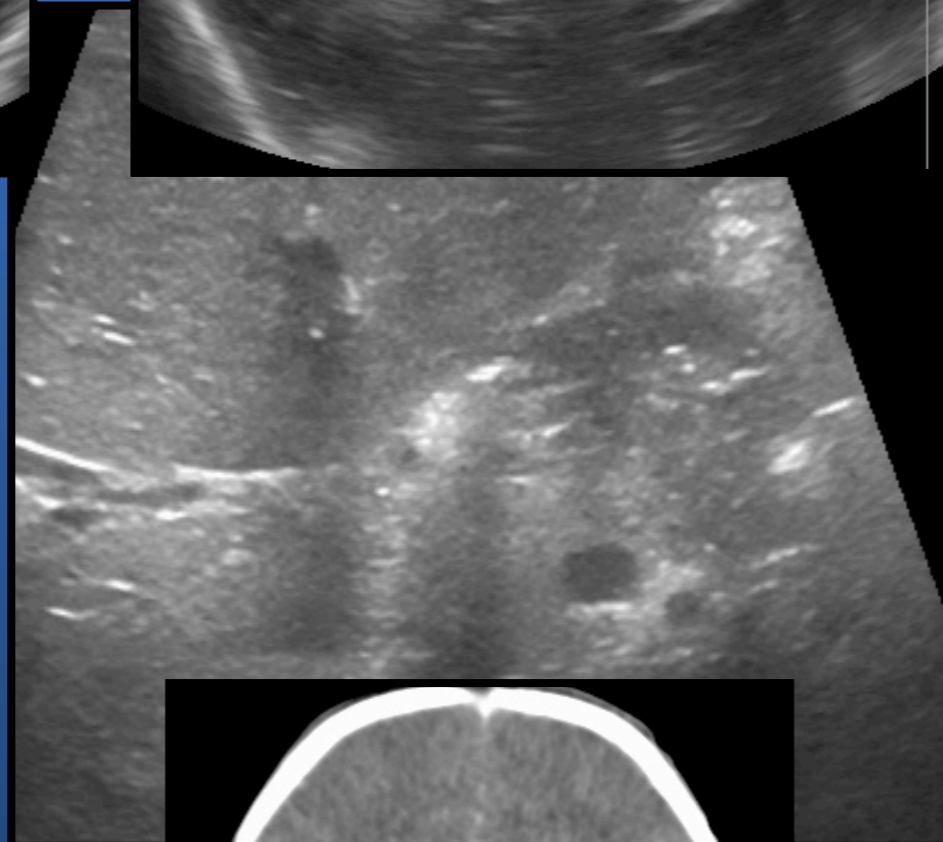
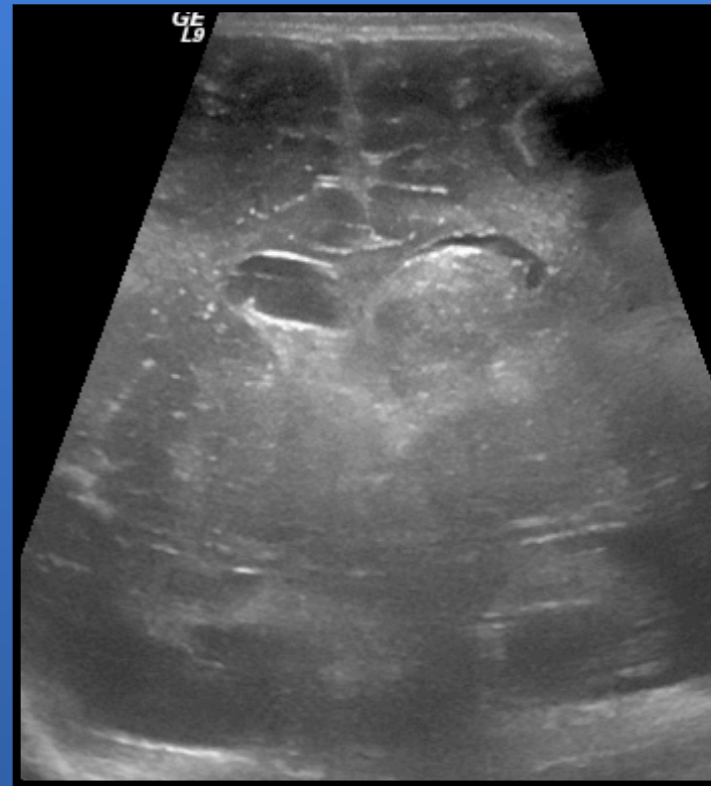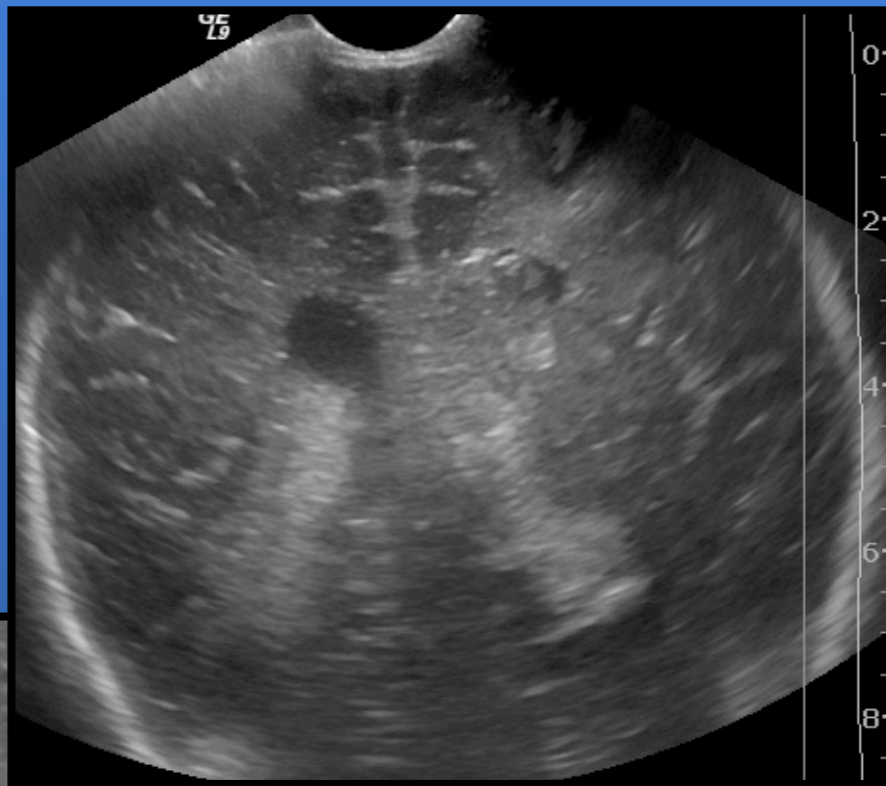
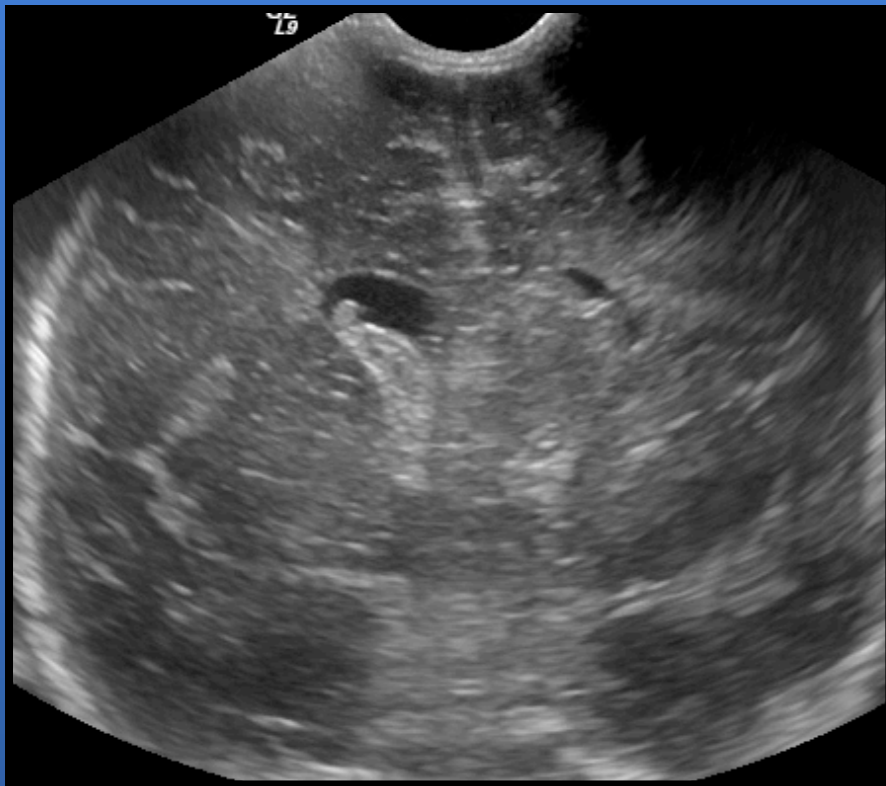
- **PATHOLOGIE DU PREMATURE**
 - EXAMENS SYTEMATIQUES
- **PATHOLOGIE DU NOUVEAU NE**
 - SIGNES CLINIQUES
- **SUSPICION DE PATHOLOGIE NEUROLOGIQUE**
- **SUIVI EVOLUTIF**
 - DILATATION
 - HEMATOMES
 - TUMEURS
 - ...
- **AUTRE**



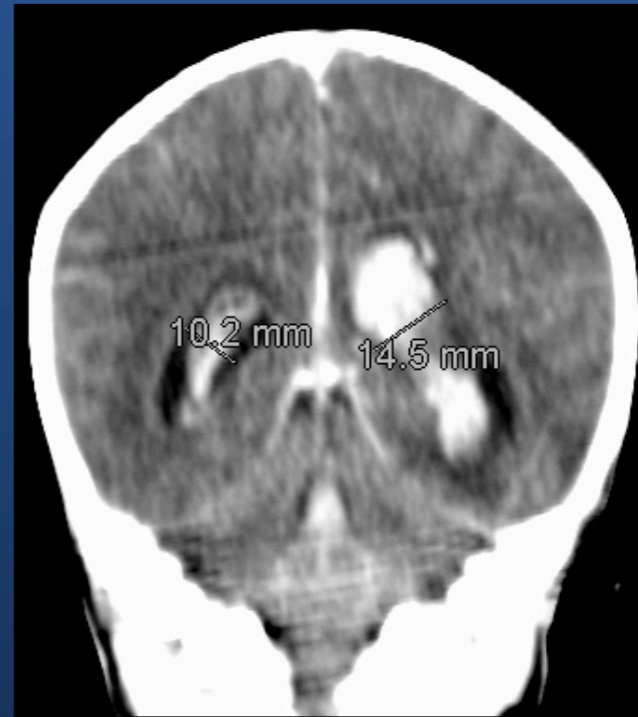
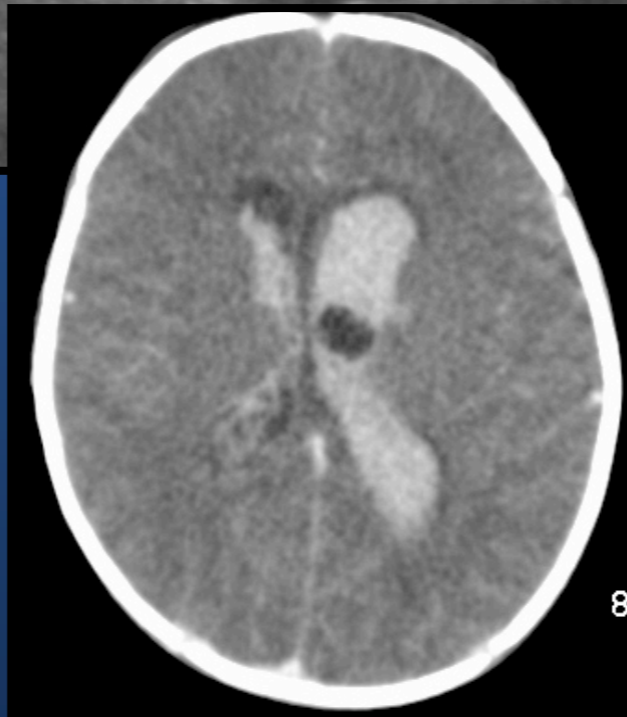
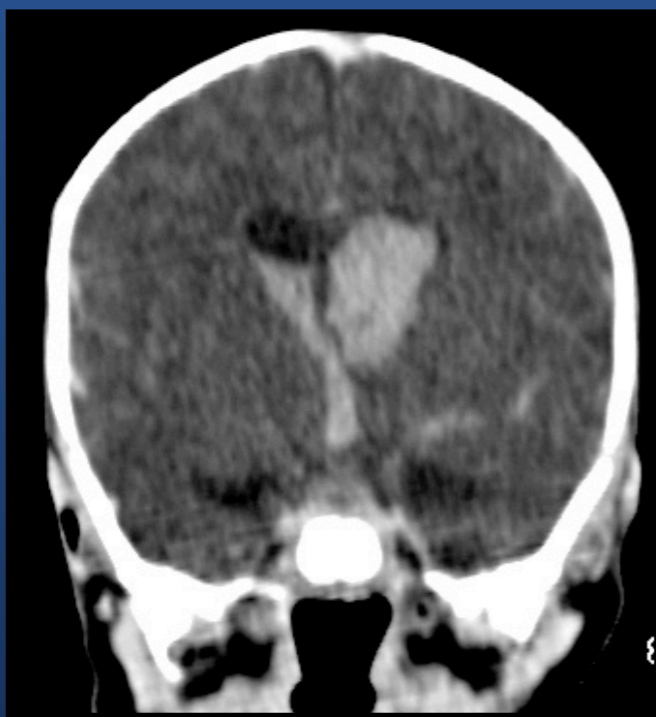1mois, vomissements



1mois, vomissements



1 mois, vomissements



LES PATHOLOGIES

- **Les plus fréquentes : néonatales**
 - **Hémorragie cérébrale**
 - **Leucomalacie péri ventriculaire**
 - **Malformations**
- **Les autres :**
 - **Infections**
 - **Traumatismes**
 - **Malformations**
 - **Tumeurs**
 - **Autres ...**

PATHOLOGIES VASCULAIRES

- . HEMORRAGIE
- . ISCHEMIE

HEMORRAGIE CEREBRALE

- **Risque ↑ quand âge gestationnel ↓**
- **Matrice germinale : plancher ventriculaire**
 - **Rupture capillaire**
 - **Si rupture paroi ventriculaire → intraventriculaire**

HEMORRAGIE CEREBRALE

- **Circonstances favorisantes :**

- ↑ flux sanguins cérébraux

- ↑ pression veineuse cérébrale

- stimulations nocives

- Complications neurologiques convulsions

- Complications systémiques pneumothorax, hypoxie

HEMORRAGIE CEREBRALE

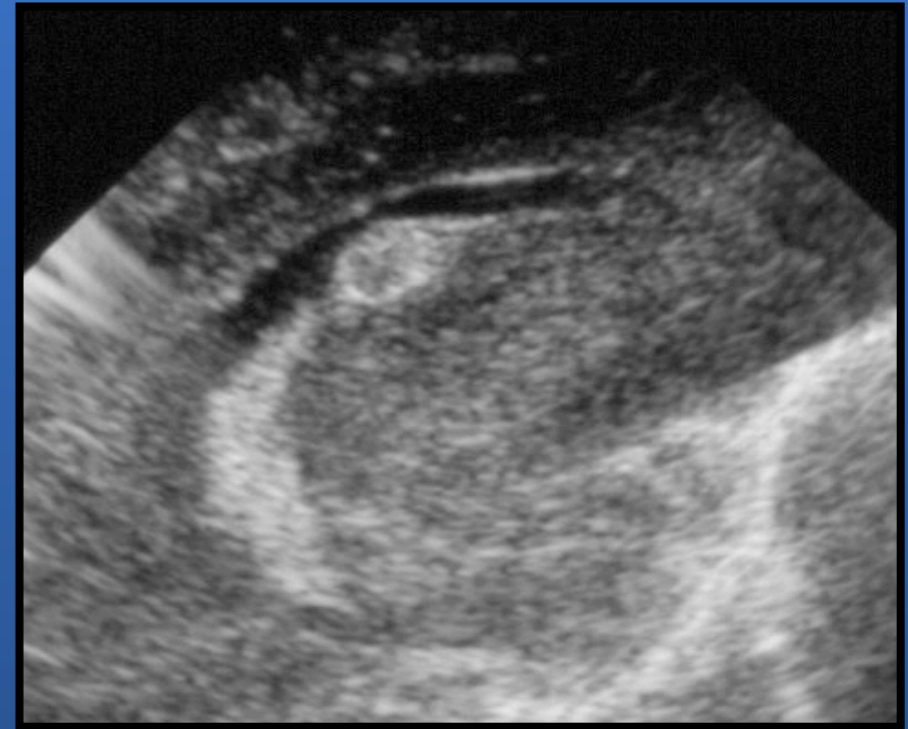
- **Population à risque :**
 - prématuré < à 32 SA
- **Précoce : 48 premières heures**
- **Expression variable**
 - asymptomatique : ETF systématique
 - 4 stades de gravité
- **Complications possibles**
 - trouble de circulation du LCR
 - destruction cellulaire

Les 4 stades de l'hémorragie

- **Stade 1 : hémorragie sous épendymaire**
- **Stade 2 : hémorragie intra ventriculaire**
- **Stade 3 : hémorragie avec dilatation ventriculaire**
- **Stade 4 : hémorragie intra parenchymateuse**

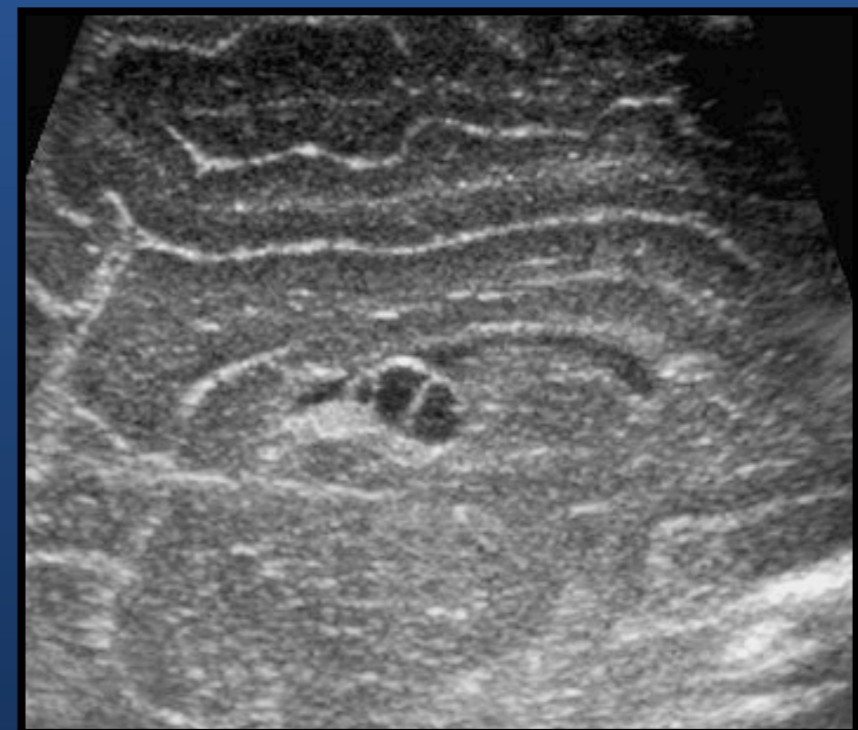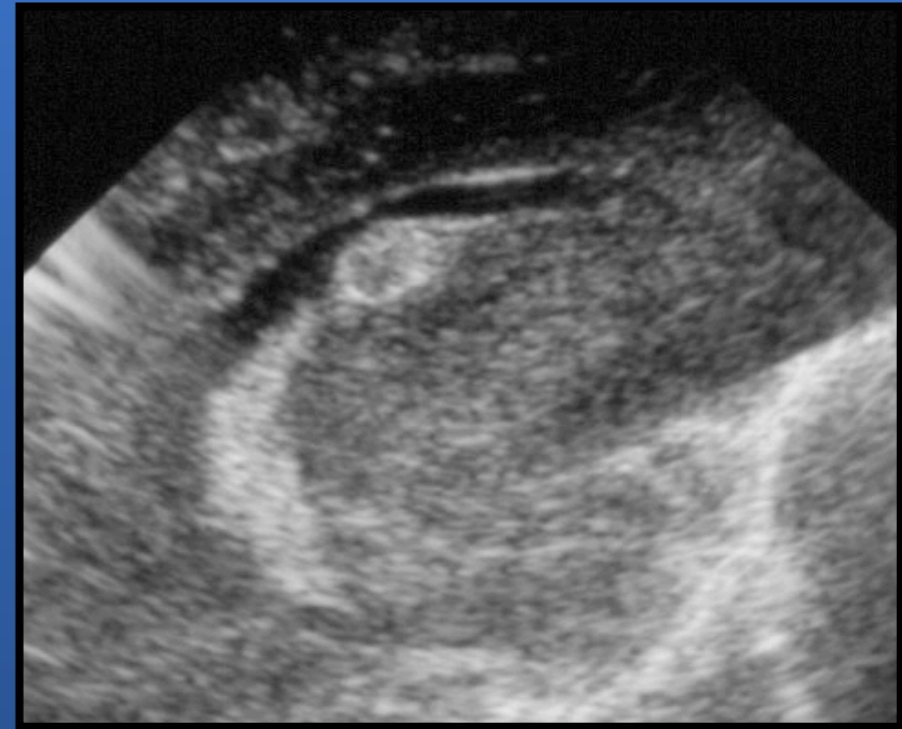
HEMORRAGIE CEREBRALE

- **Stade initial**
 - Image fortement échogène
- **Évolution**
 - Aspect en cocarde
 - Image kystique



HEMORRAGIE CEREBRALE

- **Stade initial**
 - Image fortement échogène
- **Évolution**
 - Aspect en cocarde
 - Image kystique

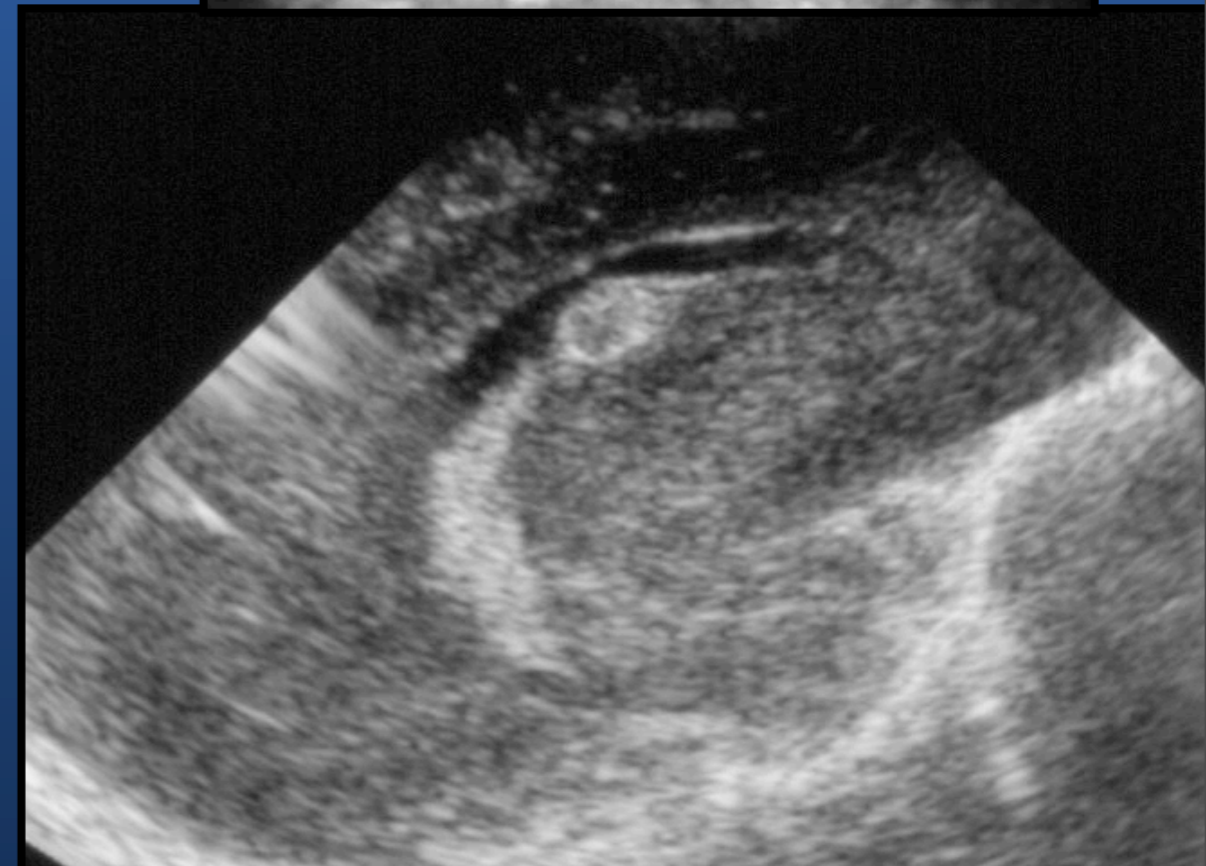
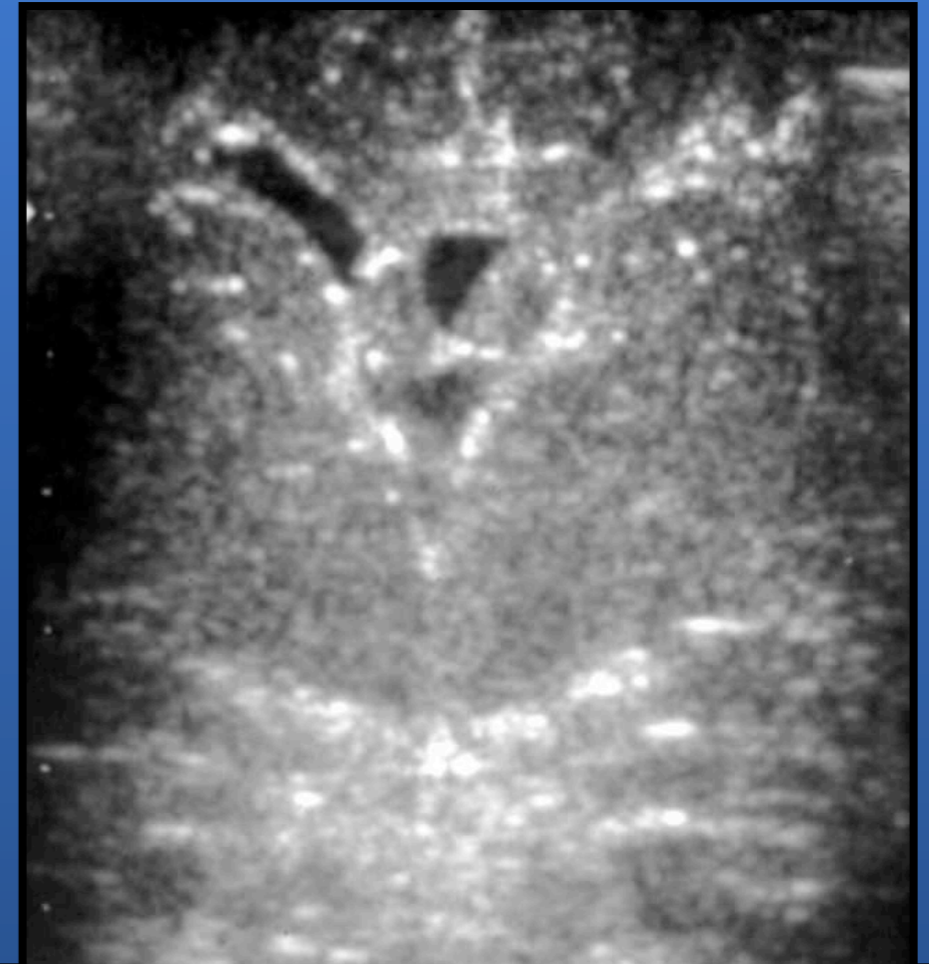
HEMORRAGIE SOUS-EPENDYMAIRE

(Stade I de Papile)

- **Fréquente :**
 - 50 % avant 32 SA
- **Localisation : matrice germinale**
 - En avant des trous de Monro
 - Sur plancher ventriculaire
 - Bilatéral 50%
- **Bon pronostic**

- **Nodule échogène antérieur**
- **Saïlle dans ventricules latéraux**
- **Au contact des noyaux caudés**

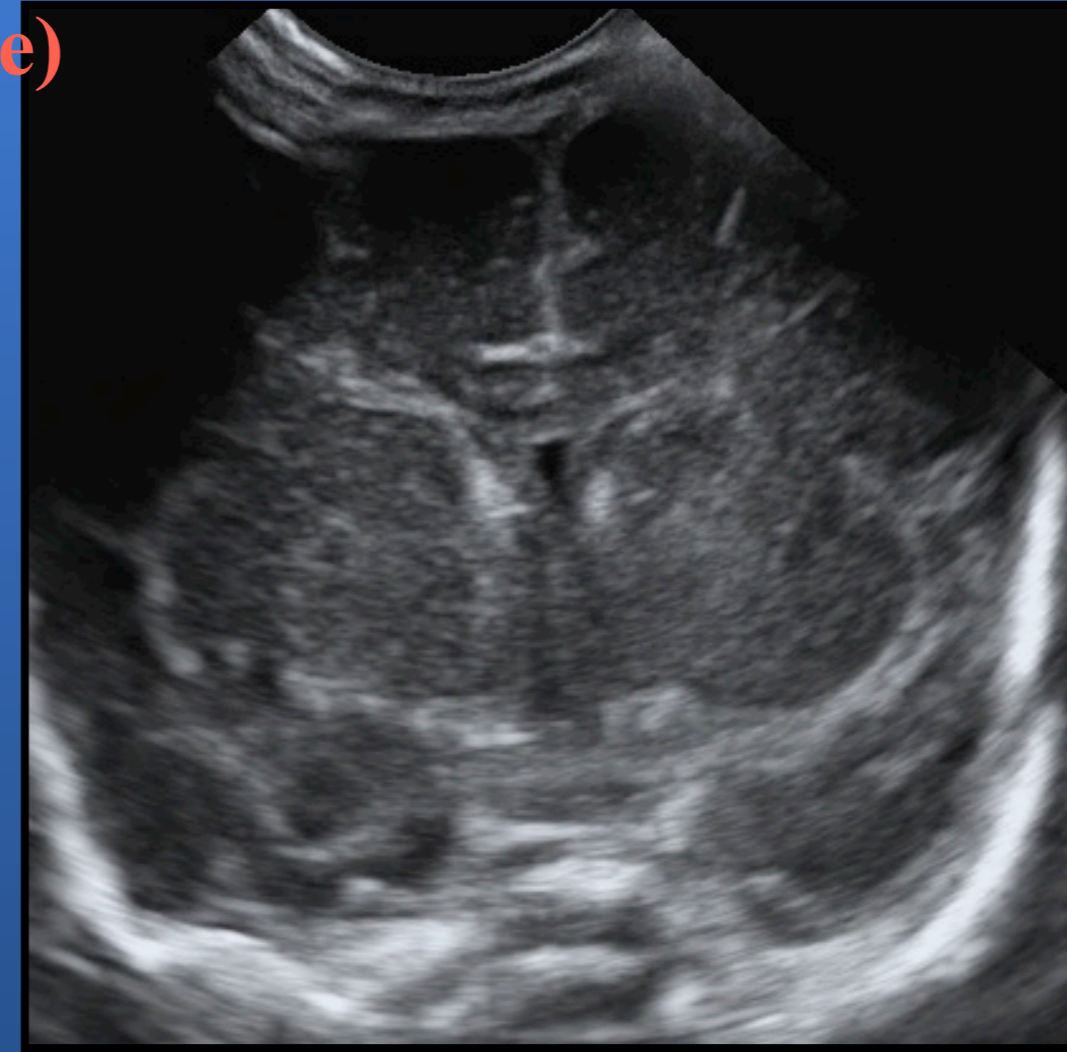


HEMORRAGIE SOUS-EPENDYMAIRE

(Stade I de Papile)

- **Fréquente :**
 - 50 % avant 32 SA
- **Localisation : matrice germinale**
 - En avant des trous de Monro
 - Sur plancher ventriculaire
 - Bilatéral 50%
- **Bon pronostic**

- **Nodule échogène antérieur**
- **Saïlle dans ventricules latéraux**
- **Au contact des noyaux caudés**

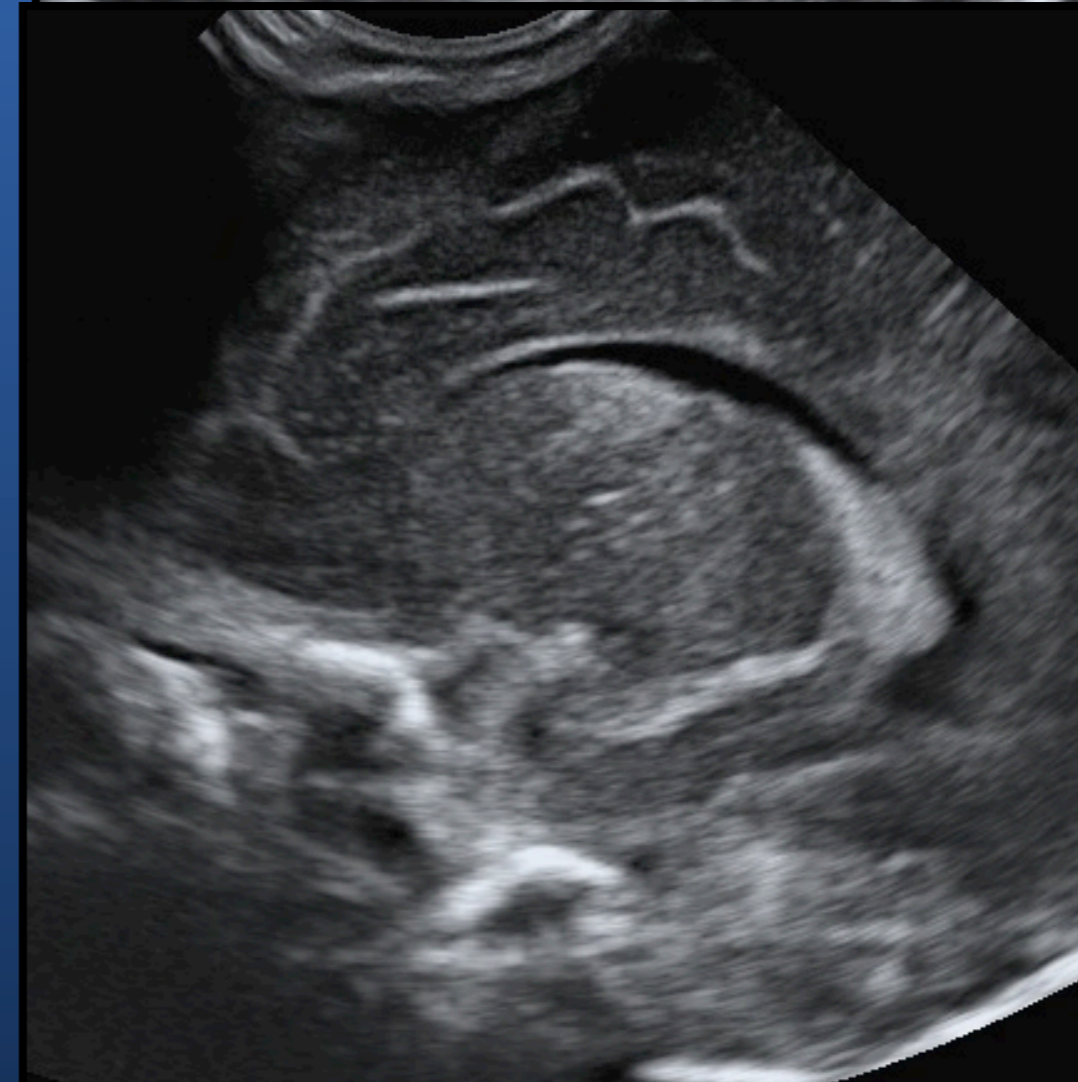
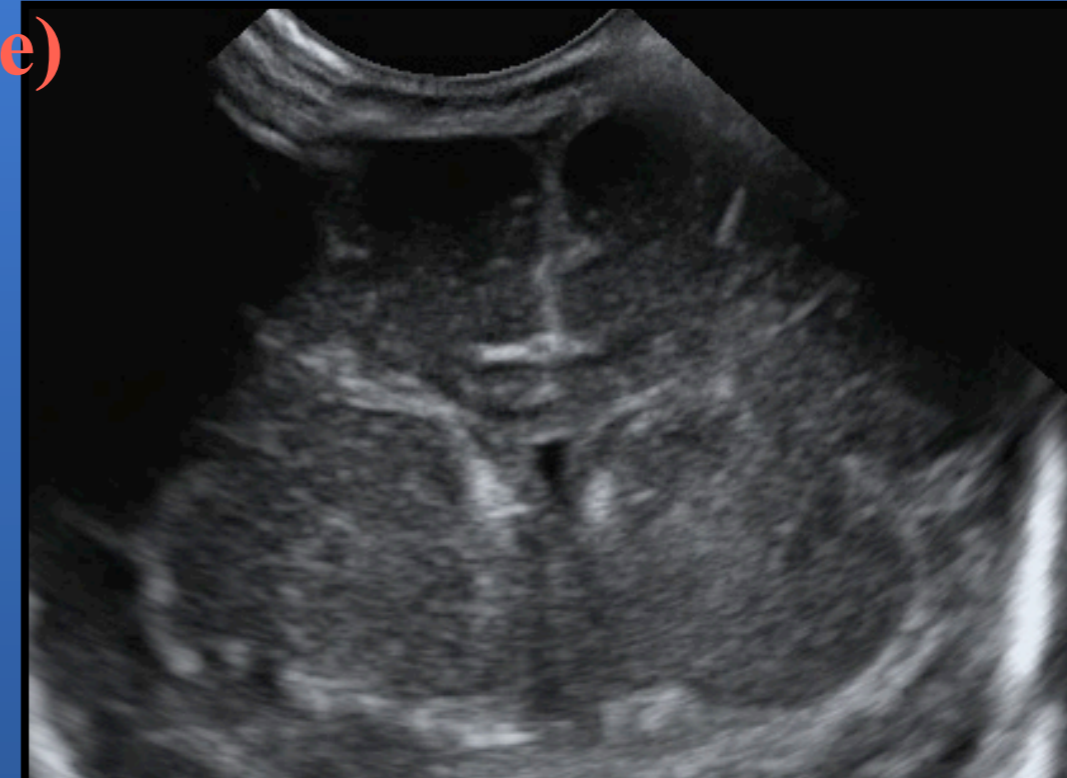


HEMORRAGIE SOUS-EPENDYMAIRE

(Stade I de Papile)

- **Fréquente :**
 - 50 % avant 32 SA
- **Localisation : matrice germinale**
 - En avant des trous de Monro
 - Sur plancher ventriculaire
 - Bilatéral 50%
- **Bon pronostic**

- **Nodule échogène antérieur**
- **Saïlle dans ventricules latéraux**
- **Au contact des noyaux caudés**

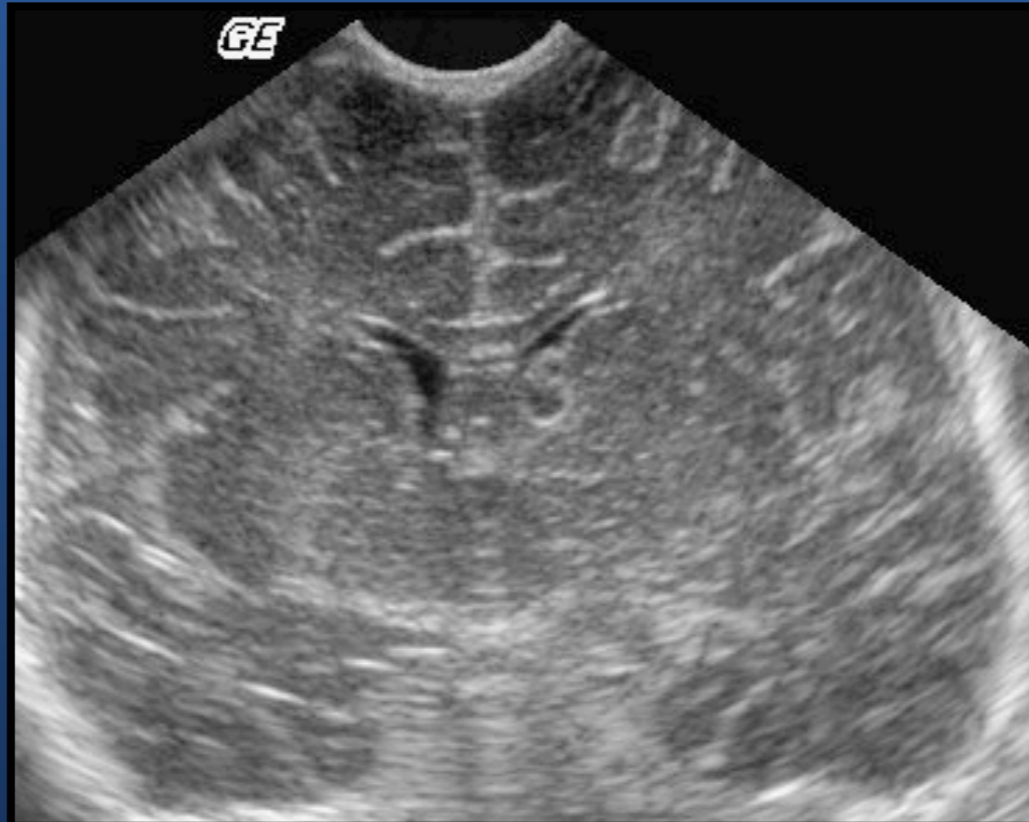

HEMORRAGIE SOUS-EPENDYMAIRE : EVOLUTION

- **Nécrose centrale : hypoéchogène**
- **Disparition complète (1 à 3 mois)**
- **Formation kystique sous-ventriculaire**
- **Bon pronostic**

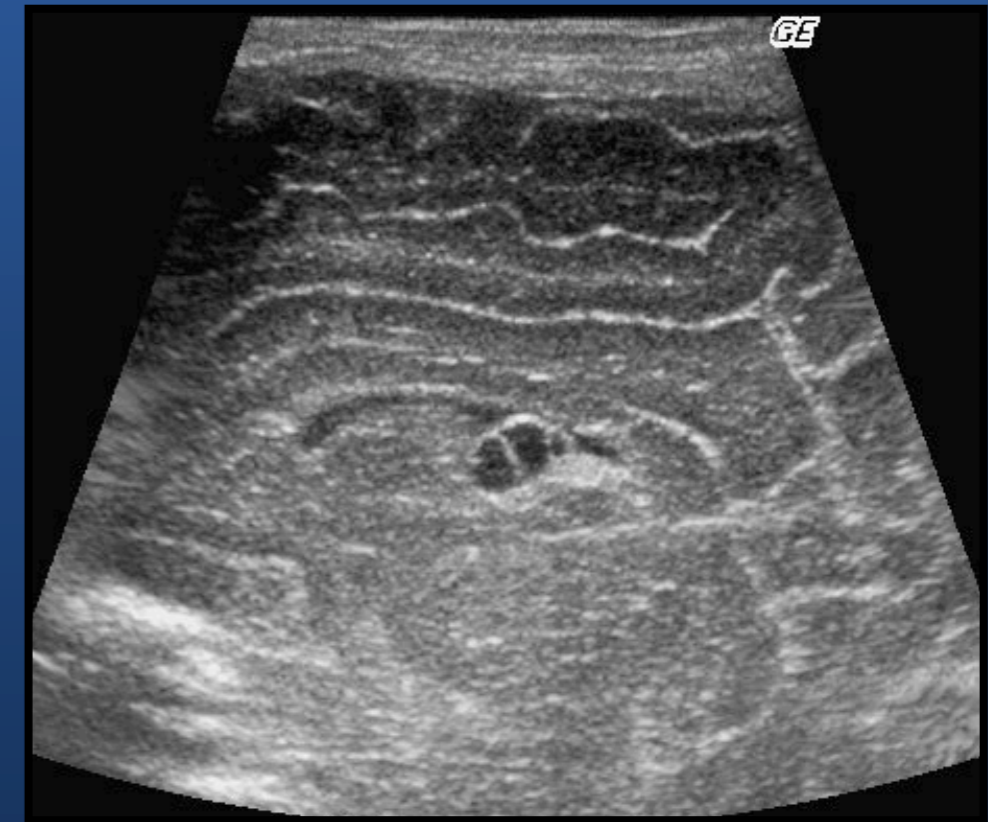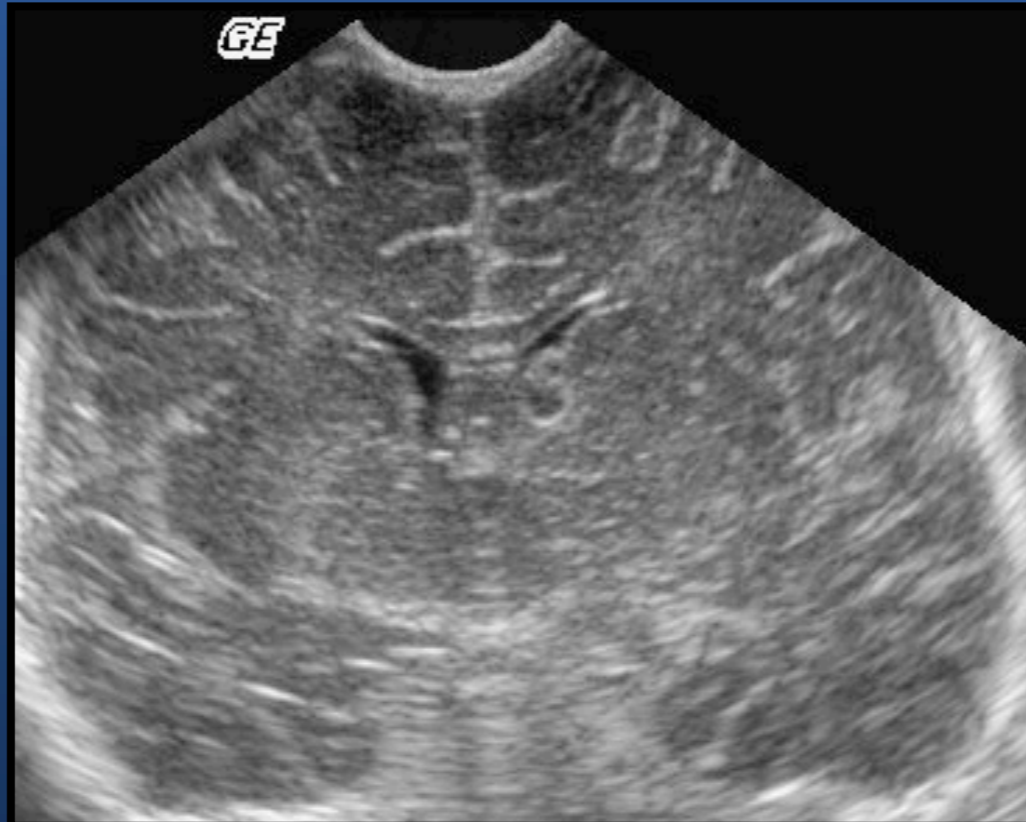HEMORRAGIE SOUS-EPENDYMAIRE : EVOLUTION

- **Nécrose centrale : hypoéchogène**
- **Disparition complète (1 à 3 mois)**
- **Formation kystique sous-ventriculaire**
- **Bon pronostic**



HEMORRAGIE SOUS-EPENDYMAIRE : EVOLUTION

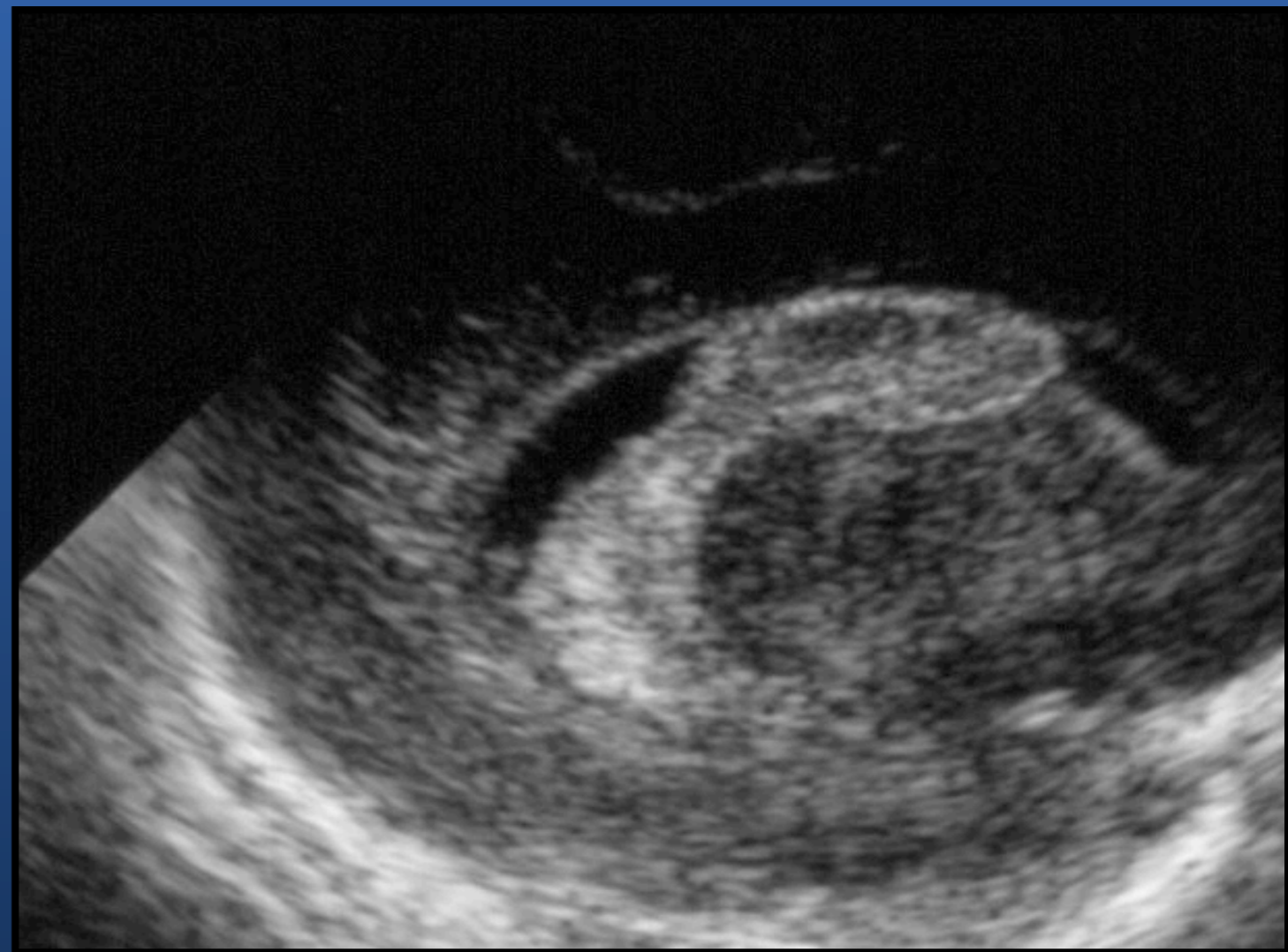
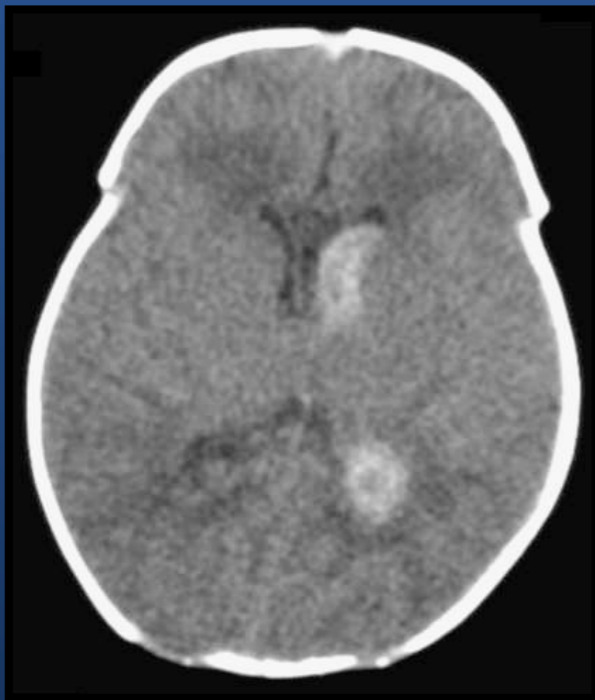
- **Nécrose centrale : hypoéchogène**
- **Disparition complète (1 à 3 mois)**
- **Formation kystique sous-ventriculaire**
- **Bon pronostic**



HEMORRAGIE INTRA-VENTRICULAIRE :

(Stade II de Papile)

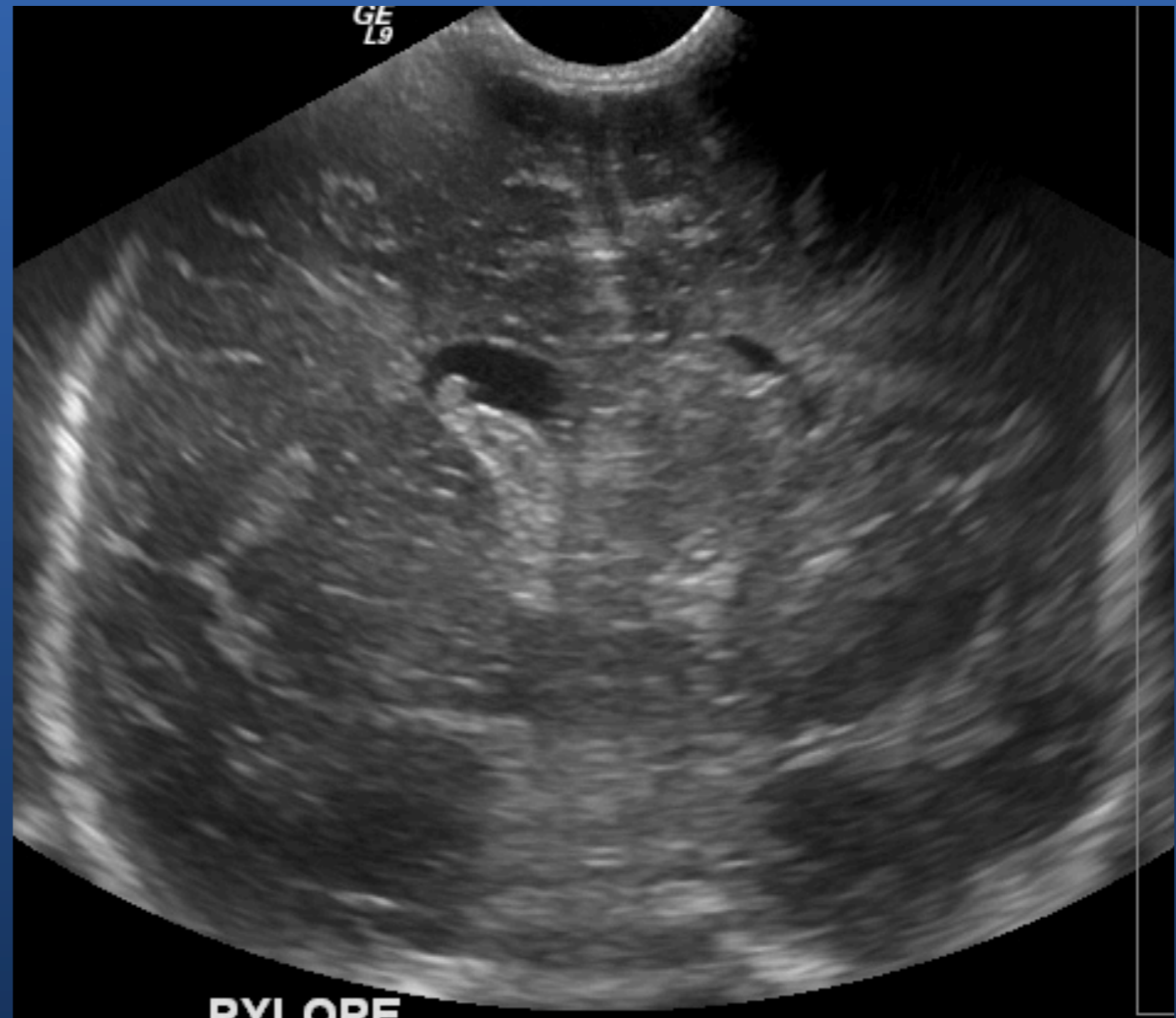- **Hyperéchogénicité intra-ventriculaire**
- **Grave : Risque d'hydrocéphalie**
- **Caillot intra-ventriculaire : masse échogène**
- **Petits ventricules :**
 - **difficulté diagnostique**
 - **comblement**
 - **signes indirects**



HEMORRAGIE INTRA-VENTRICULAIRE :

(Stade II de Papile)

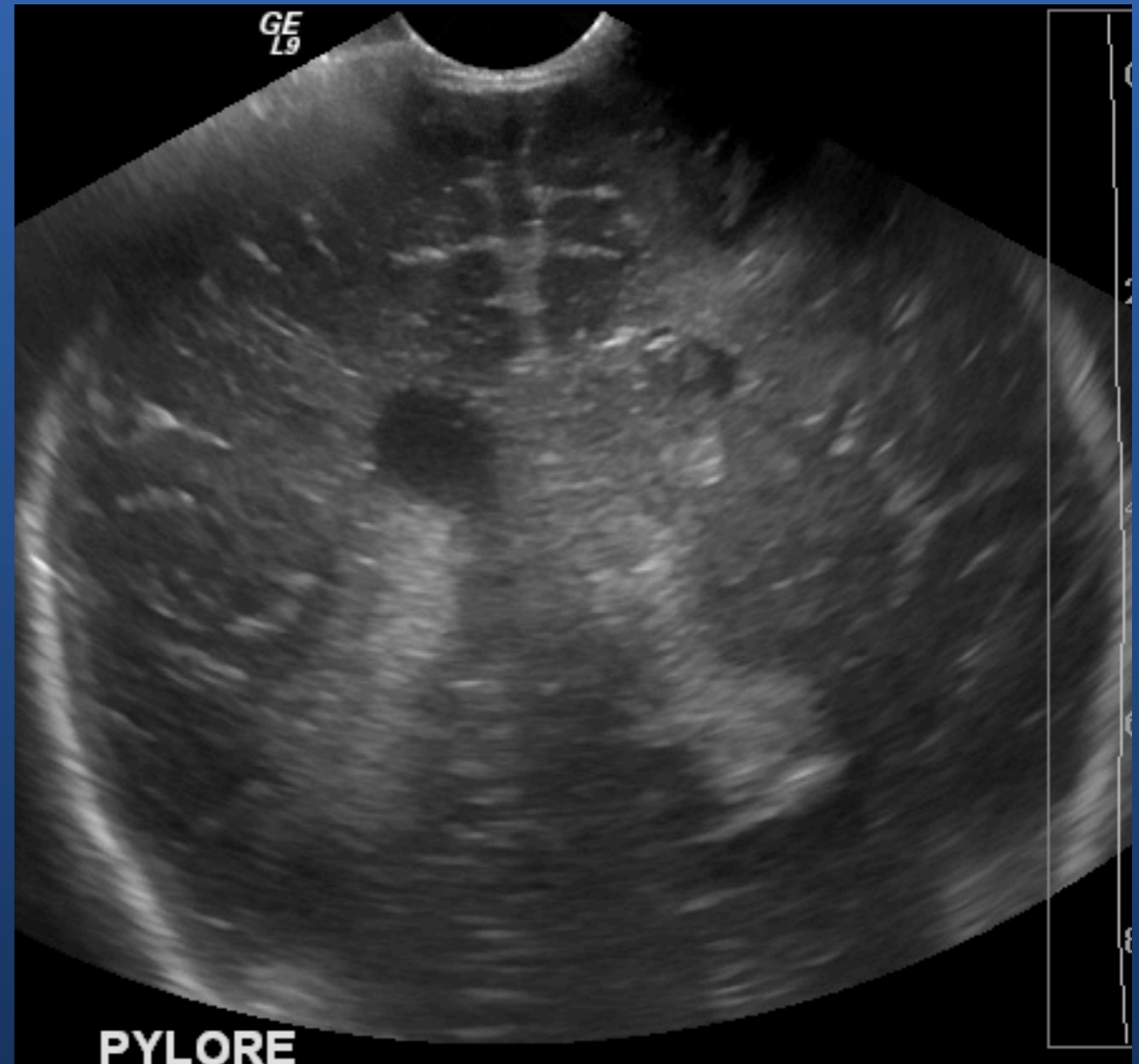
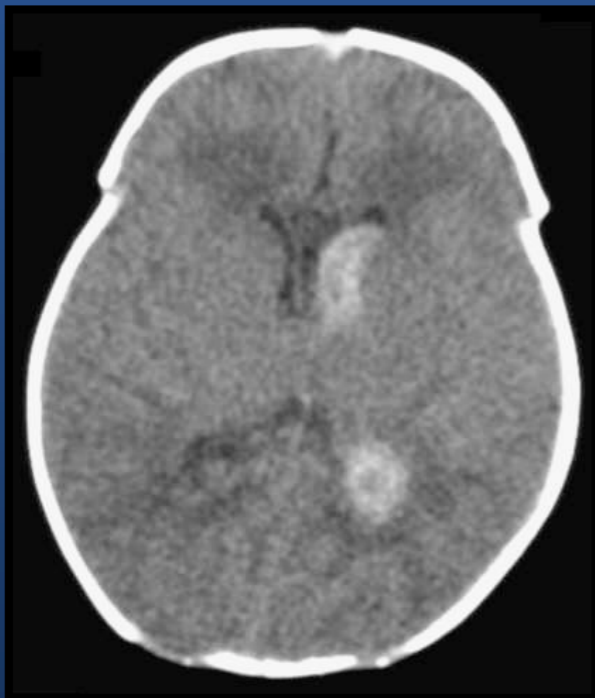
- **Hyperéchogénicité intra-ventriculaire**
- **Grave : Risque d'hydrocéphalie**
- **Caillot intra-ventriculaire : masse échogène**
- **Petits ventricules :**
 - **difficulté diagnostique**
 - **comblement**
 - **signes indirects**



HEMORRAGIE INTRA-VENTRICULAIRE :

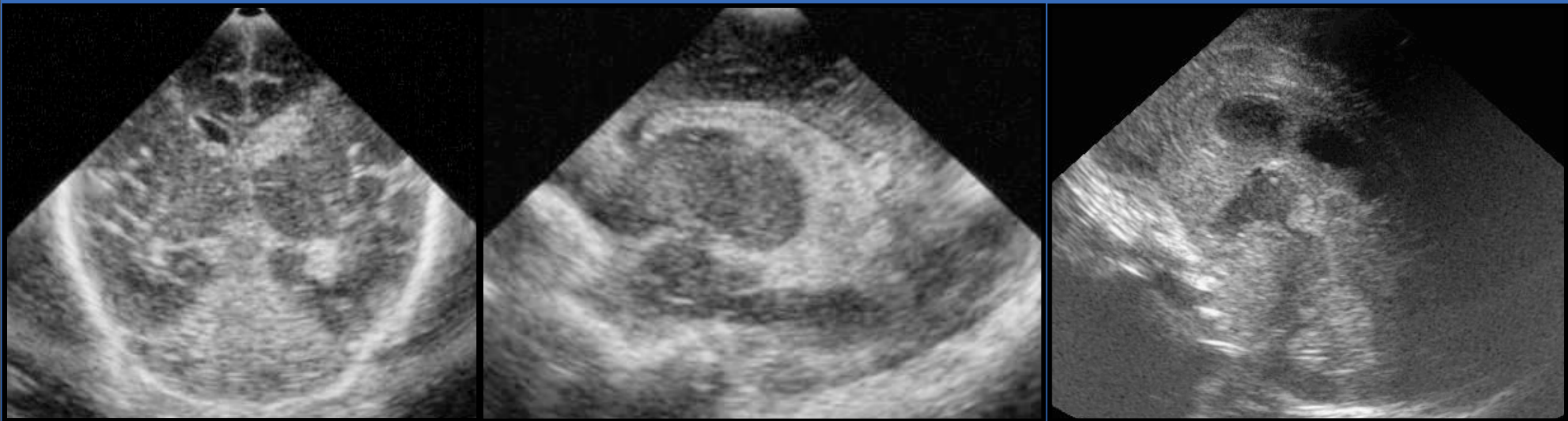
(Stade II de Papile)

- **Hyperéchogénicité intra-ventriculaire**
- **Grave : Risque d'hydrocéphalie**
- **Caillot intra-ventriculaire : masse échogène**
- **Petits ventricules :**
 - **difficulté diagnostique**
 - **comblement**
 - **signes indirects**



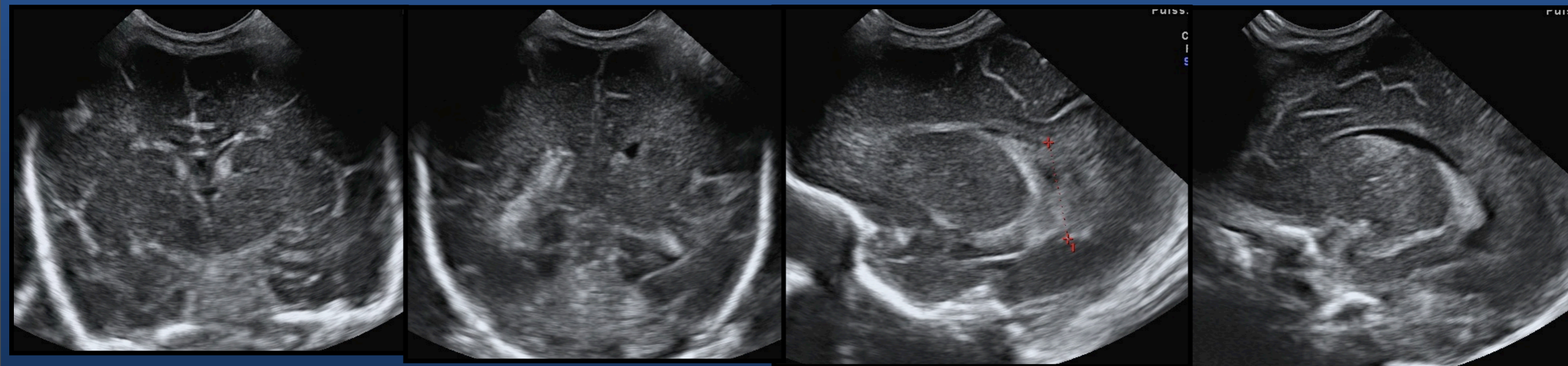
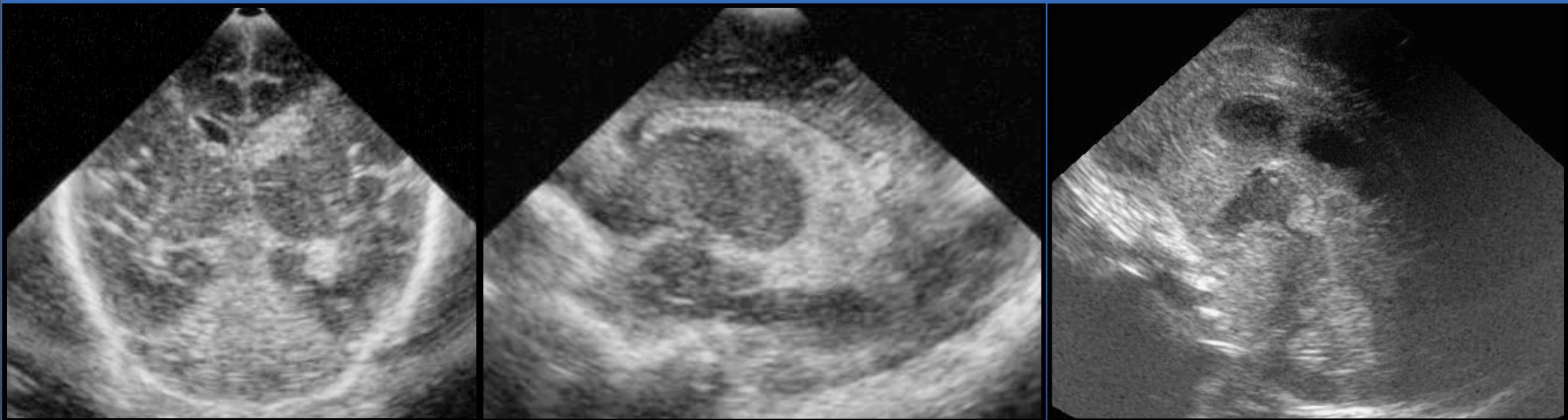
Hémorragie intra-ventriculaire stade II

Préciser l'abondance : V3 V4

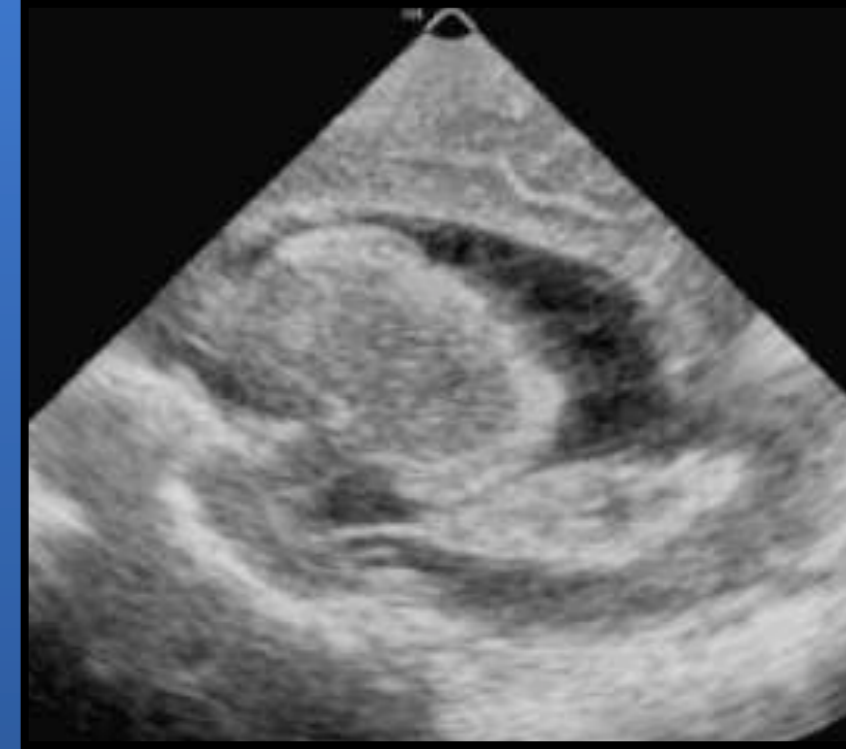
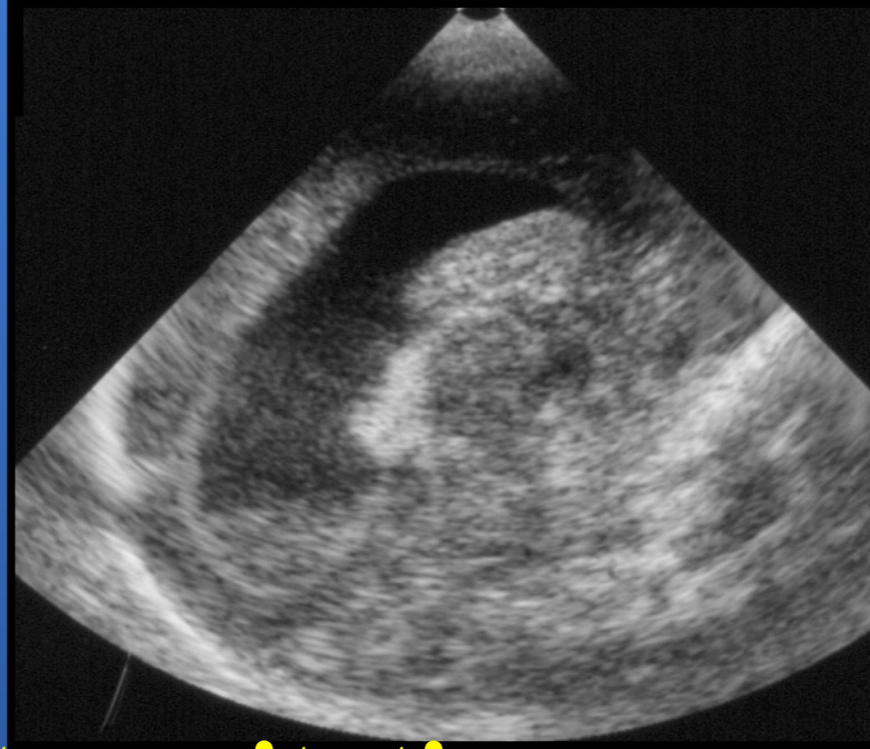


Hémorragie intra-ventriculaire stade II

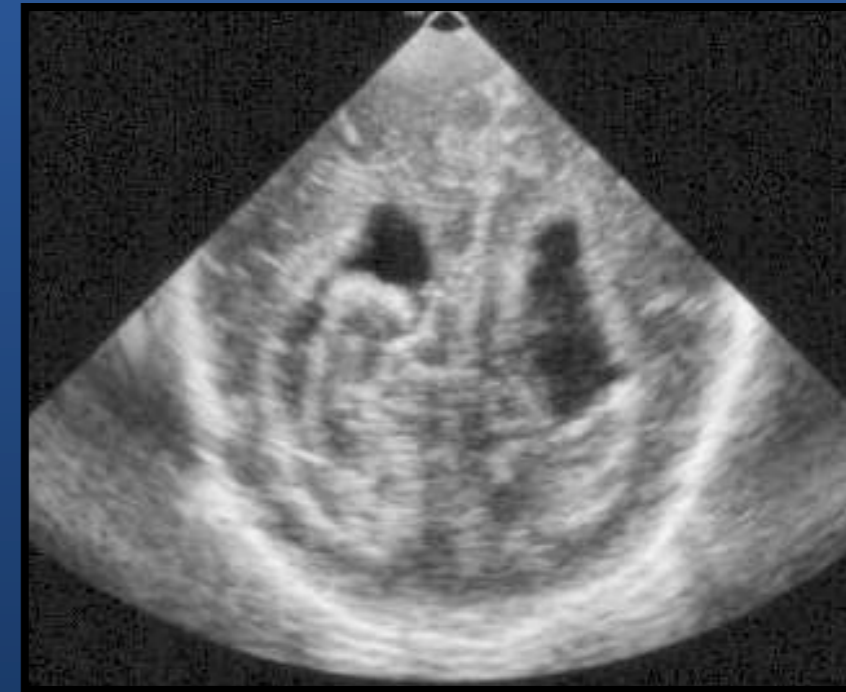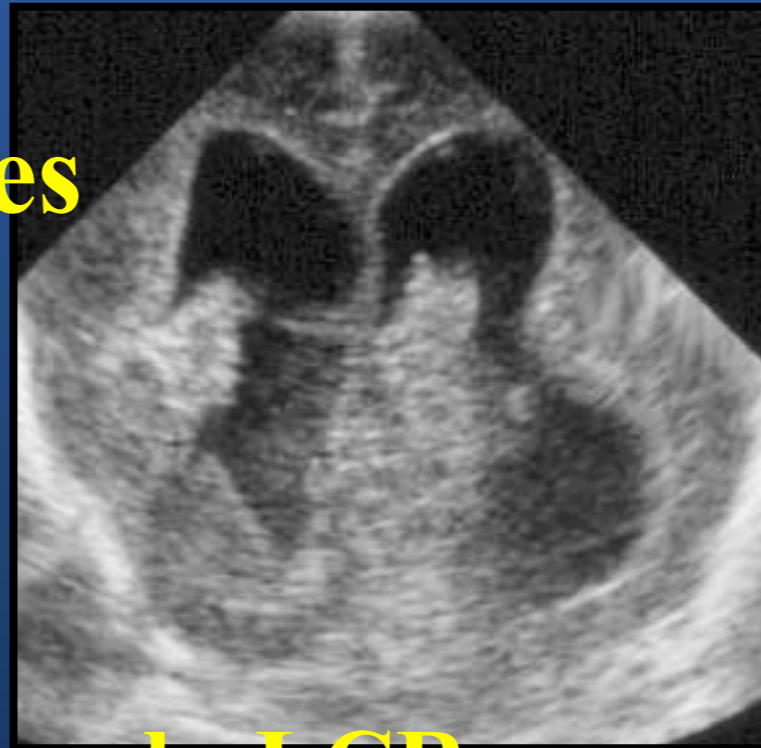Préciser l'abondance : V3 V4



HEMORRAGIE VENTRICULAIRE :

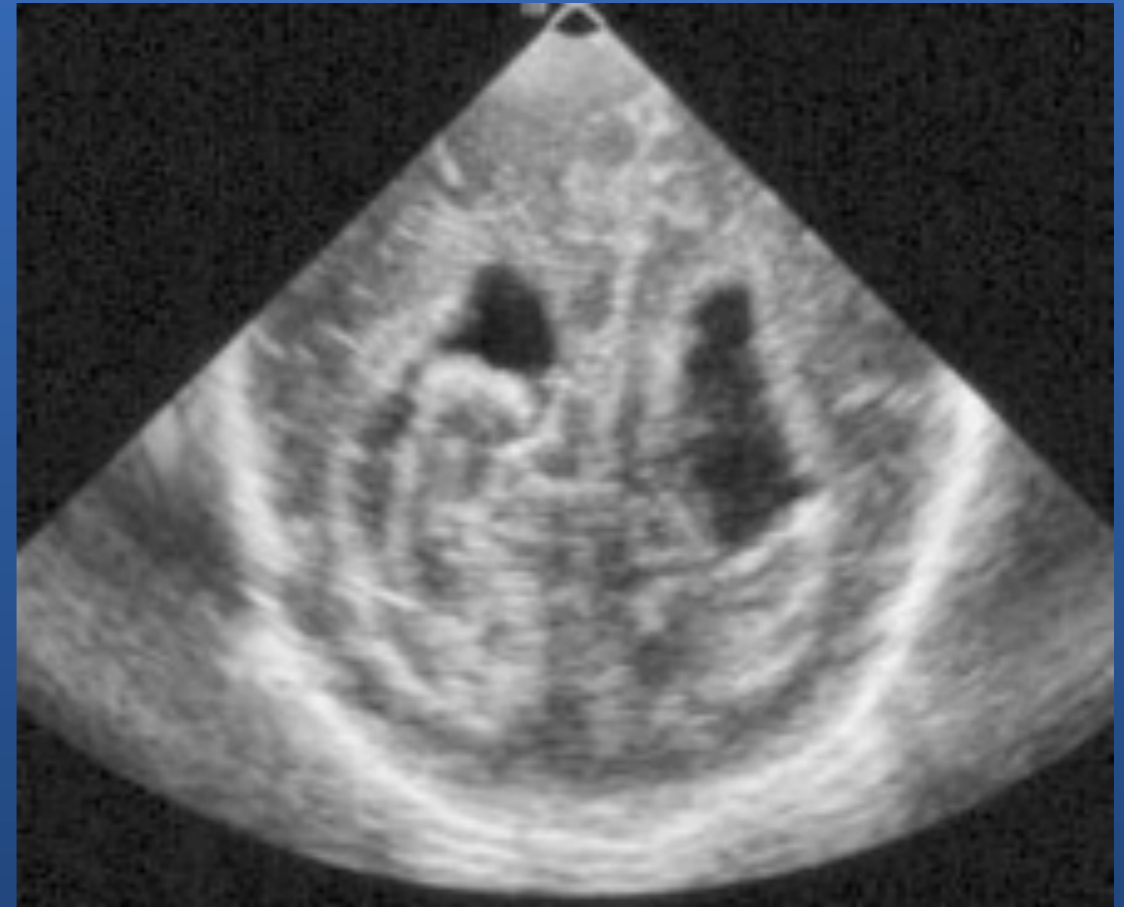


- **Évolution :**
- **nécrose du caillot, cavitation**
- **Résorption**
- **Bords ventriculaires échogènes**
- **hydrocéphalie**
 - **Obstacle**
 - **Trouble de résorption du LCR**



HEMORRAGIE VENTRICULAIRE : evolution

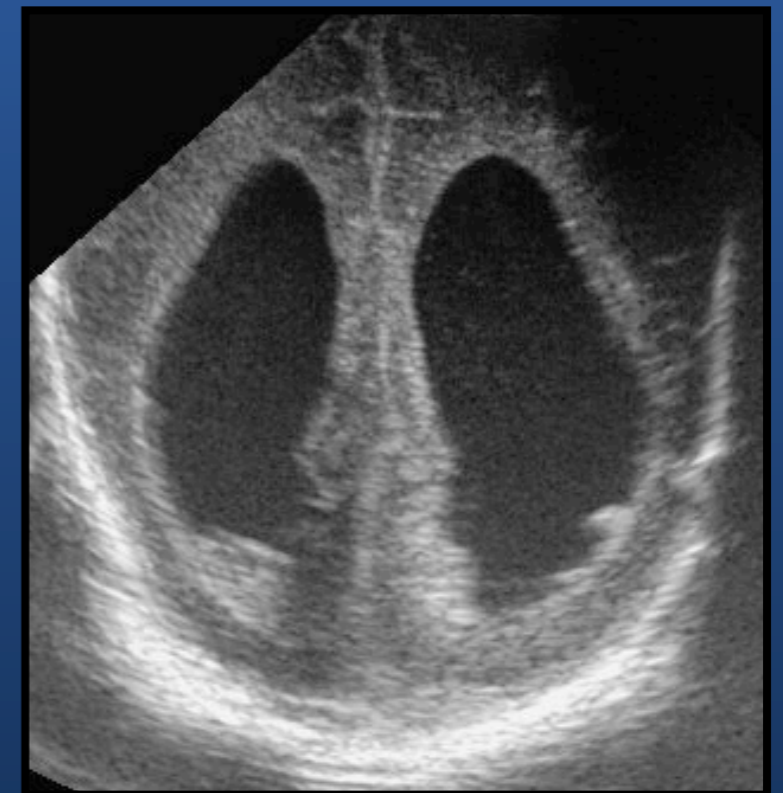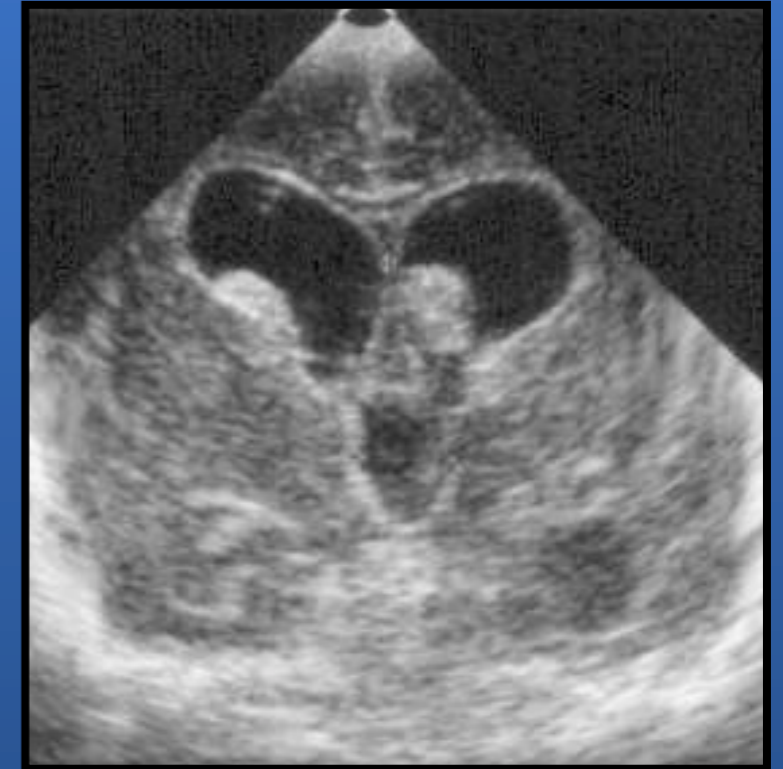- **Évolution :**
- **nécrose du caillot, cavitation**
- **Résorption**
- **Bords ventriculaires échogènes**
- **hydrocéphalie**
 - **Obstacle**
 - **Trouble de résorption du LCR**



Hémorragie intra ventriculaire avec dilatation

Stede III de Papile

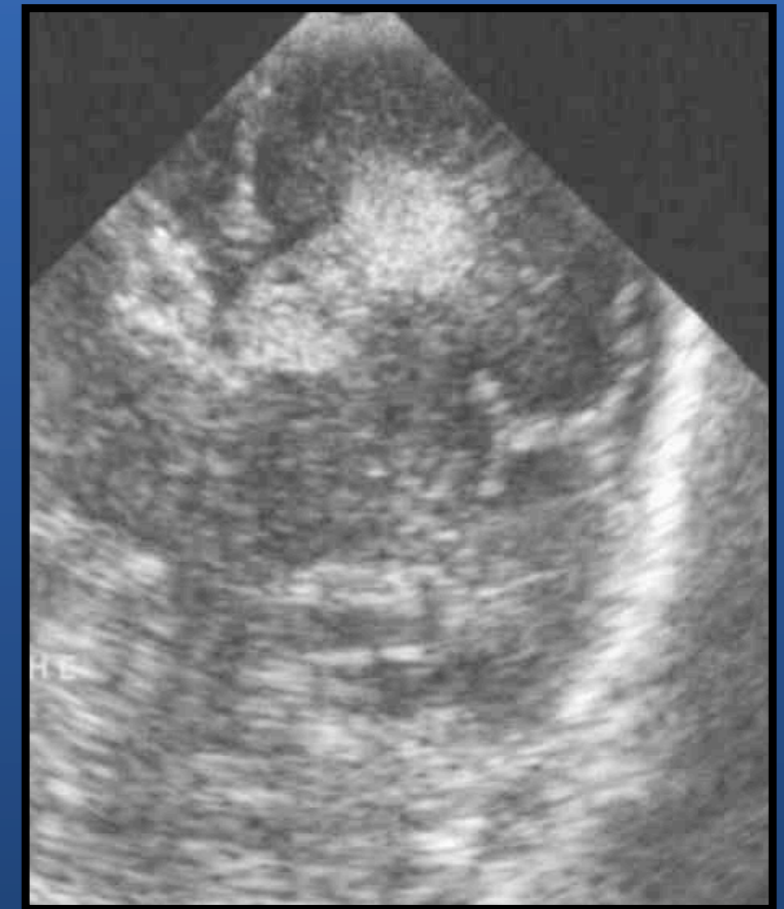- **Majeure**
 - Dérivation ?
- **Localisation**
 - symétrique ou non (Monro)
 - uni, bi, triventriculaire
 - quadriventriculaire :
résorption ?

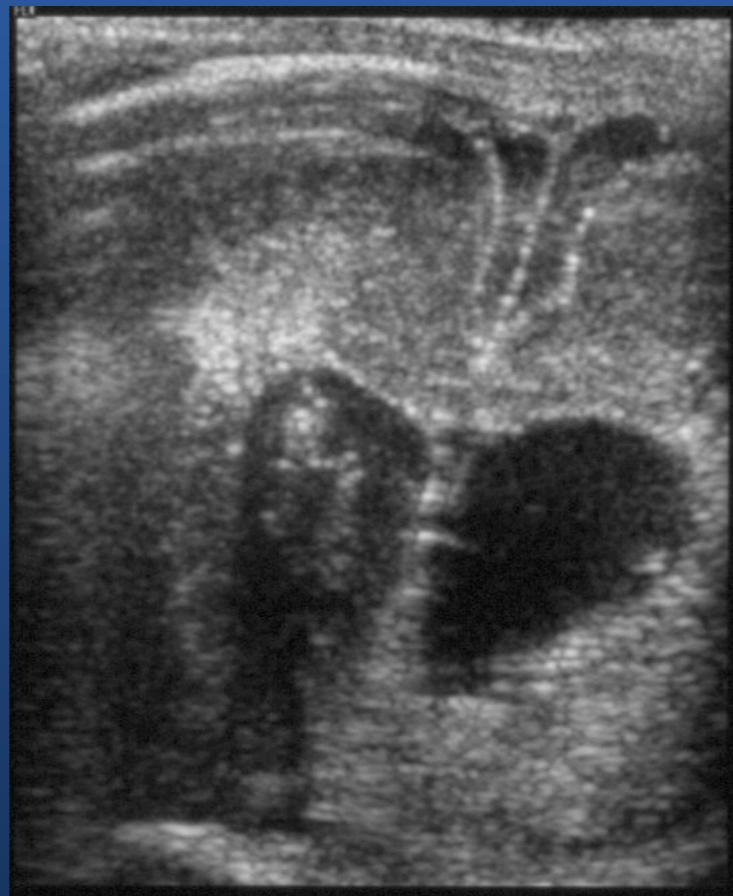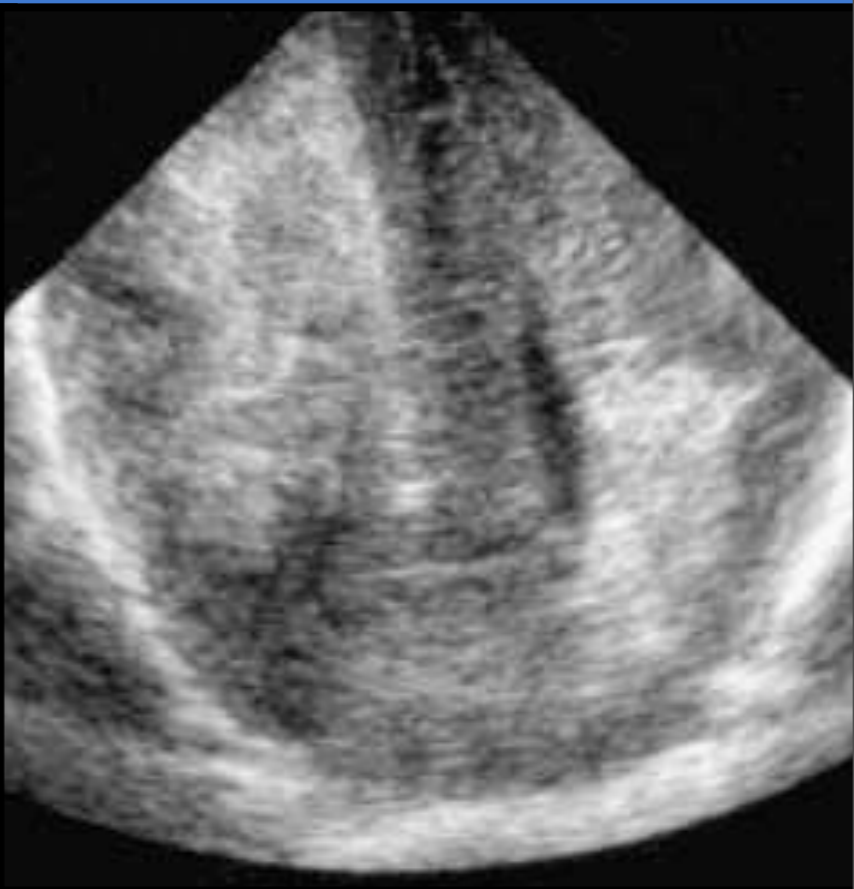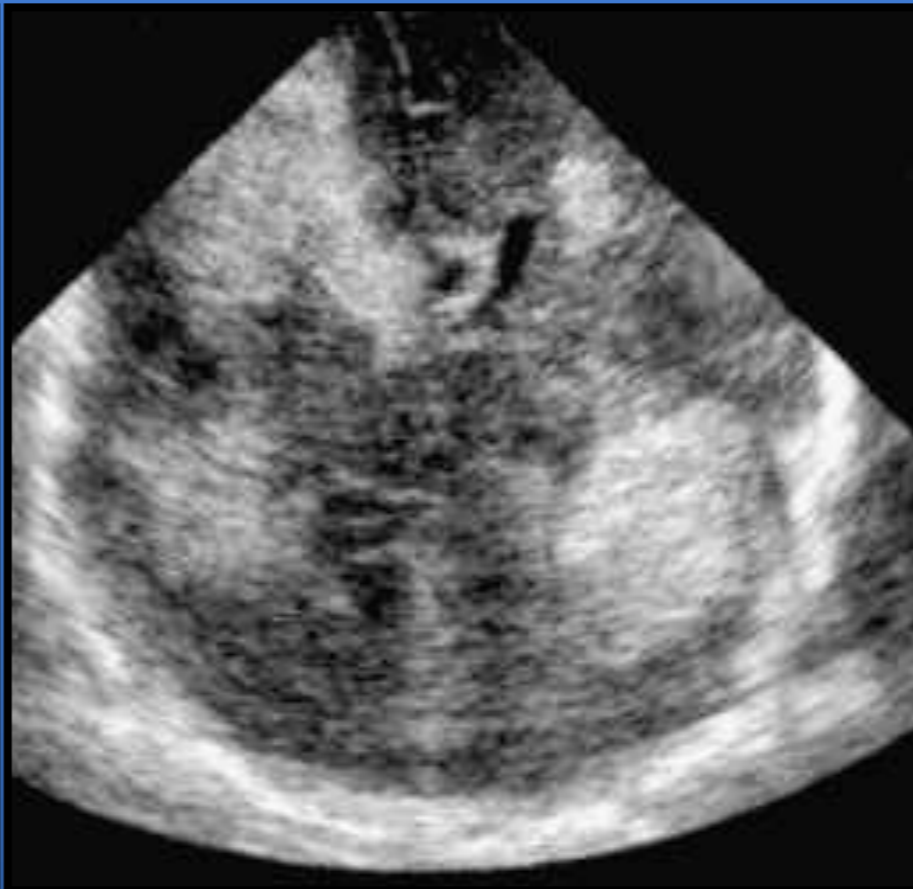
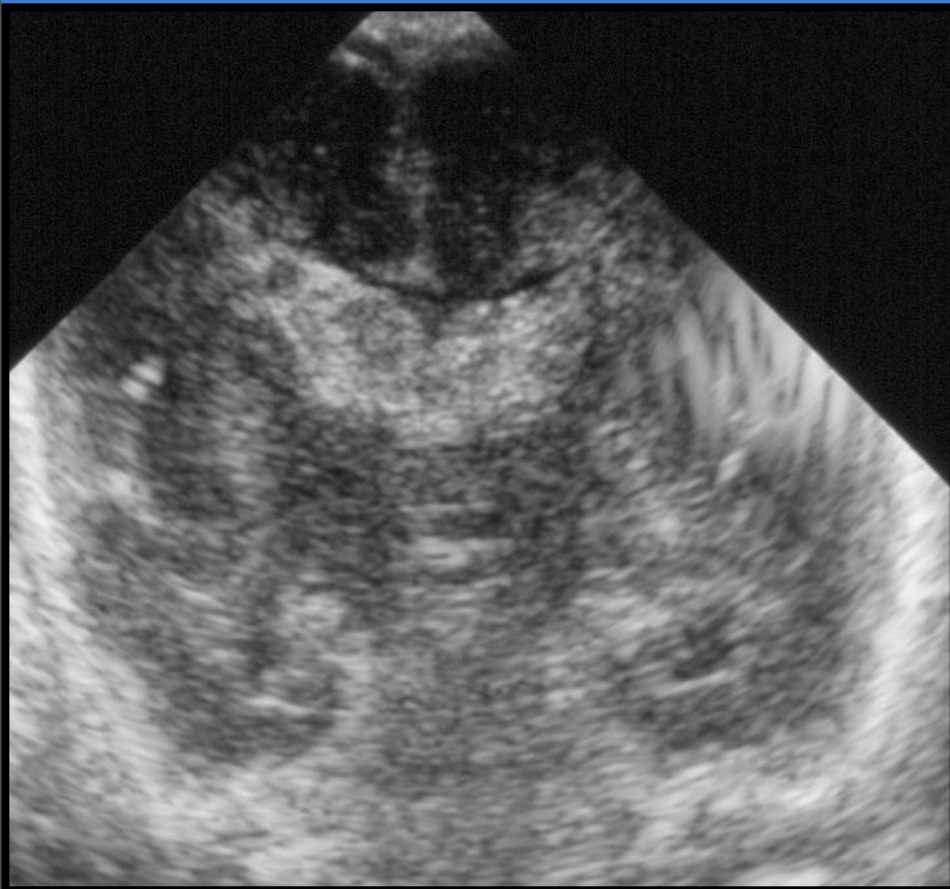


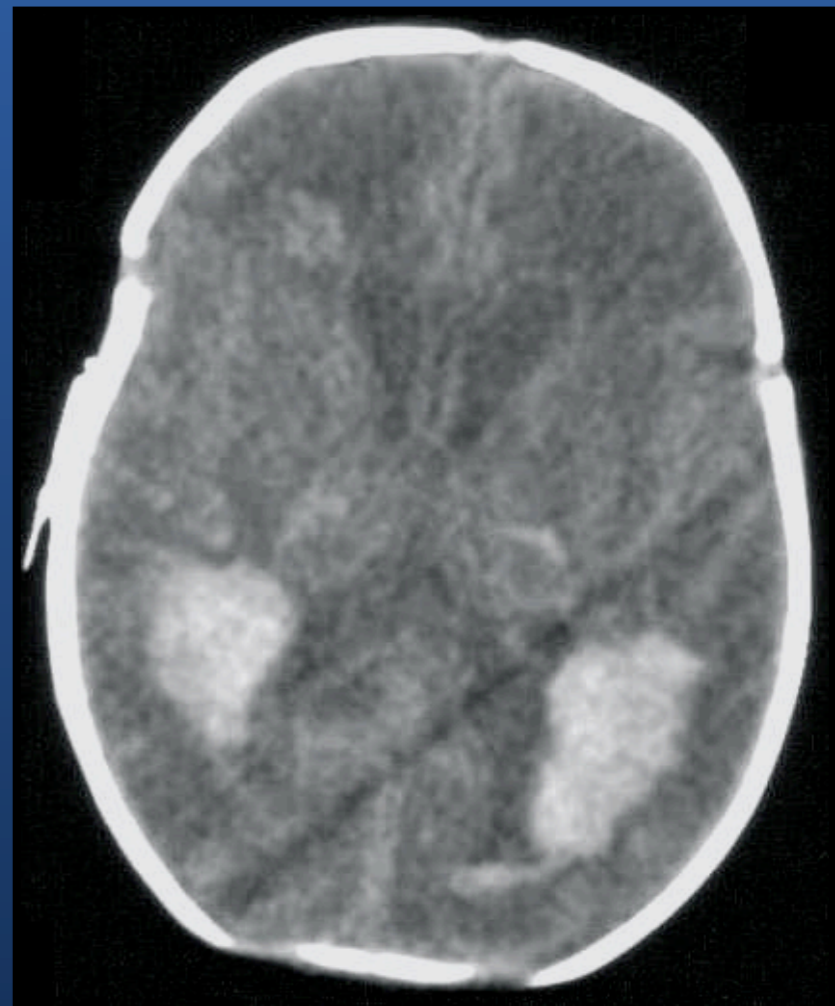
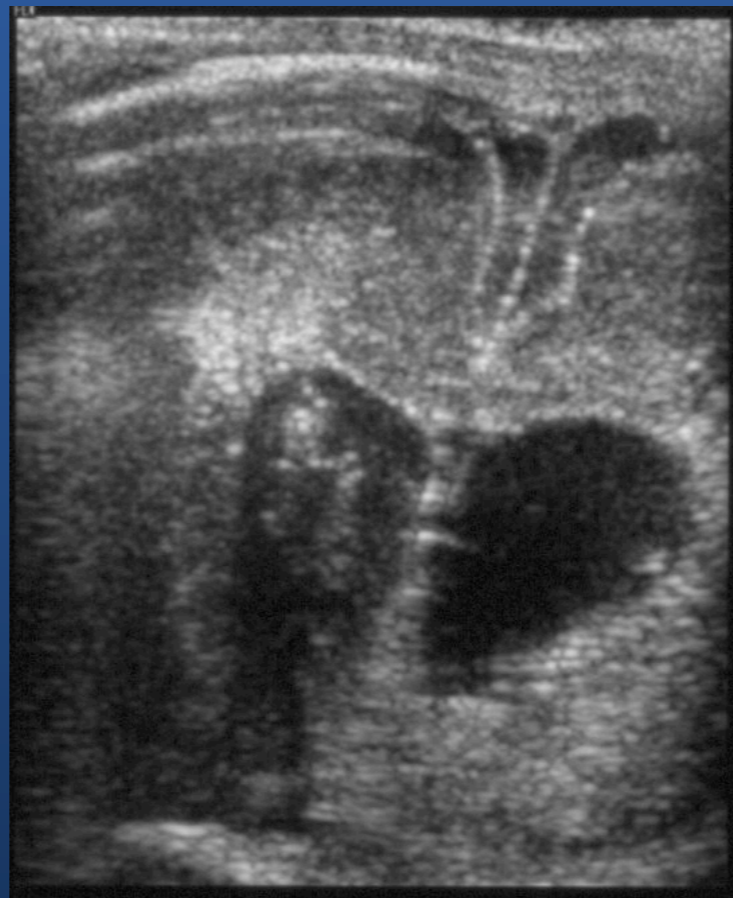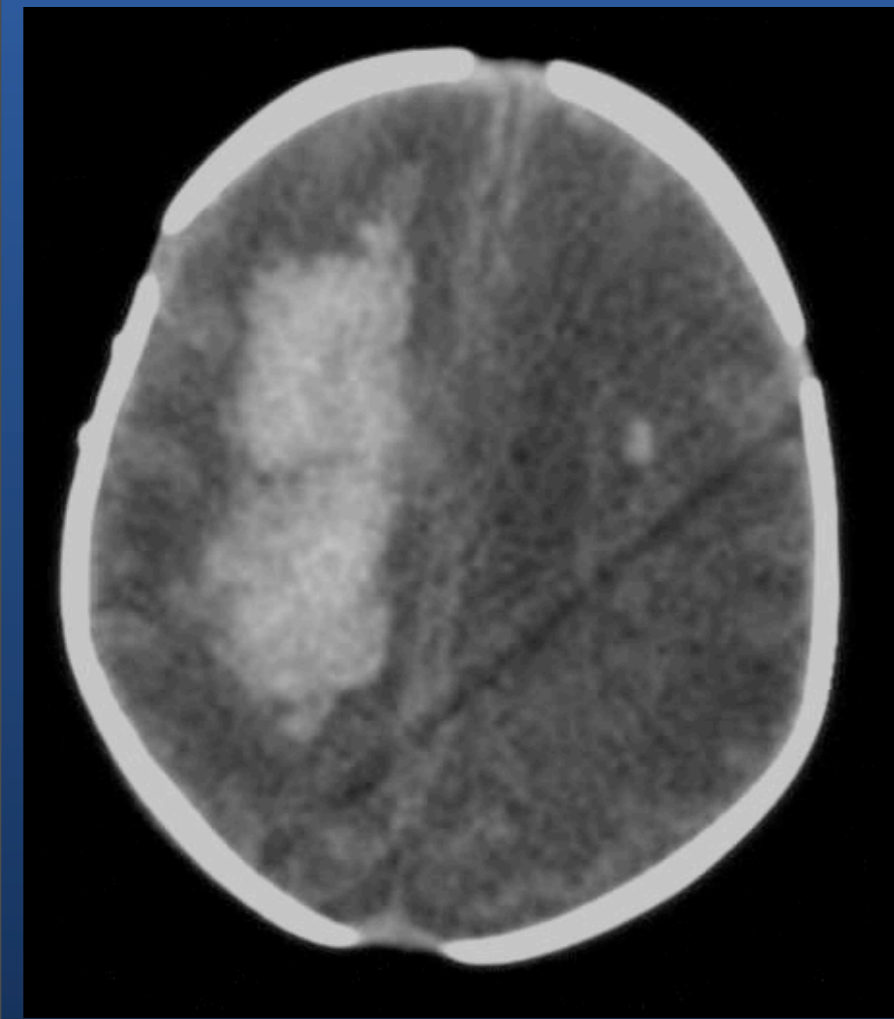
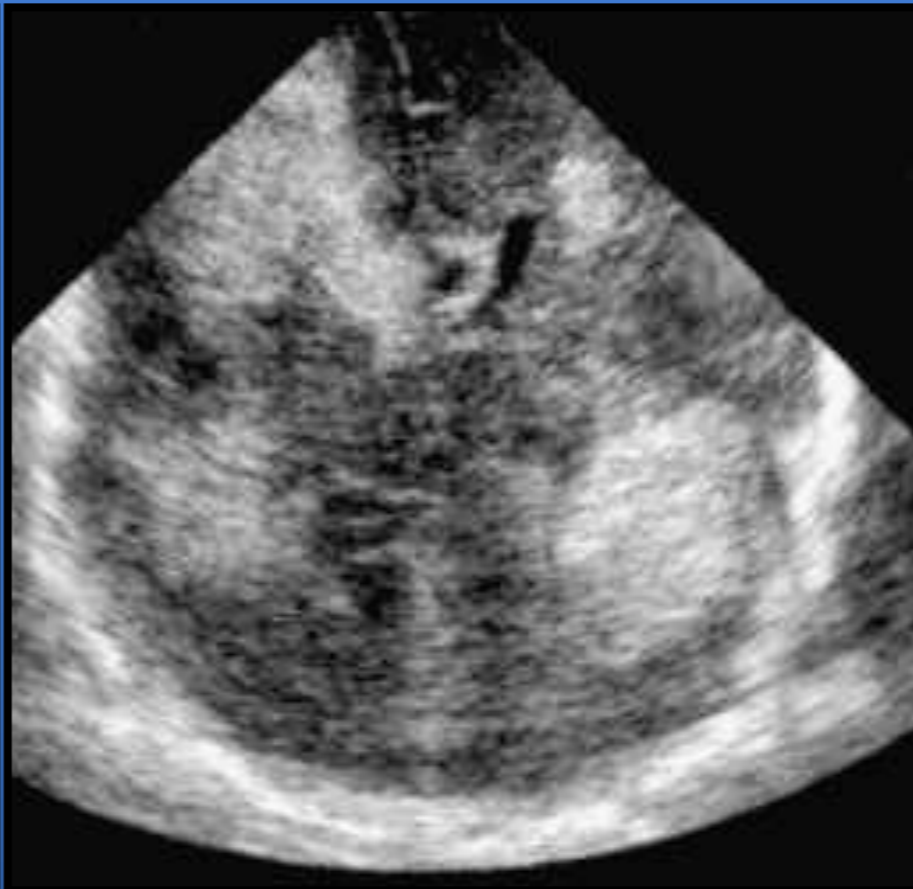
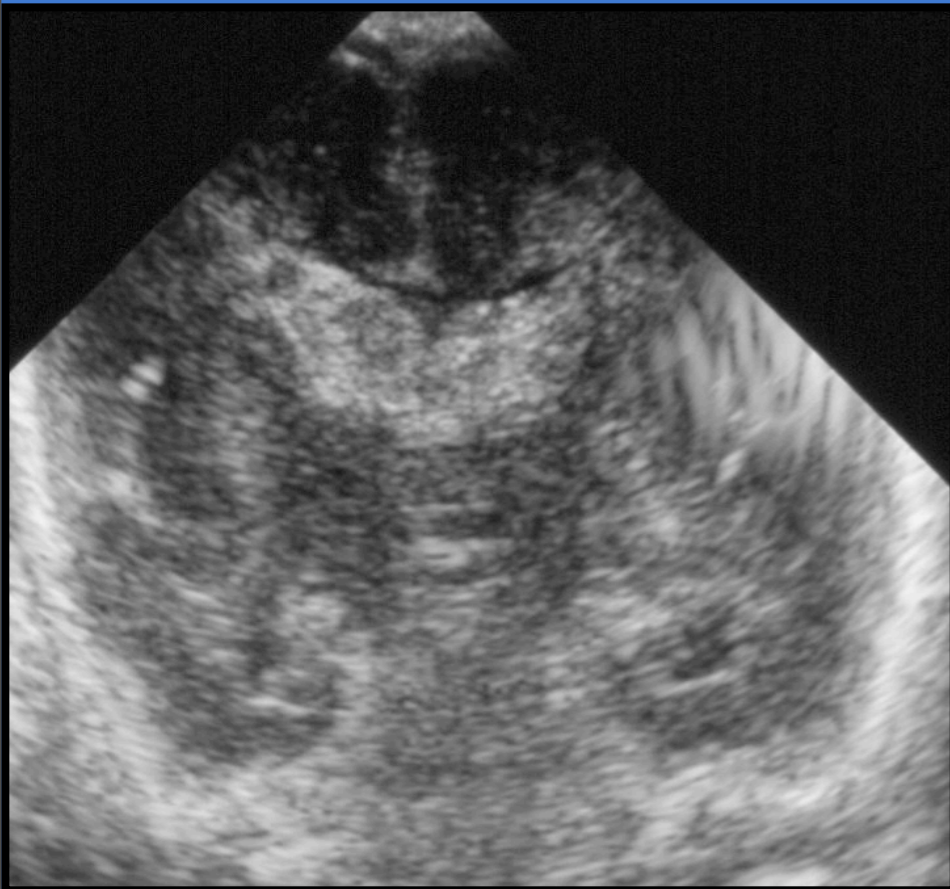
HEMORRAGIE PARENCHYMATEUSE

(Stade IV de Papile)

- **Infarctissement hémorragique**
- **Toujours associée au stade II (ou III)**
- **Hyperéchogénicité juxta-ventriculaire**
 - Avec ou sans effet de masse
 - Bien limitée
- **Peut toucher les noyaux gris centraux**
- **Diagnostic différentiel : LPV**



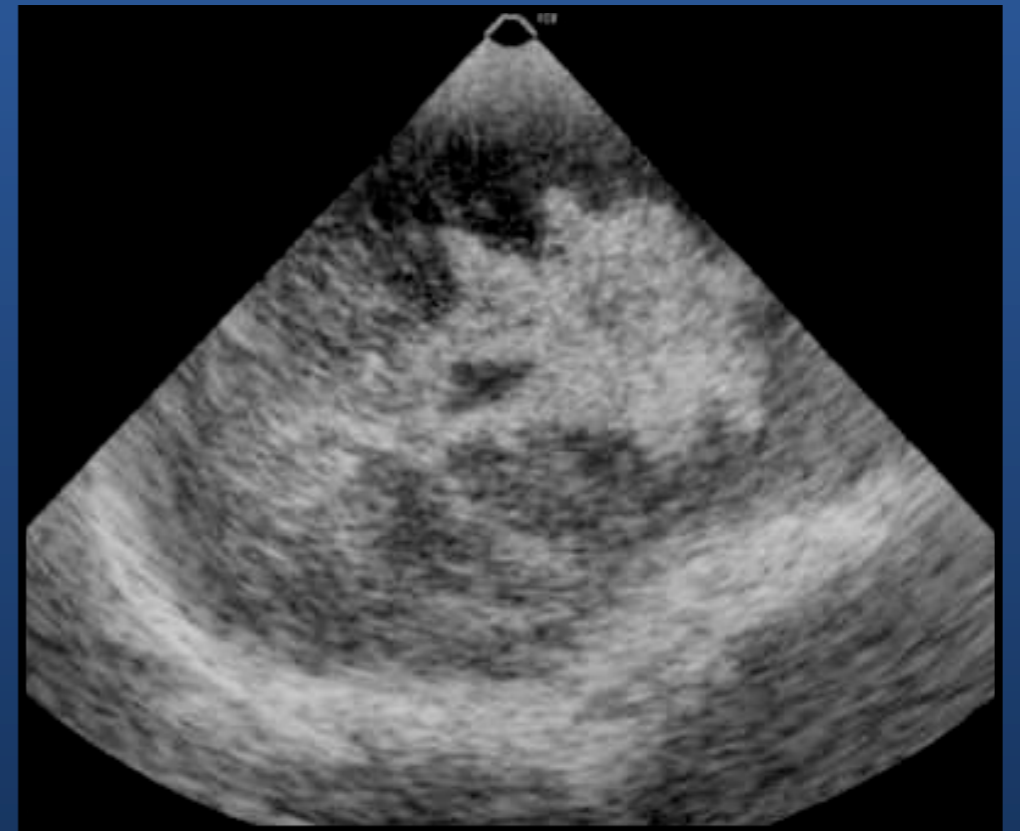
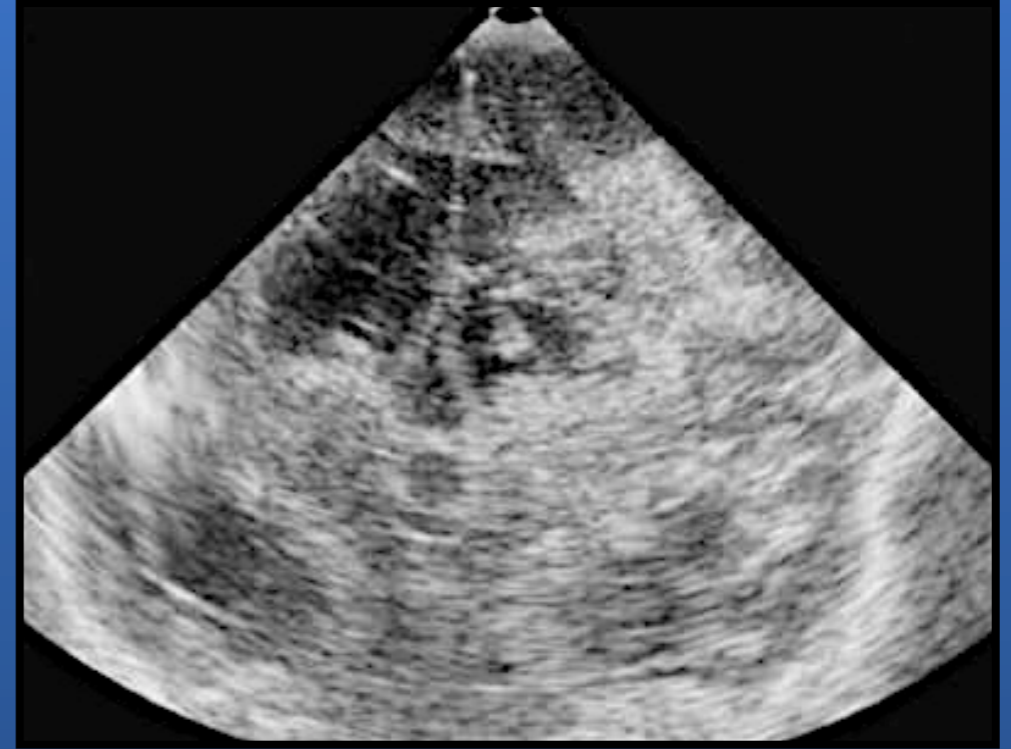




HEMORRAGIE PARENCHYMATEUSE

(Stade IV de Papile) **EVOLUTION :**

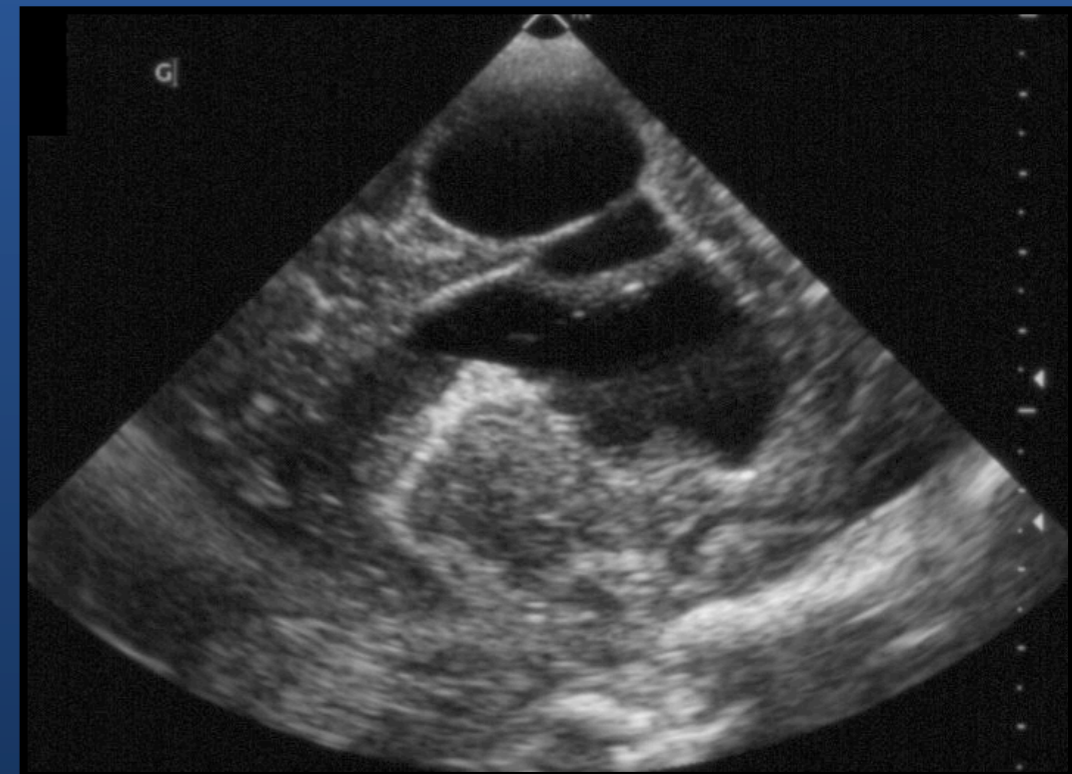
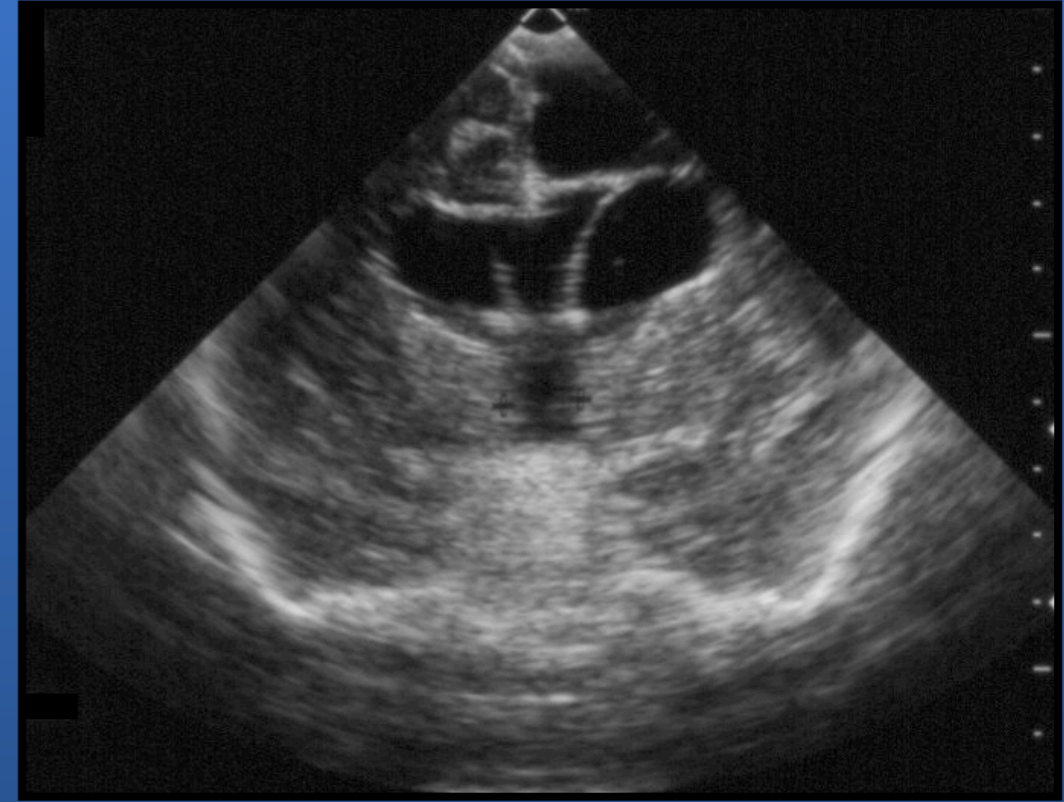
- **Aggravation initiale J4**
- **Nécrose centrale**
- **Évolution vers la cavitation**
 - **Cavité porencéphalique communicante**
- **Pronostic sombre**



HEMORRAGIE PARENCHYMATEUSE

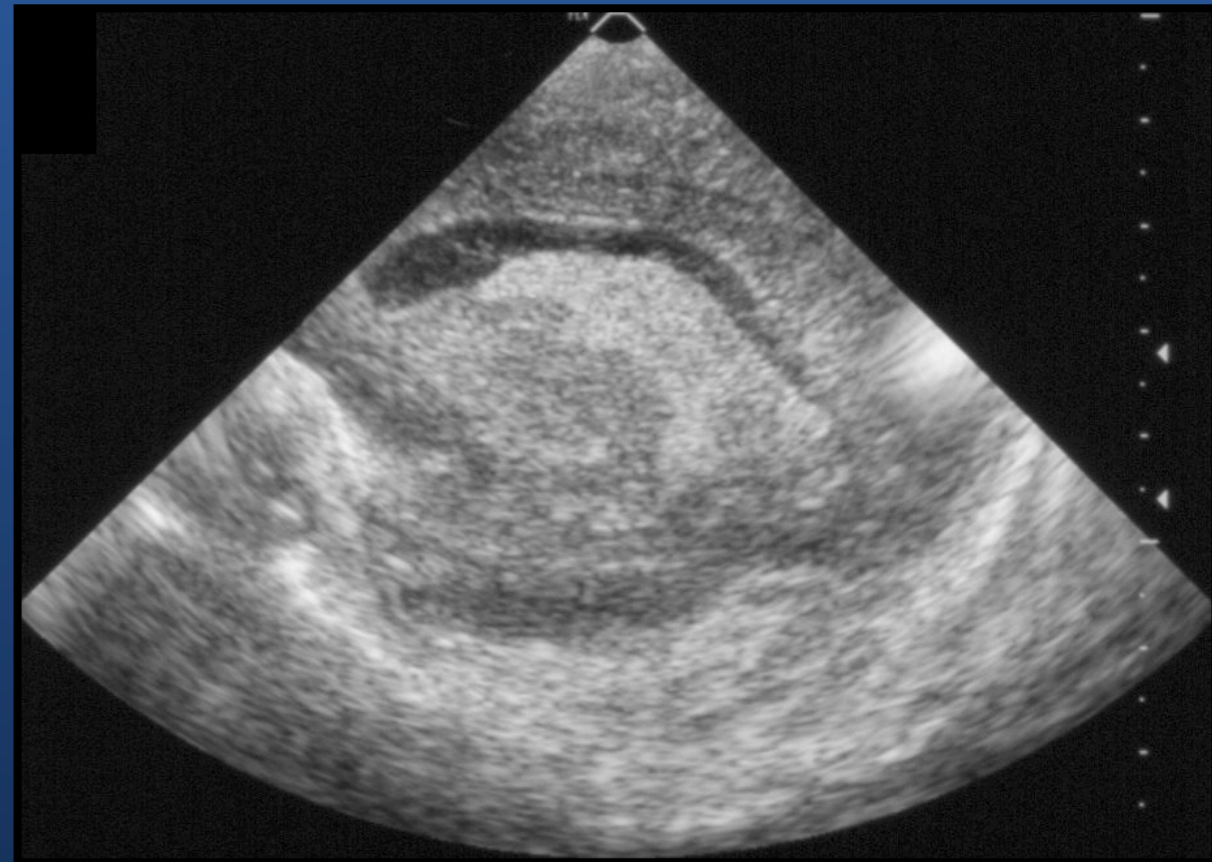
(Stade IV de Papile) **EVOLUTION :**

- **Aggravation initiale J4**
- **Nécrose centrale**
- **Évolution vers la cavitation**
 - **Cavité porencéphalique communicante**
- **Pronostic sombre**



HEMORRAGIE DU NOUVEAU NE A TERME

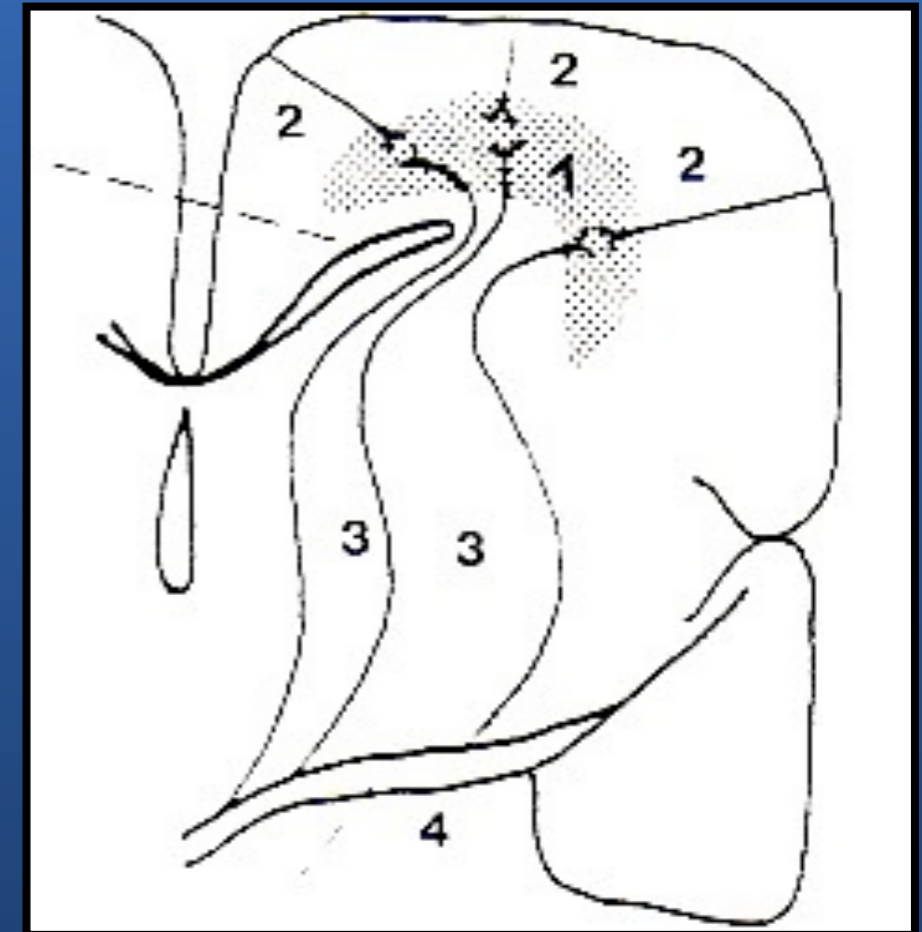
- Plexus choroïdes > matrice germinale
- Anoxo-ischémie
- Traumatologie
- Anomalie de la coagulation
- 25% étiologie non retrouvée



PATHOLOGIE ISCHEMIQUE

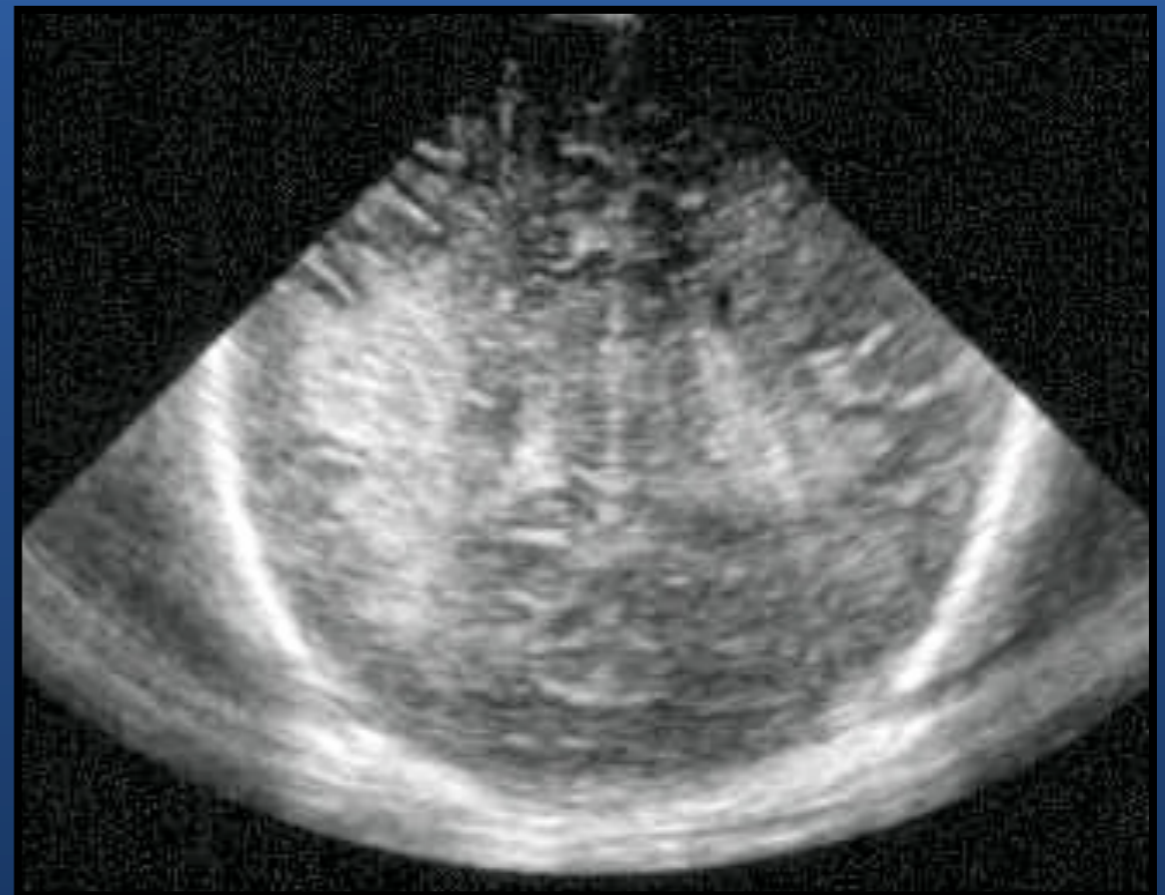
LEUCOMALACIE PERI-VENTRICULAIRE

- **Pathologie ischémique**
 - zones frontières
 - Substance blanche
- **Grave, pronostic moteur**
- **Prématuré < à 30 SA**
- **Immaturité :**
 - troubles de l'autorégulation :
 - DCC, PO^2 , PCO^2 , PA

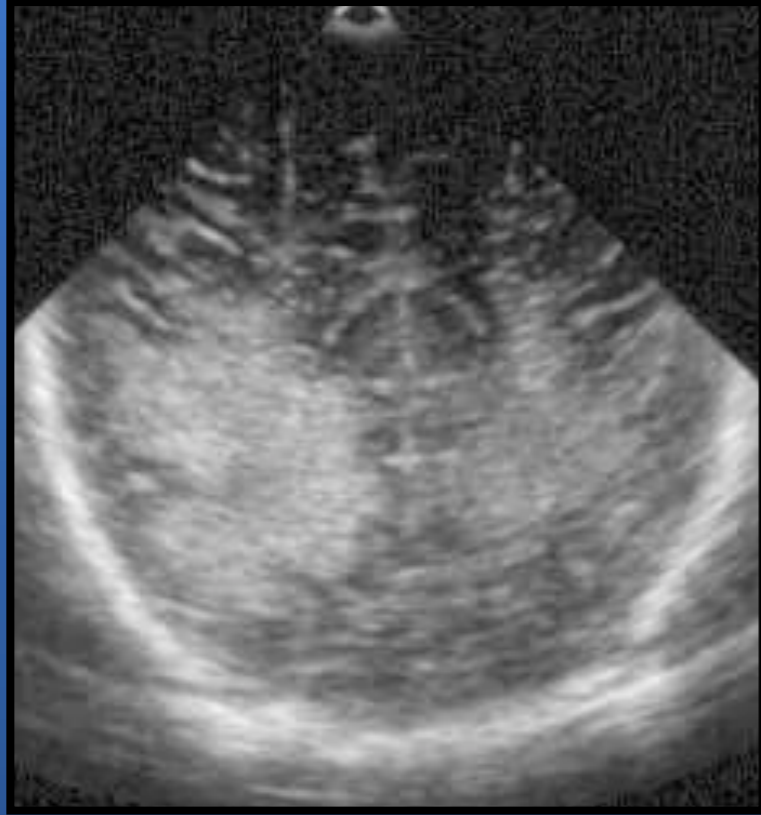


L.P.V : SEMIOLOGIE

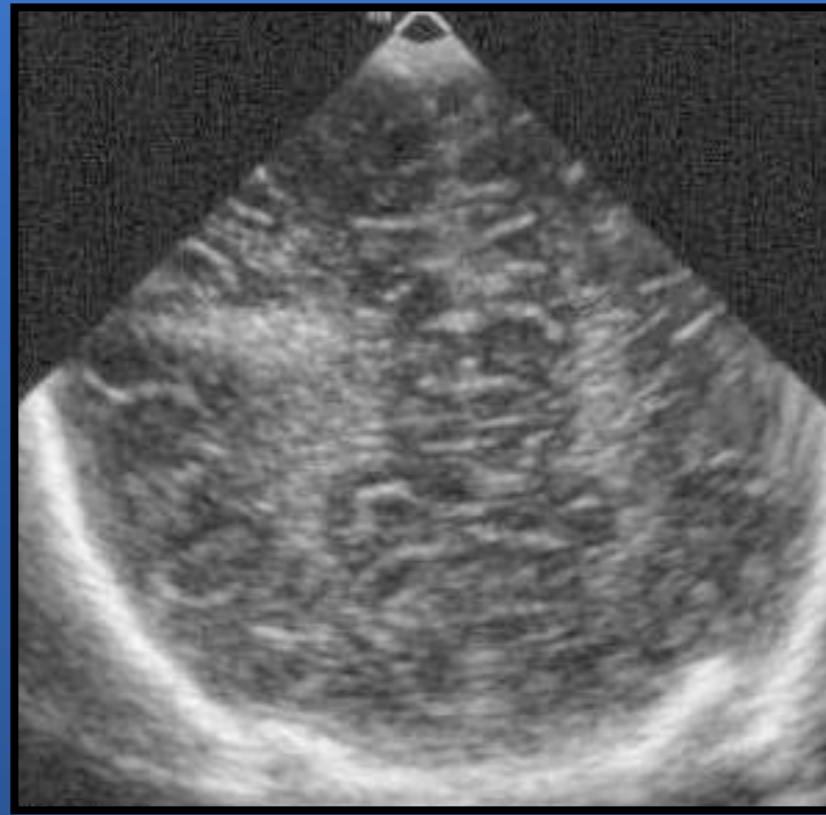
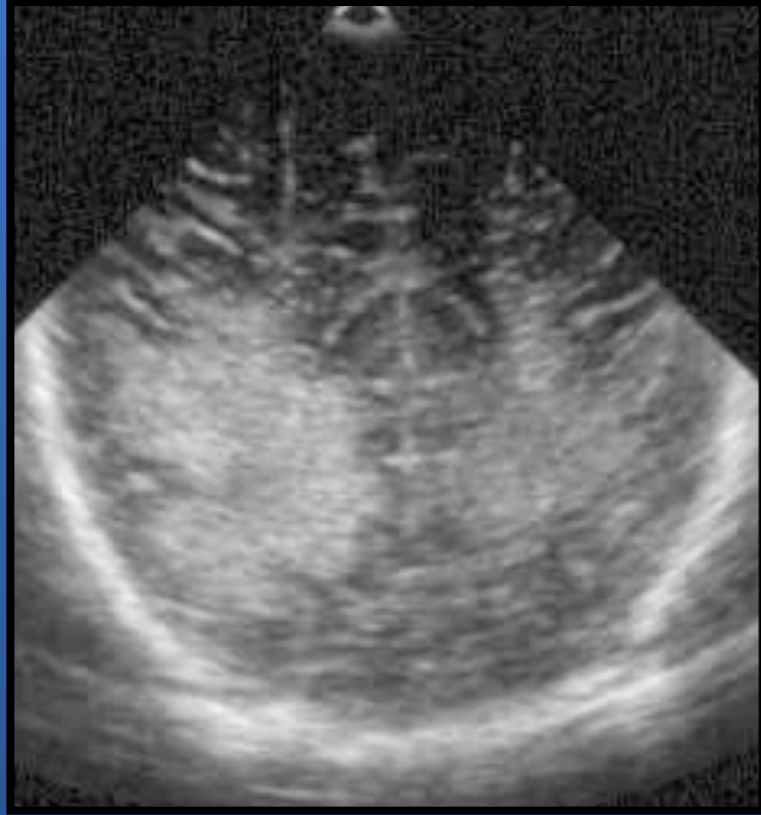
- **Hyperéchogénicité de la SB péri-ventriculaire**
- **Localisé (triangulaire)**
- **ou diffuse**
- **difficulté diagnostique :**
 - prématurité
 - diagnostic par excès



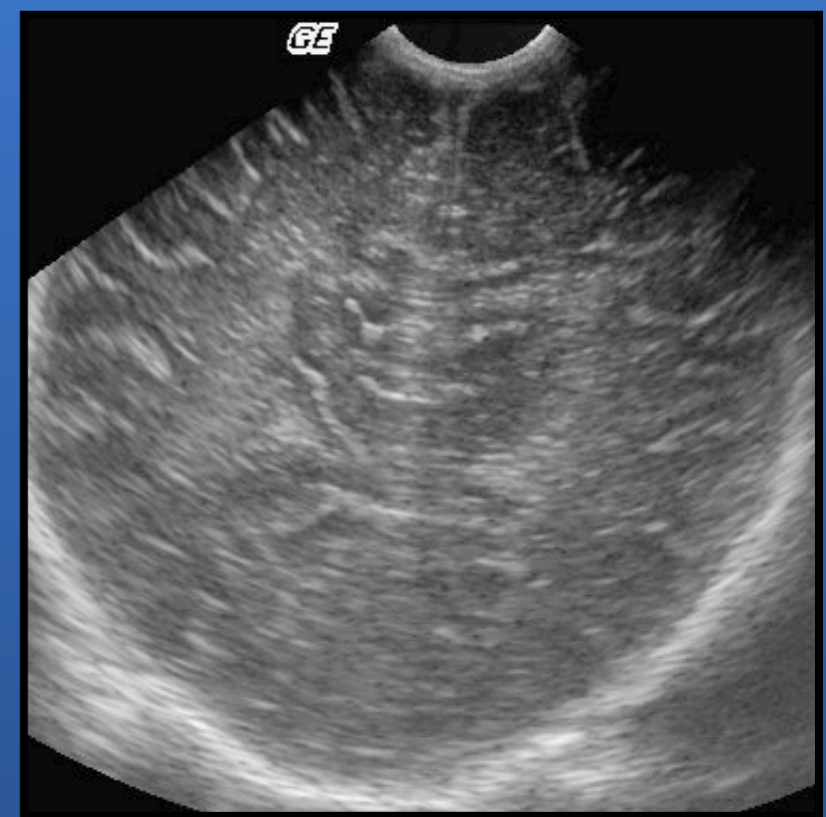
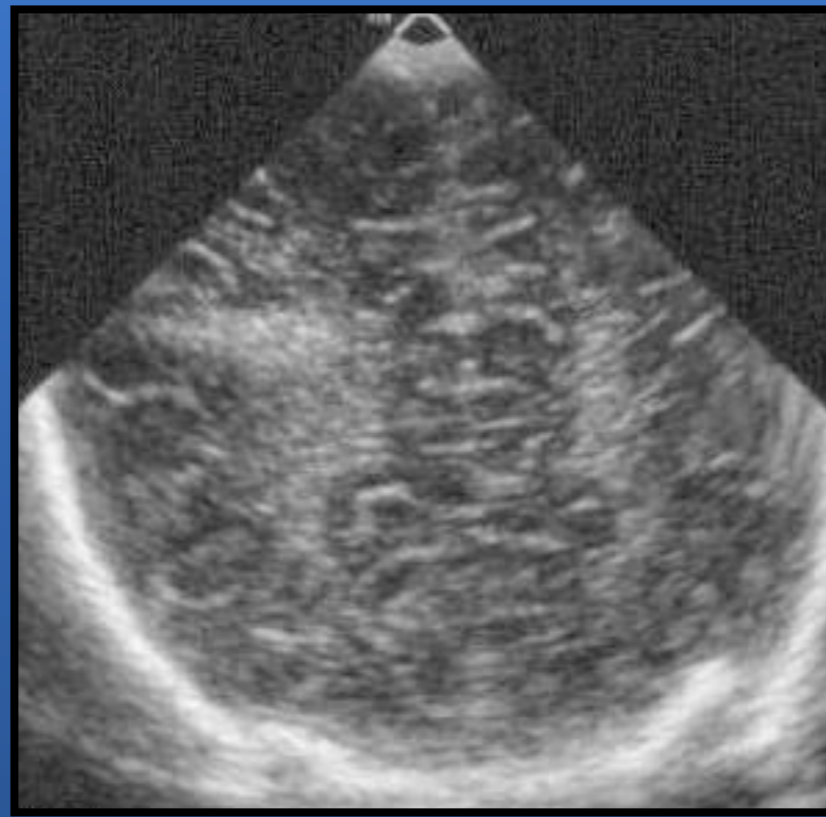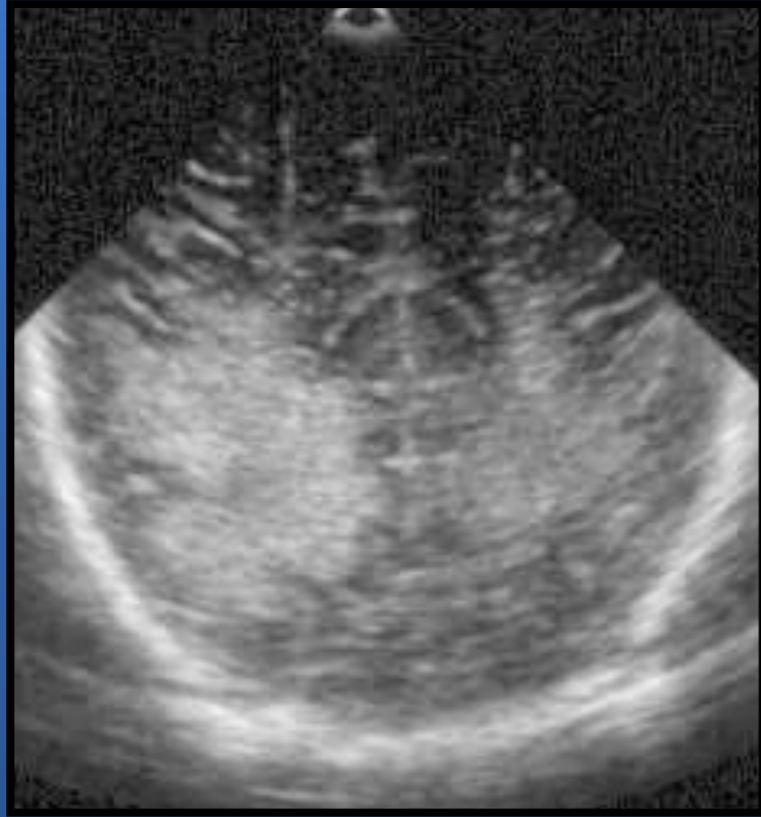
LPV : Coronal



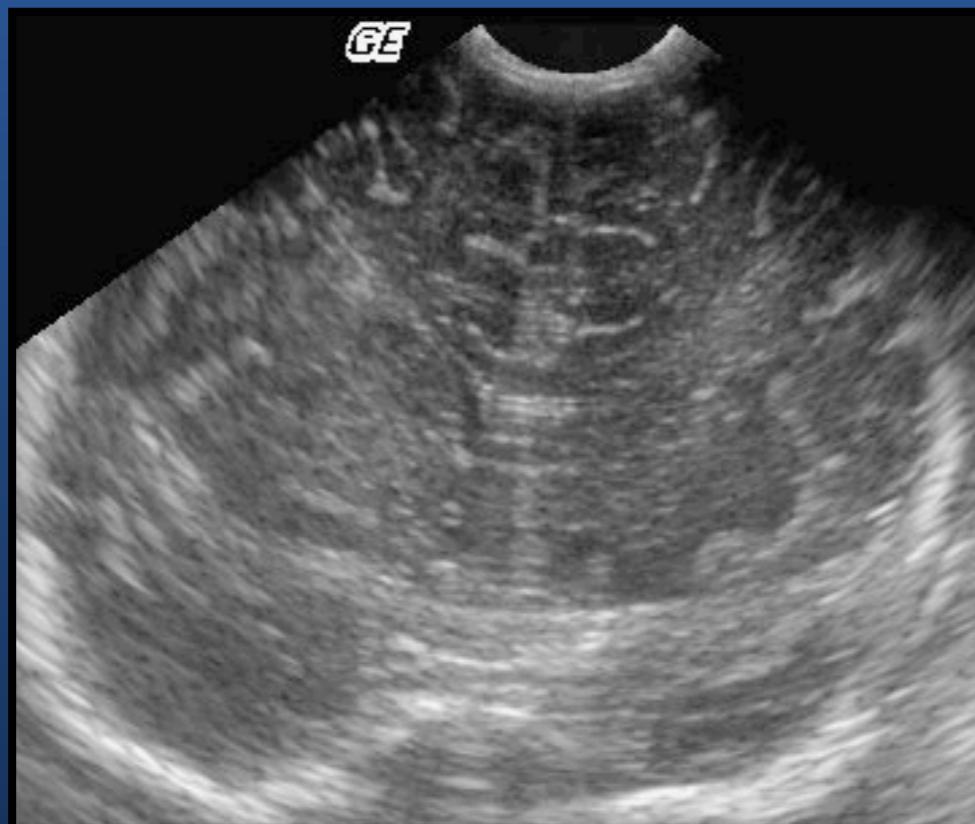
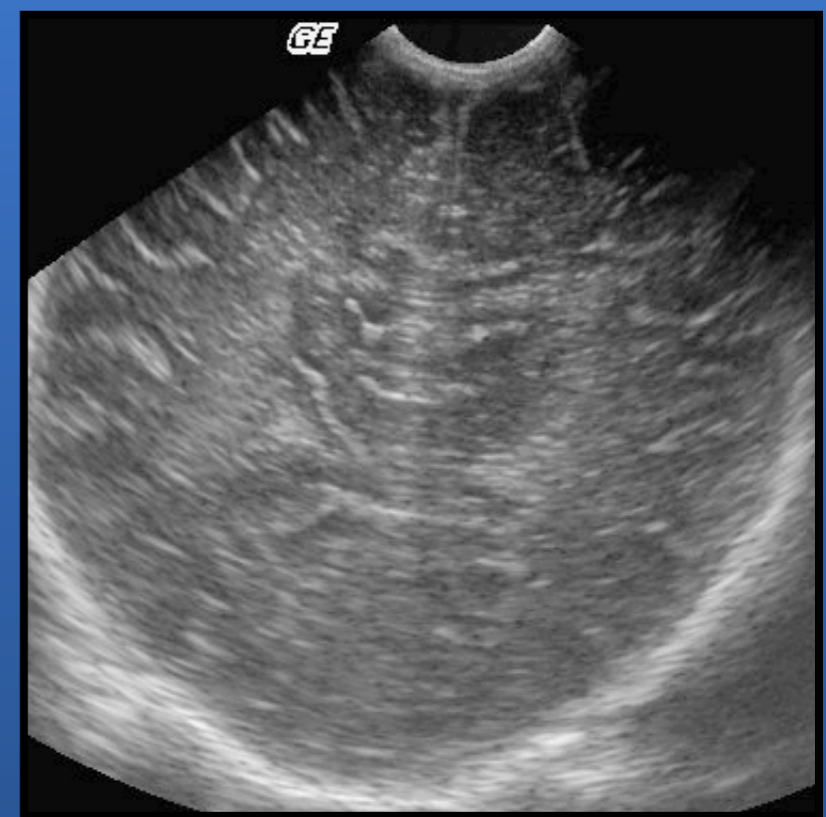
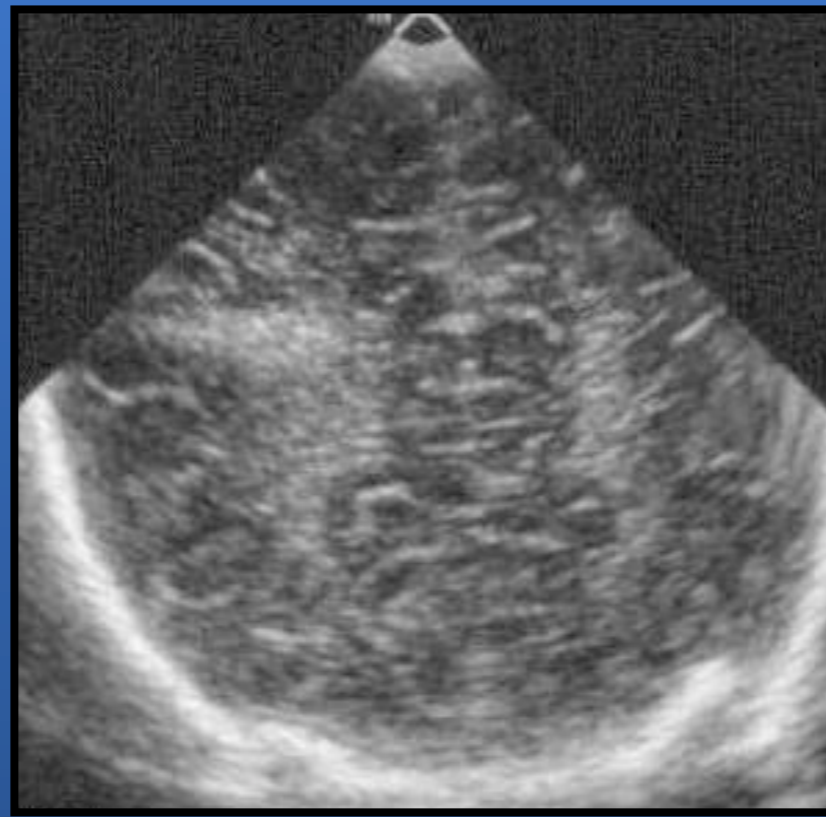
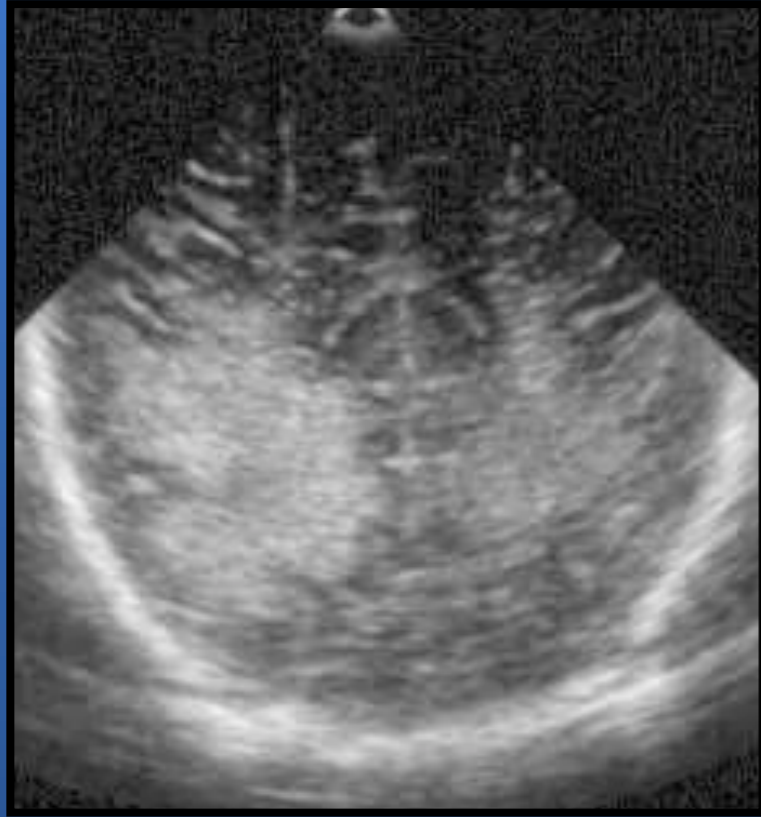
LPV : Coronal



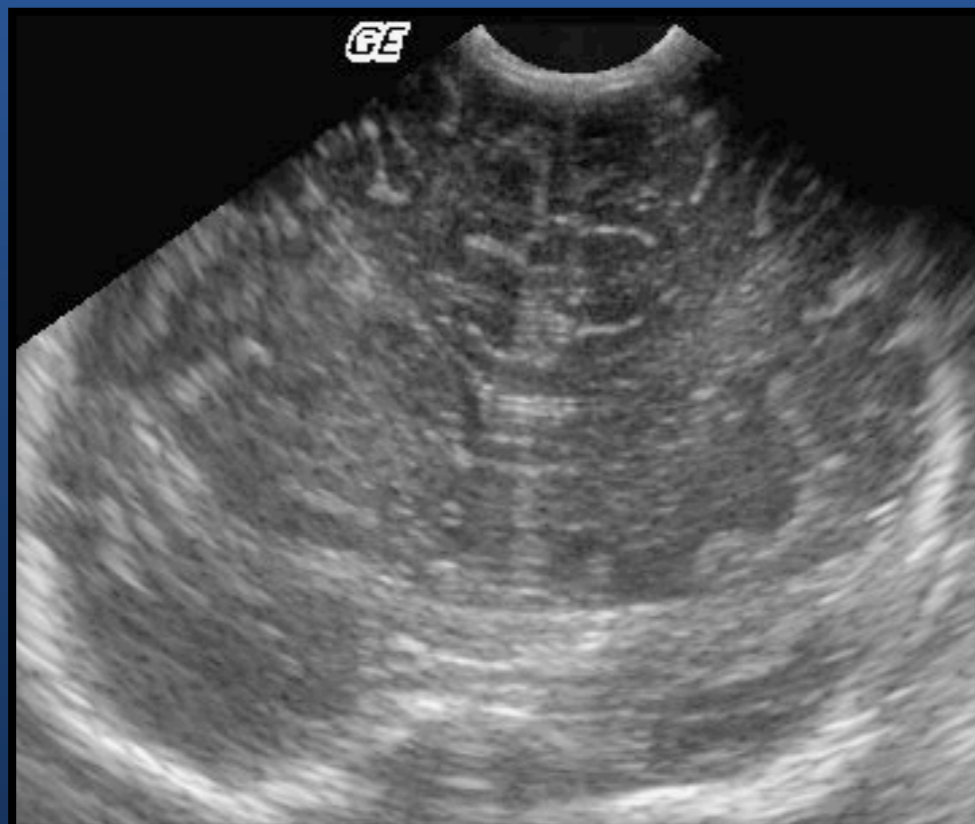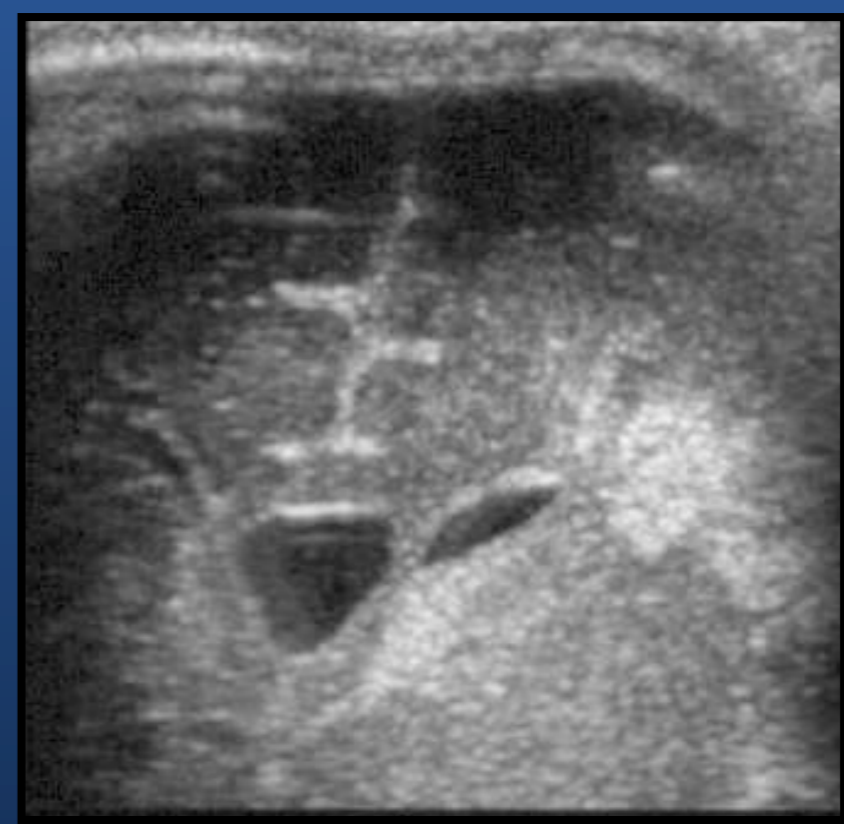
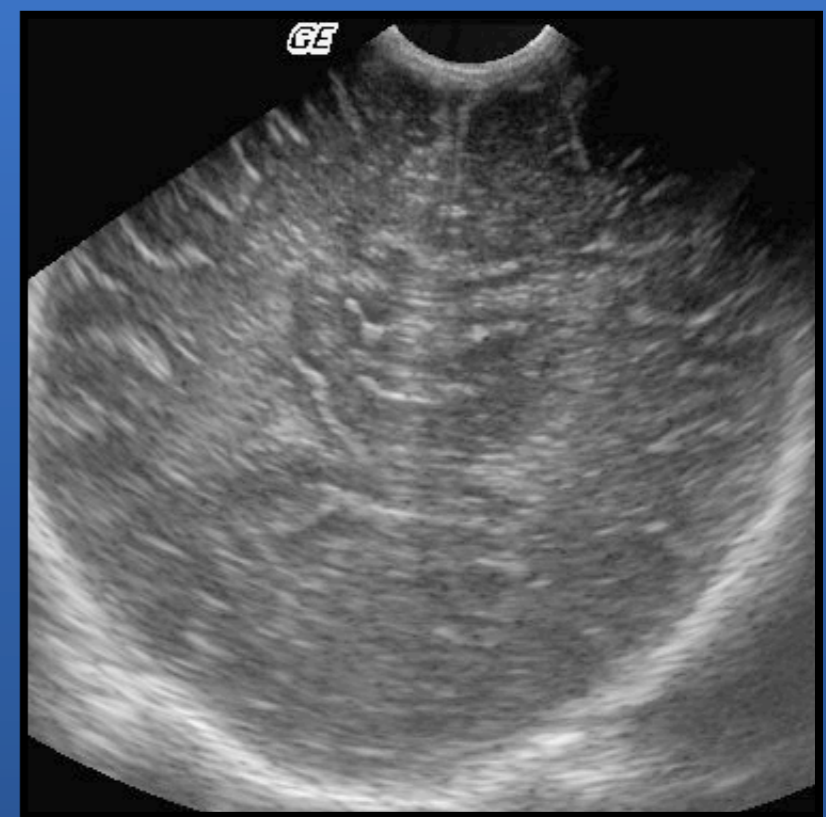
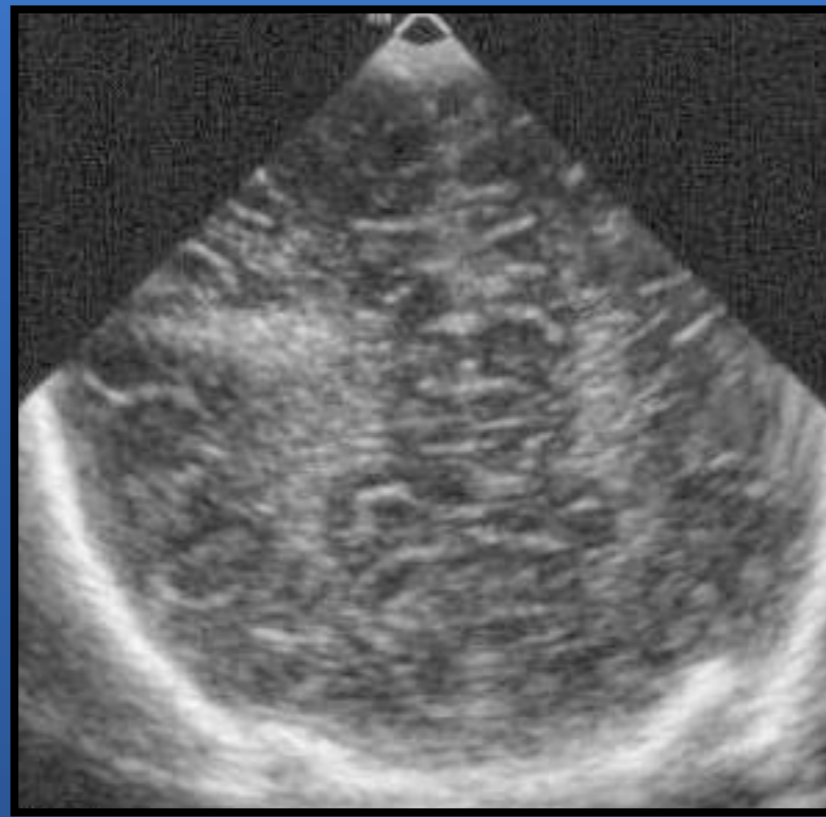
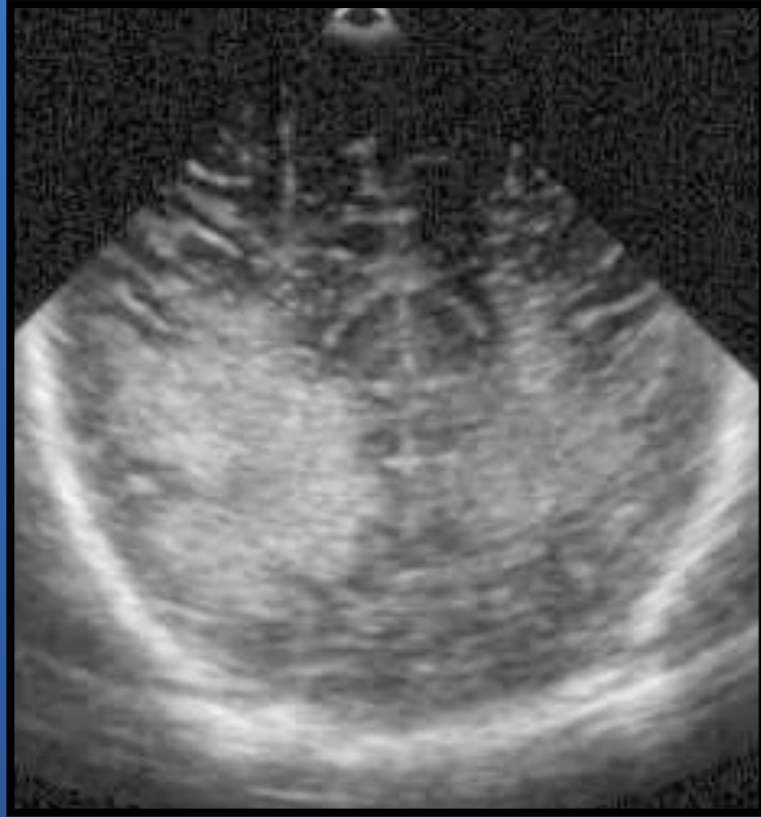
LPV : Coronal



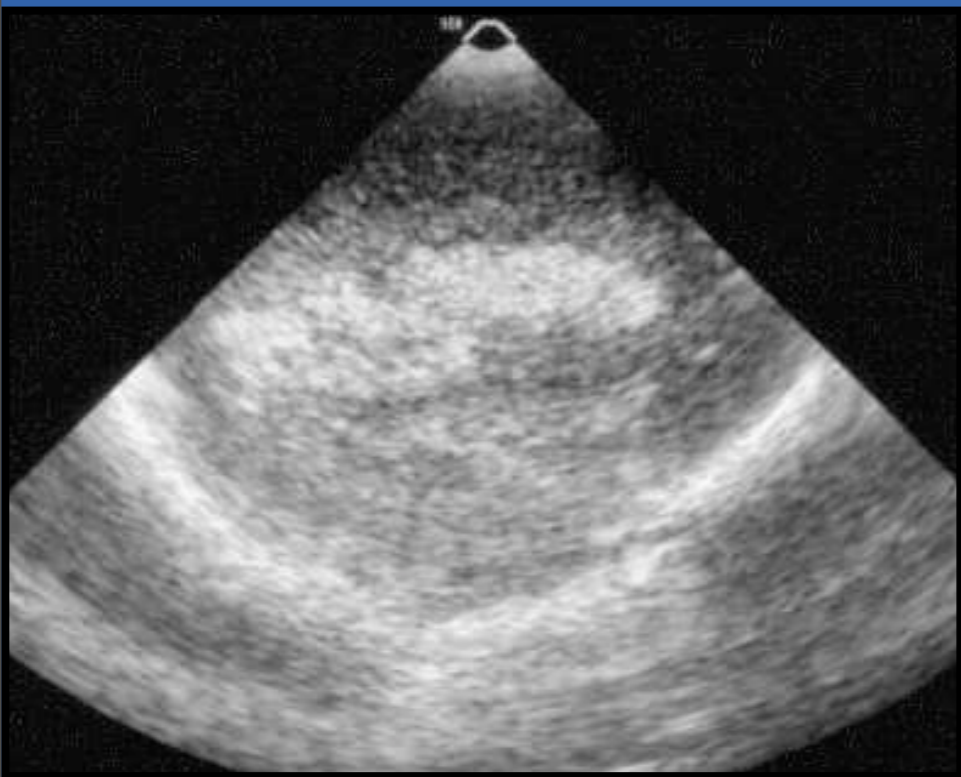
LPV : Coronal



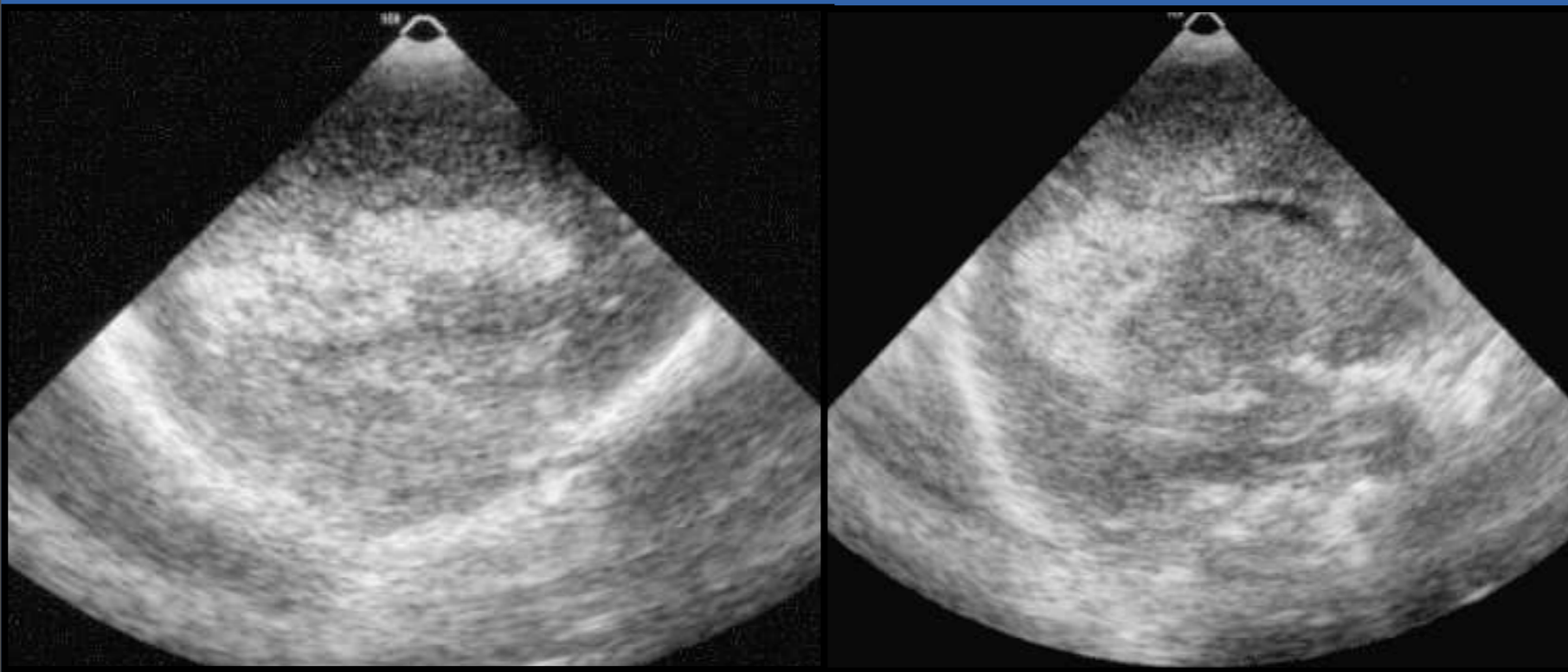
LPV : Coronal



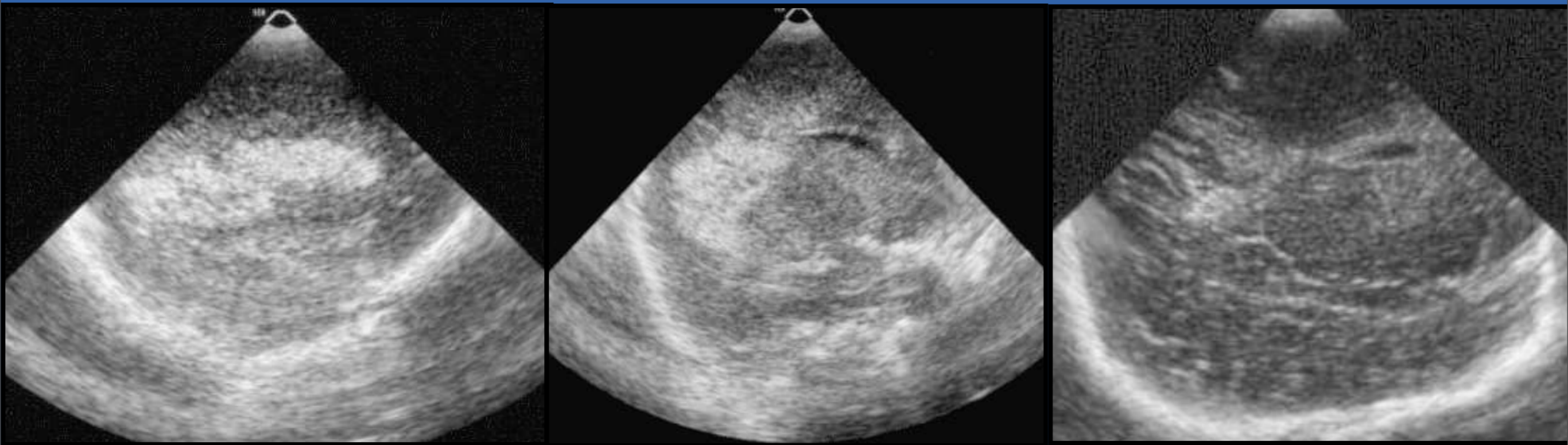
LPV : Sagittal



LPV : Sagittal

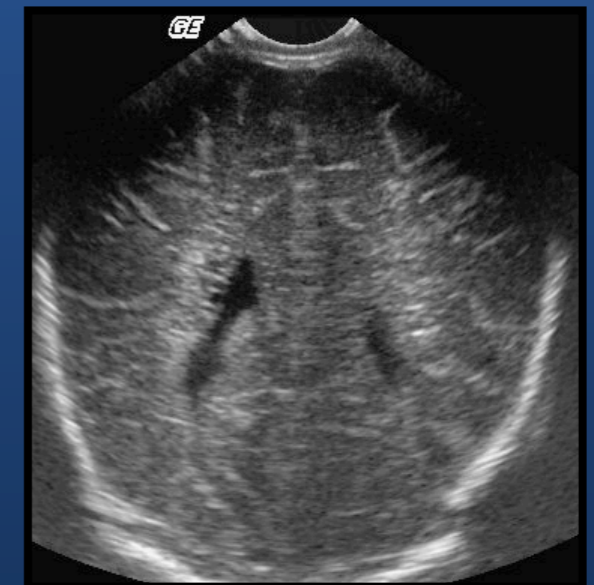
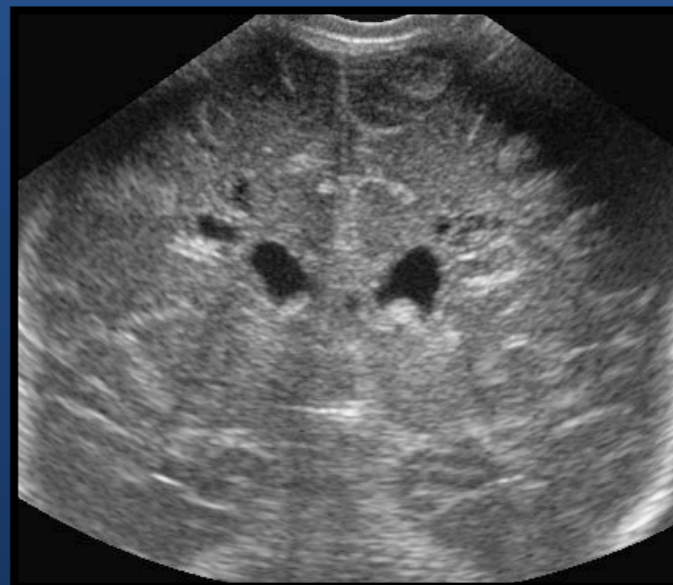
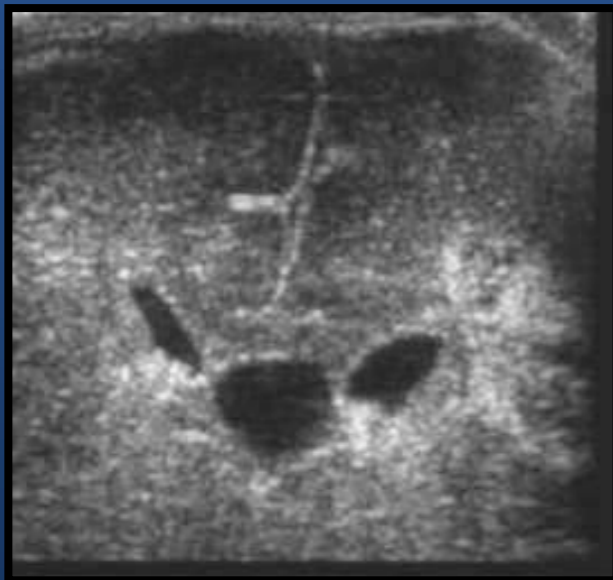
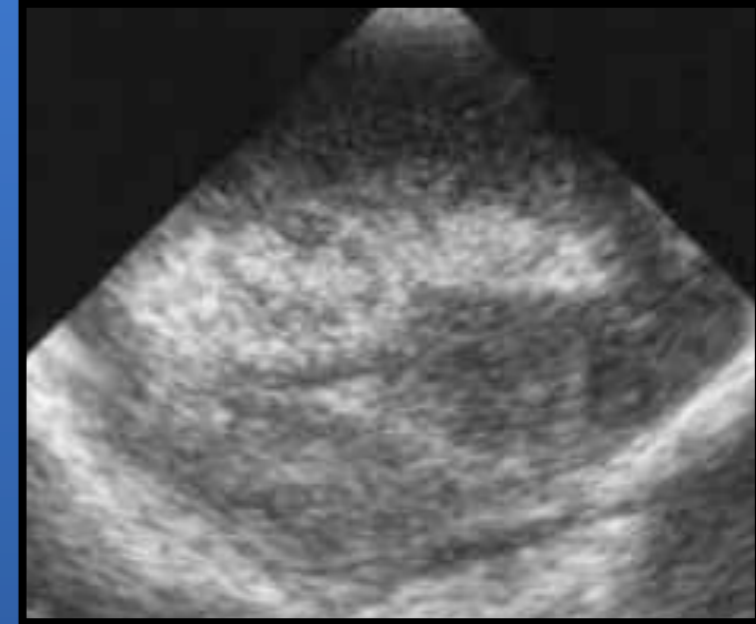LPV : Sagittal



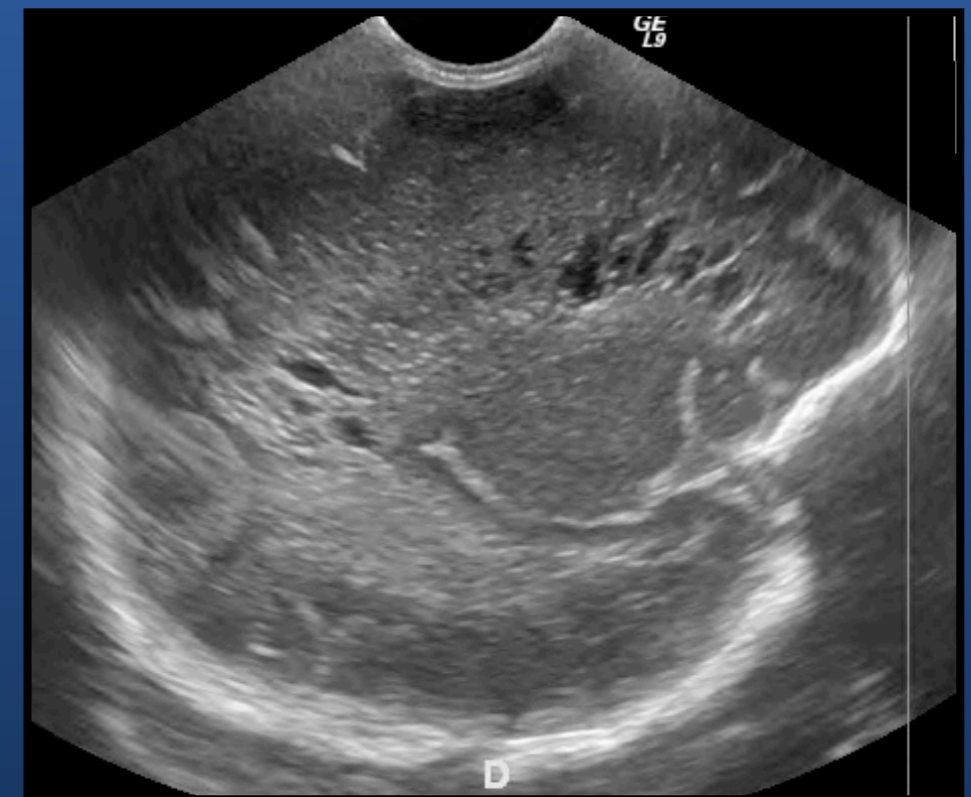
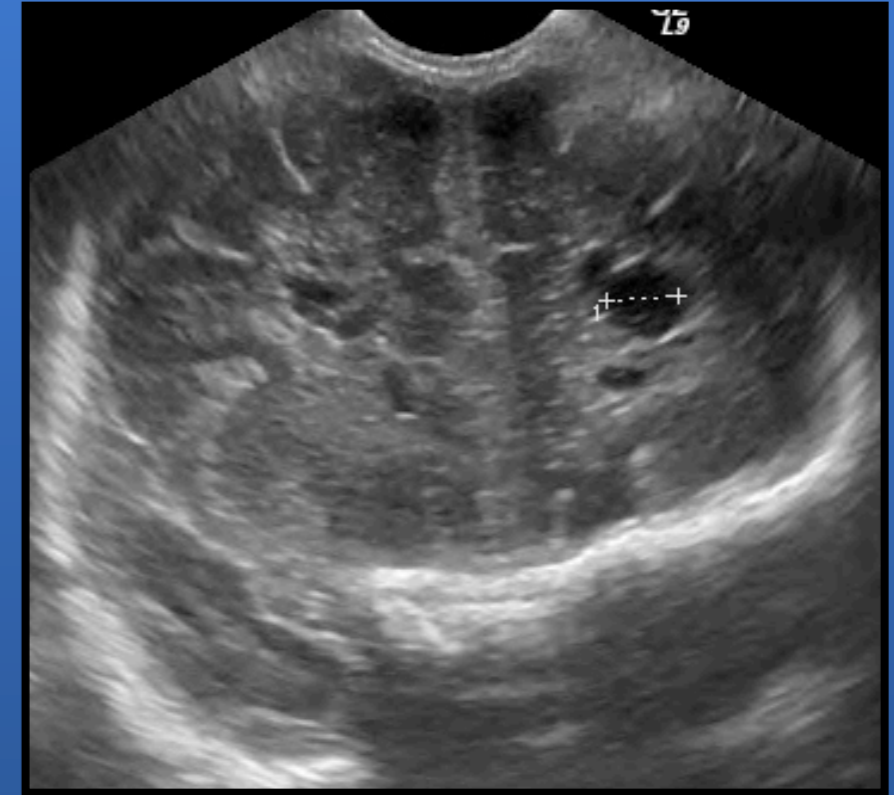
L.P.V. EVOLUTION

- 1^{ères} semaines :
 - persistance ou majoration
 - Petite zones hémorragiques
 - Hétérogénéité → cavitations



L.P.V EVOLUTION

- **A distance**
 - Normalisation
 - cicatrices gliales
 - « kyste » résiduel
 - petite dilatation ventriculaire adjacente atrophie



Hétérogénéité

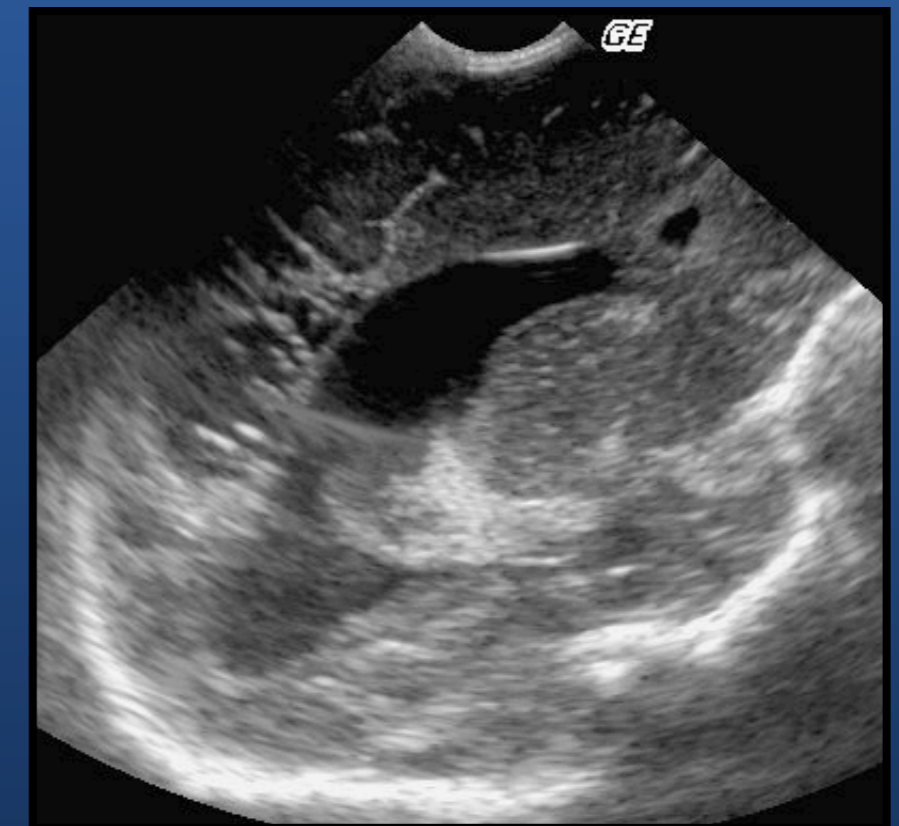
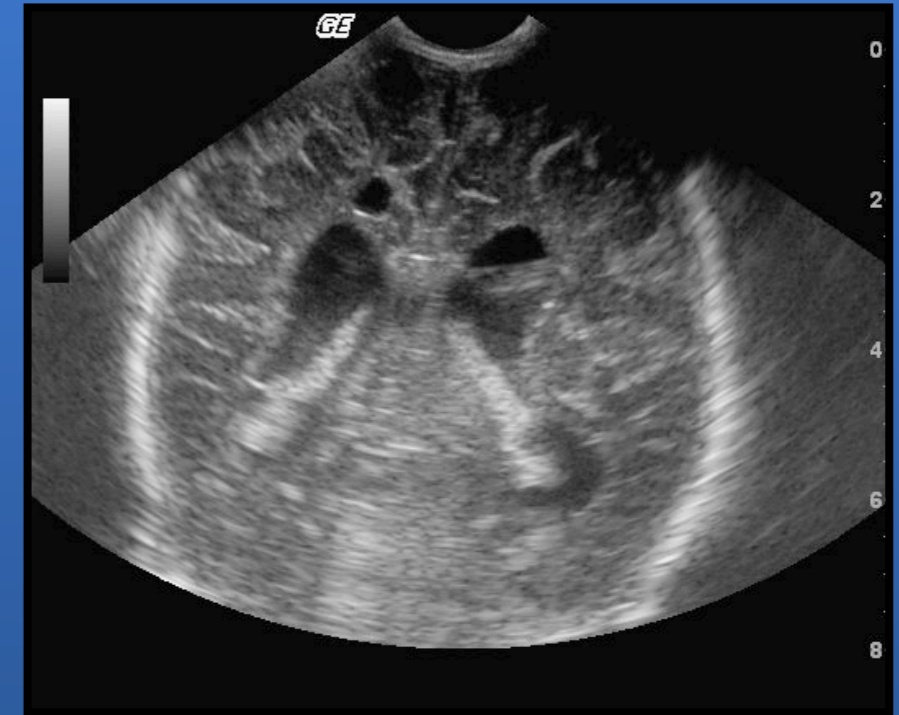
Cavitations

+/-confluentes

+/- communquant avec les ventricules

L.P.V EVOLUTION

- **A distance**
 - Normalisation
 - cicatrices gliales
 - « kyste » résiduel
 - petite dilatation ventriculaire adjacente atrophie



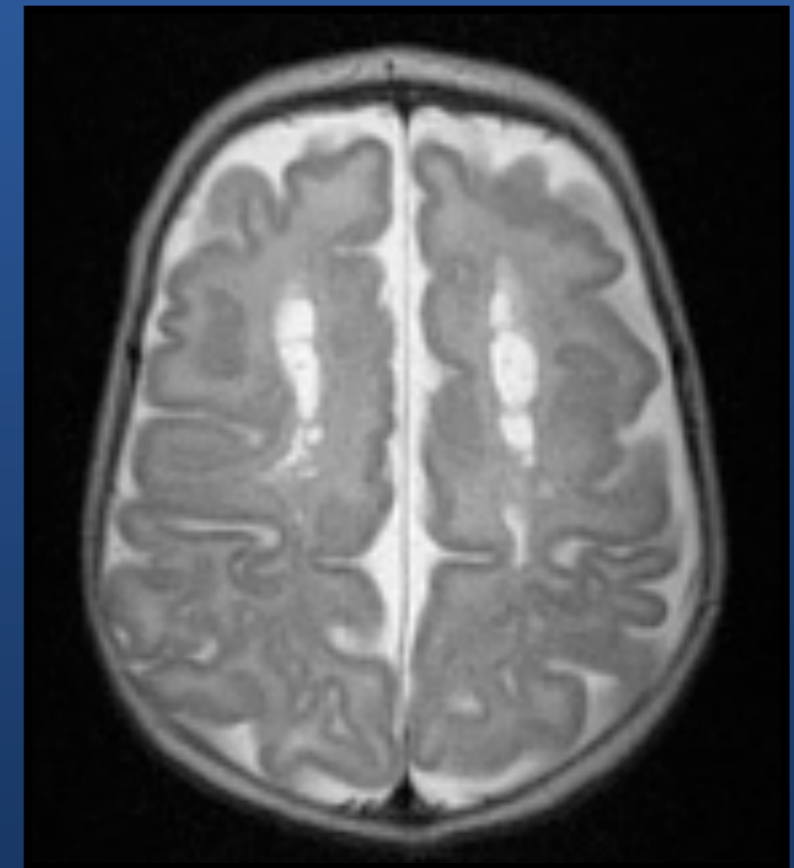
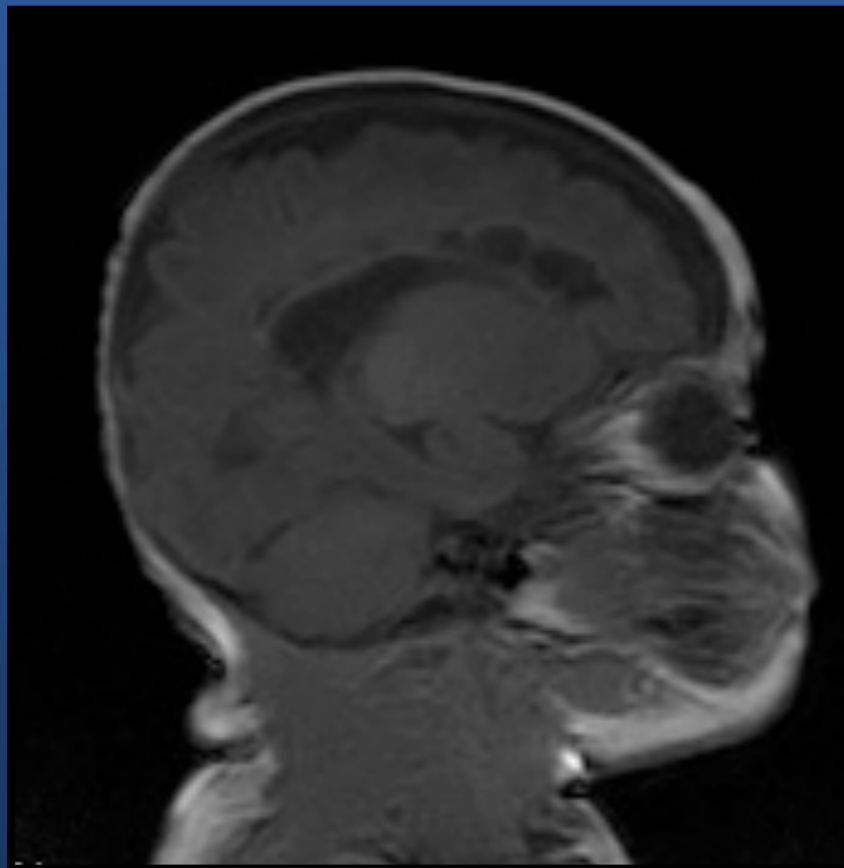
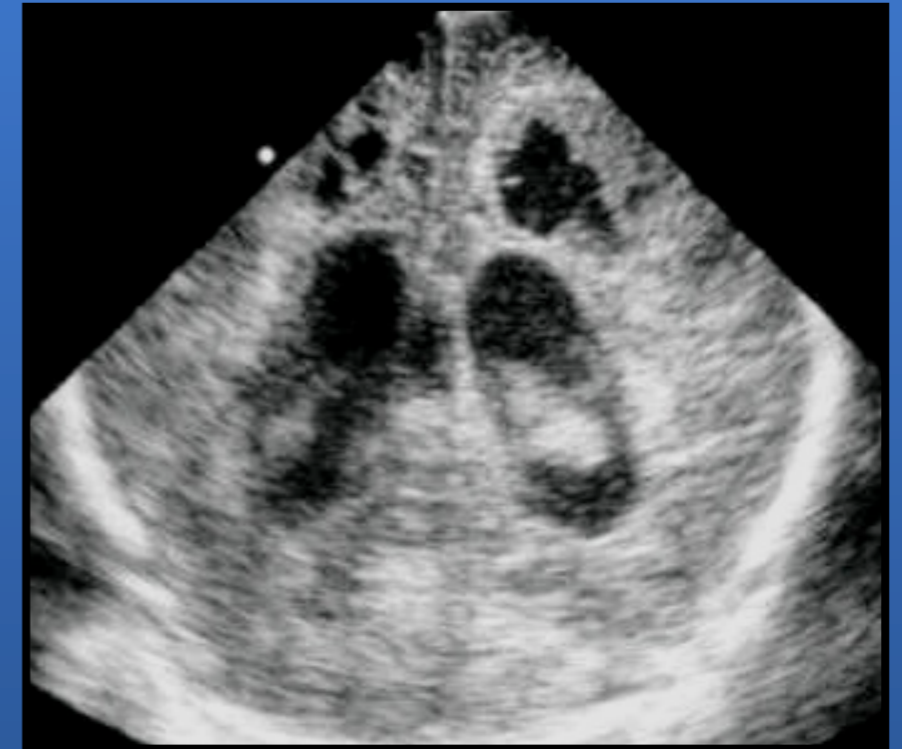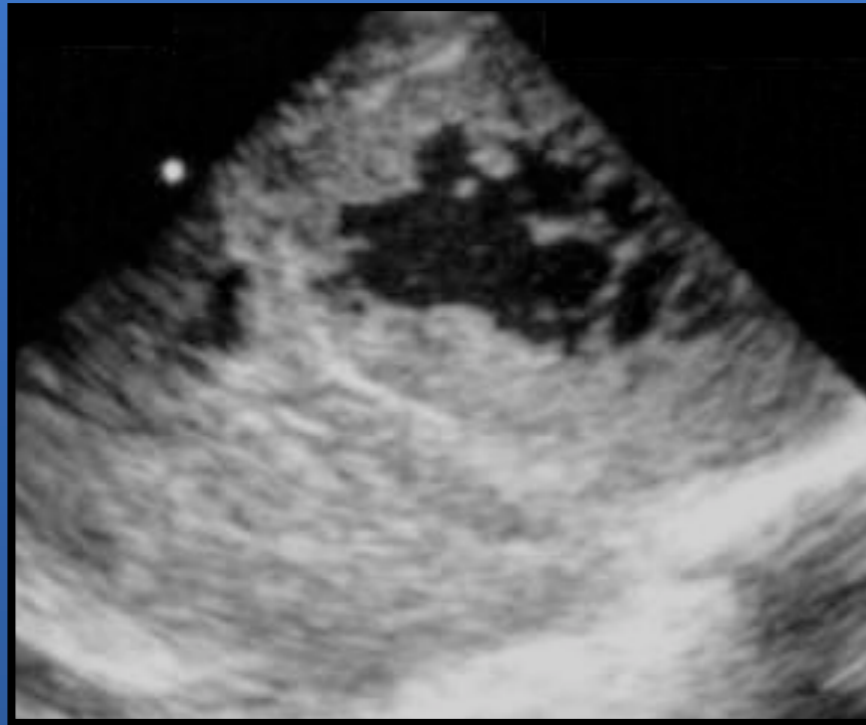Hétérogénéité

Cavitations

+/- confluentes

+/- communiquantes avec les ventricules

L.P.V EVOLUTION



Encéphalopathie anoxo-ischémique du nouveau né à terme

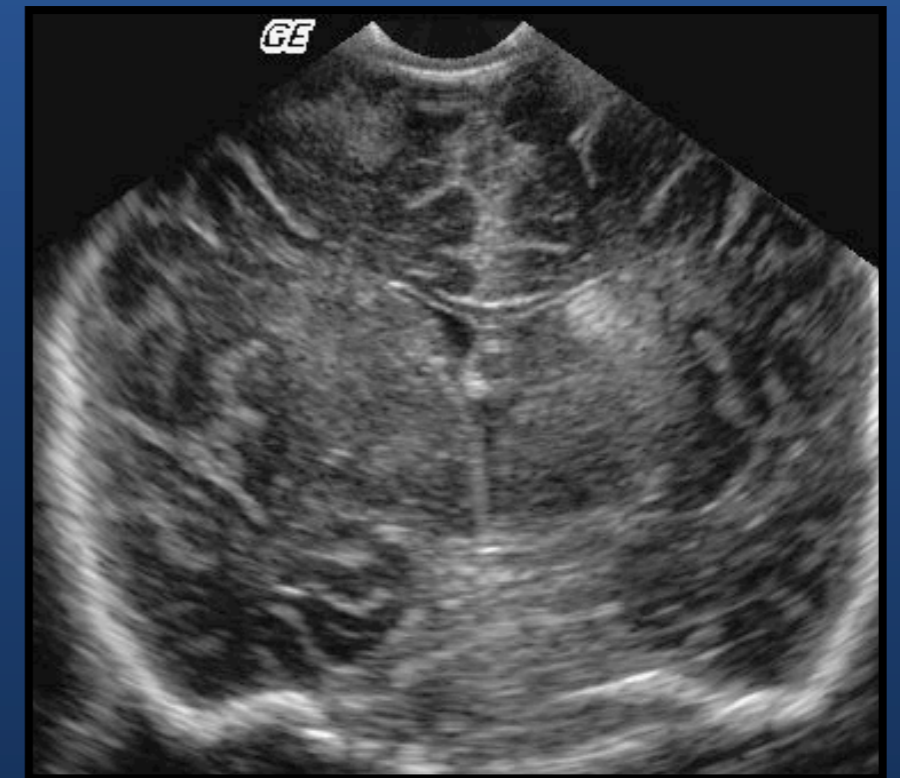
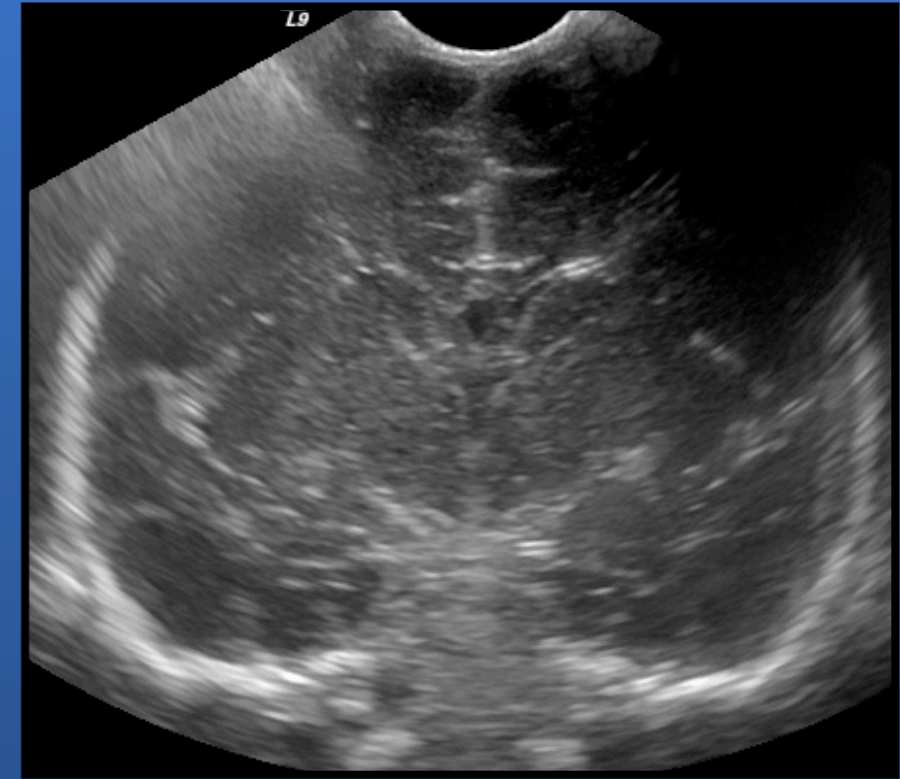
Asphyxie néonatale

Peu de signes échographiques

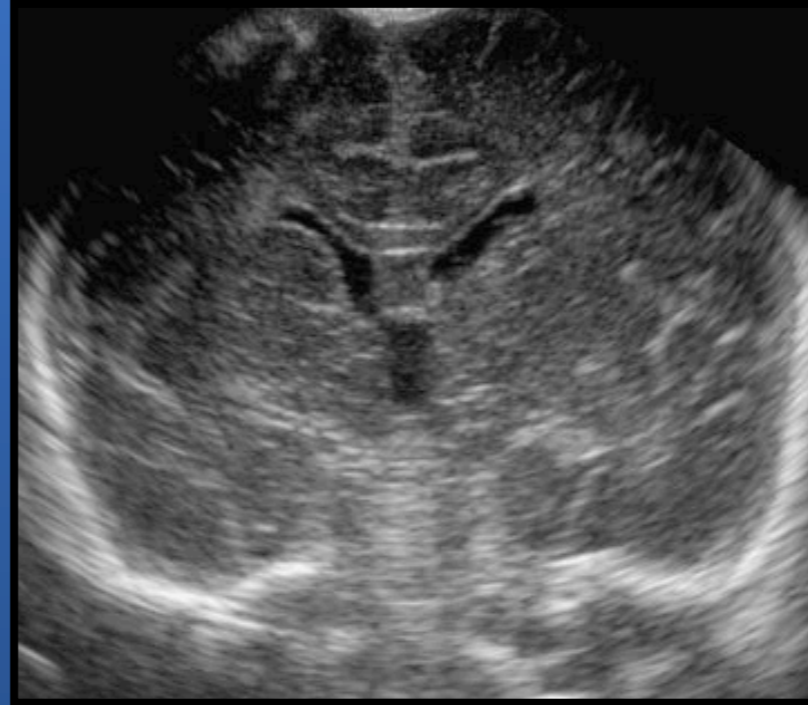
**Sauf sévère : images en patchwork
hyperéchogènes**

Surveillance de l'atrophie

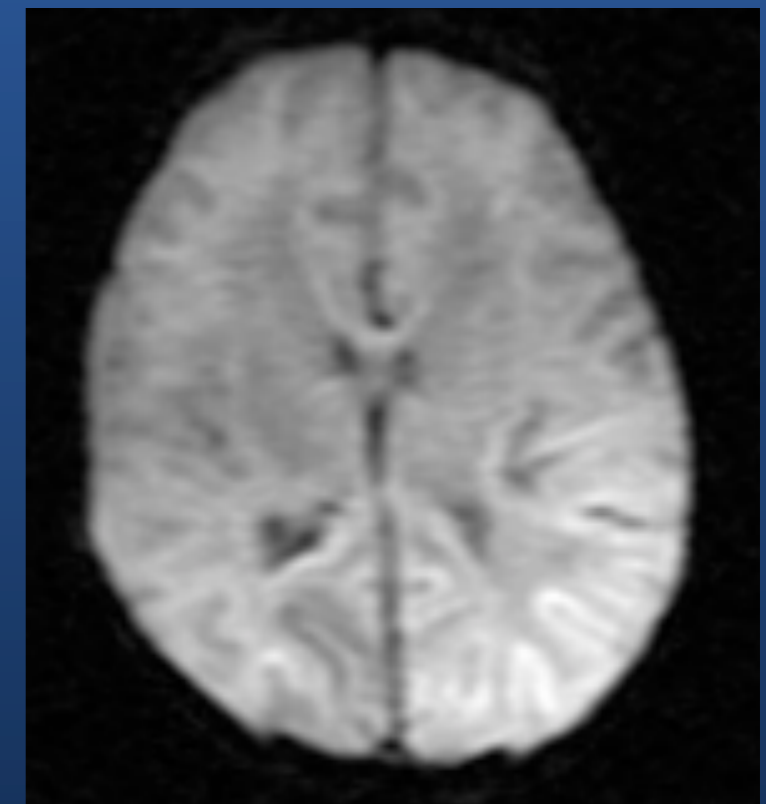
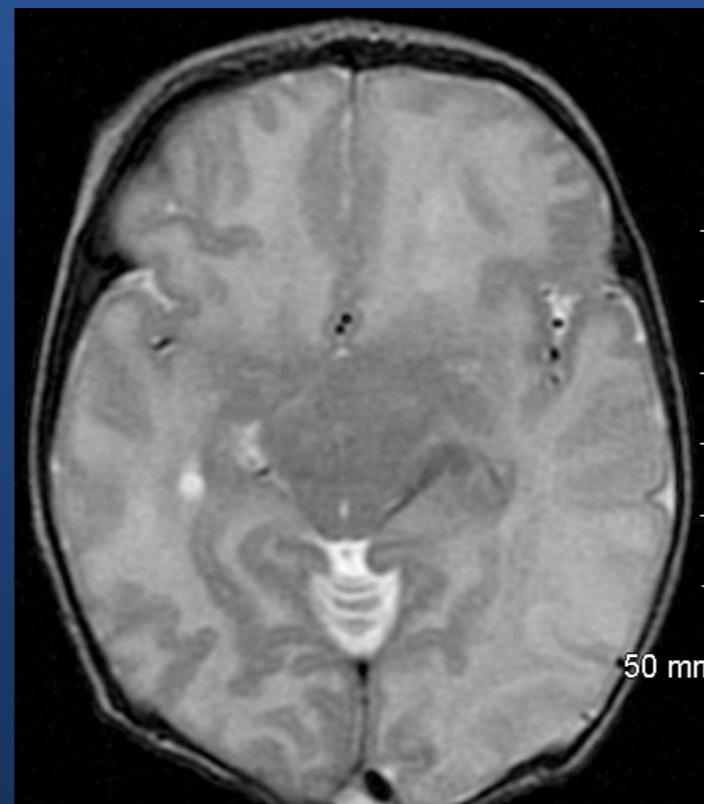
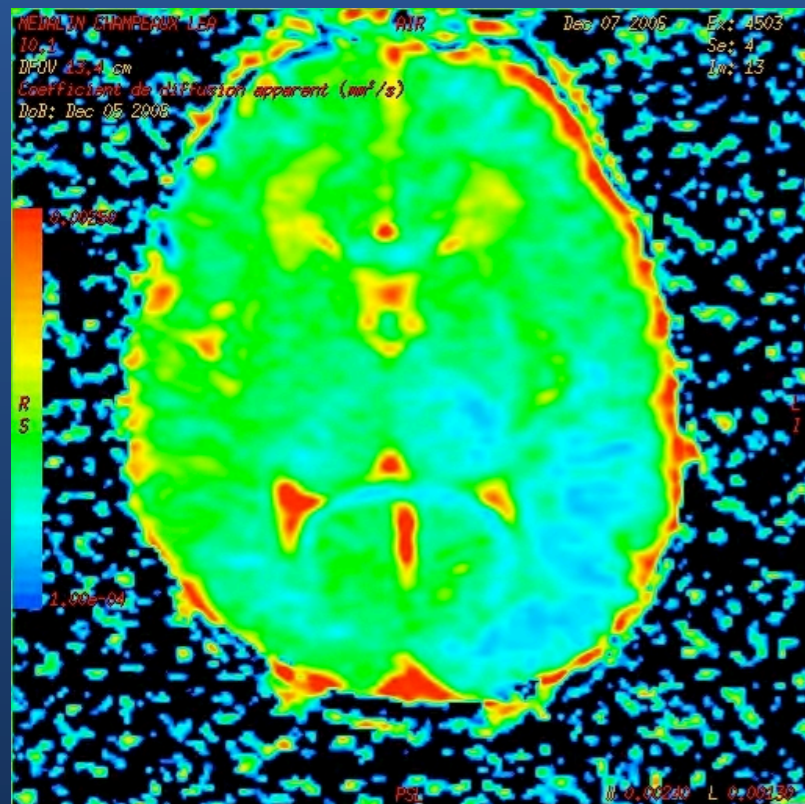
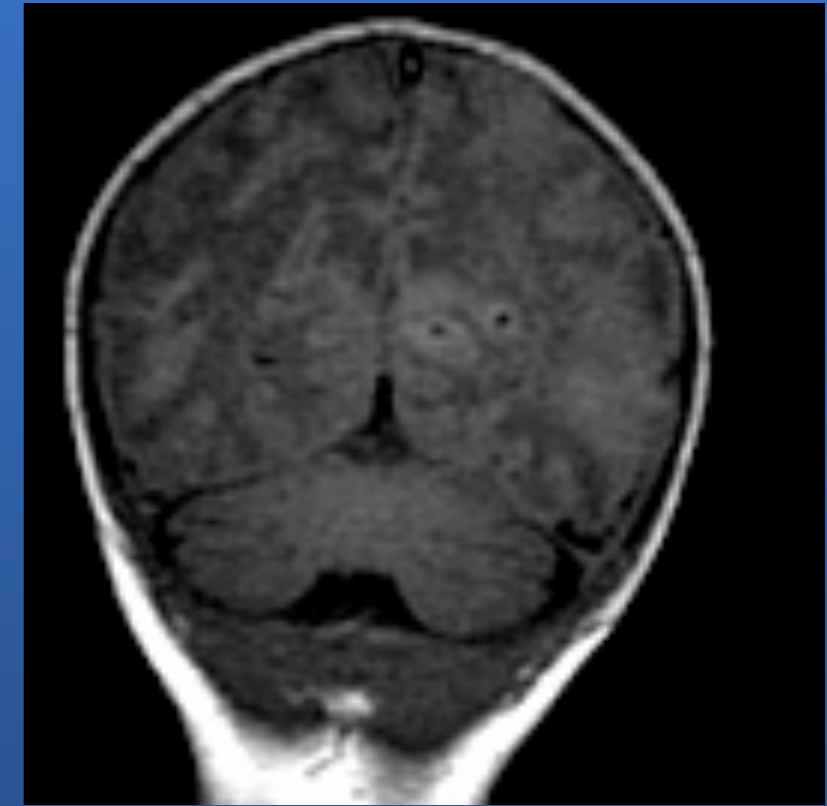
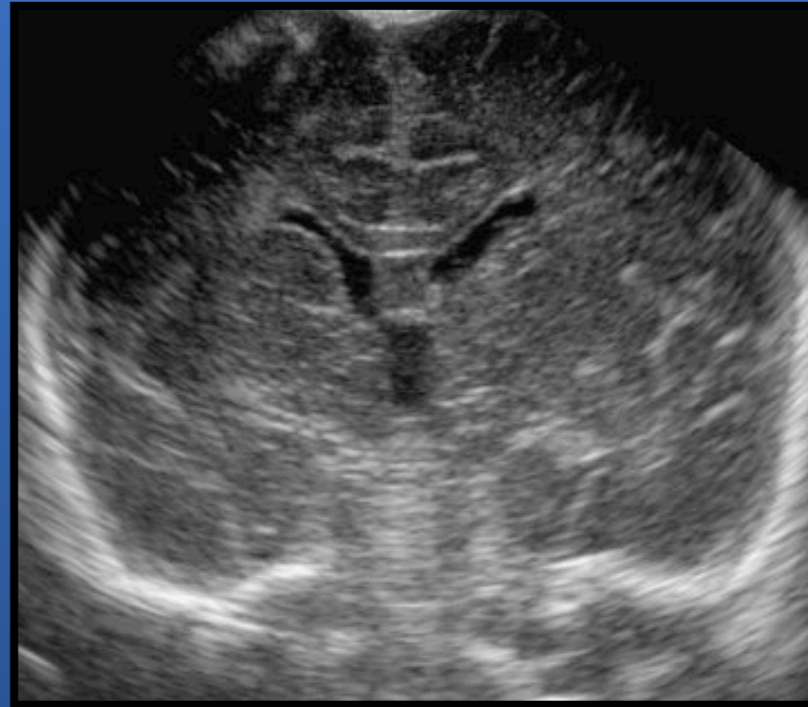
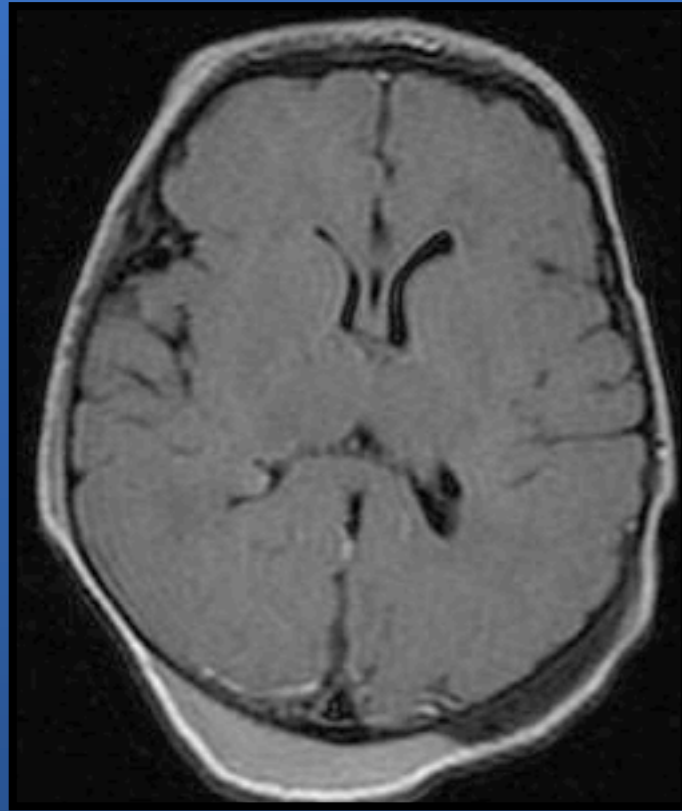
IRM +++



- **E.T.F le plus souvent normale**
- **I.R.M +++ diffusion**



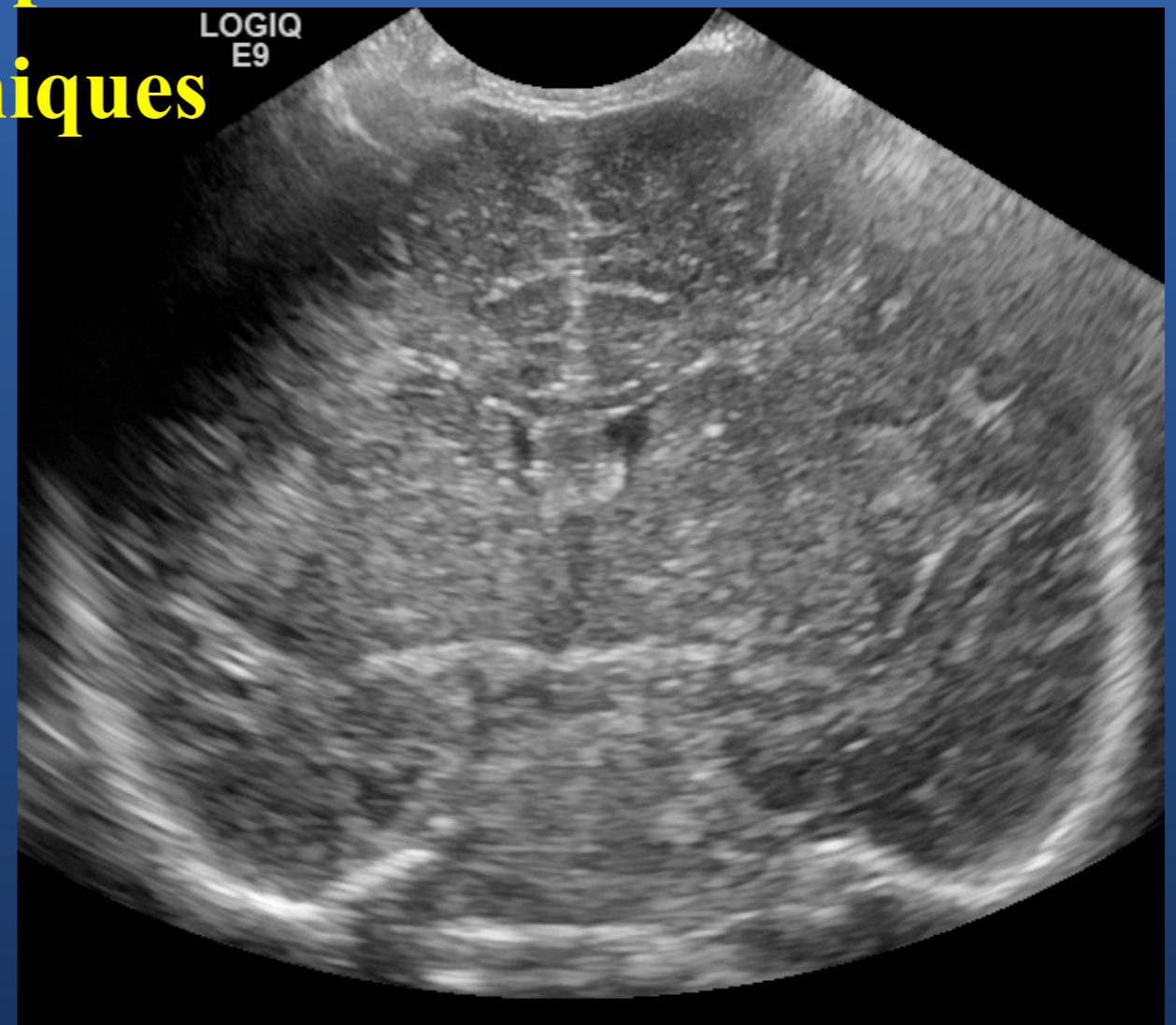
- E.T.F le plus souvent normale
- I.R.M +++ diffusion

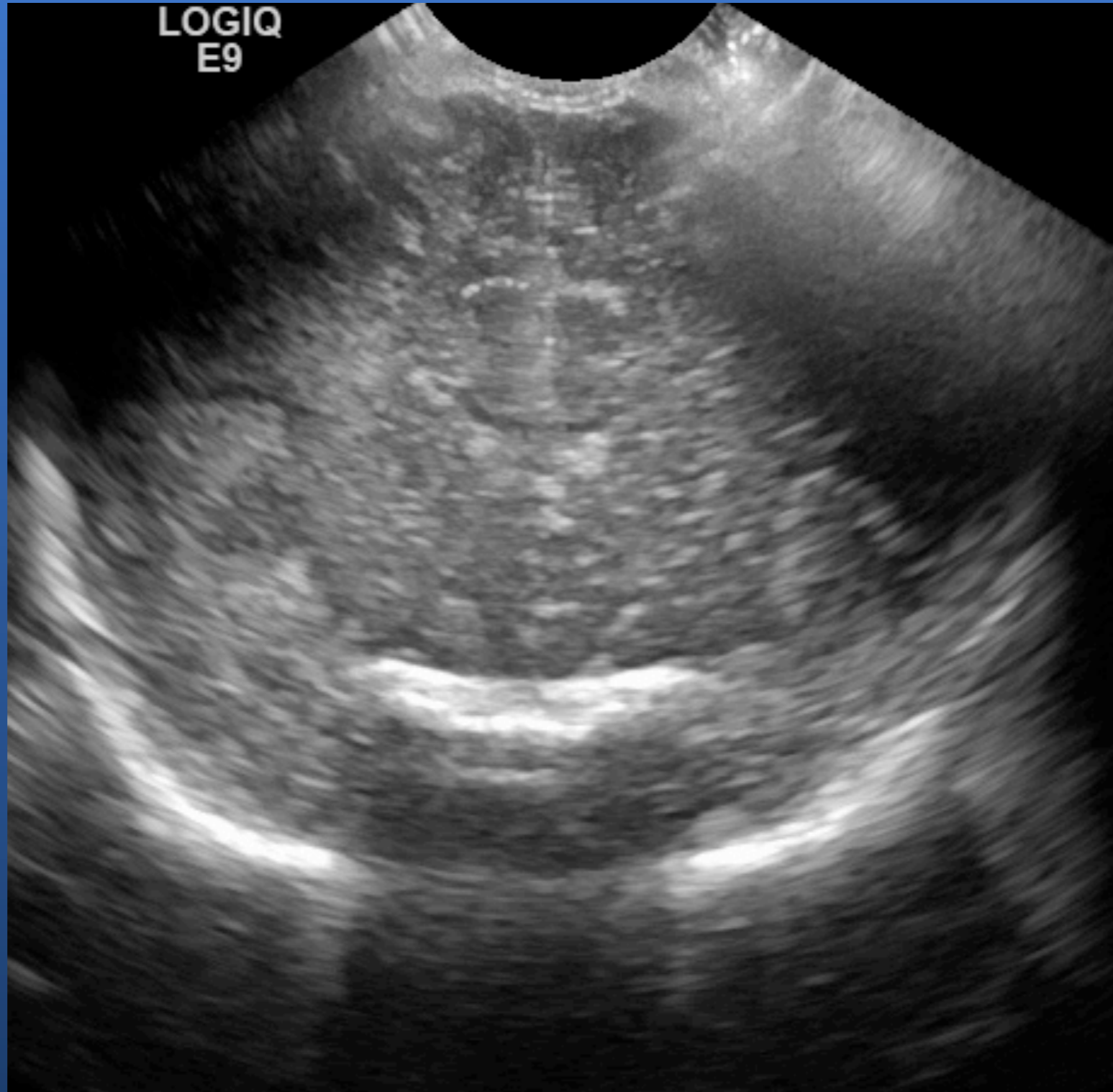


INFARCTUS ISCHEMIQUE

du N. né à terme

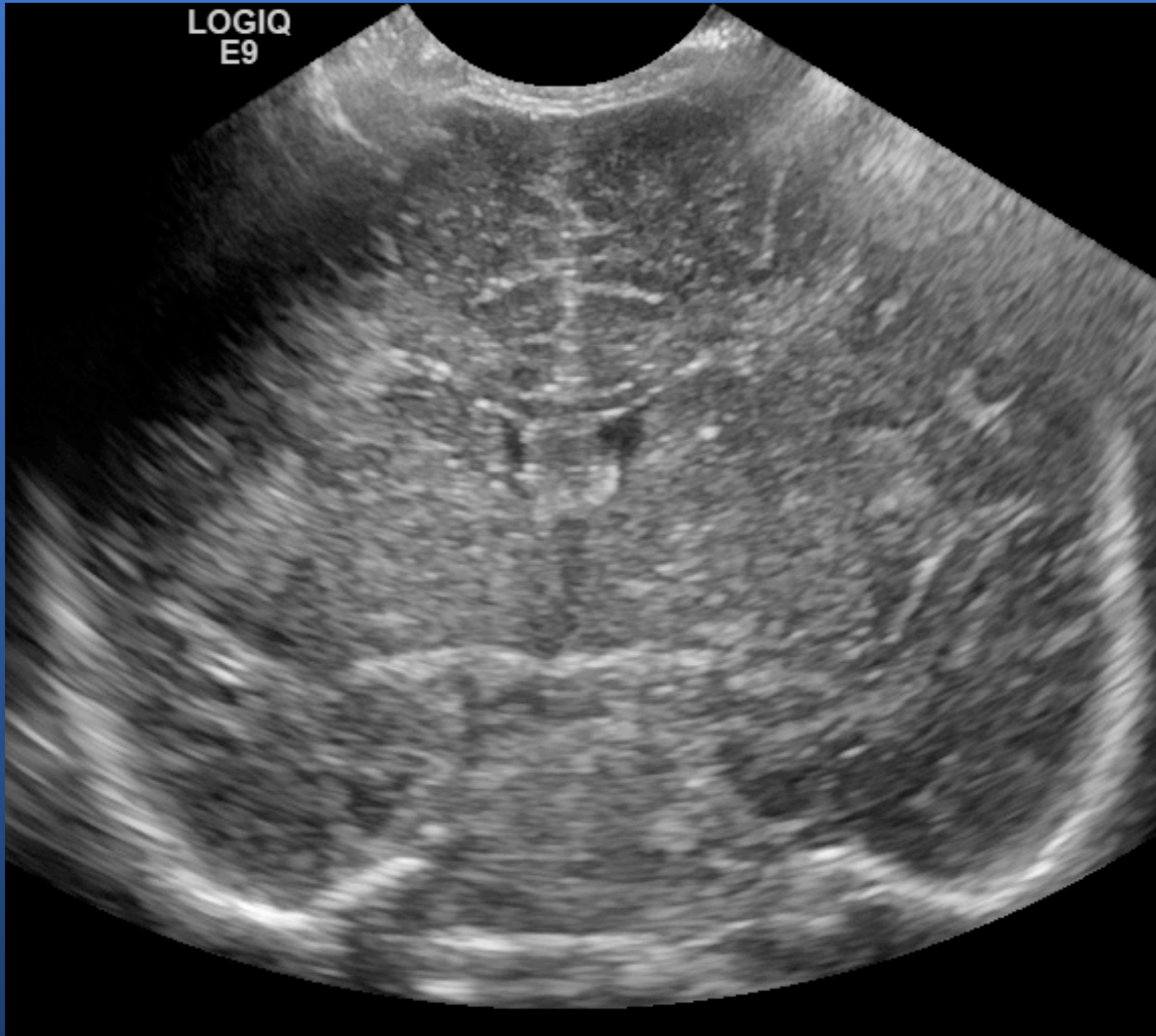
- **Convulsions, déficit moteur**
- **Facteurs favorisants**
 - **Détresse perinatale, polyglobulie, infection, cardiopathie**
- **Pauvreté des signes échographiques**
 - **Phase de début**
 - **Hyperéchogénicité**
 - **Cortico-souscorticale**
- **Recours à la TDM ou l'IRM**





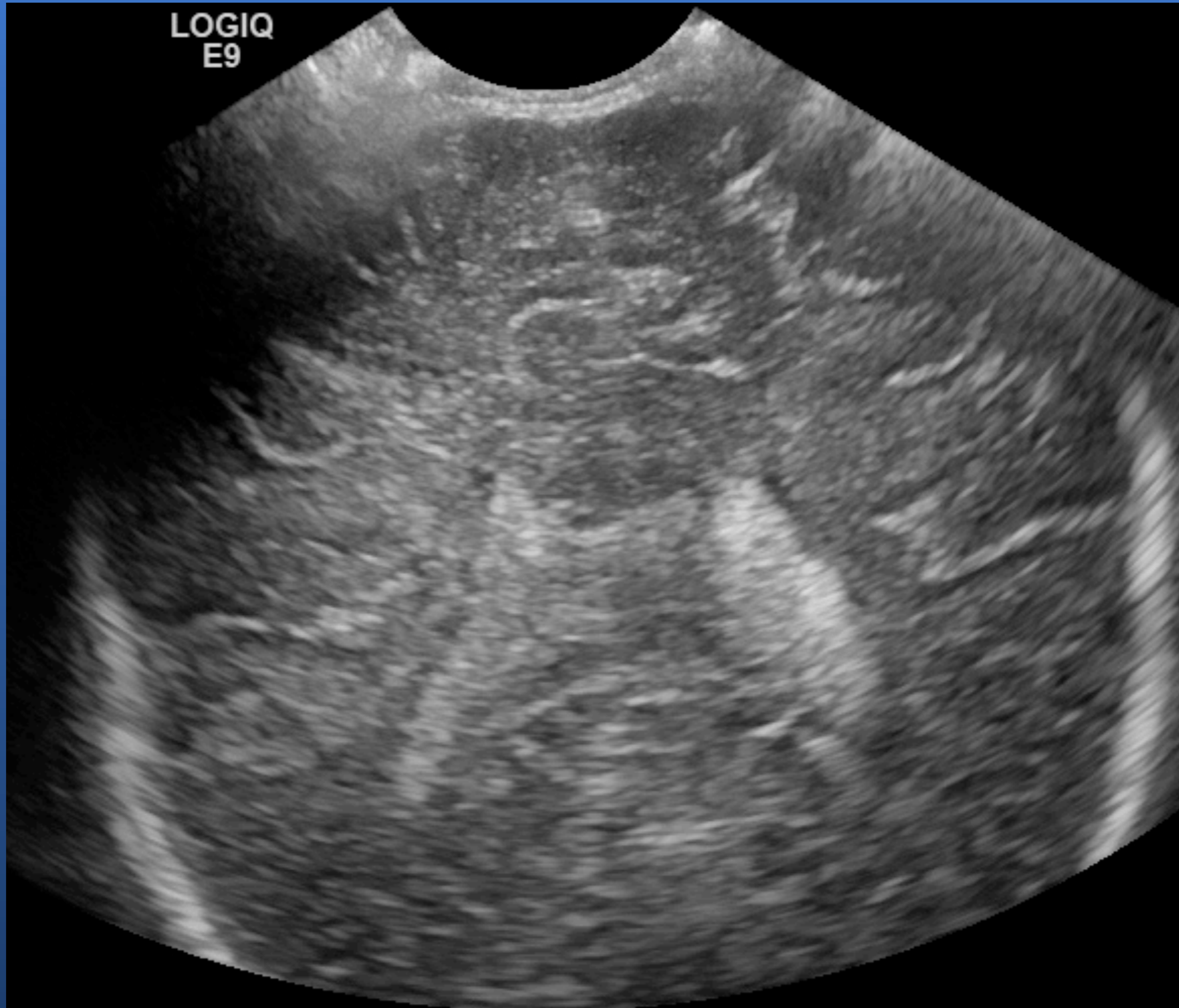
CONVULSIONS CHEZ UN NOUVEAU NE

78



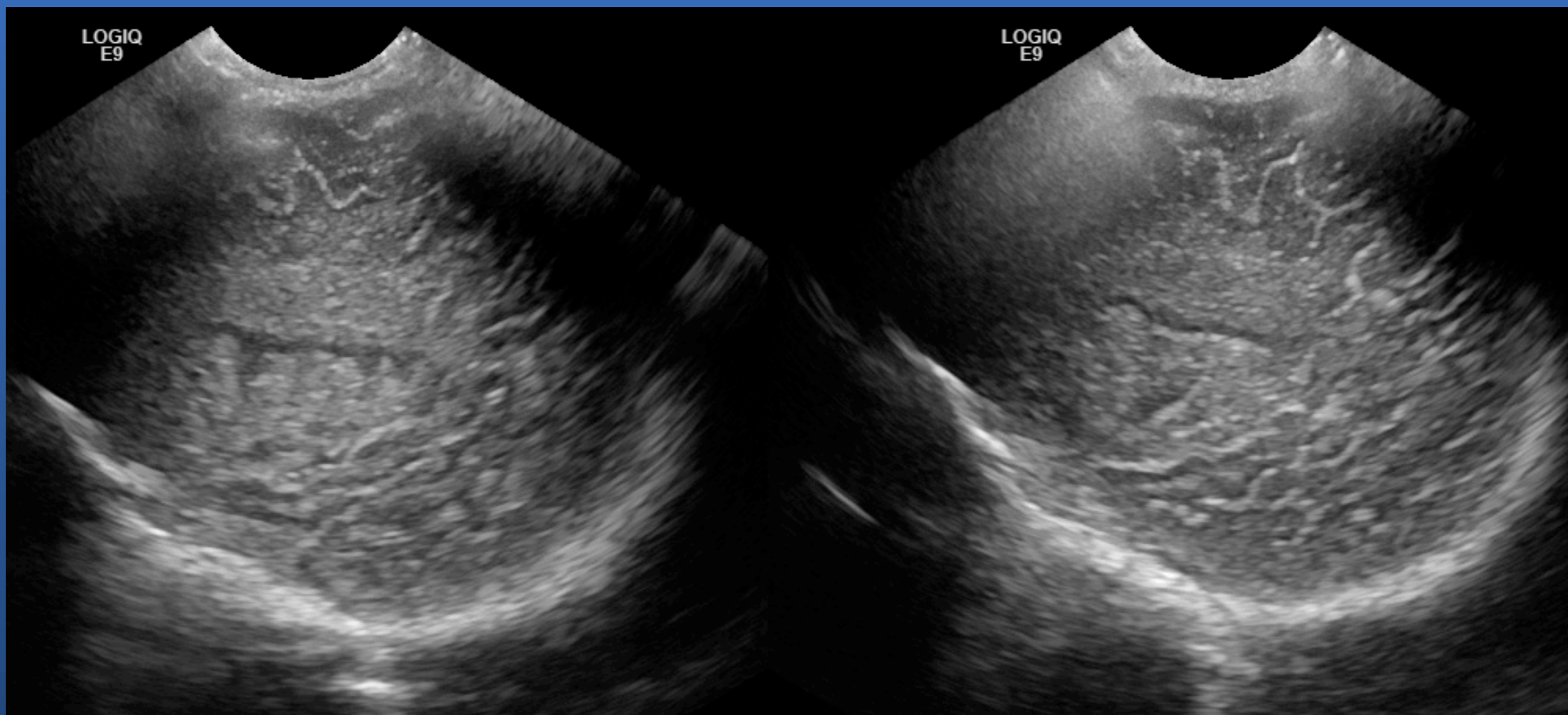
CONVULSIONS CHEZ UN NOUVEAU NE

78

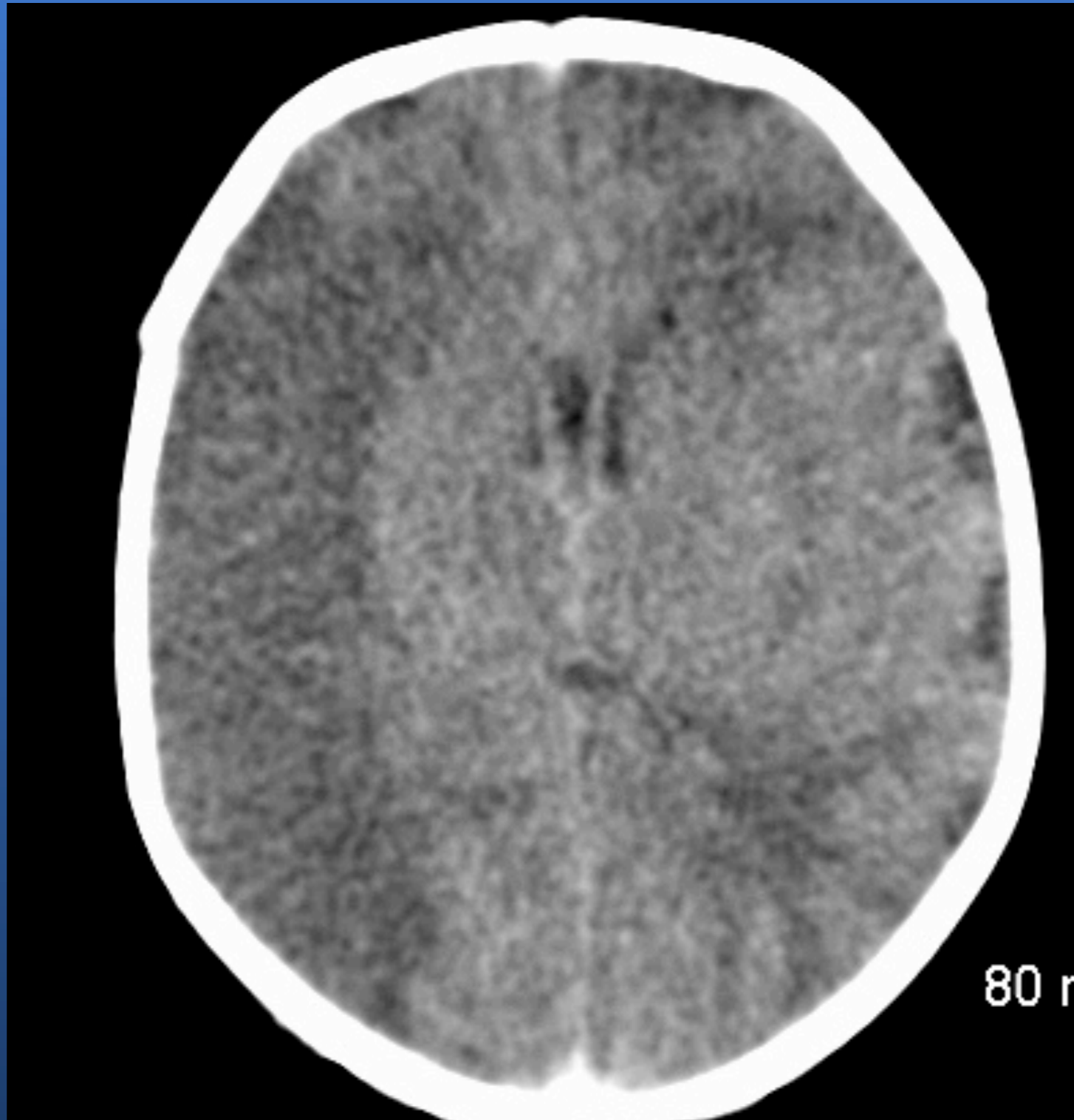


CONVULSIONS CHEZ UN NOUVEAU NE

78

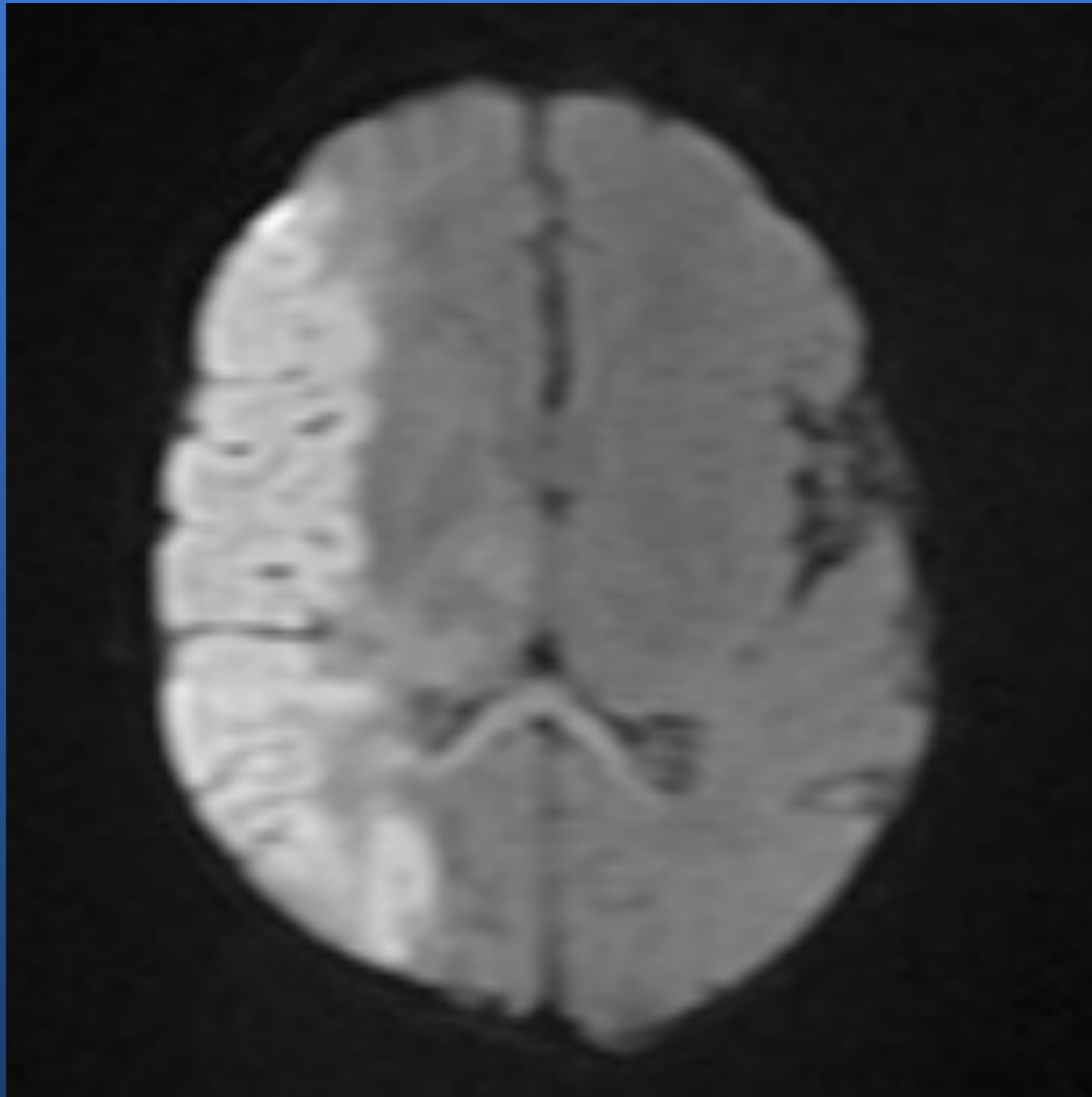


CONVULSIONS CHEZ UN NOUVEAU NE 78



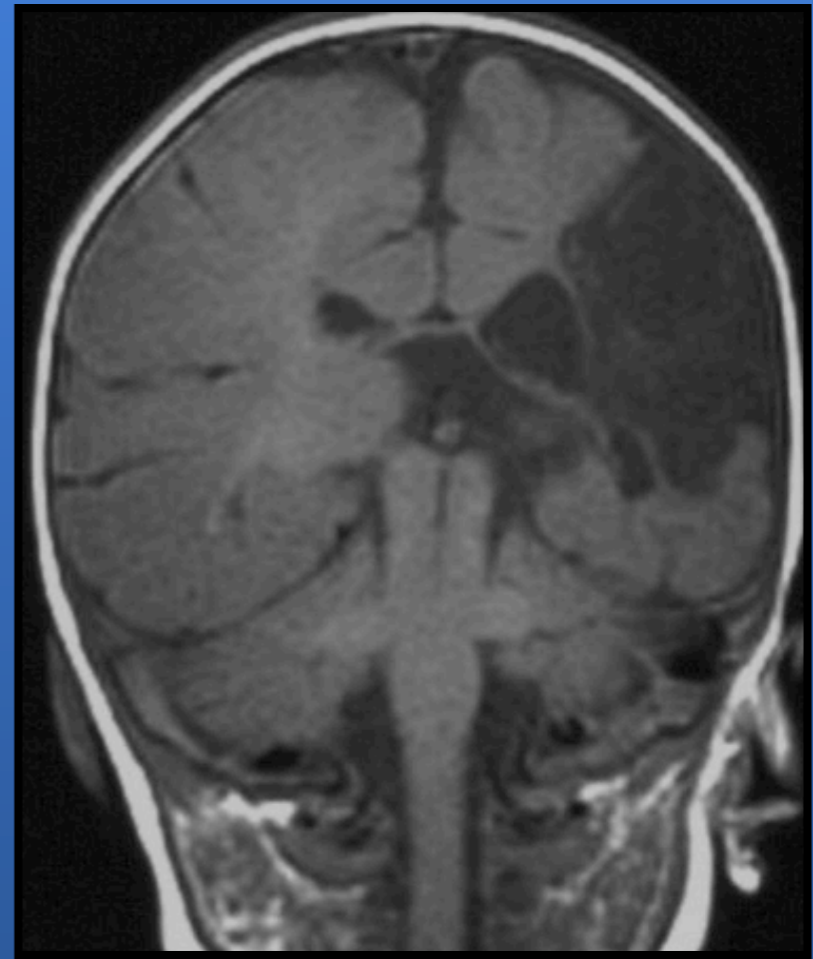
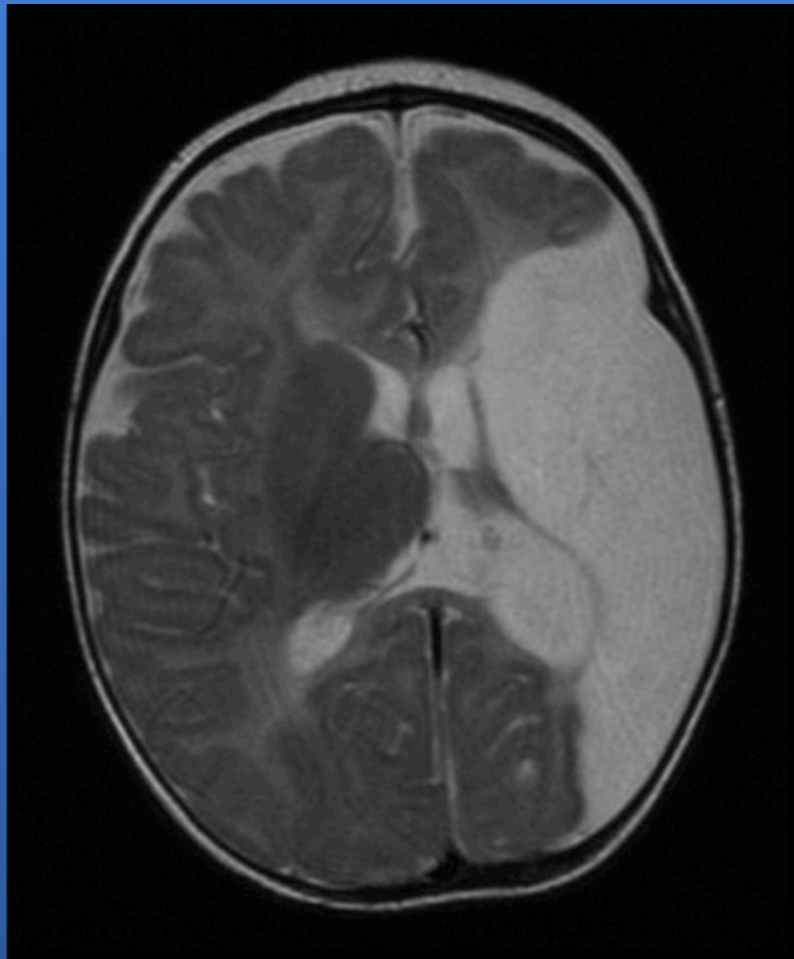
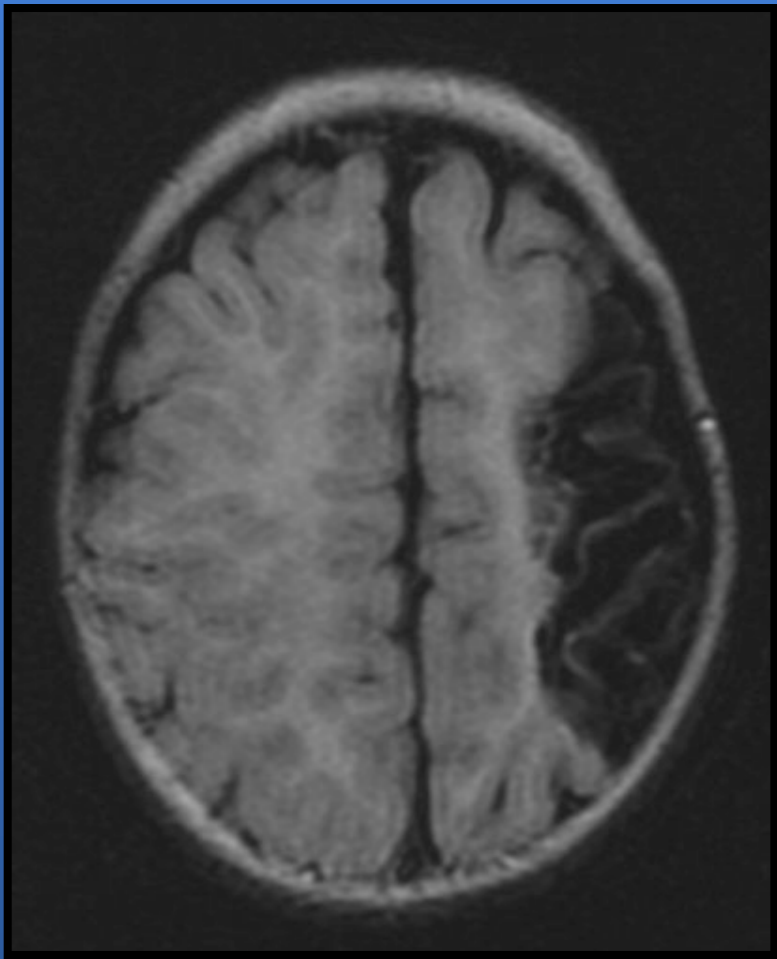
CONVULSIONS CHEZ UN NOUVEAU NE

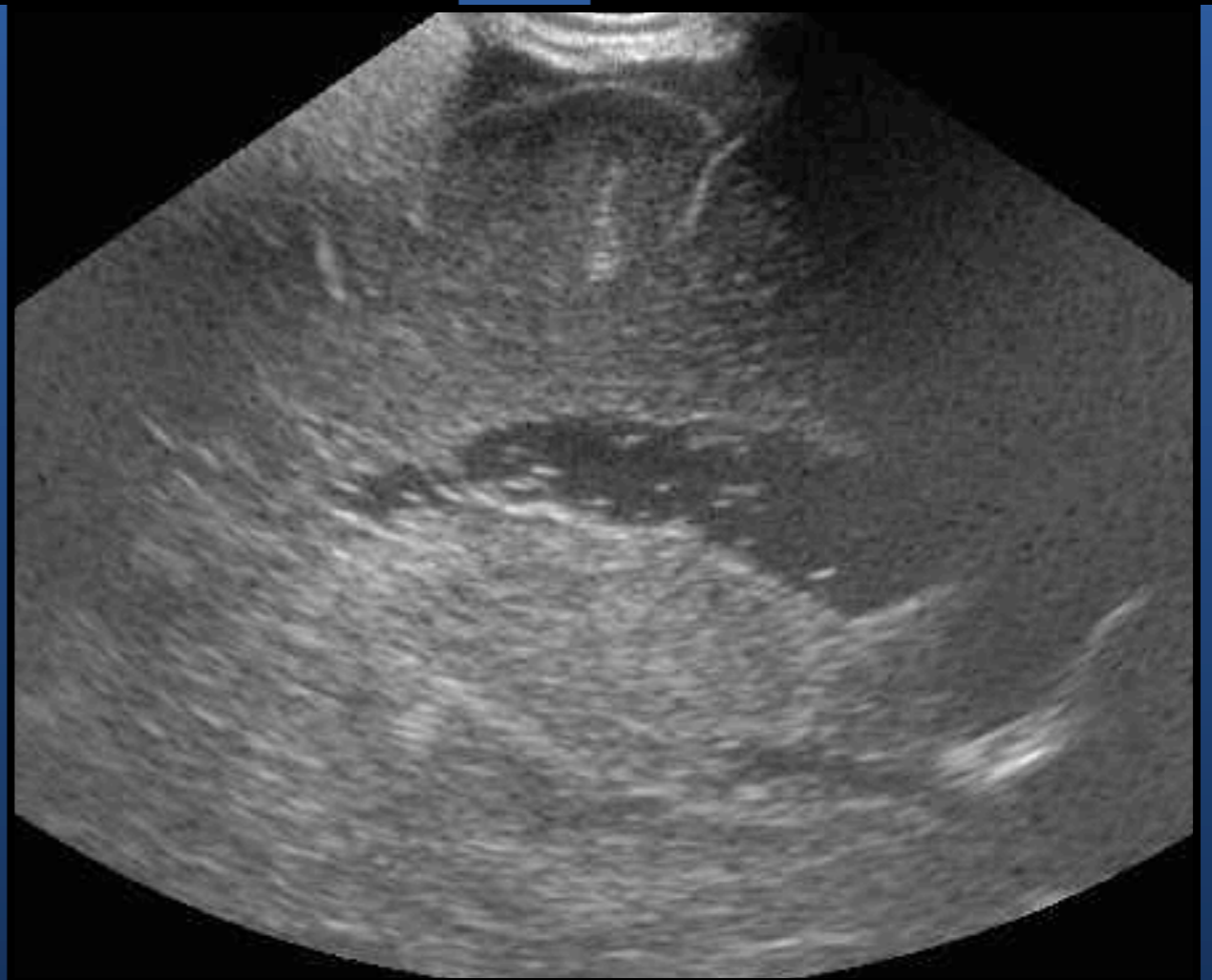
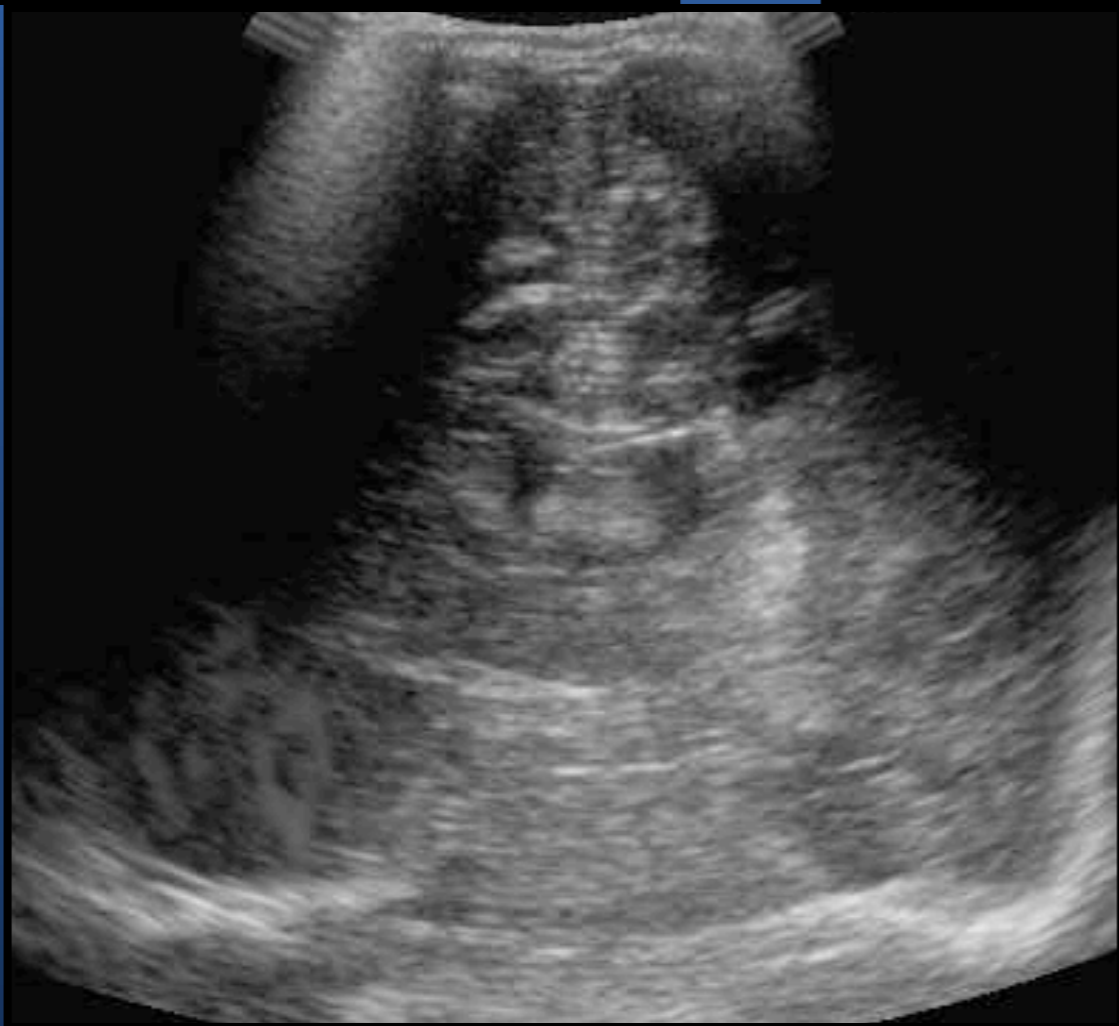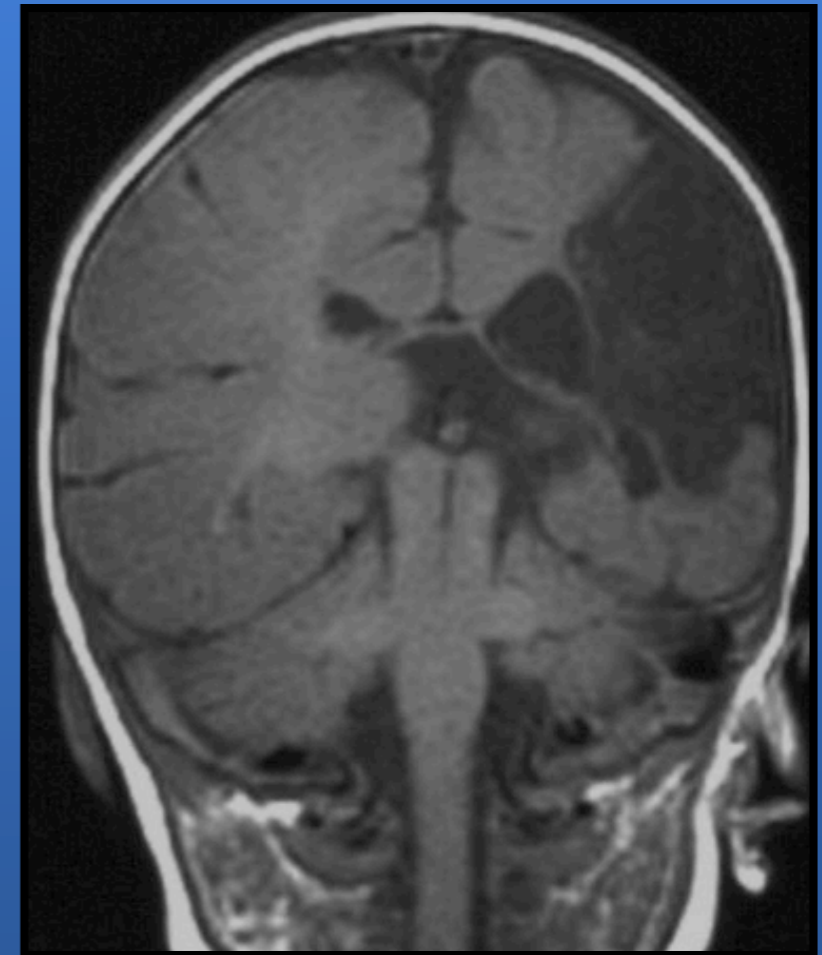
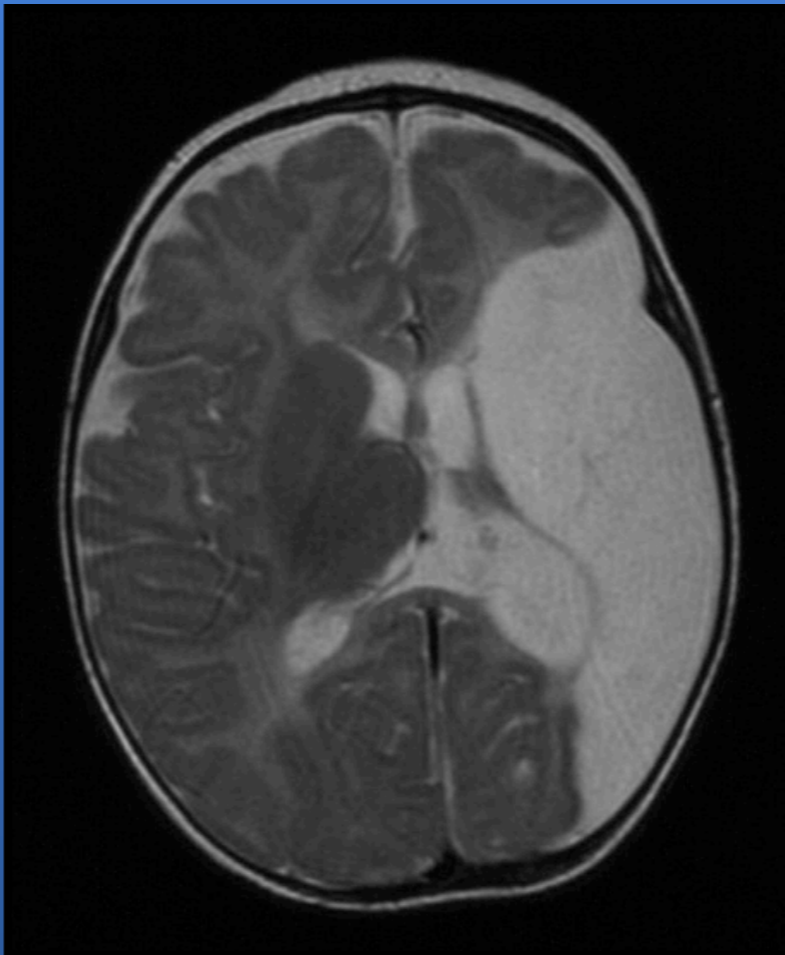
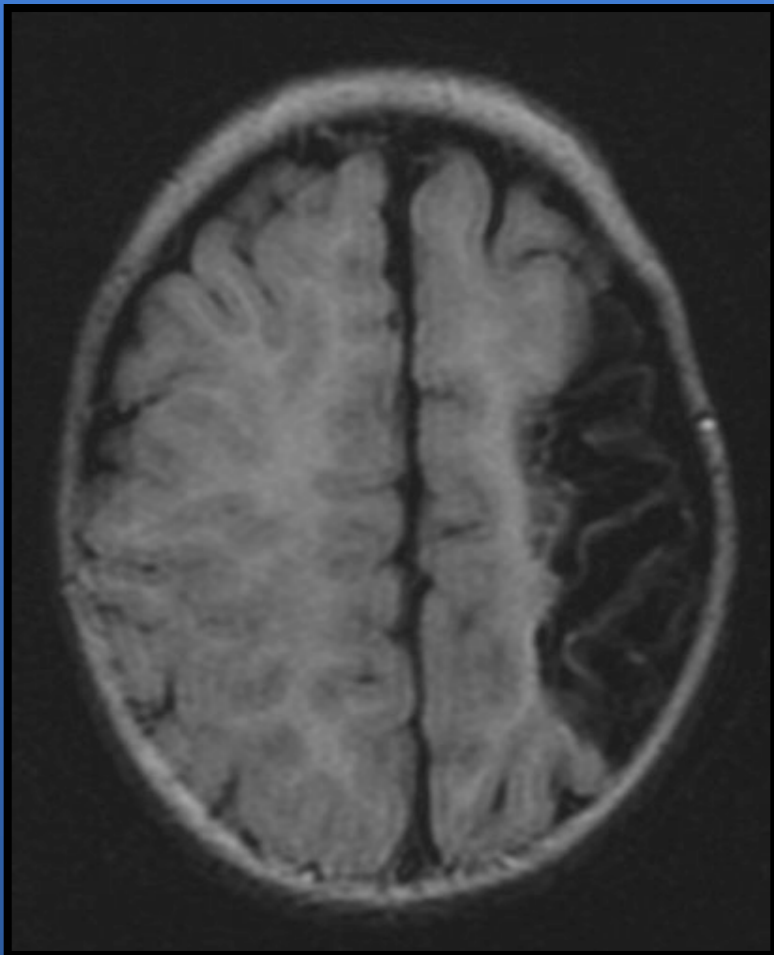
78

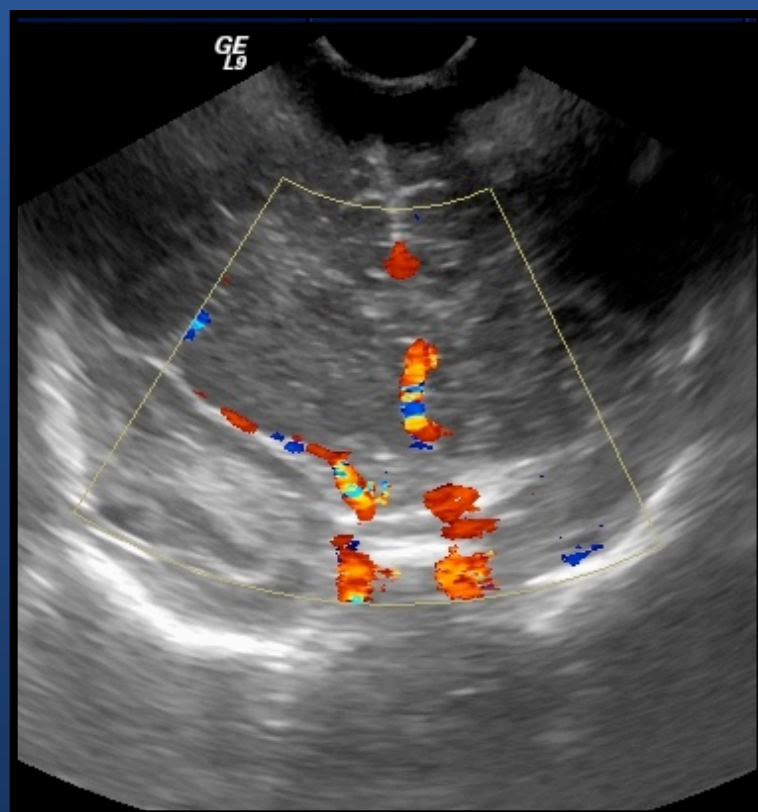
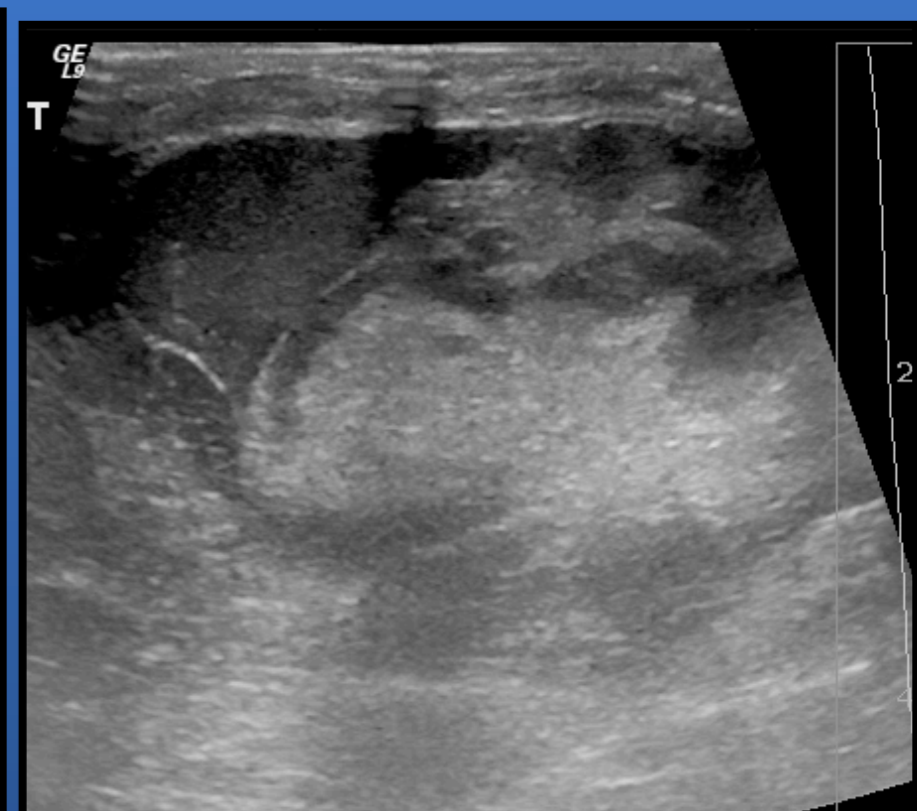
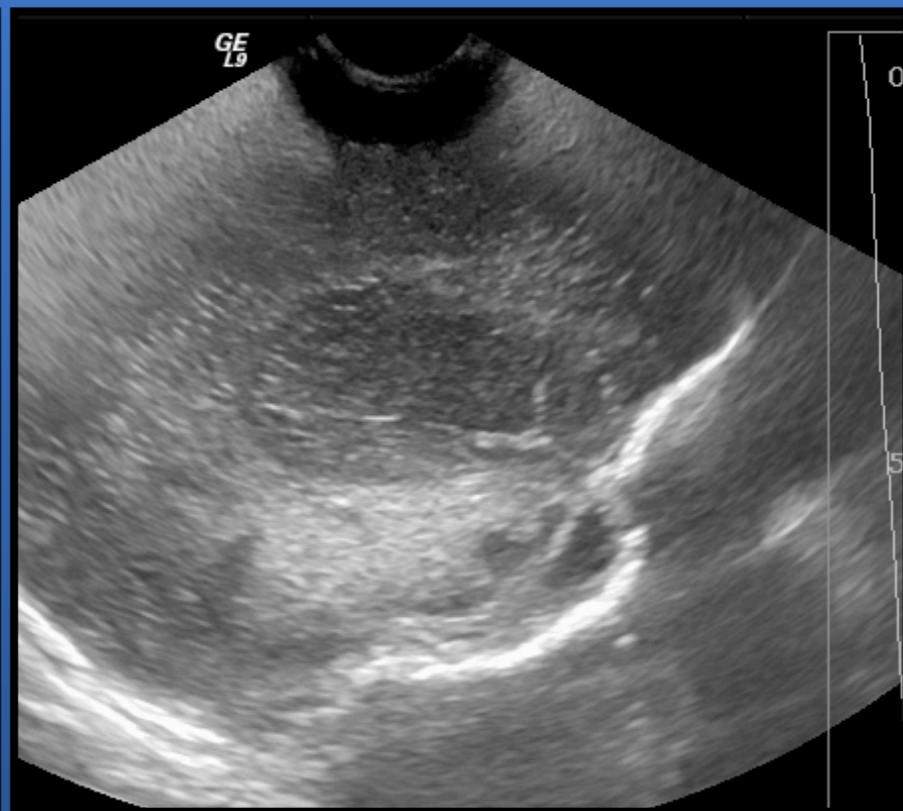
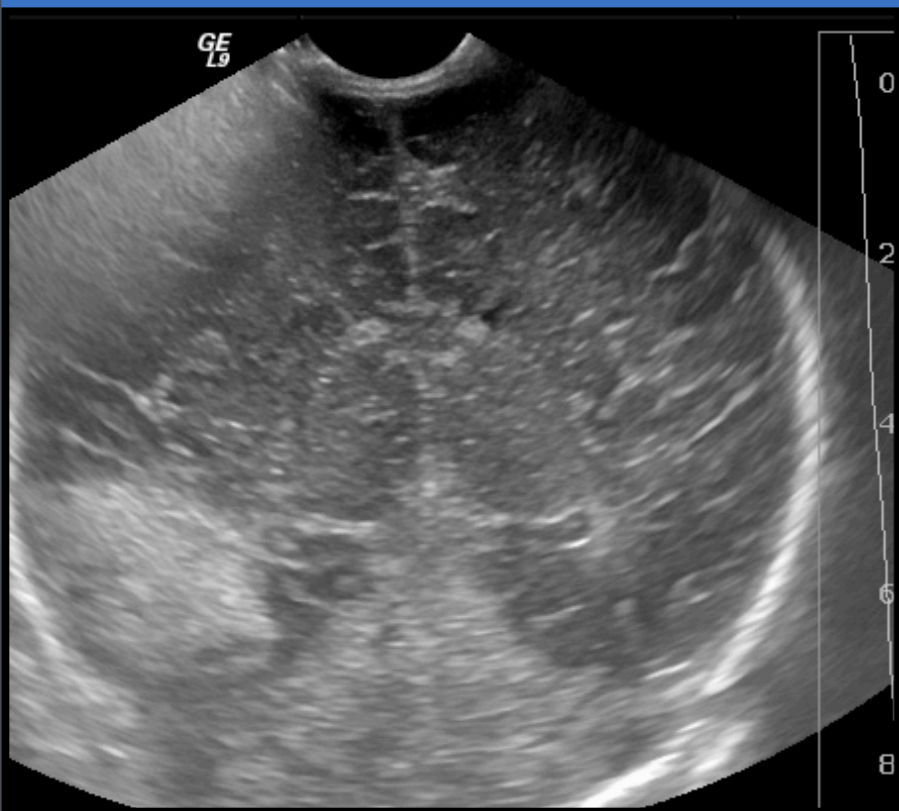


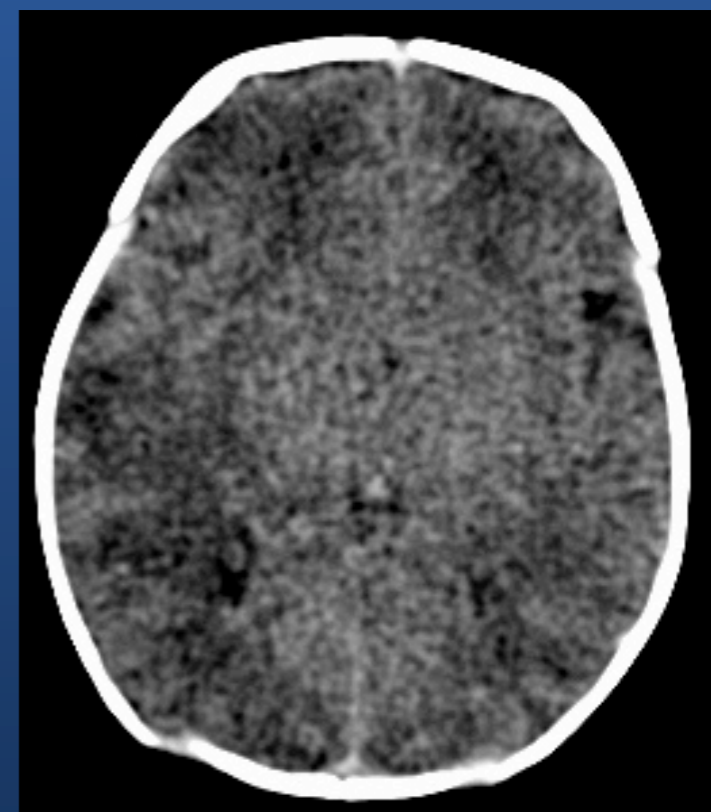
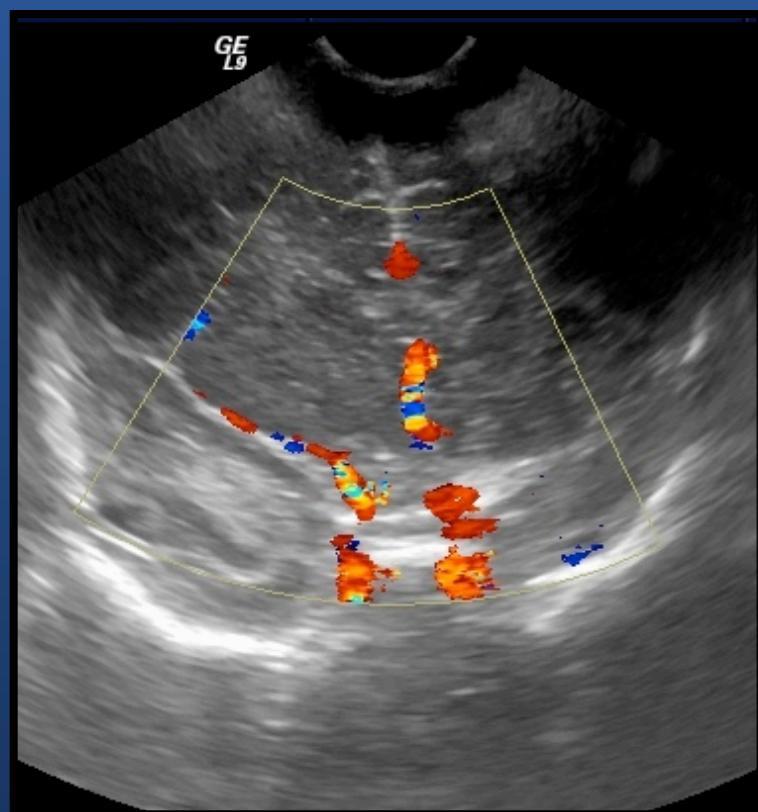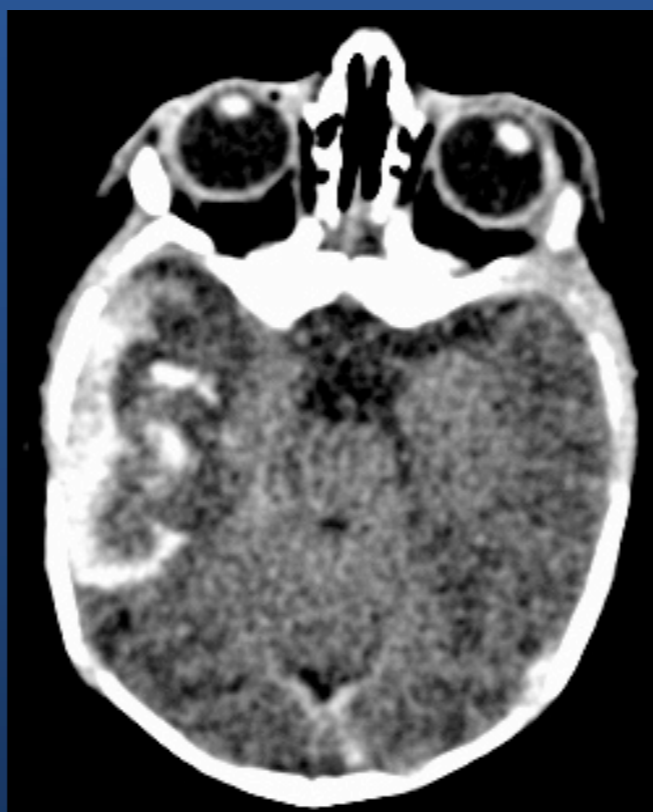
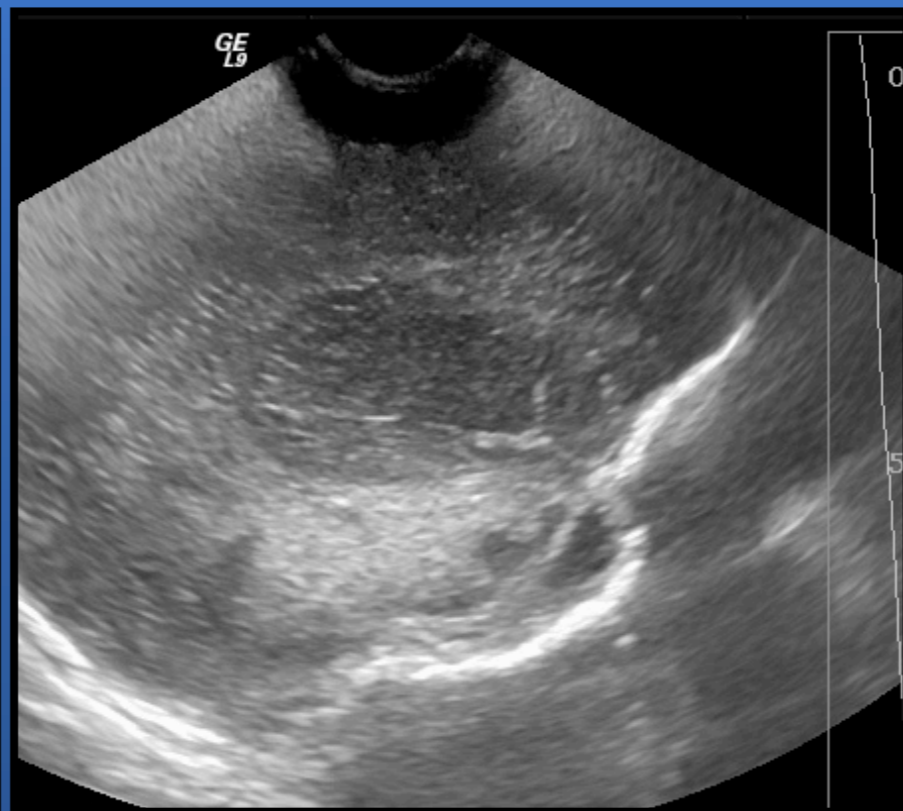
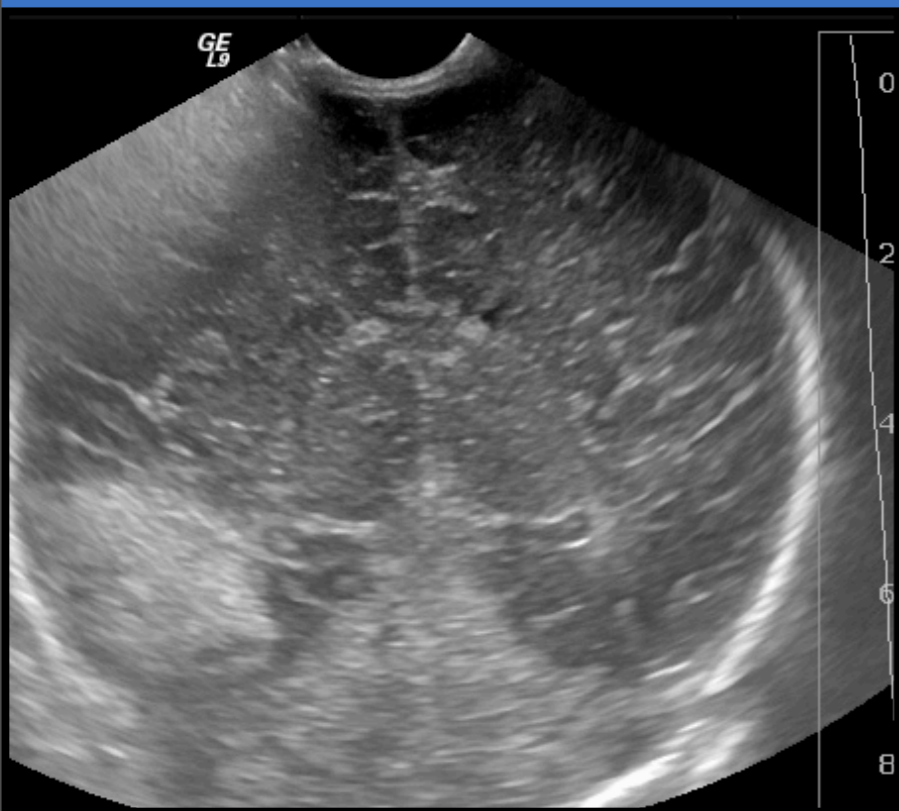
CONVULSIONS CHEZ UN NOUVEAU NE

78

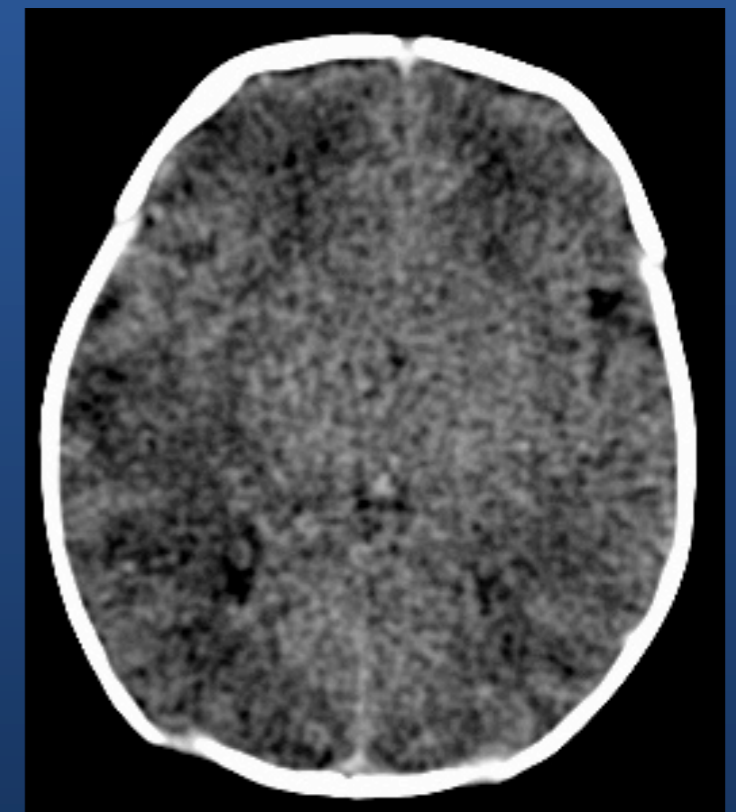
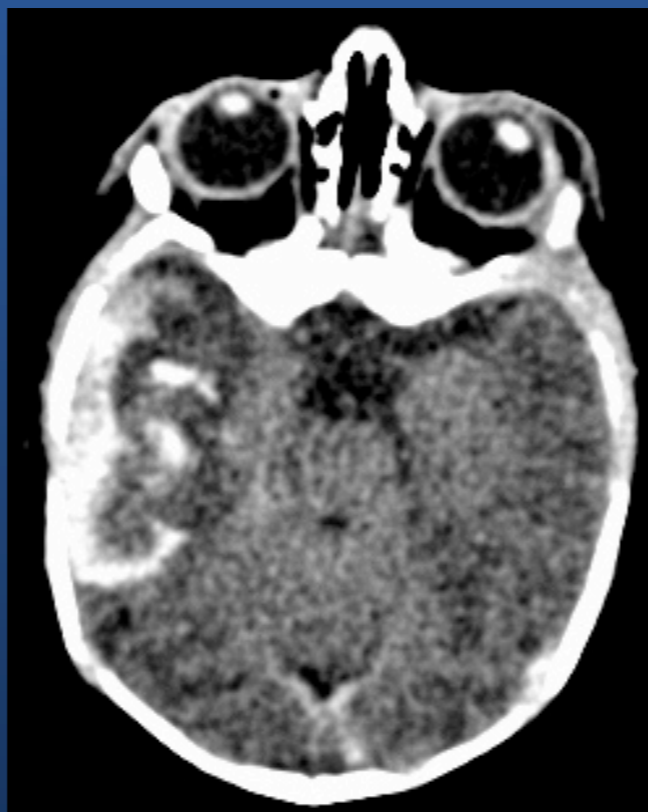
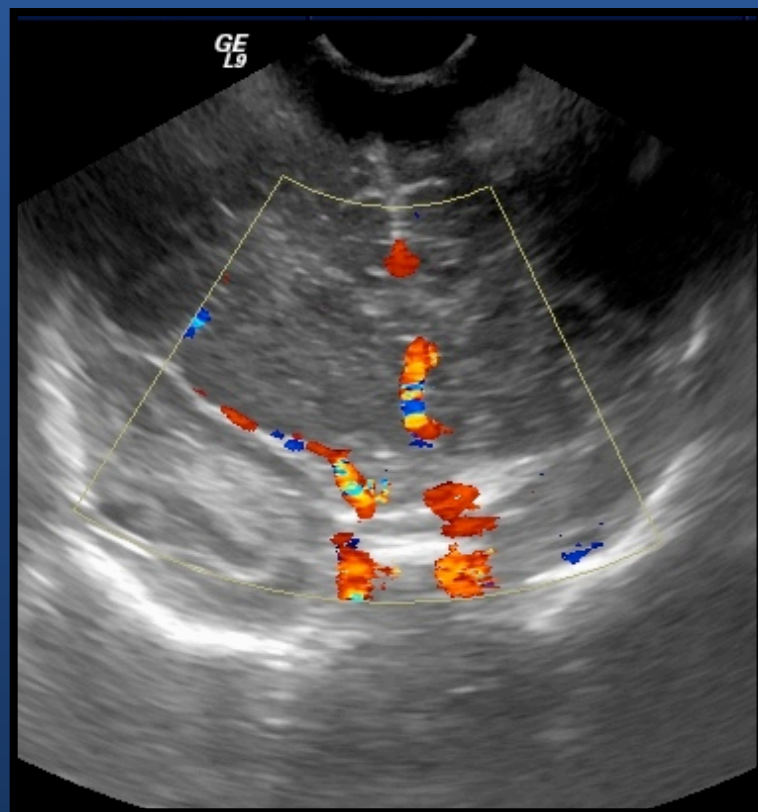
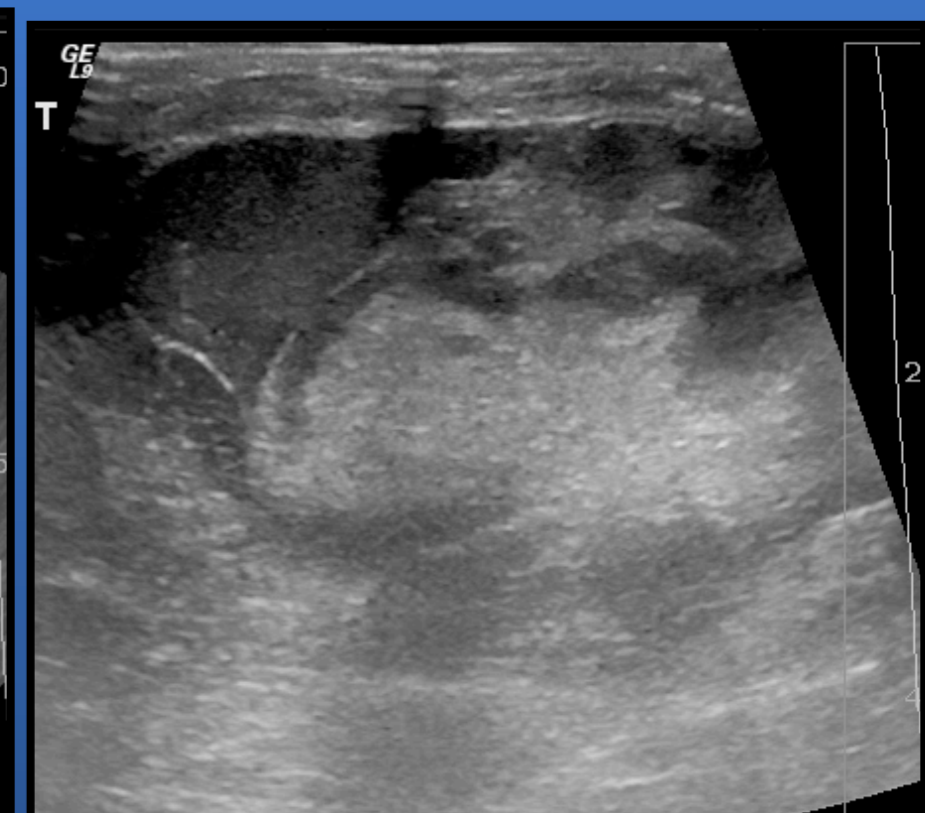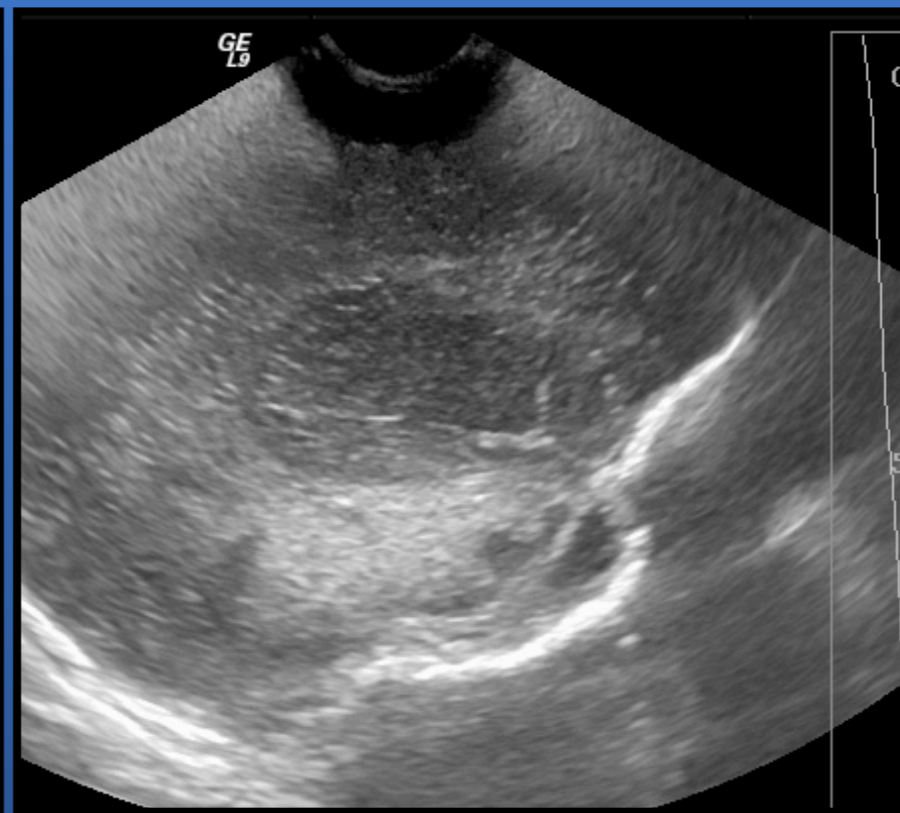
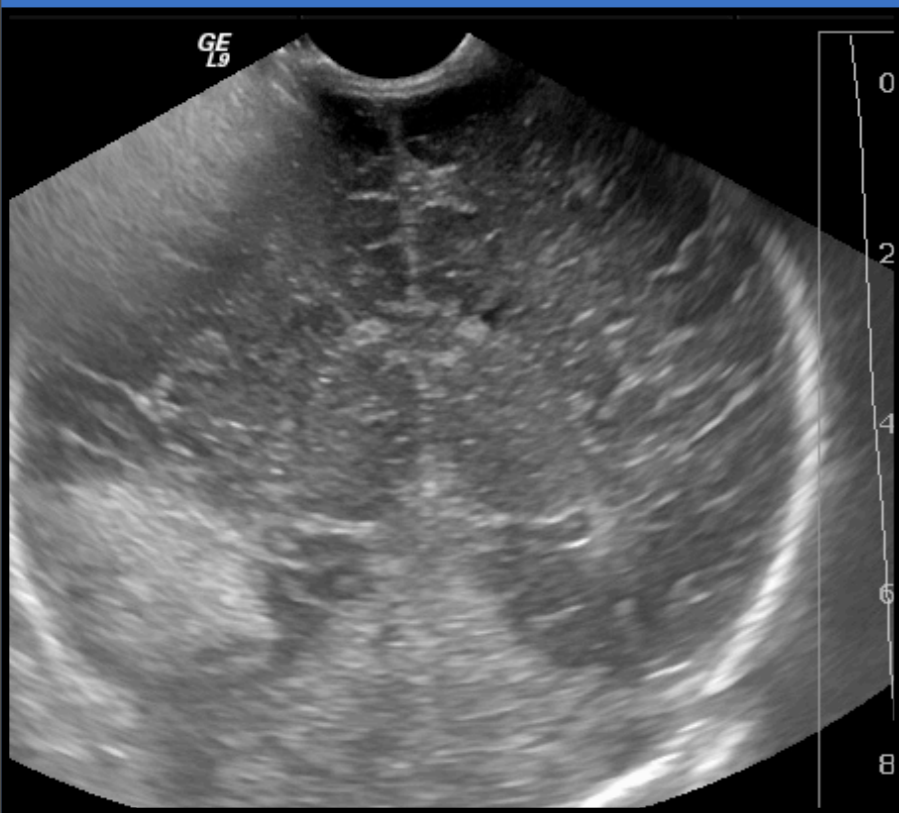






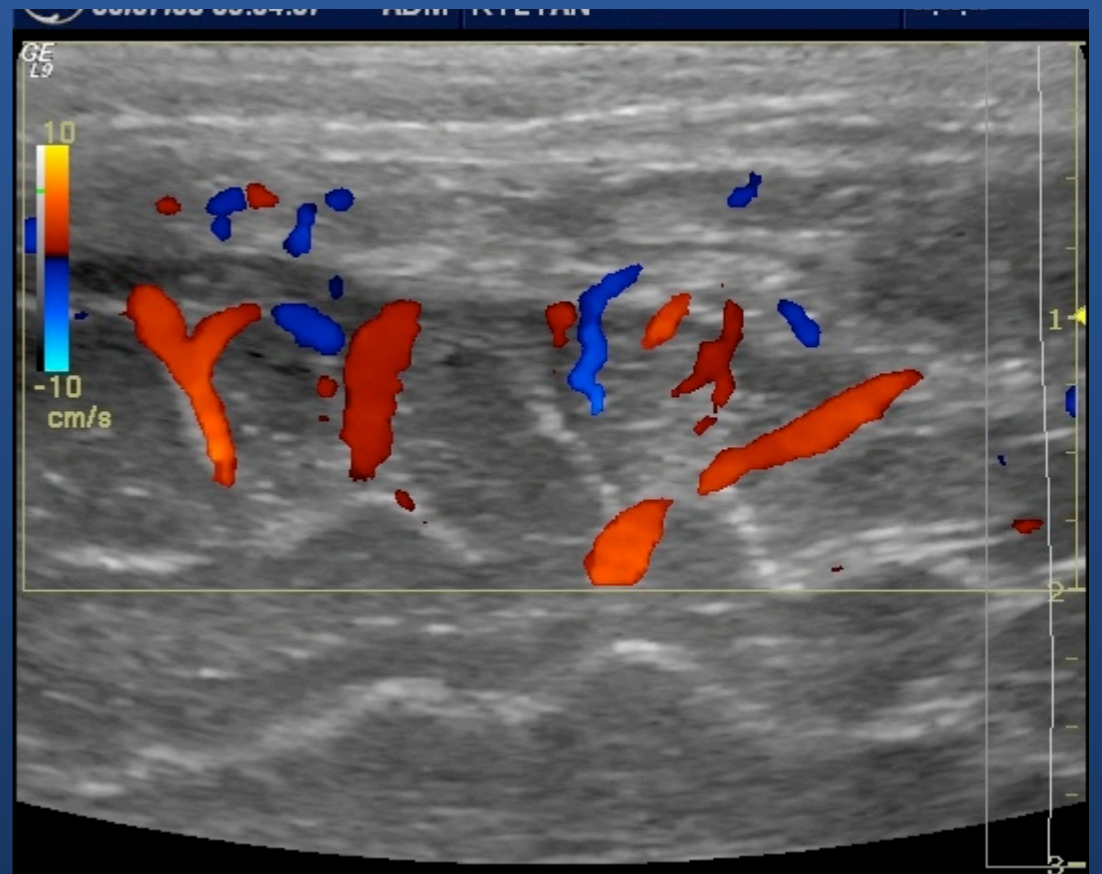
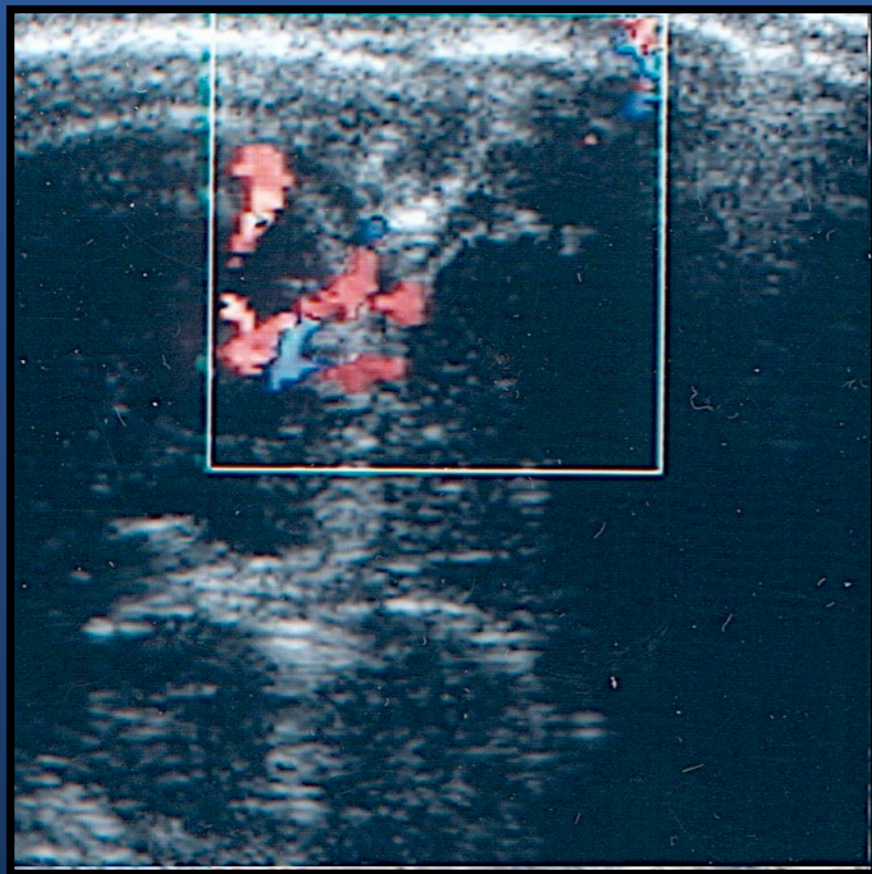
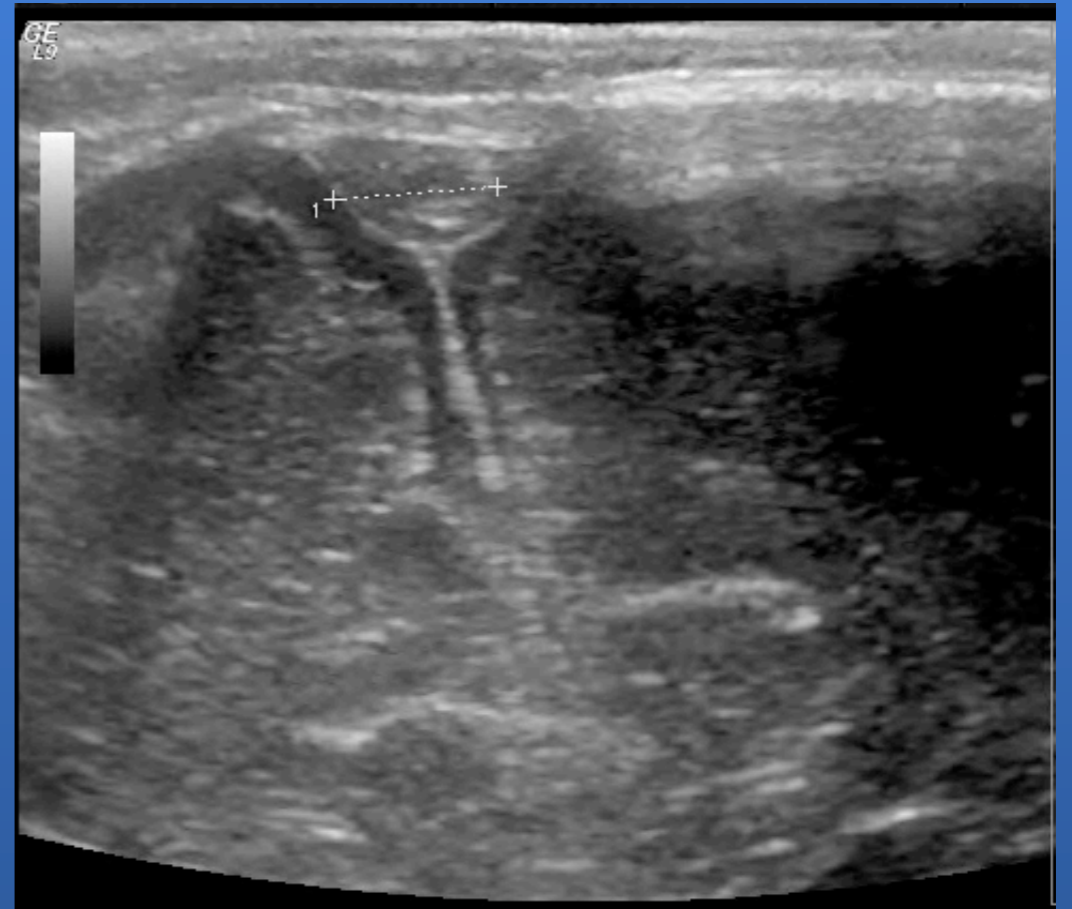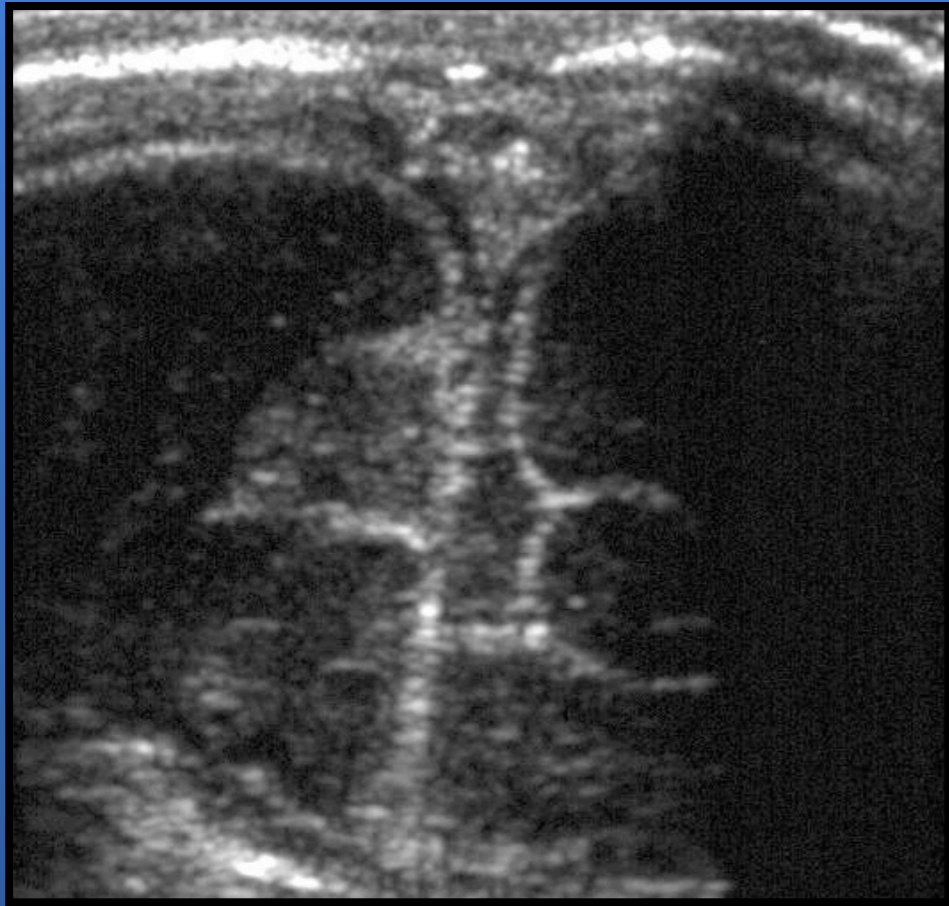


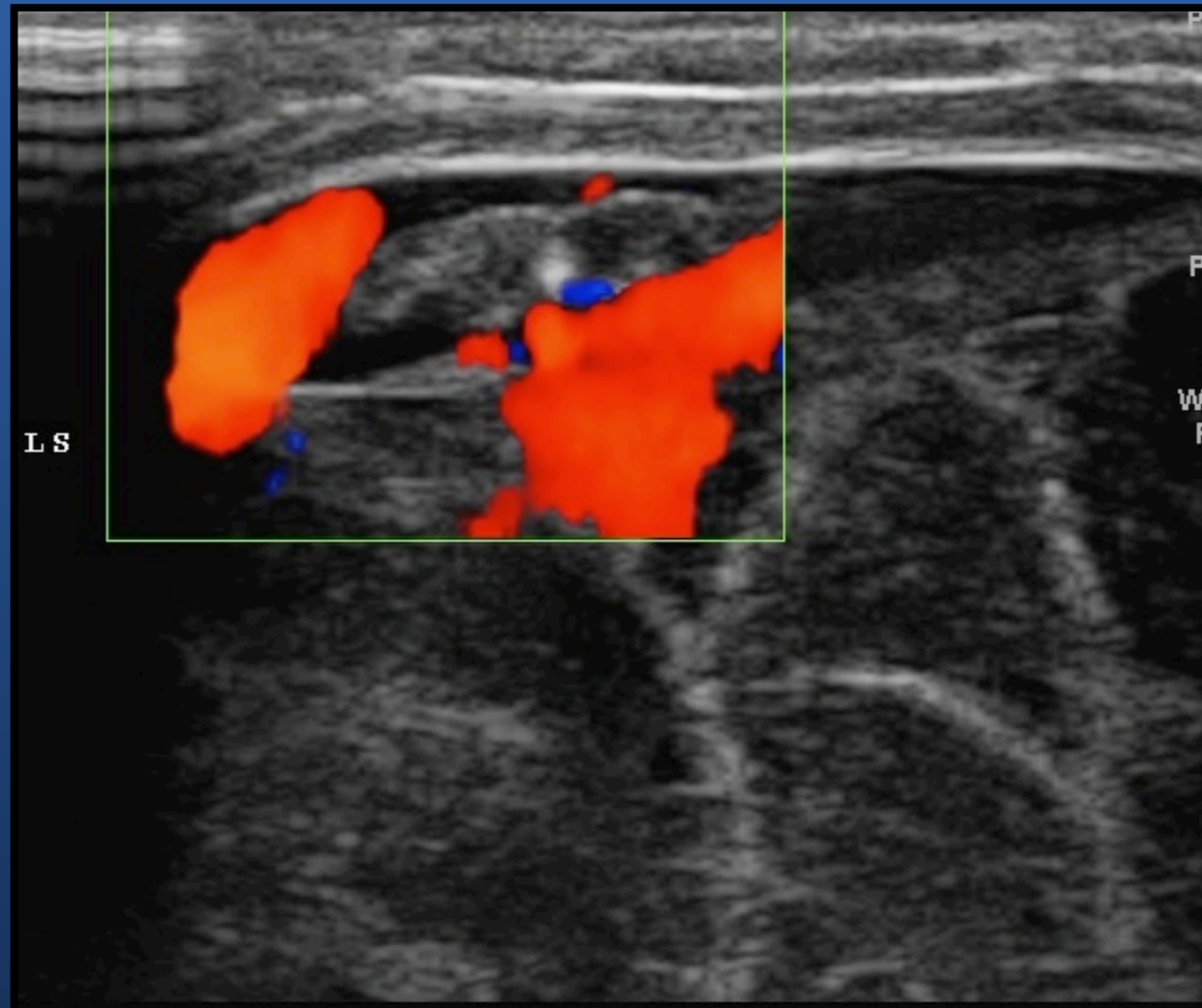
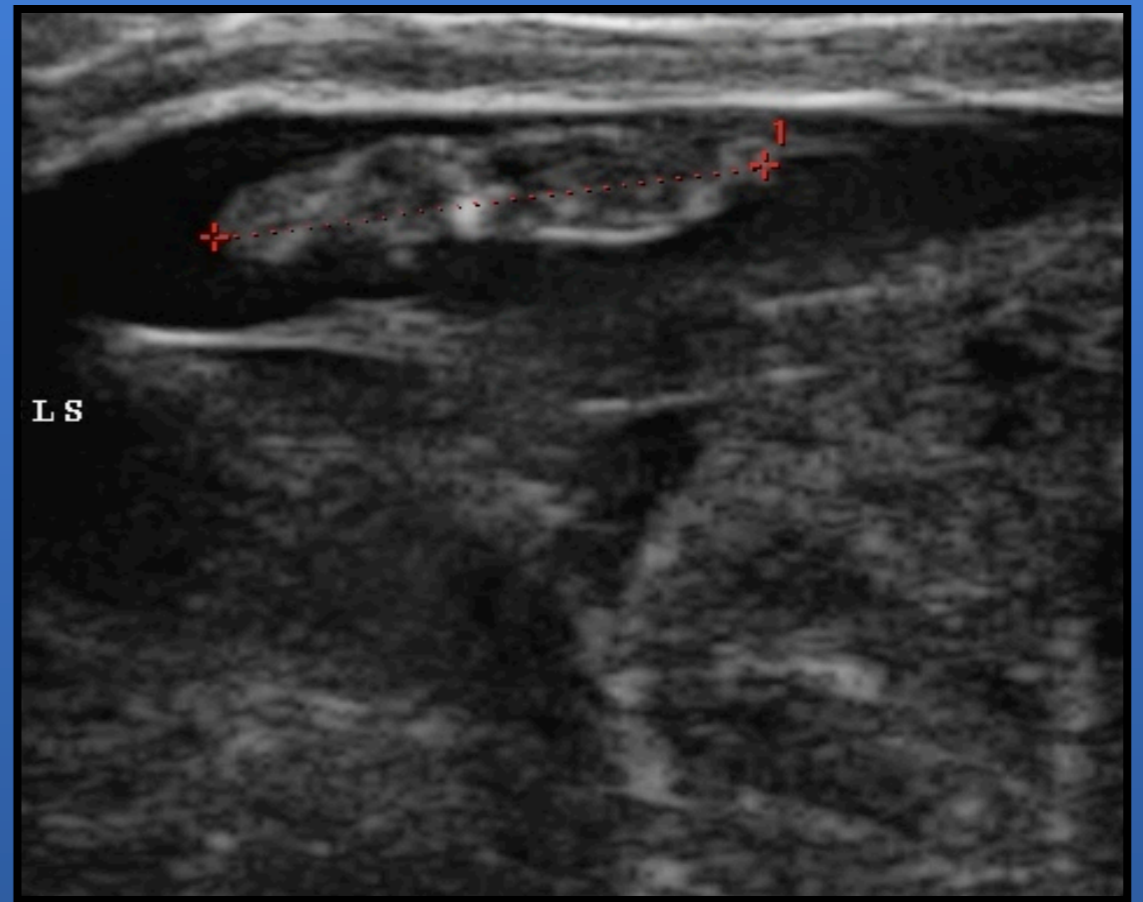
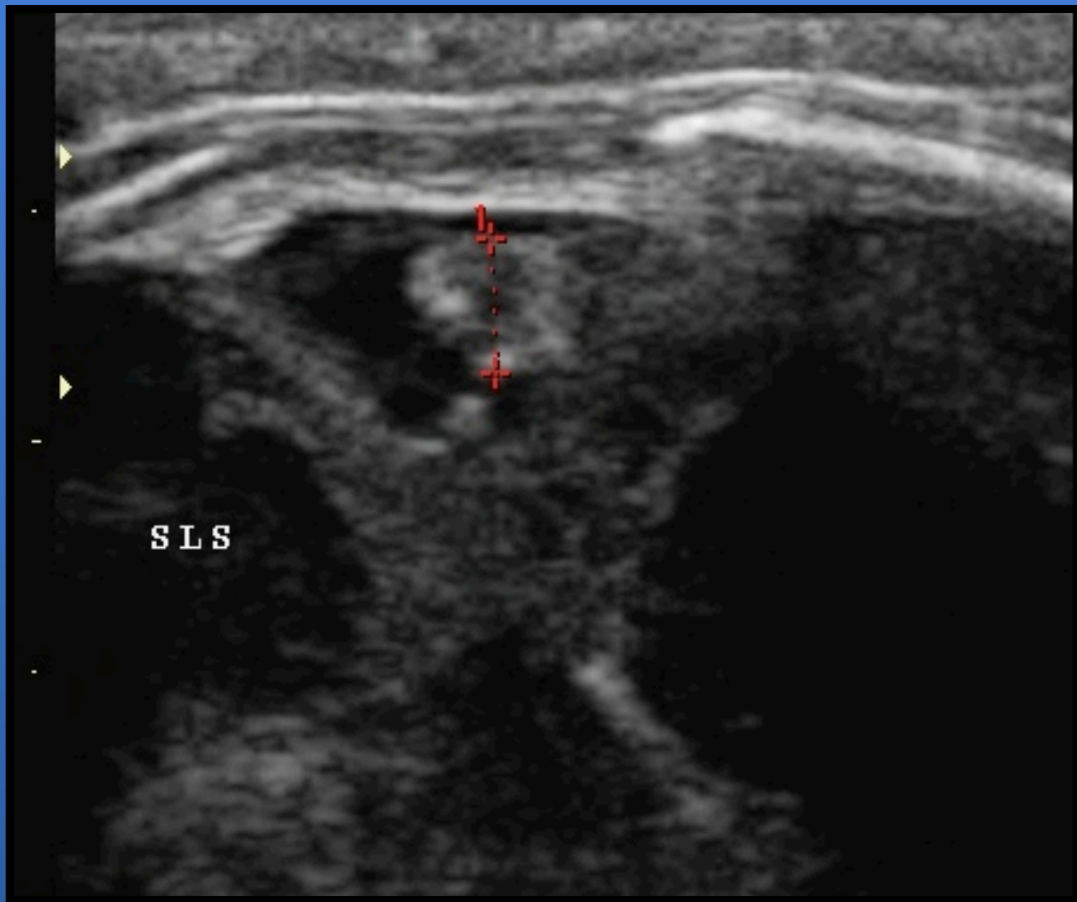
AVC HÉMORRAGIQUE



THROMBOSE DU SINUS LONGITUDINAL SUPERIEUR

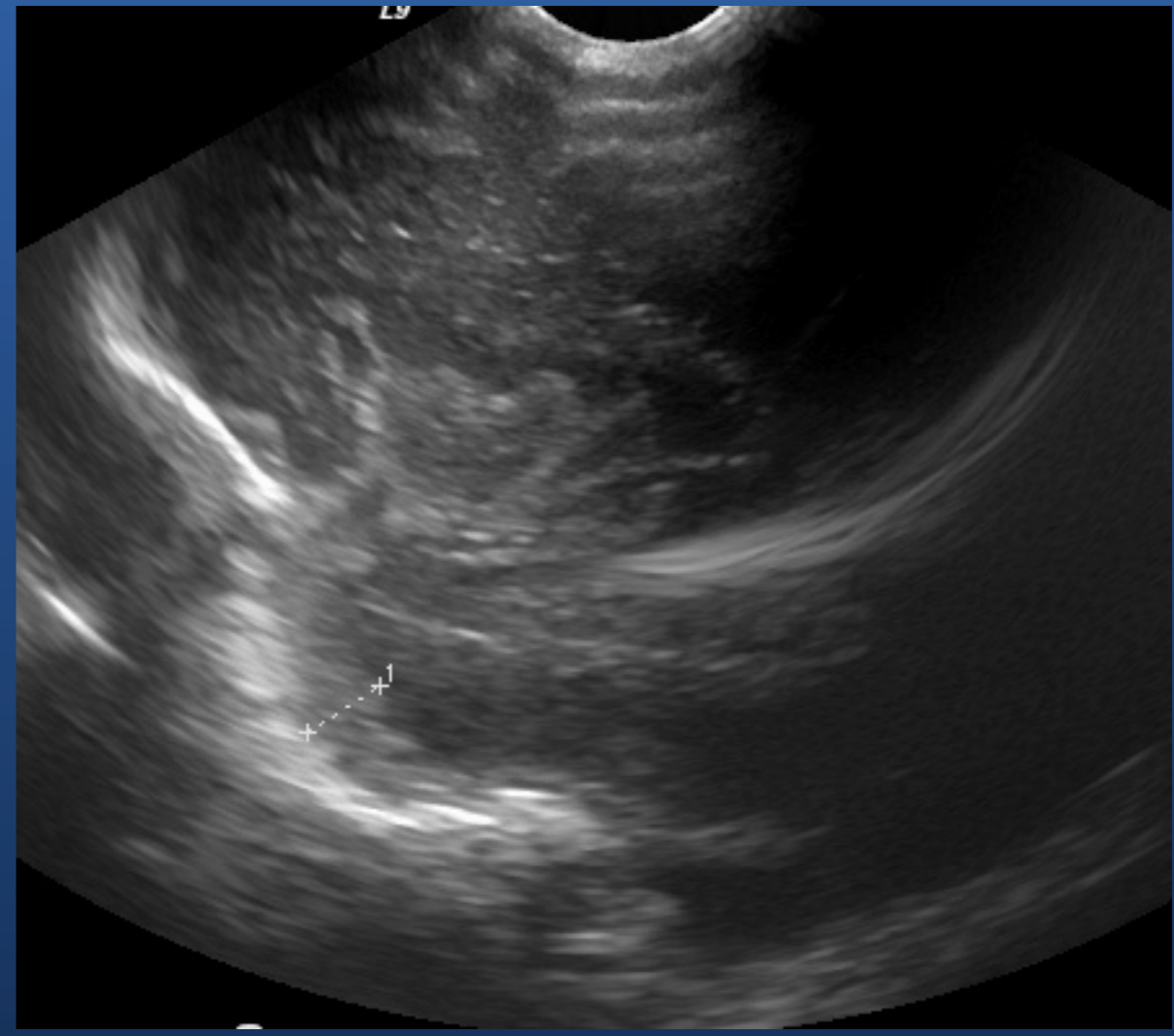
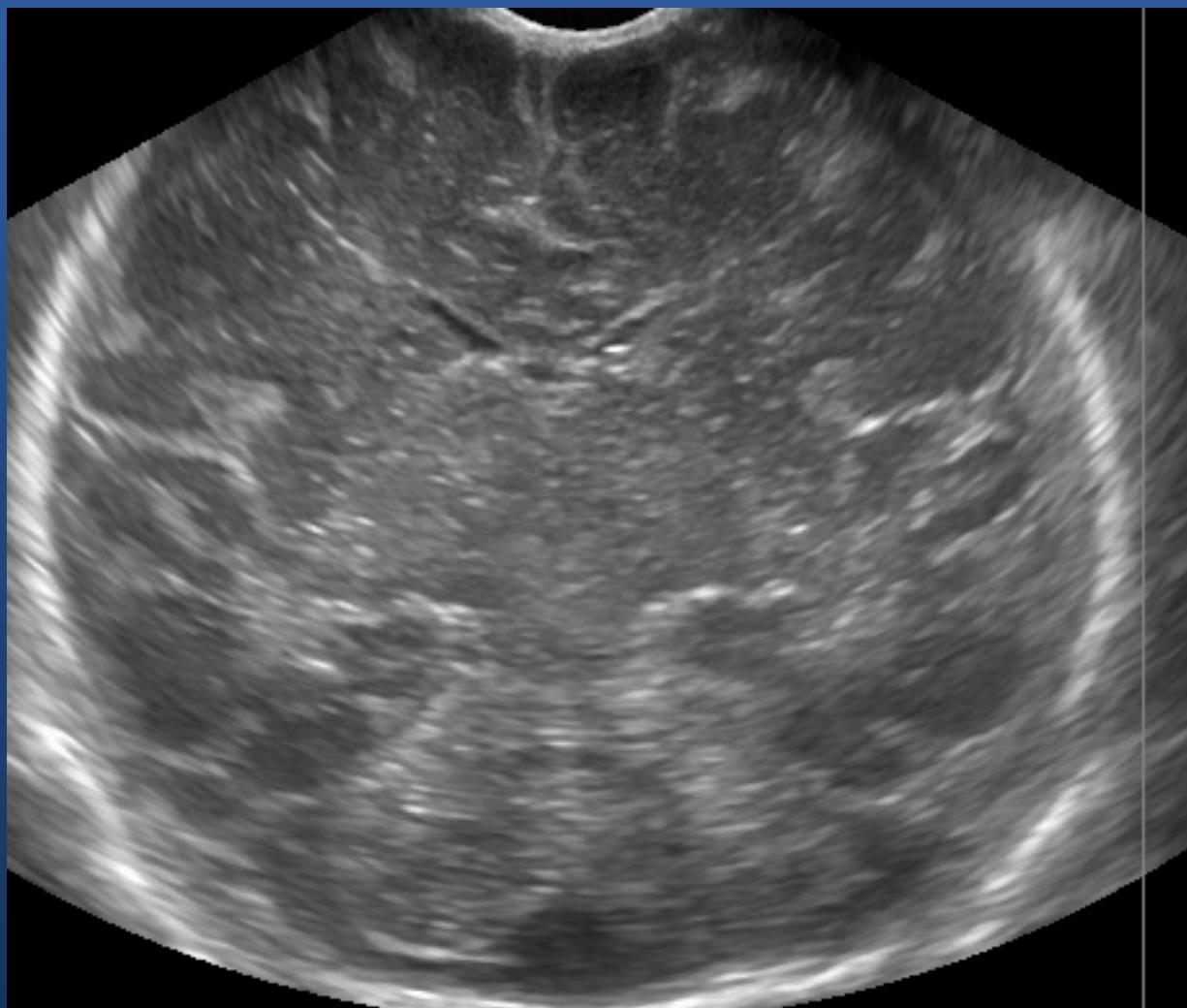
- **Facteurs favorisants**
 - troubles de la coagulation
 - méningite
- **Hyperéchogénicité du sinus**
- **Absence de flux en doppler couleur**
- **↑ des flux au niveau des veines corticales**





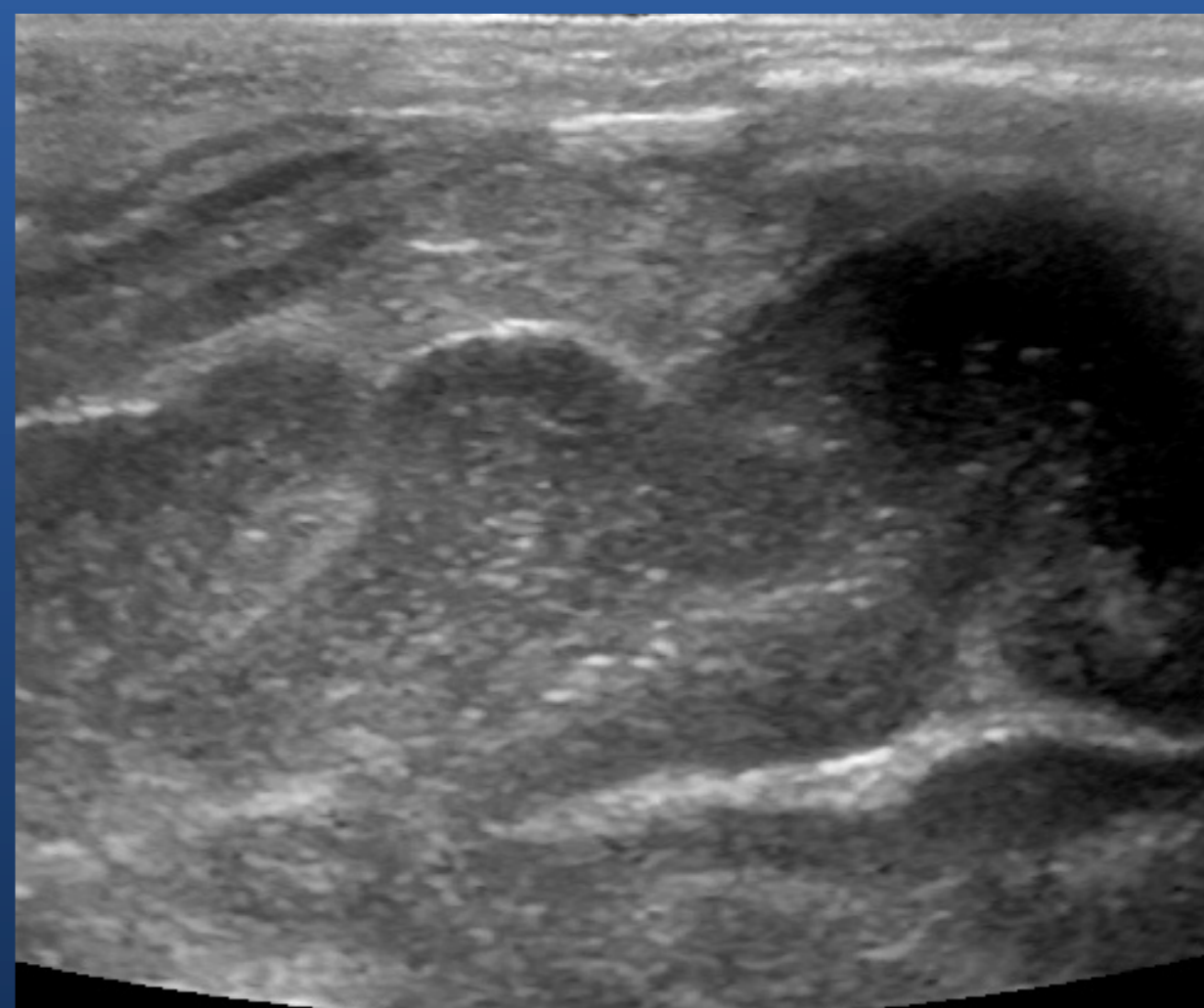
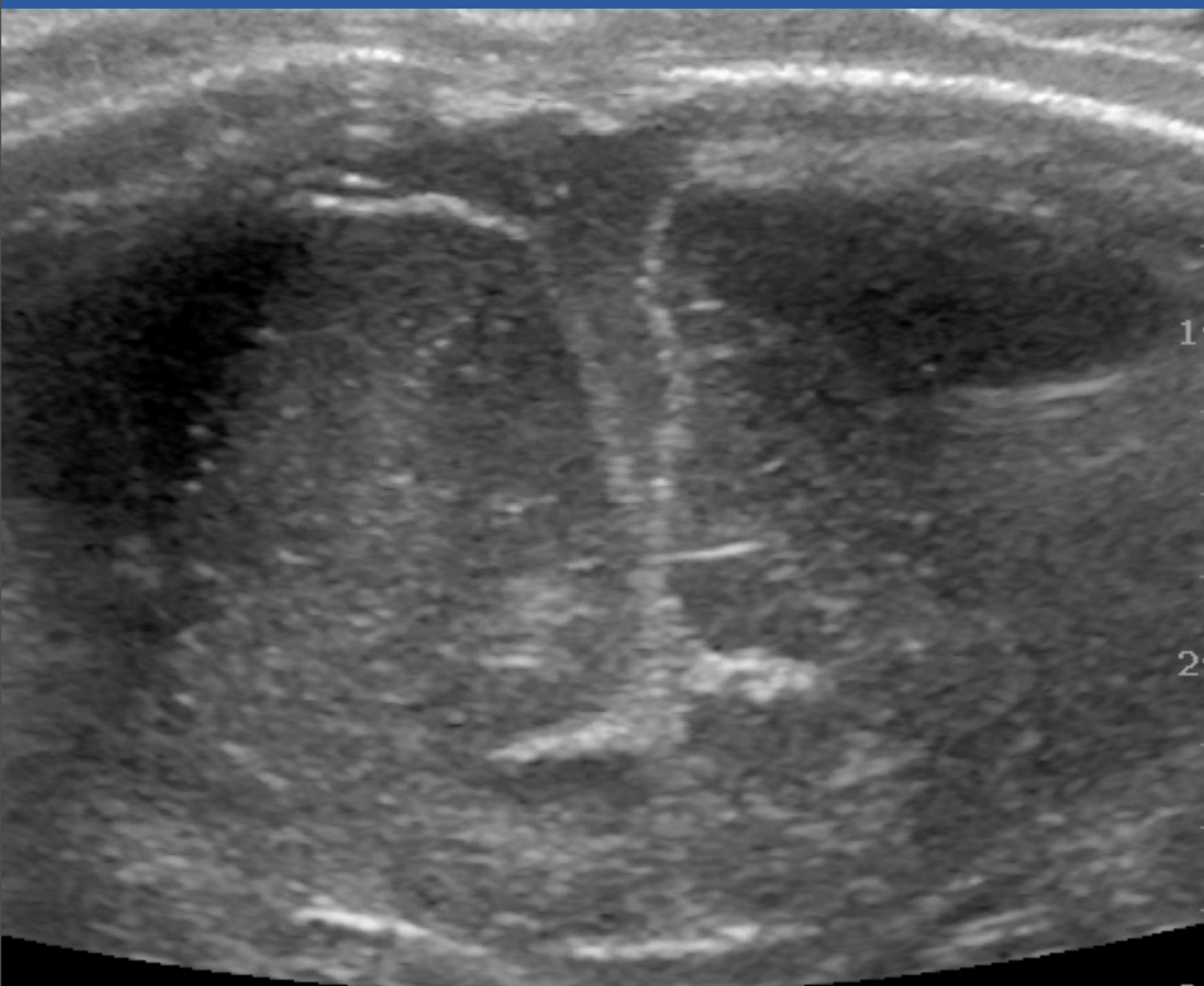
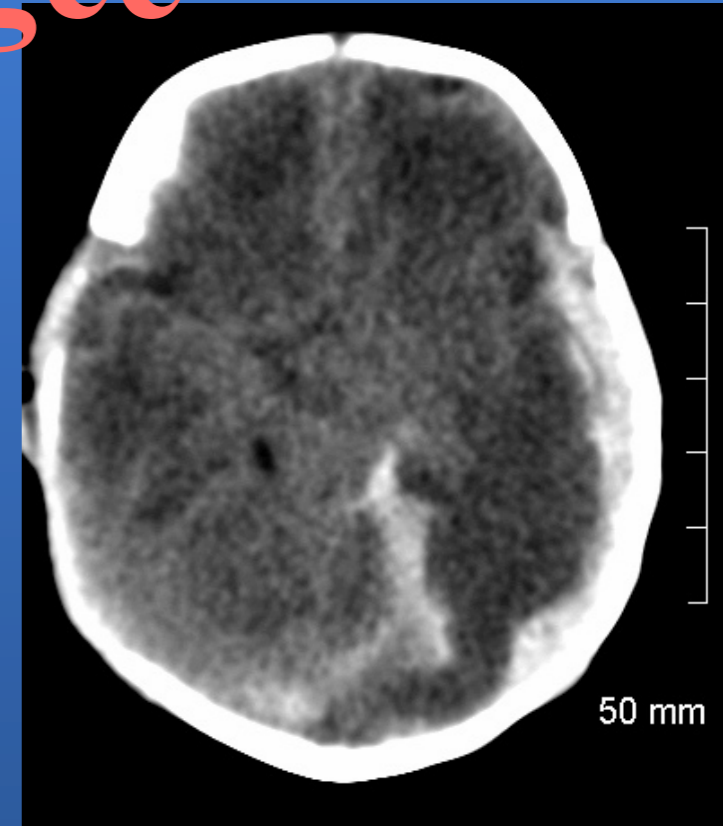
Hémorragie méningée

- Clinique
- Convulsions
- Accouchement traumatique
- Aspect échogène des espaces sous arachnoïdiens



Hémorragie méningée

- Clinique
- Convulsions
- Accouchement traumatique
- Aspect échogène des espaces sous arachnoïdiens

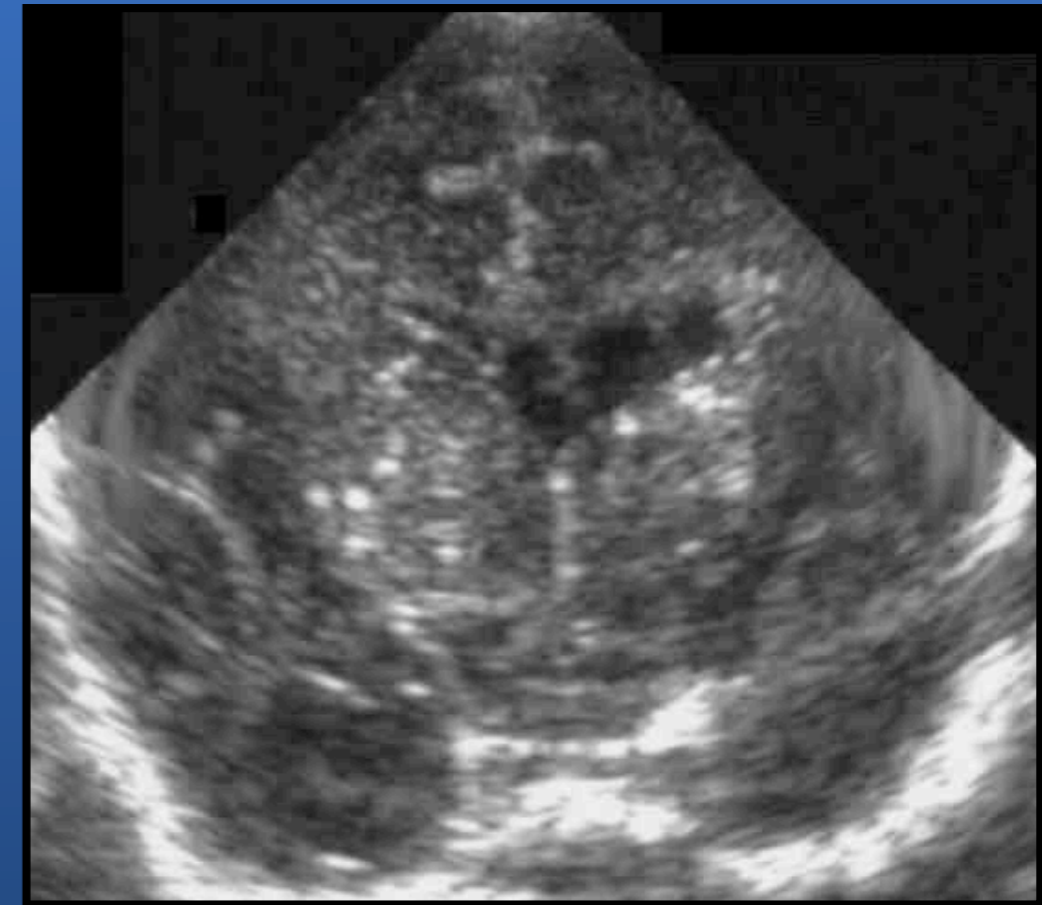


LES INFECTIONS

- **Ante ou post-natales**
- **Apport diagnostique**
- **Surveillance +++**

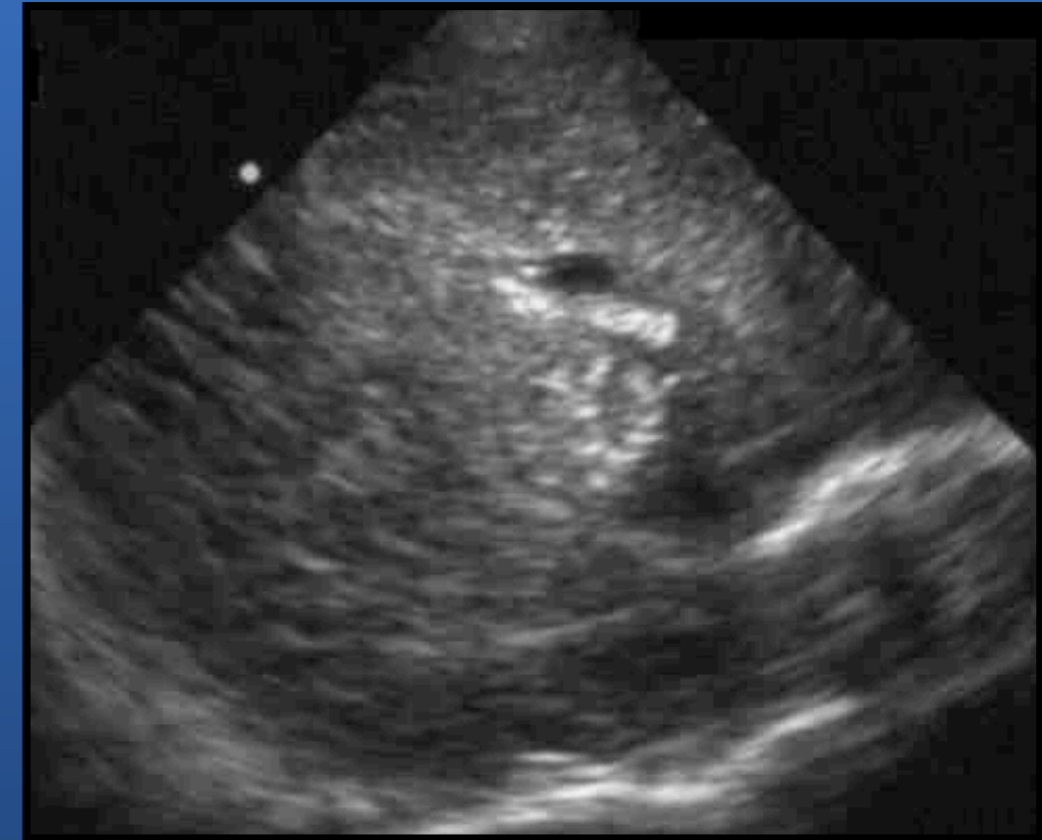INFECTIONS FOETALES

- **Signes non spécifiques**
- **Embryofœtopathologie**
 - **CMV, toxoplasmose, rubéole**
- **Sémiologie**
 - **Dilatation ventriculaire**
 - **Atrophie cérébrale**
 - **Zone hyperéchogène calcifiée**
 - **Périventriculaire, thalamique**
 - **Kyste sous-épendymaire**



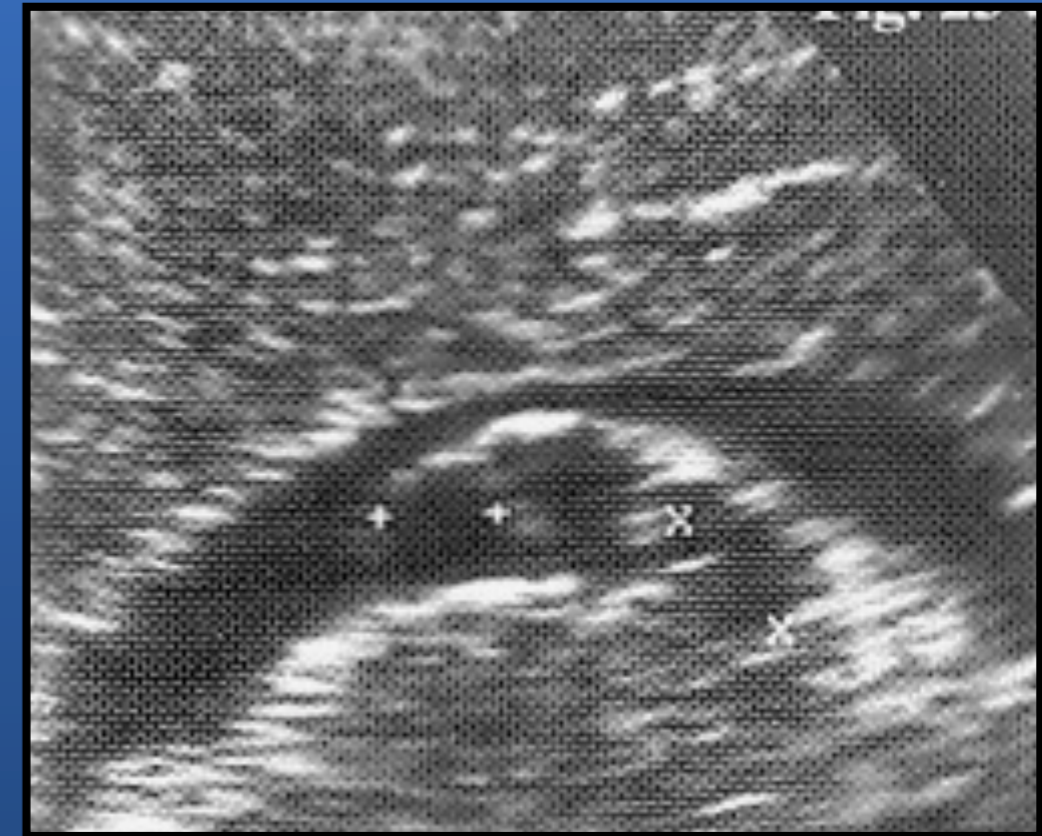INFECTIONS FOETALES

- **Signes non spécifiques**
- **Embryofœtopathologie**
 - **CMV, toxoplasmose, rubéole**
- **Sémiologie**
 - **Dilatation ventriculaire**
 - **Atrophie cérébrale**
 - **Zone hyperéchogène calcifiée**
 - **Périventriculaire, thalamique**
 - **Kyste sous-épendymaire**



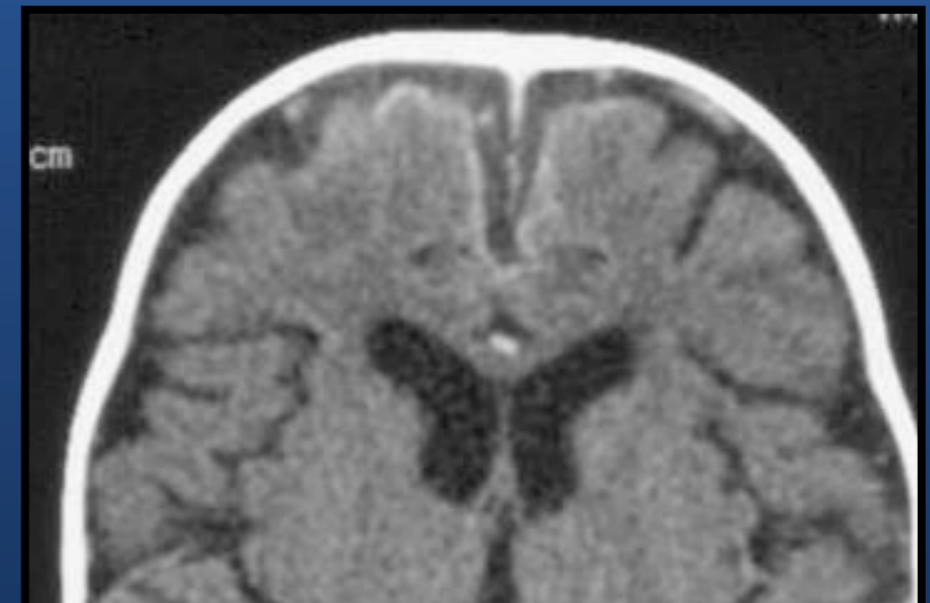
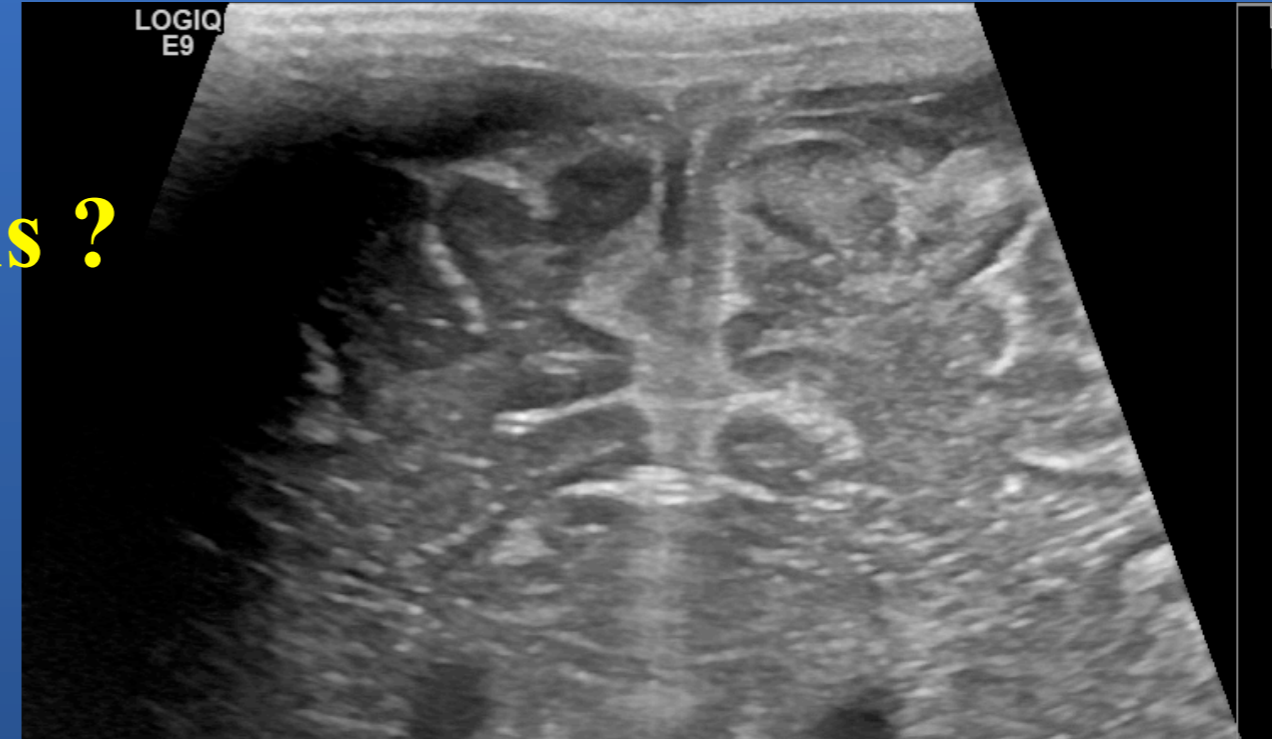INFECTIONS FOETALES

- **Signes non spécifiques**
- **Embryofœtopathologie**
 - **CMV, toxoplasmose, rubéole**
- **Sémiologie**
 - **Dilatation ventriculaire**
 - **Atrophie cérébrale**
 - **Zone hyperéchogène calcifiée**
 - **Périventriculaire, thalamique**
 - **Kyste sous-épendymaire**



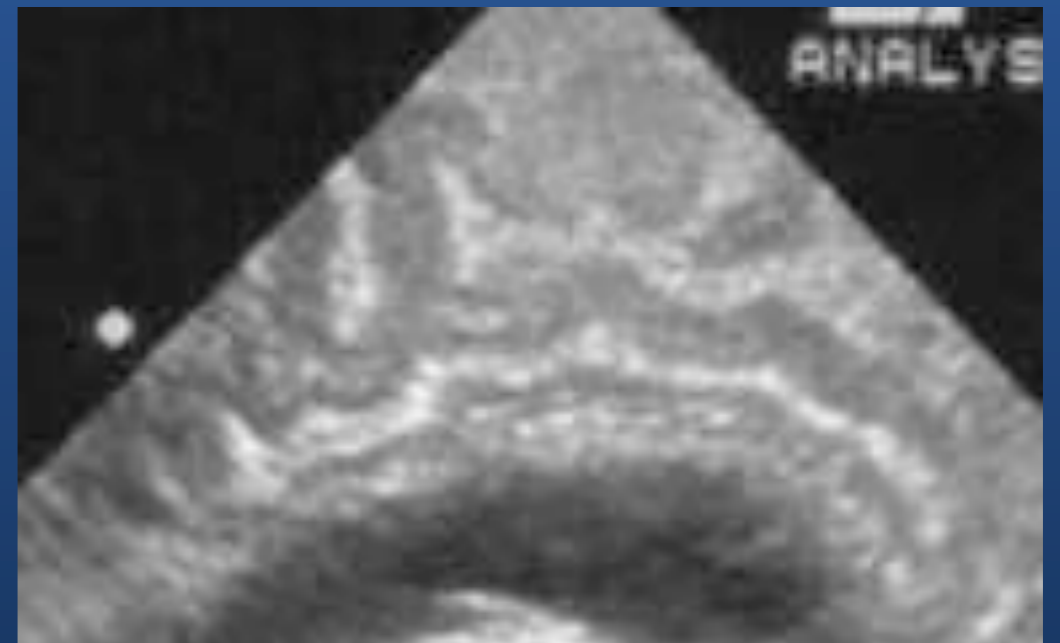
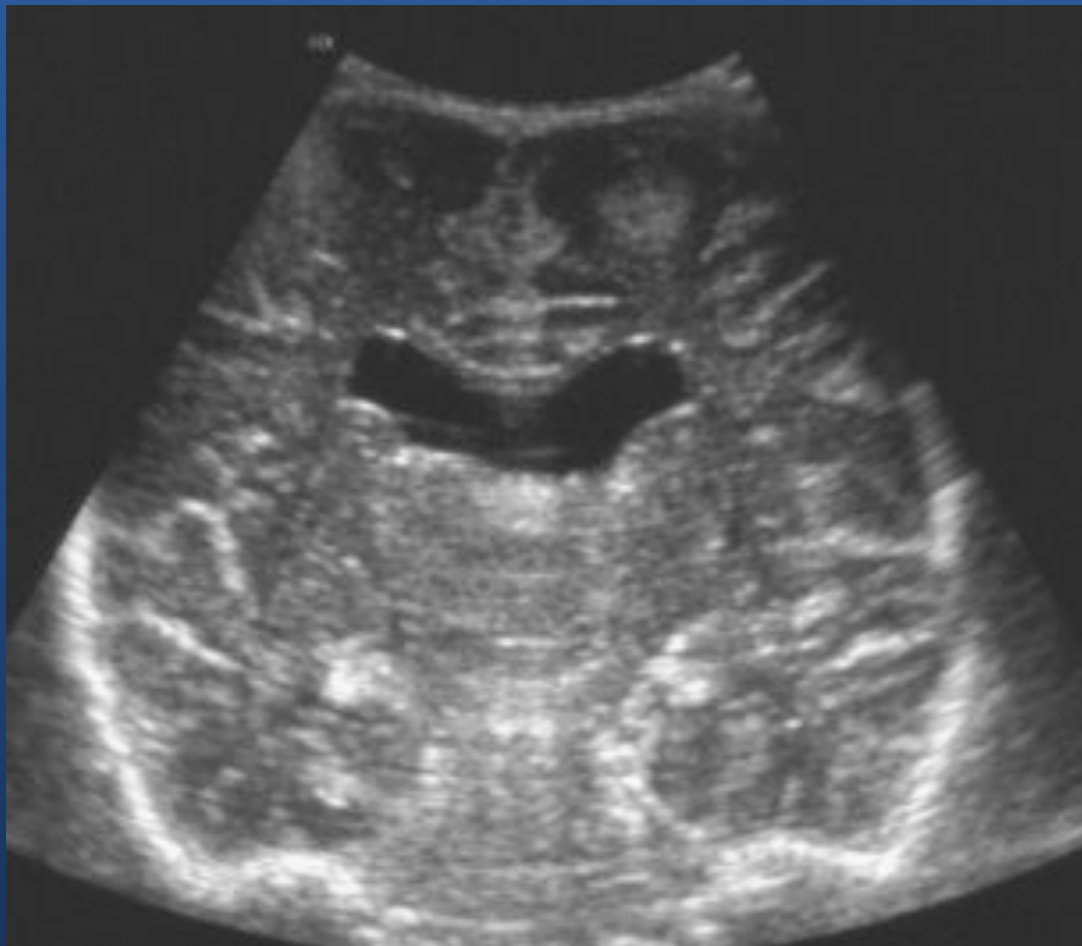MENINGITE

- **Signes de début : RAS**
 - hyperéchogénicité des sillons ?
- **Signes secondaires :**
 - diminution des ventricules (oedème)
 - ventriculite
- **Complications**



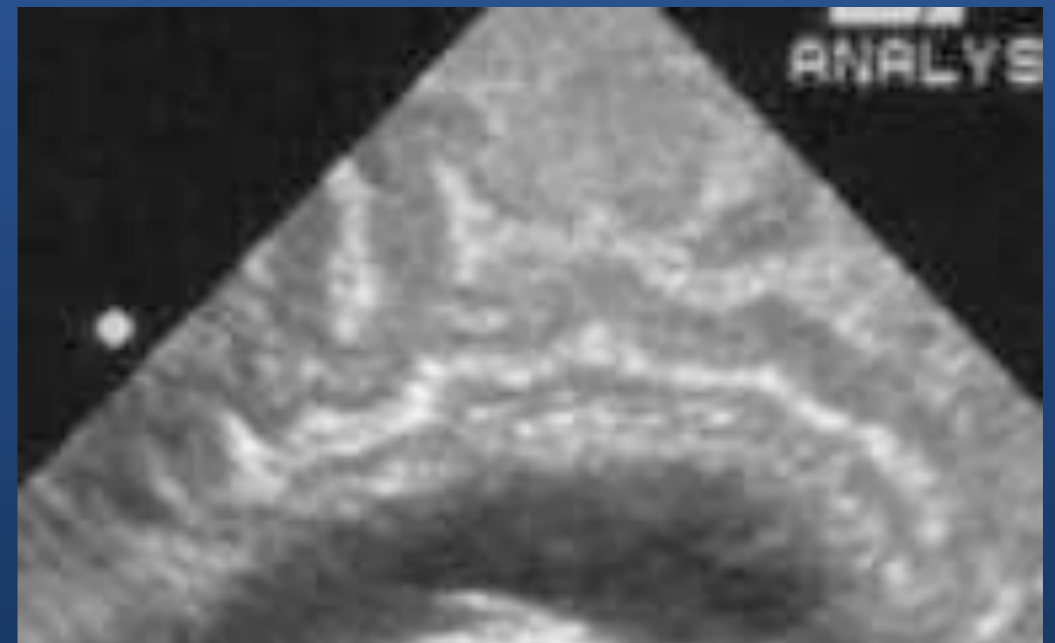
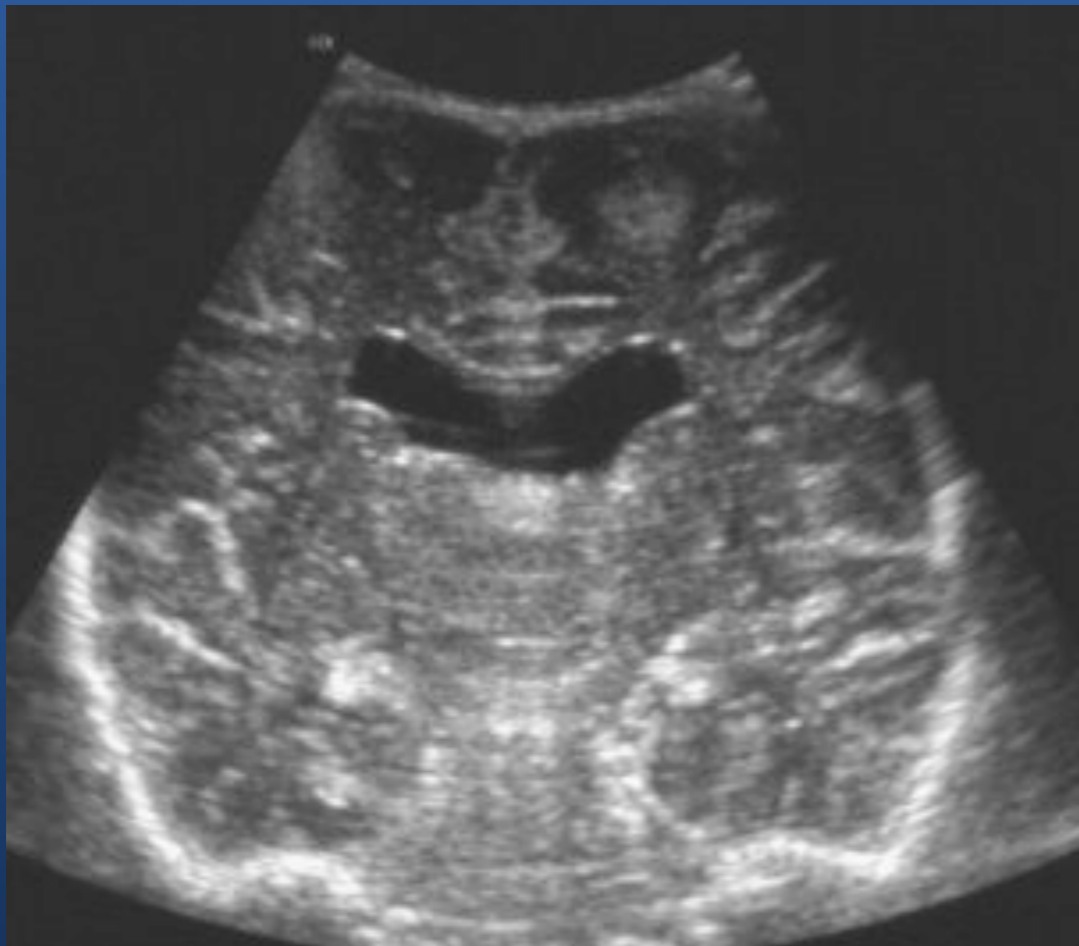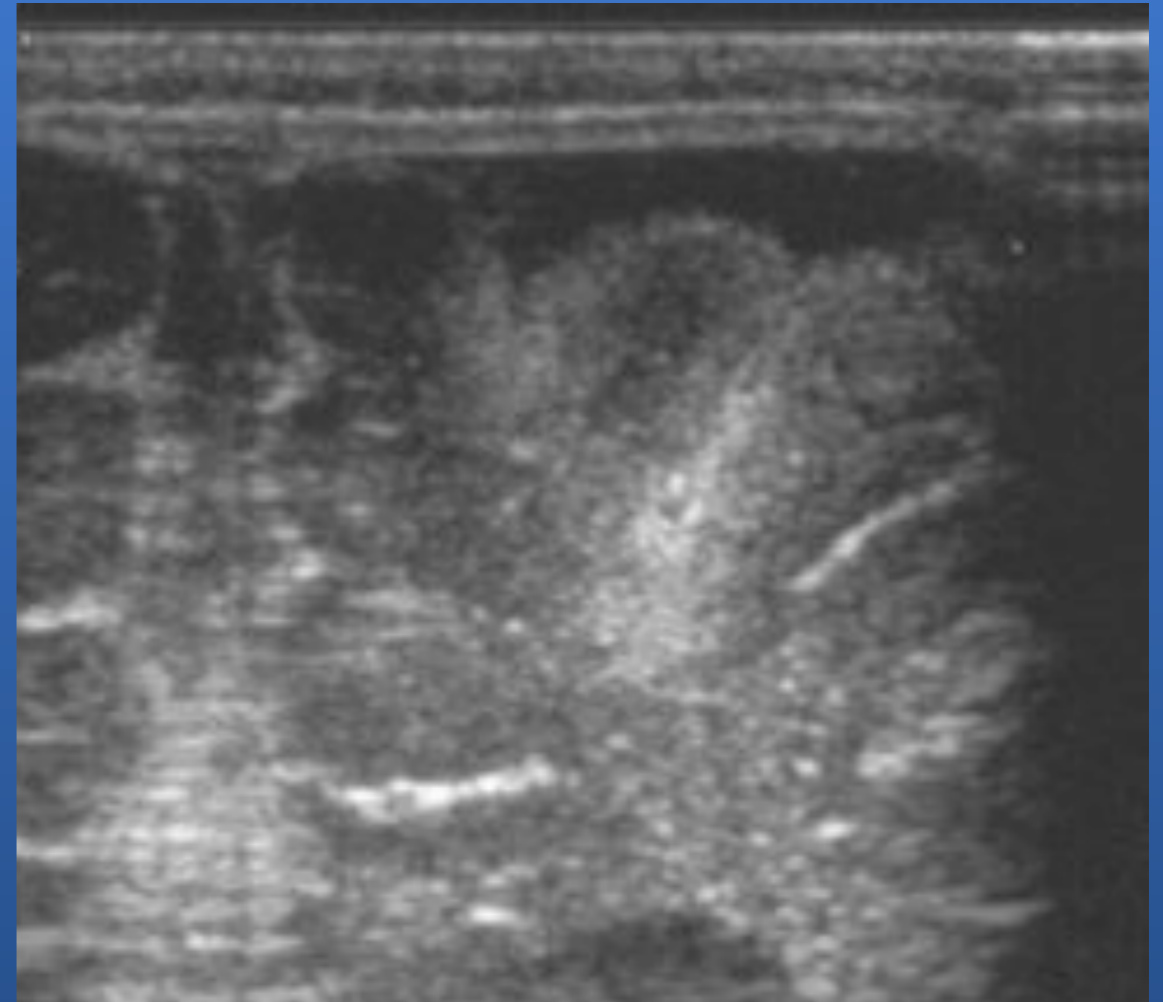MÉNINGITE

- Normale
- Sillons hyper échogènes



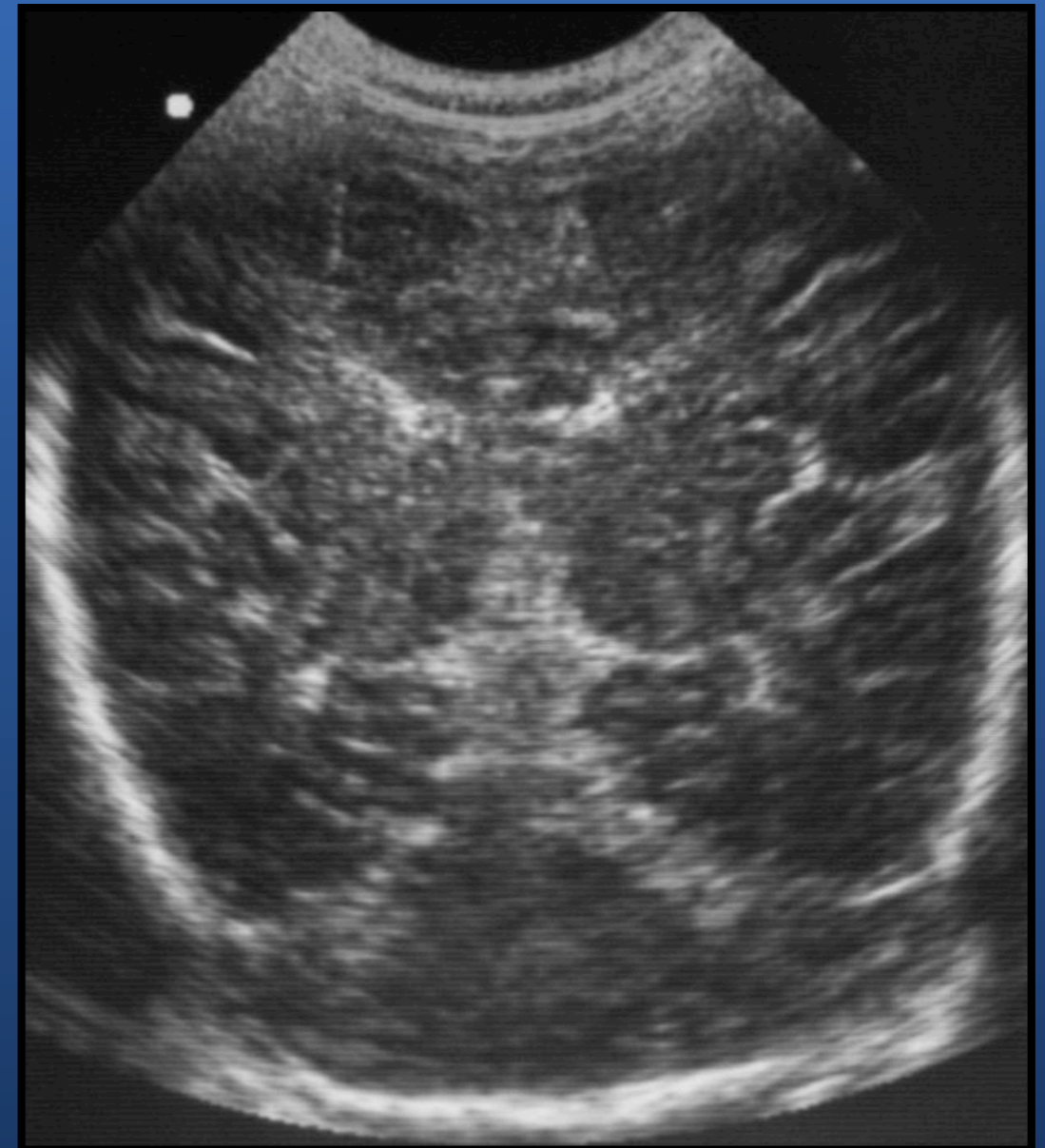MÉNINGITE

- Normale
- Sillons hyper échogènes



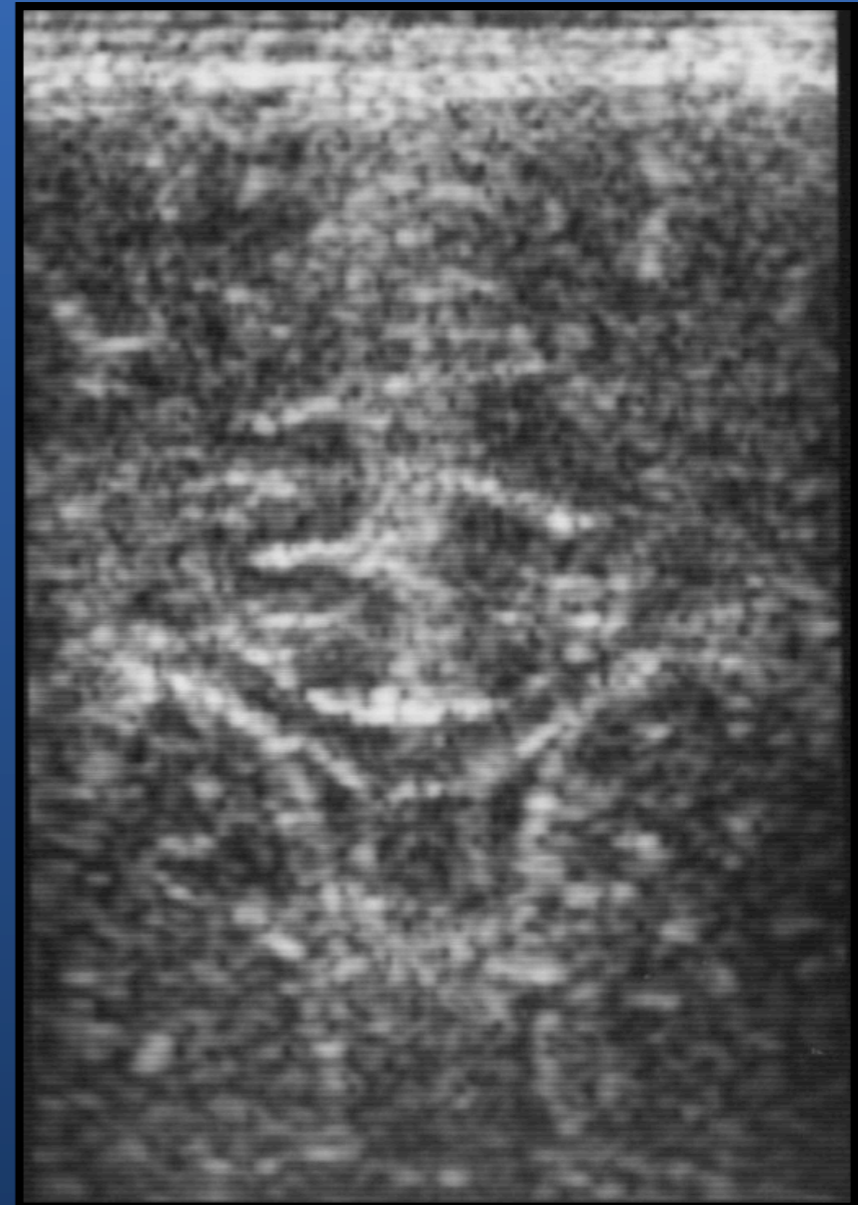Méningite complications : ventriculite

- **Hyper échogénicité des parois**
- **Aspect irrégulier**
- **Echos dans la lumière ventriculaire**
- **Dilatation**



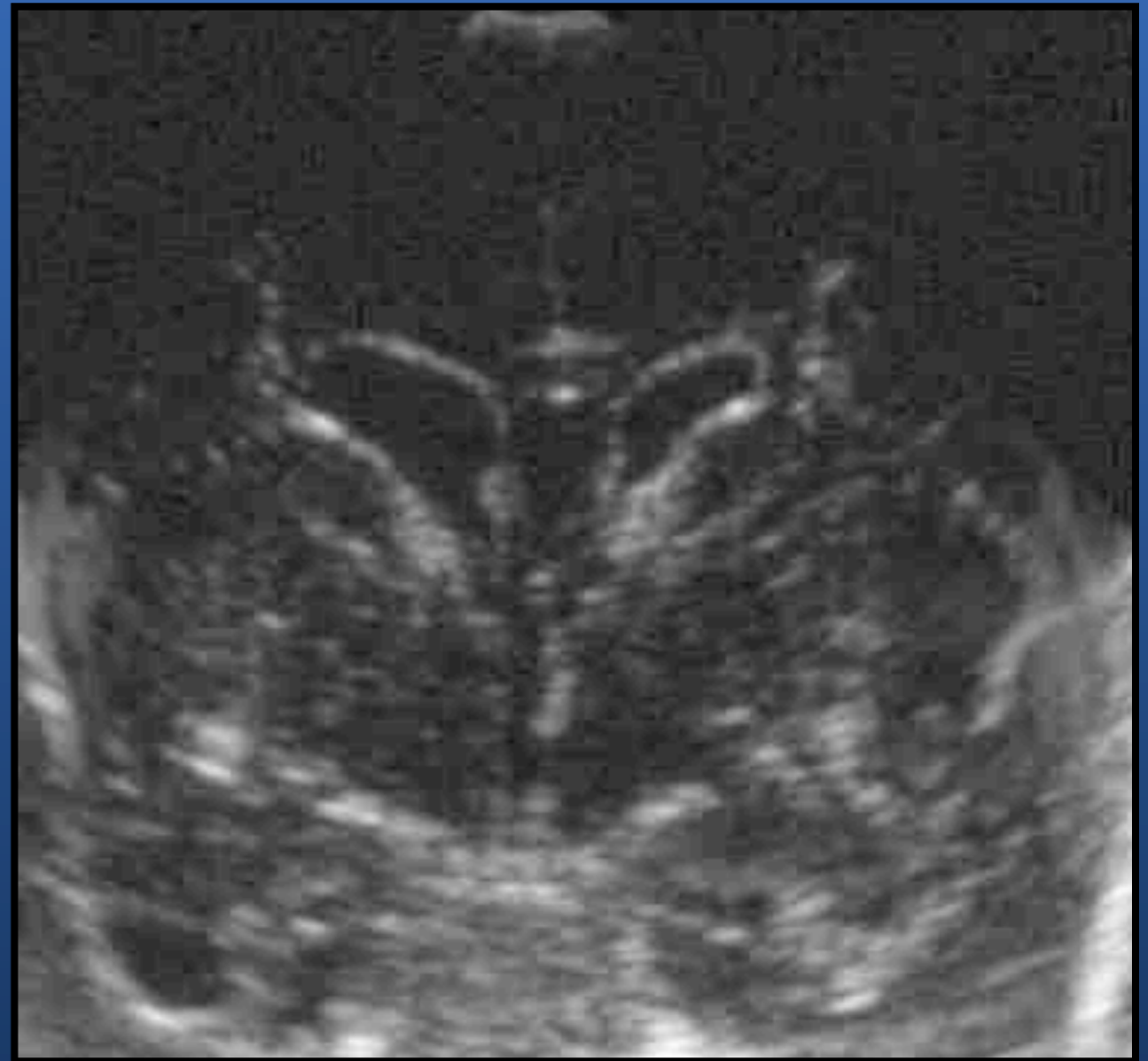Méningite complications : ventriculite

- **Hyper échogénicité des parois**
- **Aspect irrégulier**
- **Echos dans la lumière ventriculaire**
- **Dilatation**



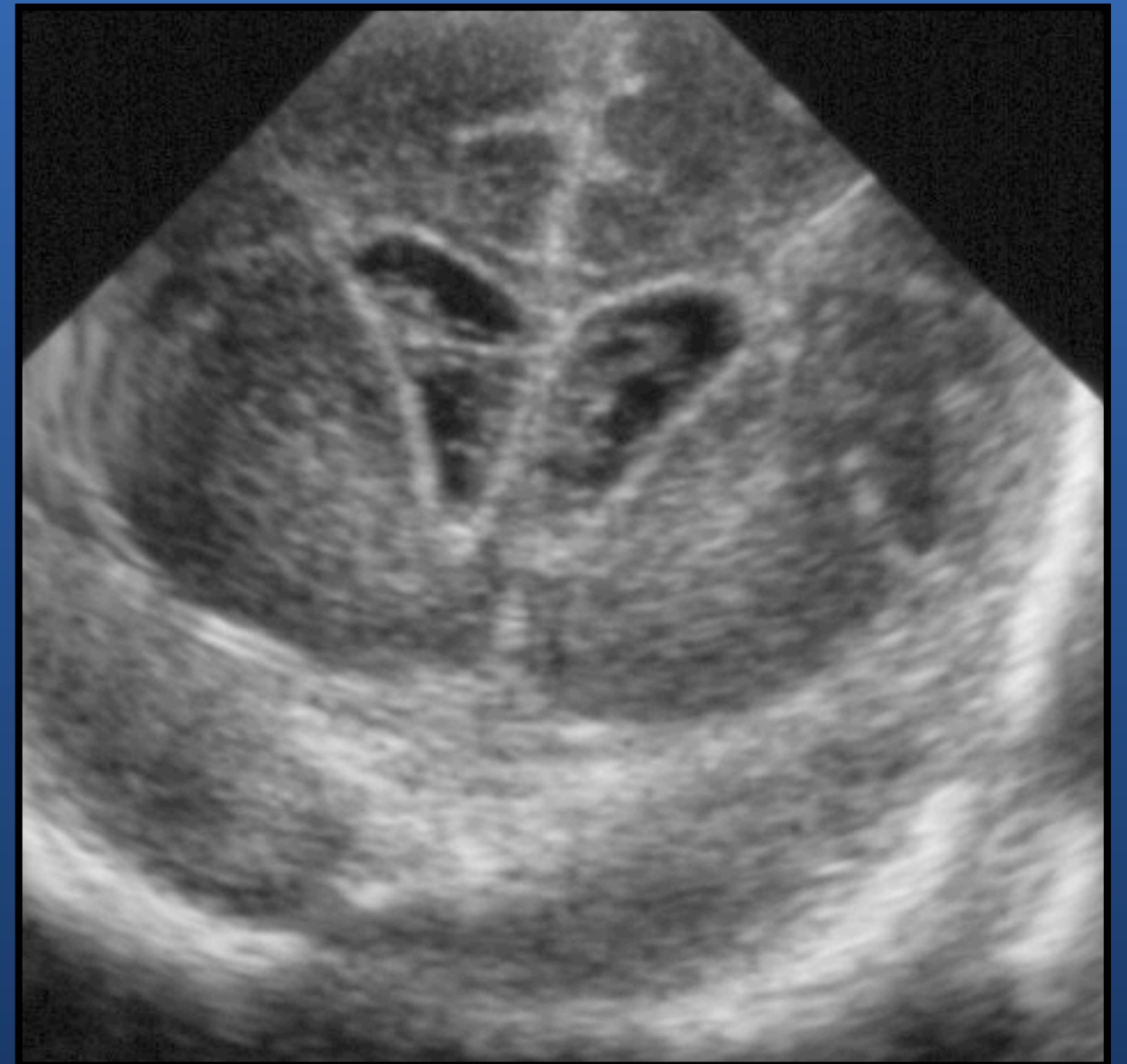
Méningite complications : ventriculite

- **Hyper échogénicité des parois**
- **Aspect irrégulier**
- **Echos dans la lumière ventriculaire**
- **Dilatation**



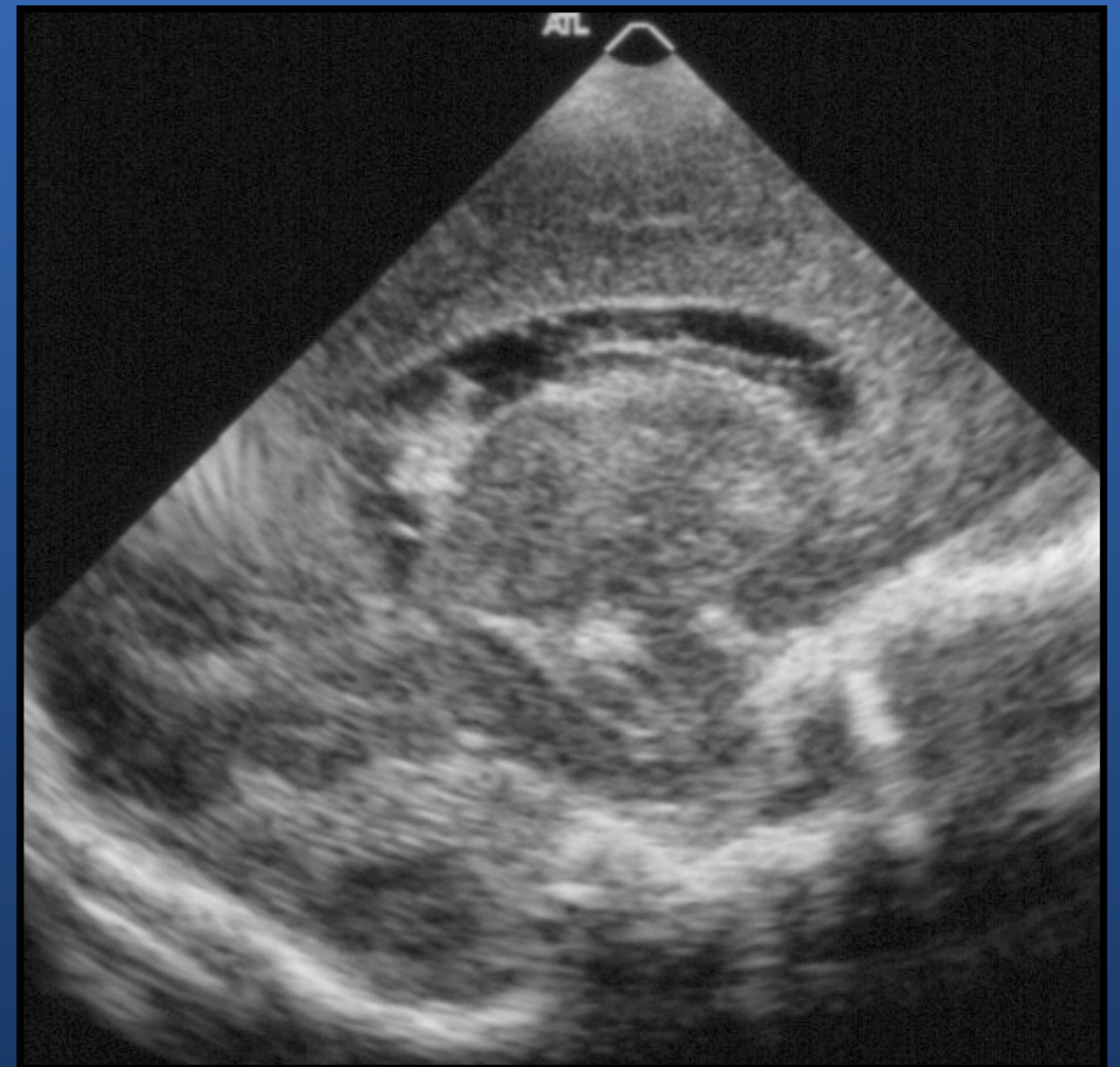
Méningite complications : ventriculite

- **Hyper échogénicité des parois**
- **Aspect irrégulier**
- **Echos dans la lumière ventriculaire**
- **Dilatation**



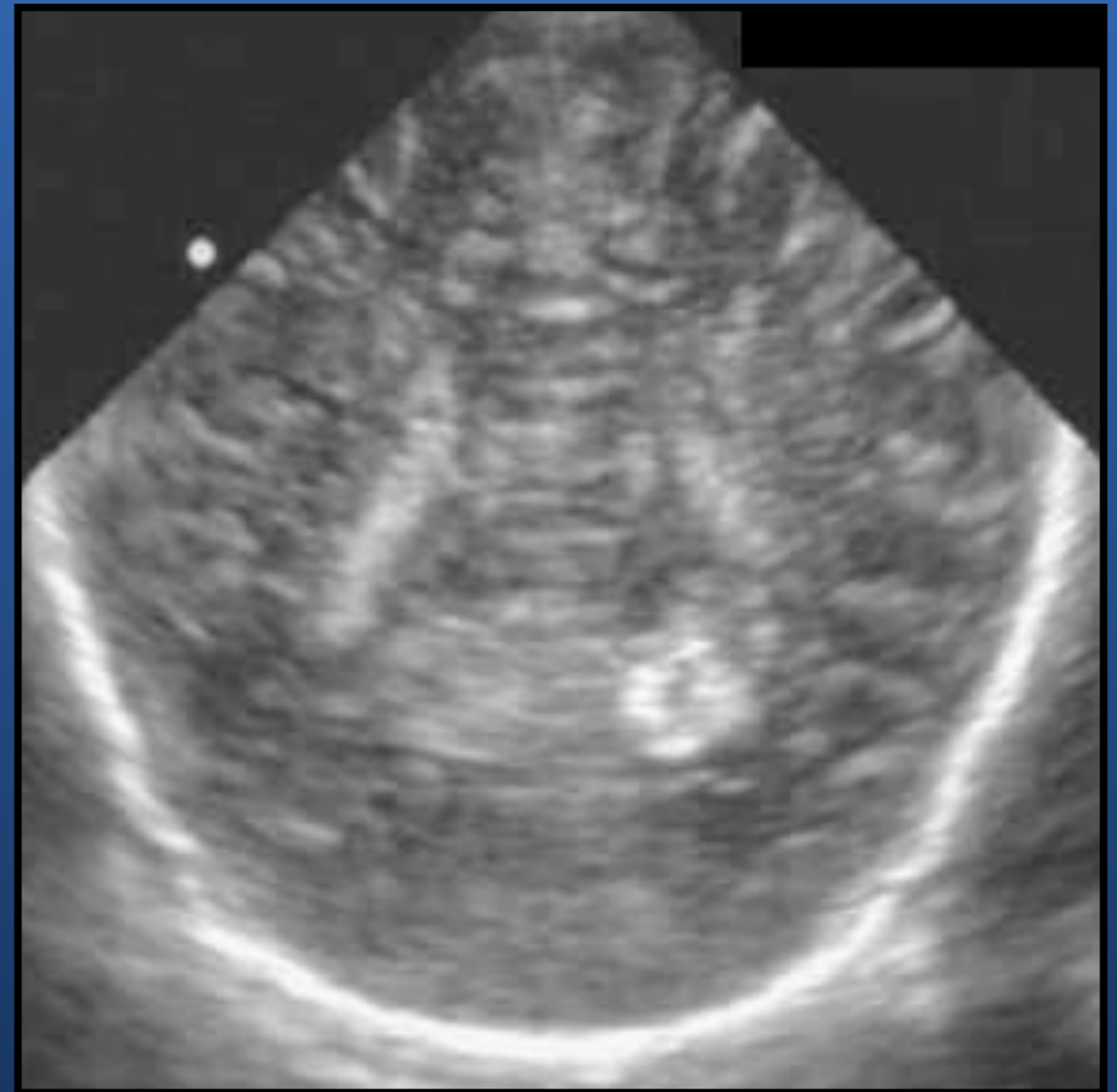
Méningite complications : ventriculite

- **Hyper échogénicité des parois**
- **Aspect irrégulier**
- **Echos dans la lumière ventriculaire**
- **Dilatation**



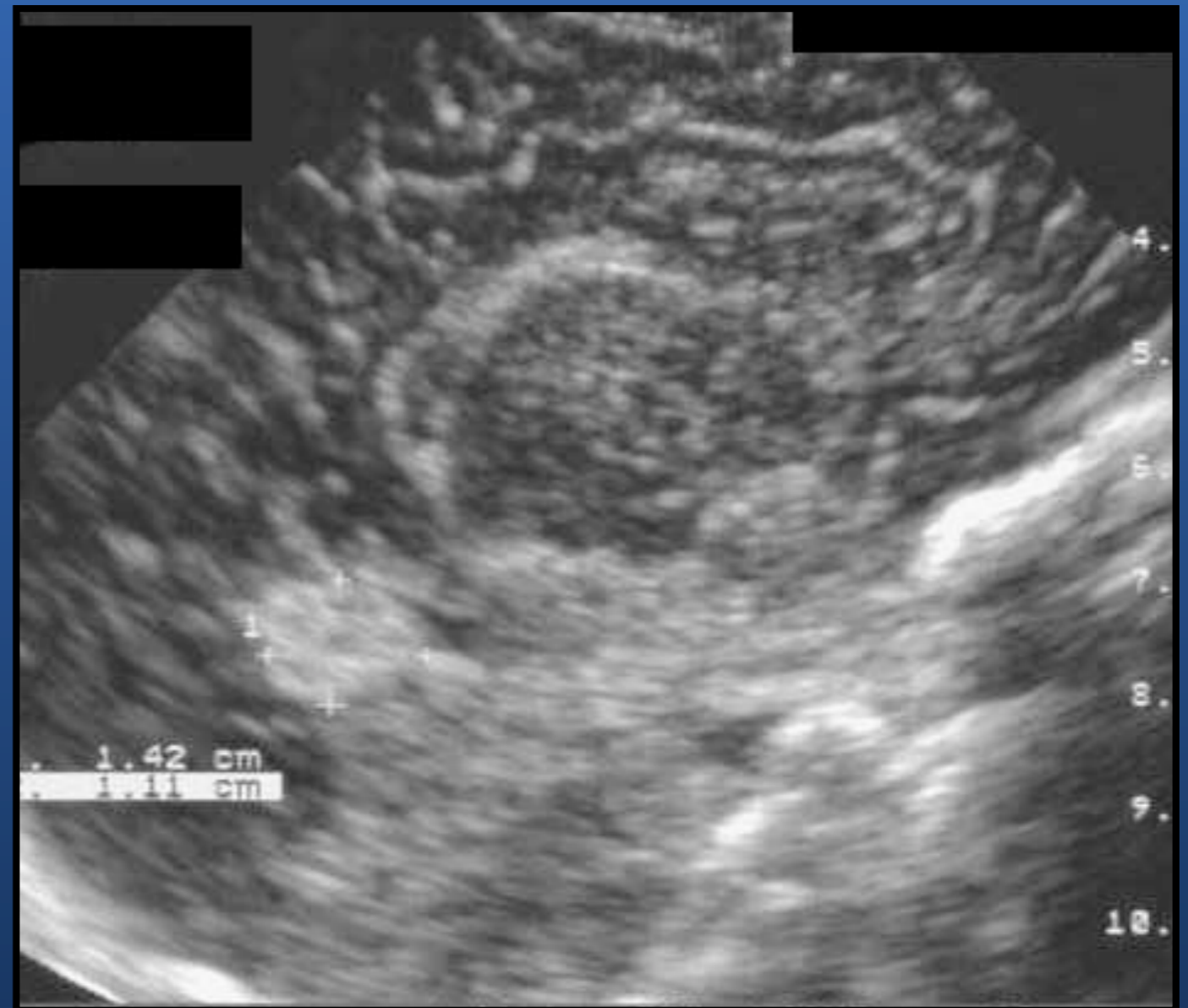
Méningite complications : abcès

- Lésion échogène
- Bords flous puis nets
- Effet de masse



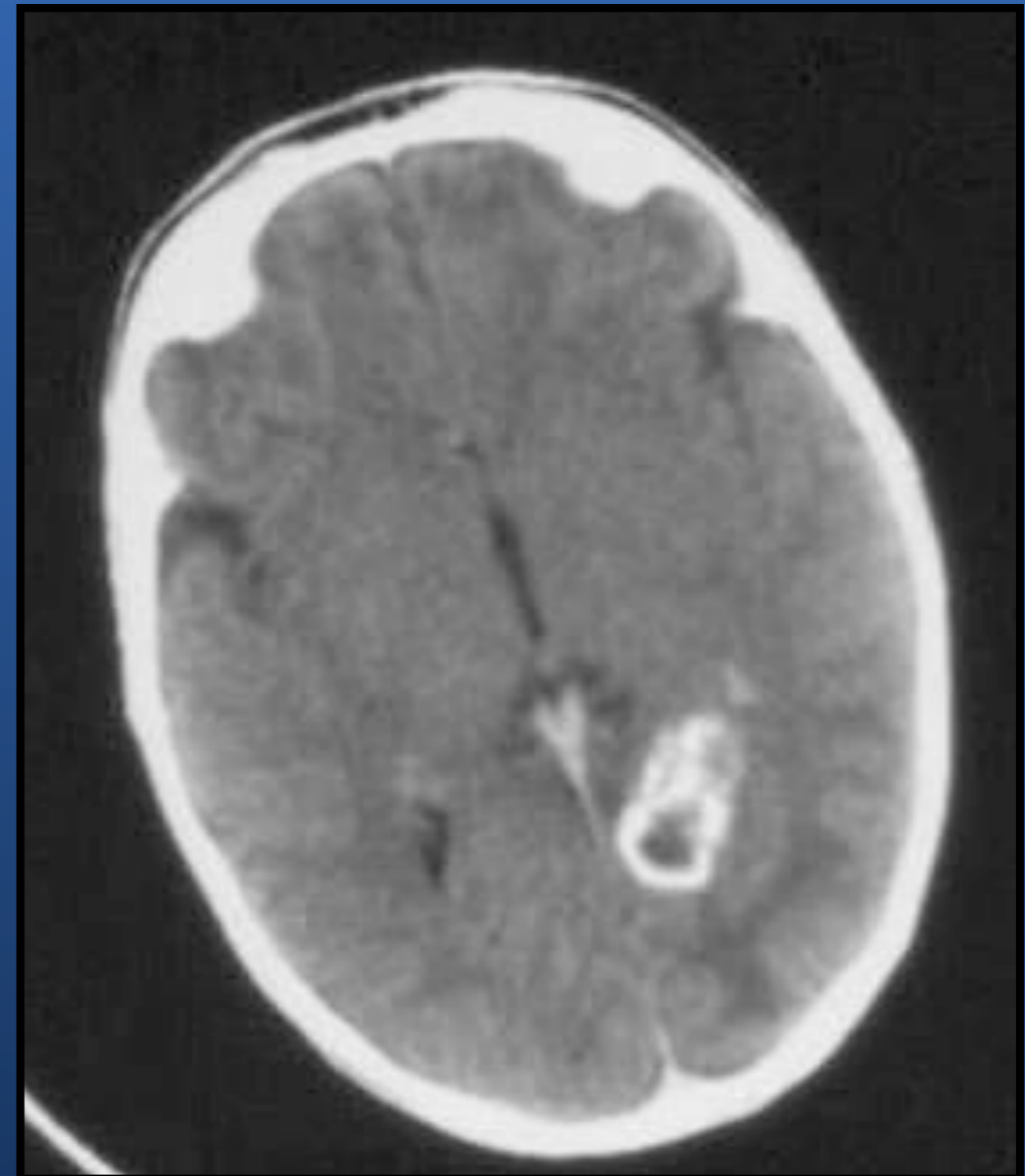
Méningite complications : abcès

- Lésion échogène
- Bords flous puis nets
- Effet de masse



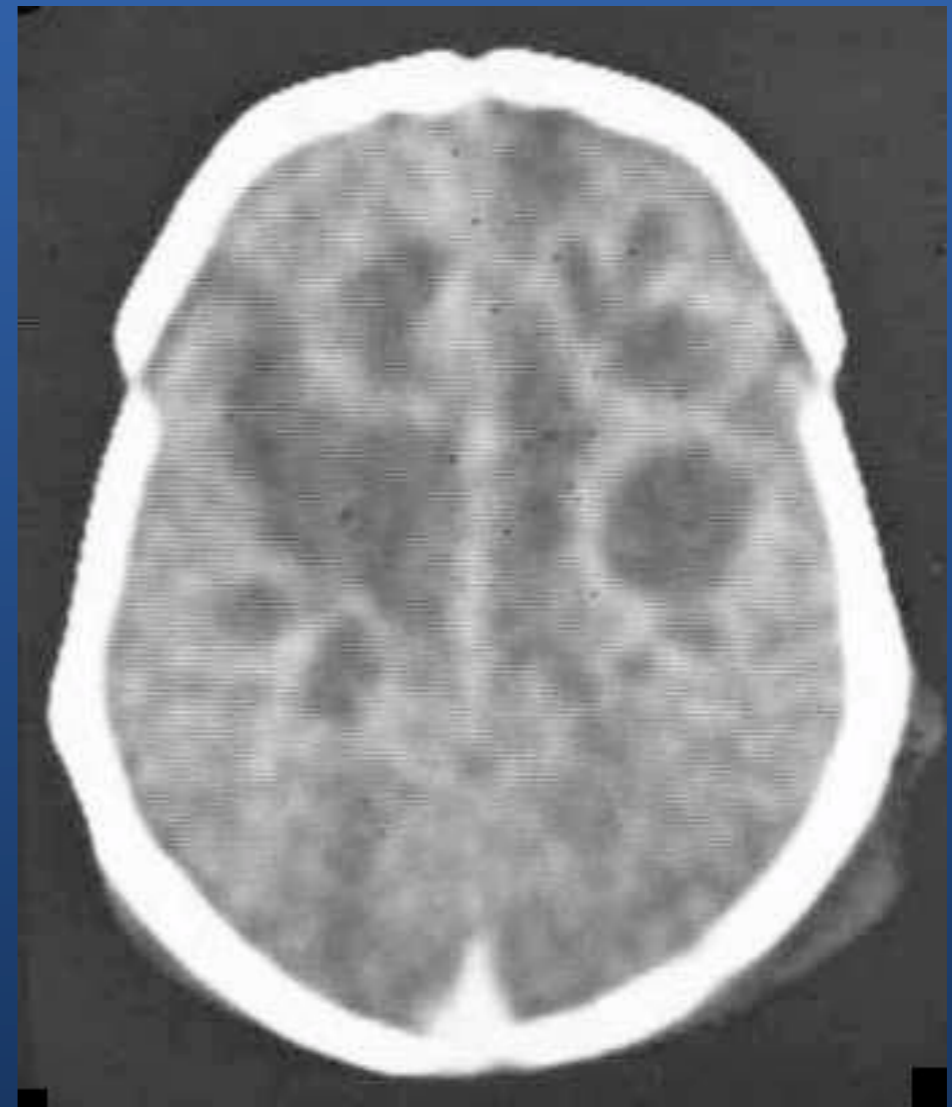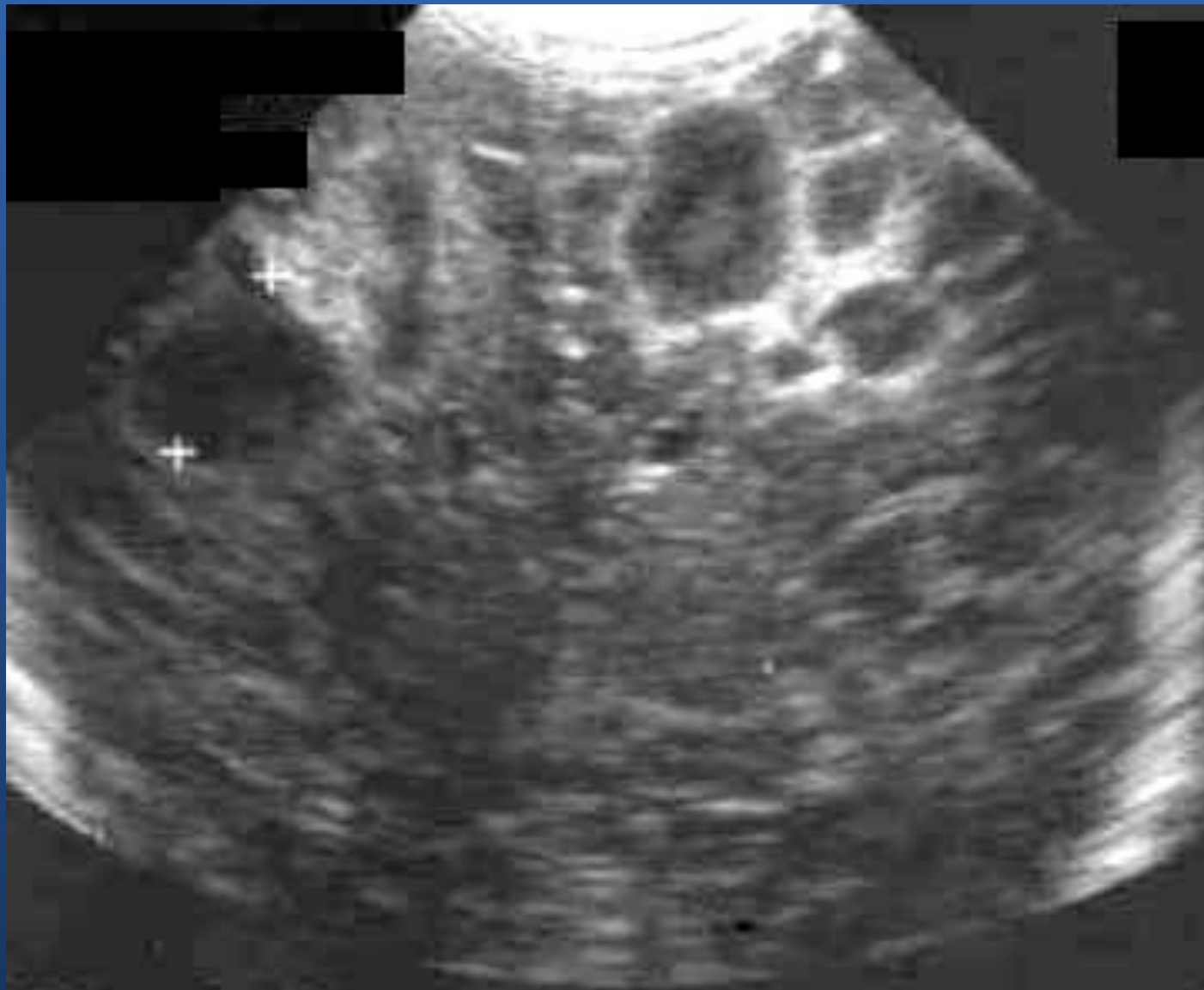Méningite complications : abcès

- Lésion échogène
- Bords flous puis nets
- Effet de masse



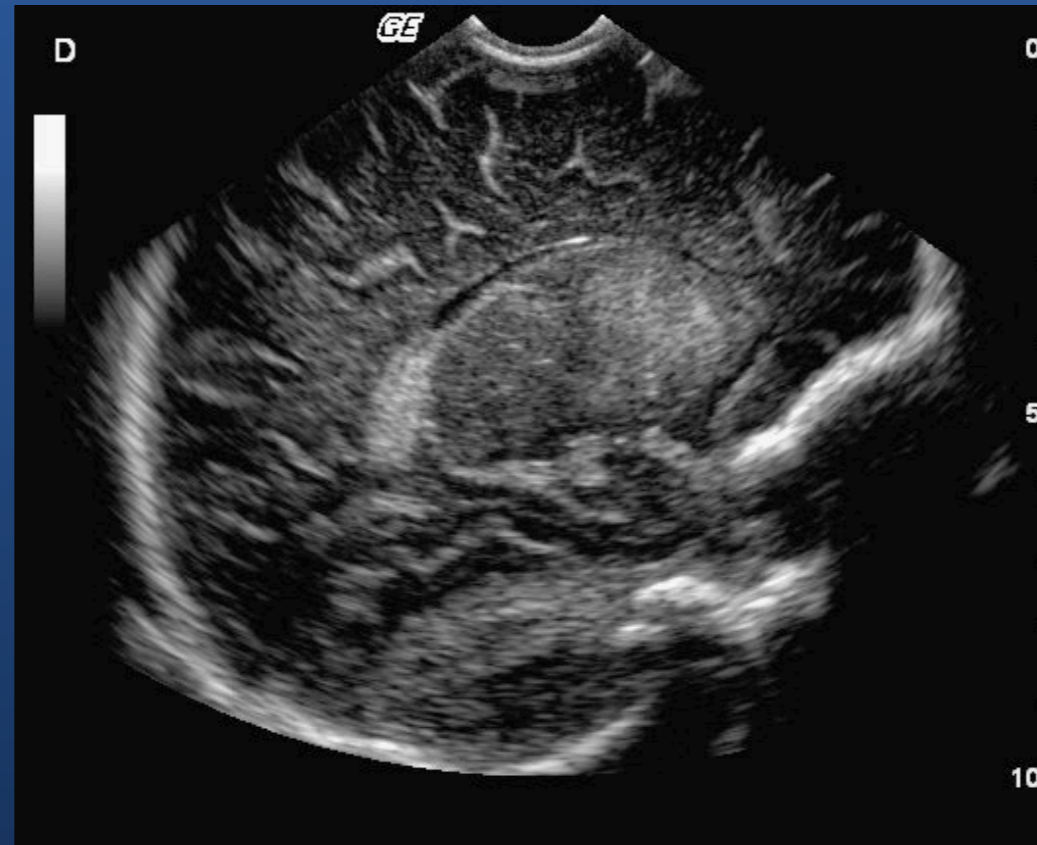
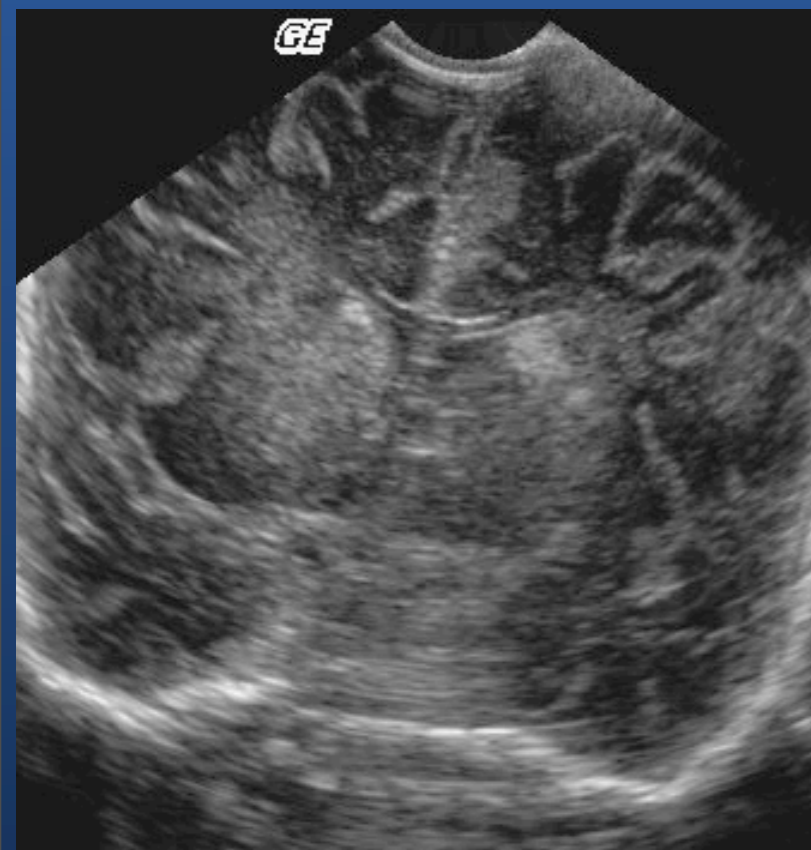
ABCES

- Evolution vers kystisation



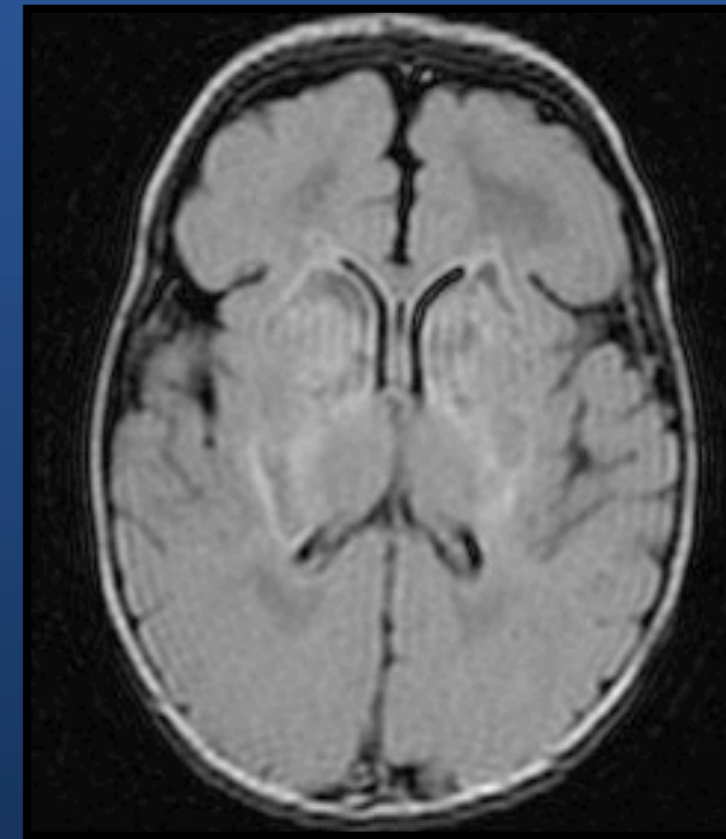
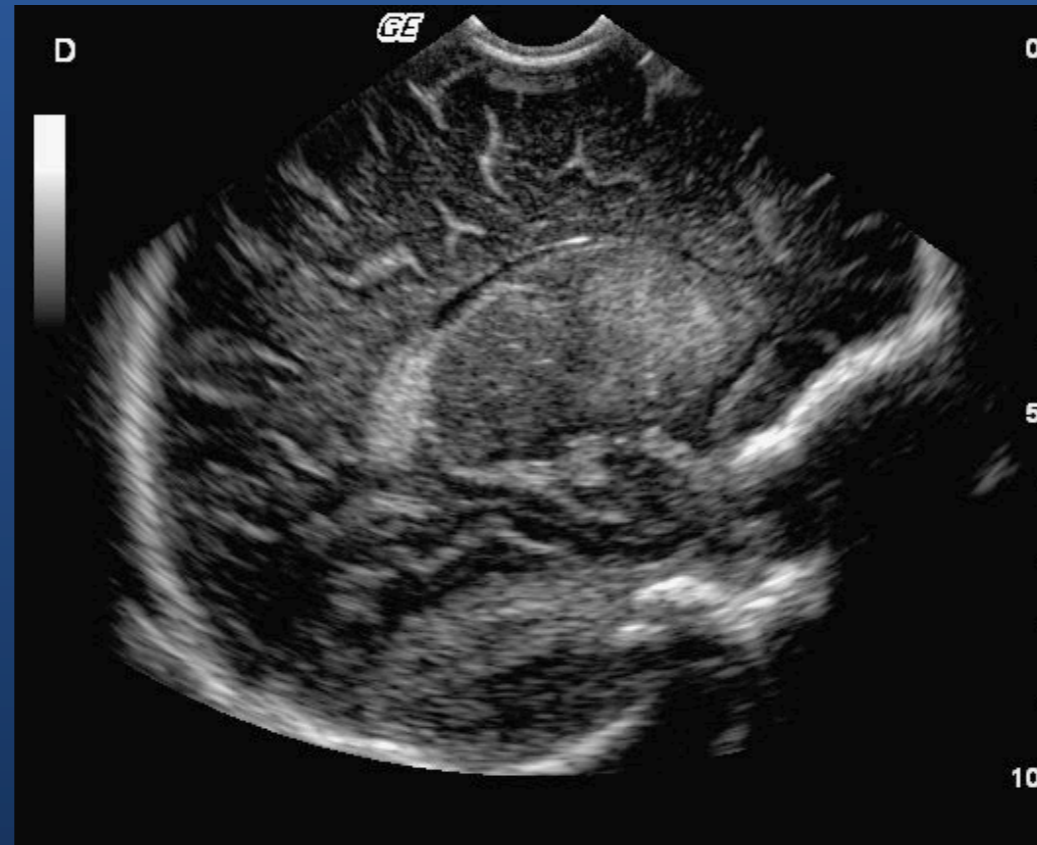
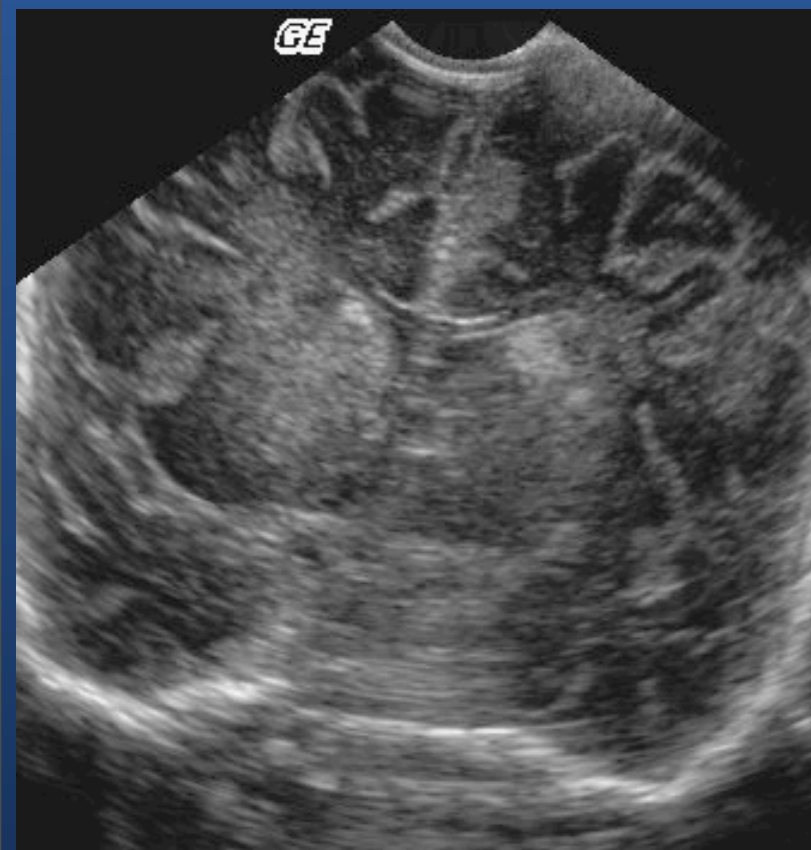
Méningite : complications lésions vasculaires aseptiques

- Infarctus veineux : images échogènes en lacher de ballon
- Lésions ischémiques images échogènes en motte atteinte des noyaux gris dans les formes sévères

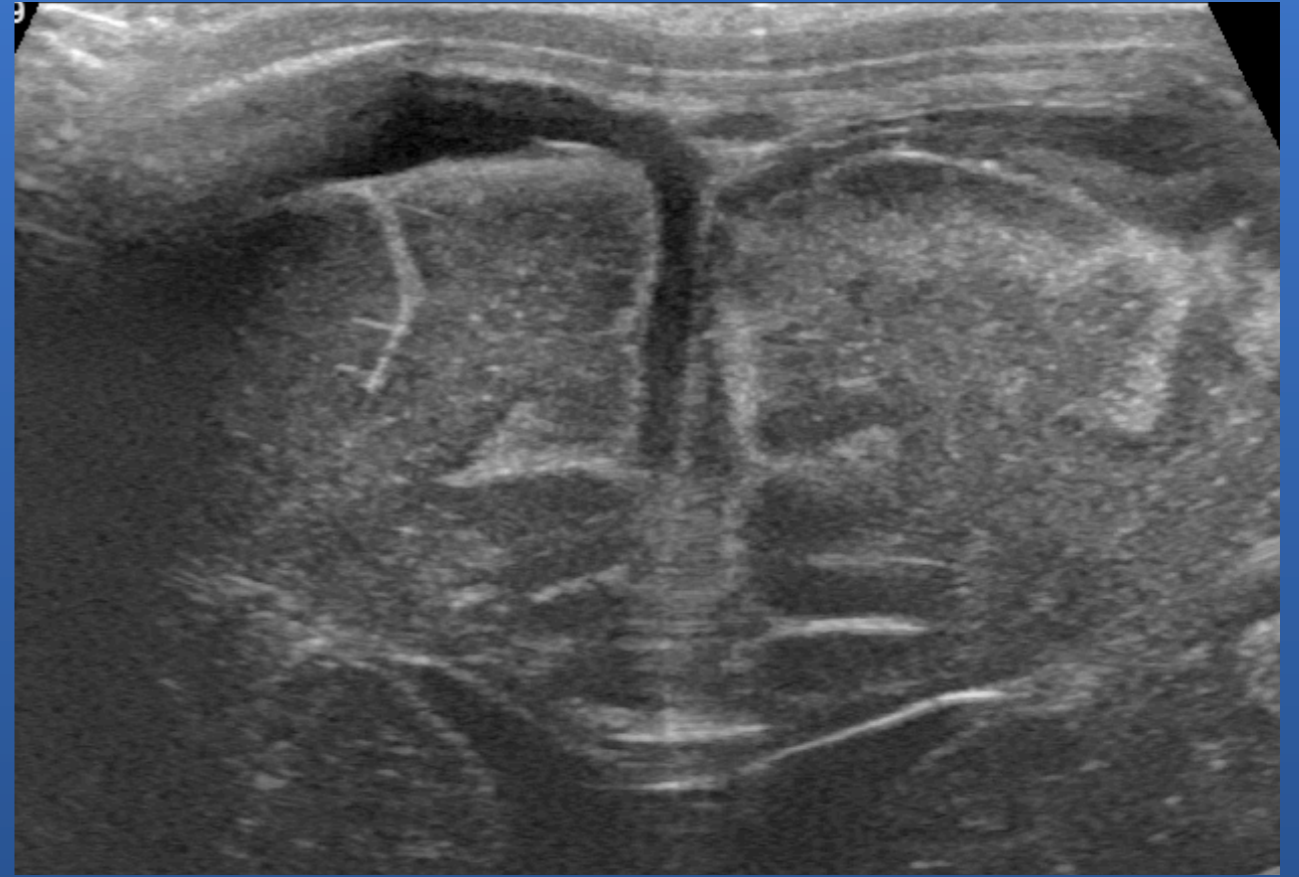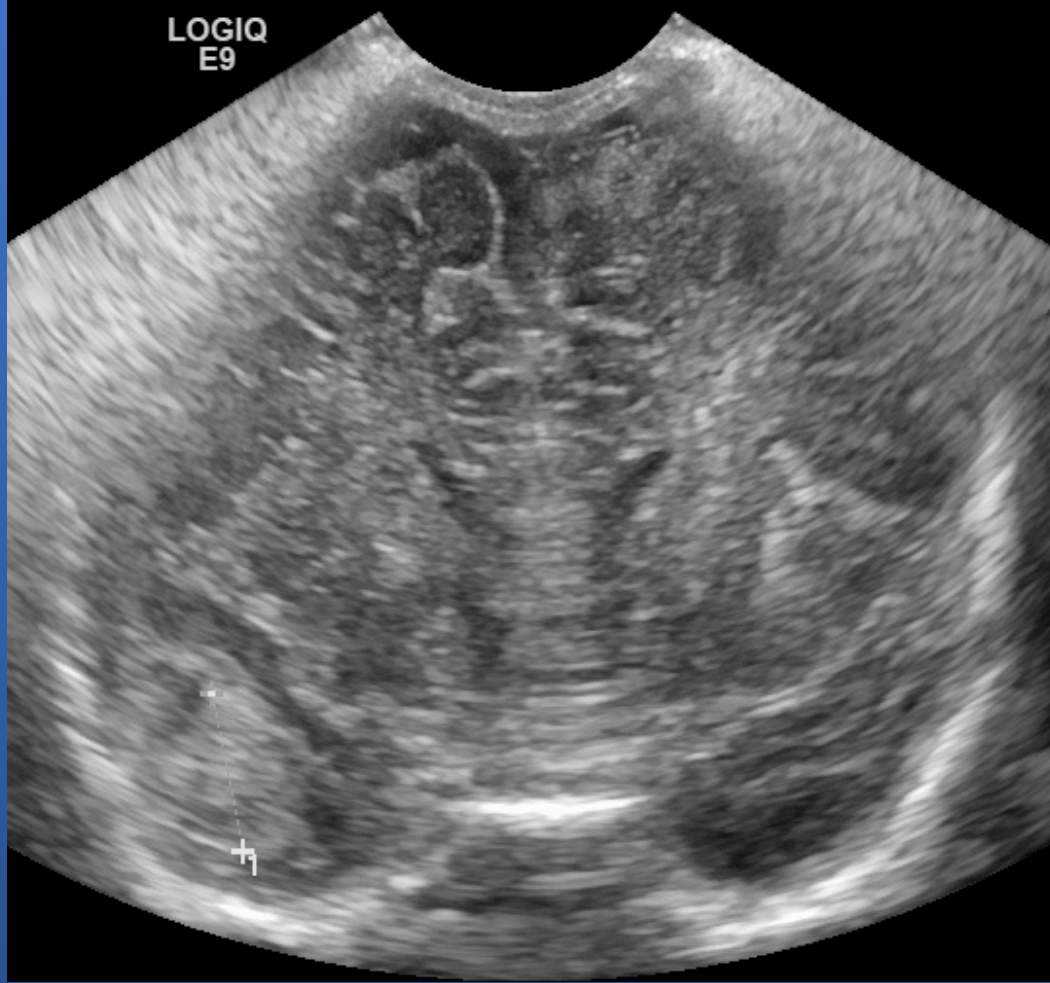


Méningite : complications lésions vasculaires aseptiques

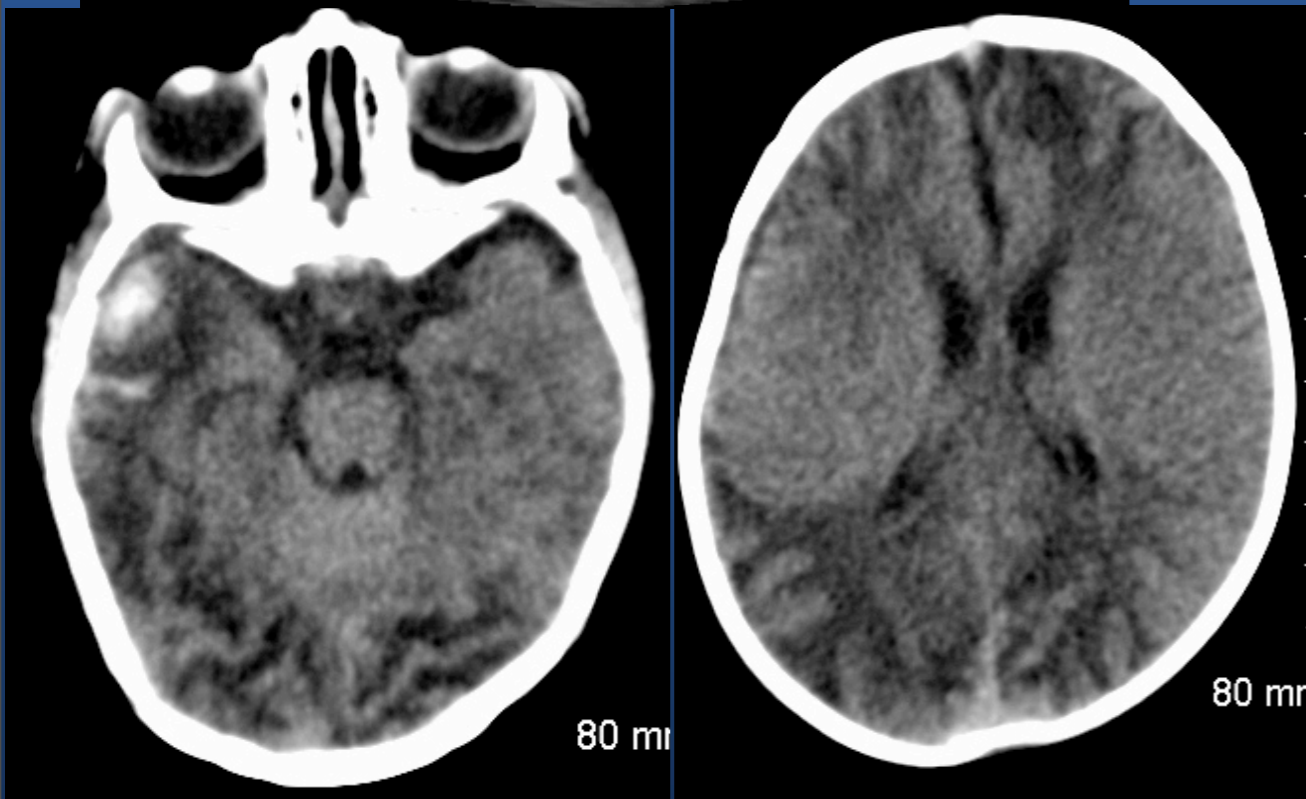
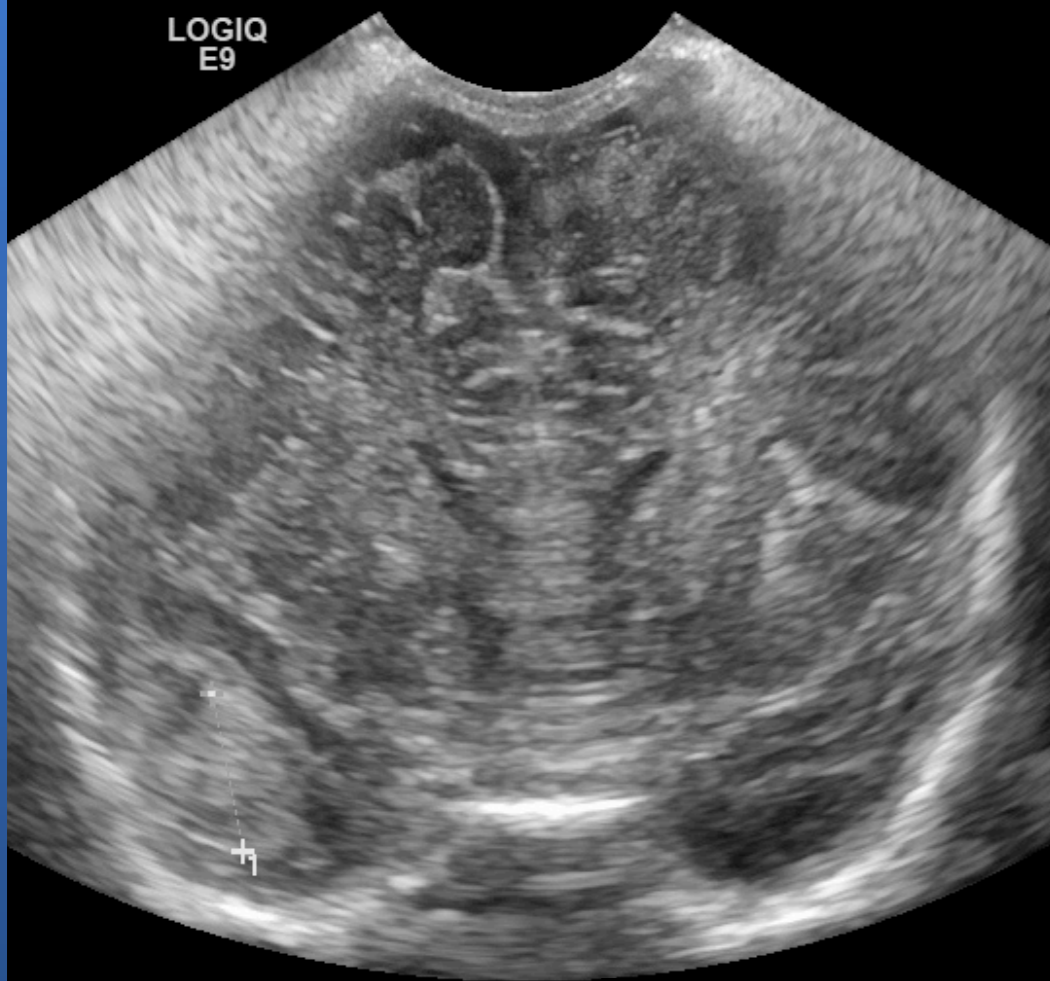- Infarctus veineux : images échogènes en lacher de ballon
- Lésions ischémiques images échogènes en motte atteinte des noyaux gris dans les formes sévères



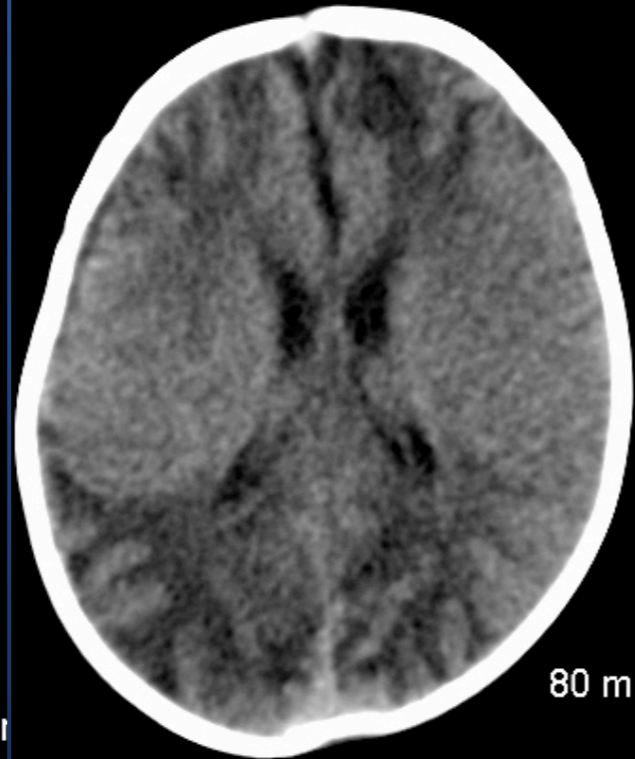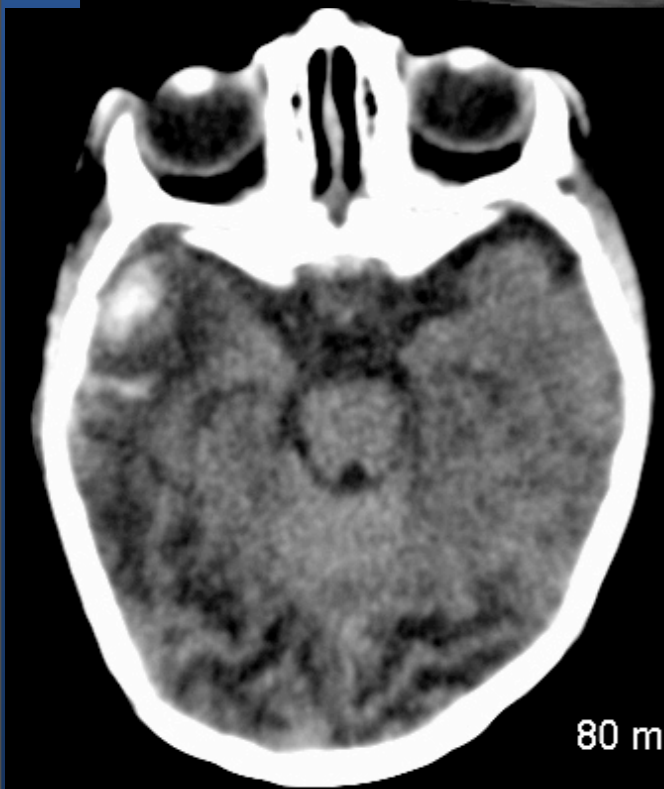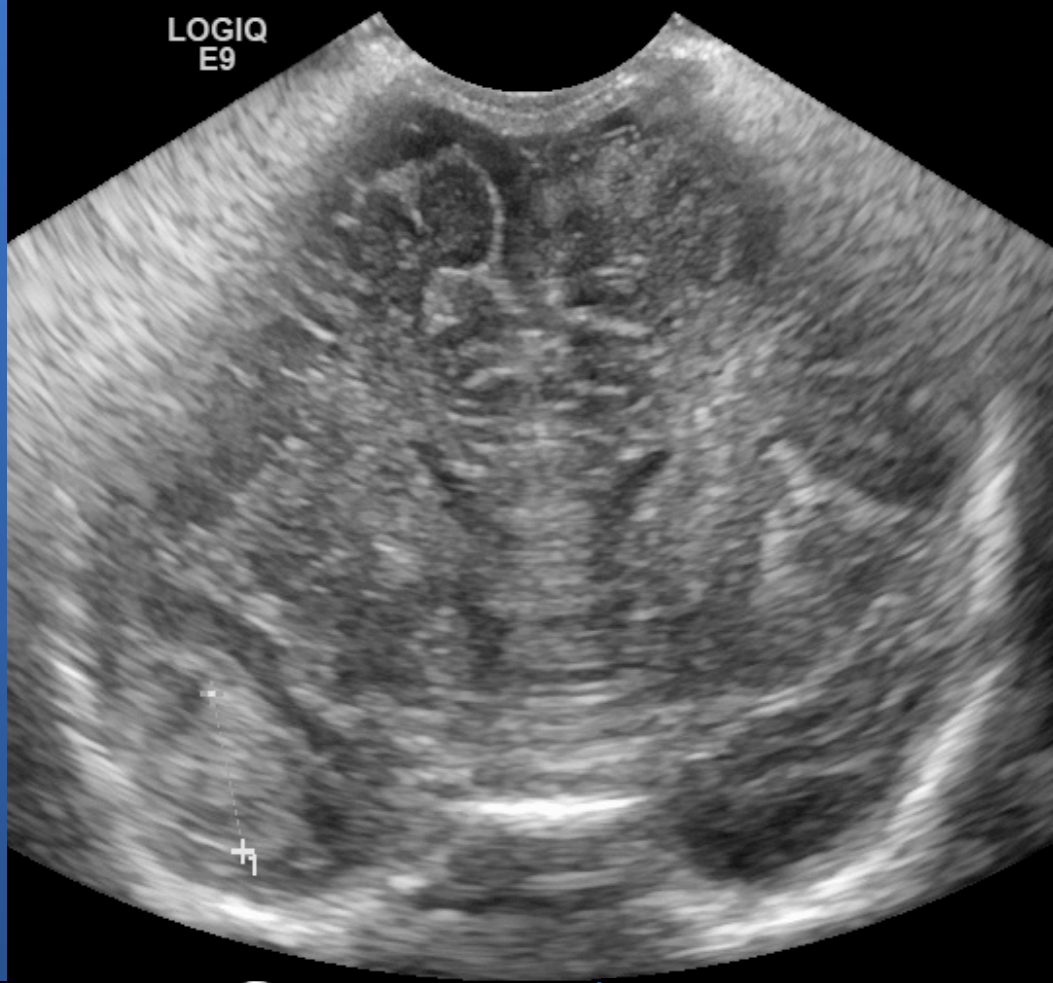
Streptocoque B



Streptococcus B

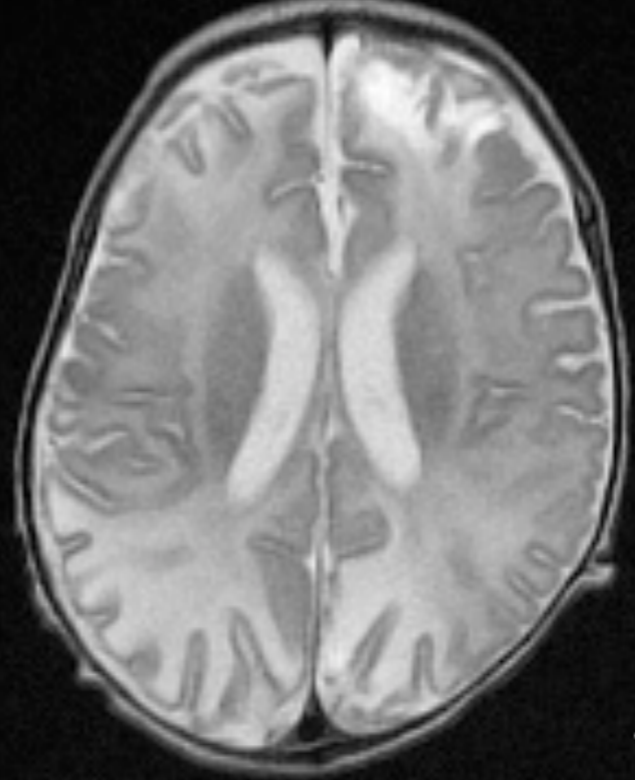


Streptococcus B

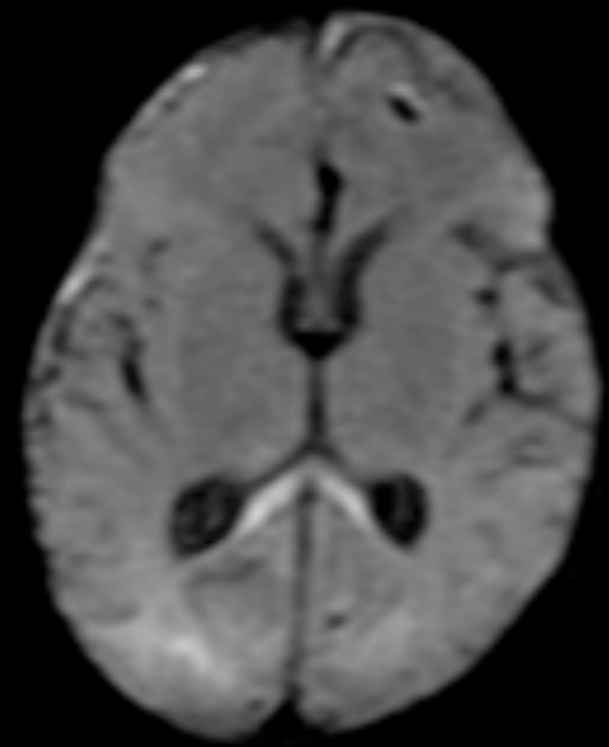


80 m

80 m



100



MALFORMATIONS

- **Recherche systématique**
- **Orientée par :**
 - **DAN**
 - **contexte clinique (convulsions, macrocranie ...)**
- **Totalité de l'encéphale :**
 - **La ligne médiane**
 - **Les hémisphères**
 - **La fosse postérieure**
- **IRM : examen de référence**

SEMIOLOGIE DES MALFORMATIONS :

ECHO +/- PERFORMANTE

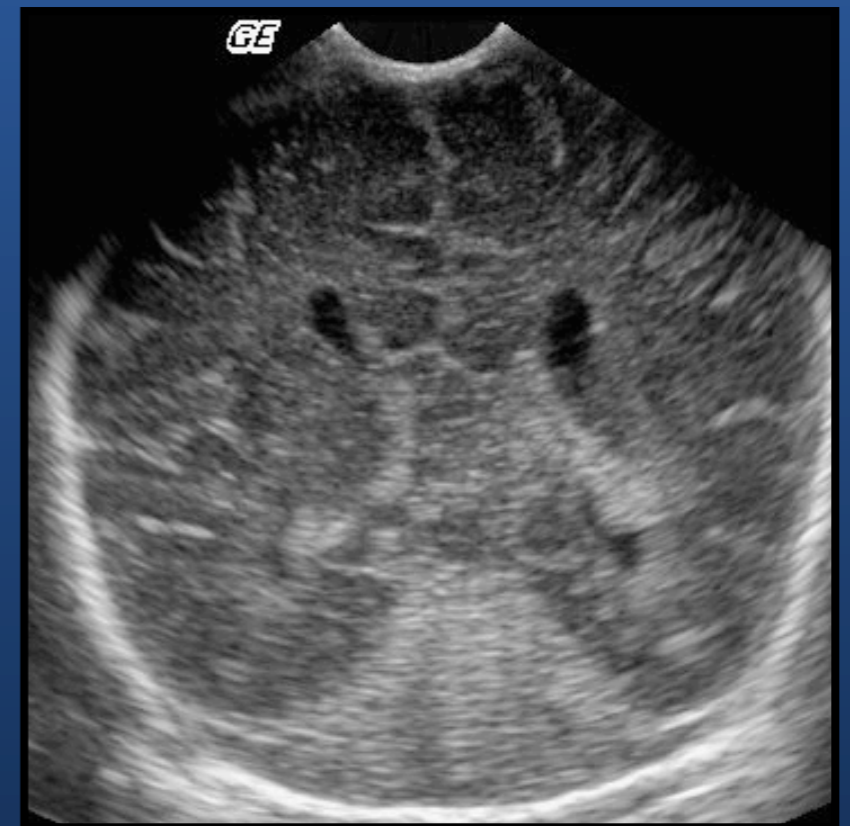
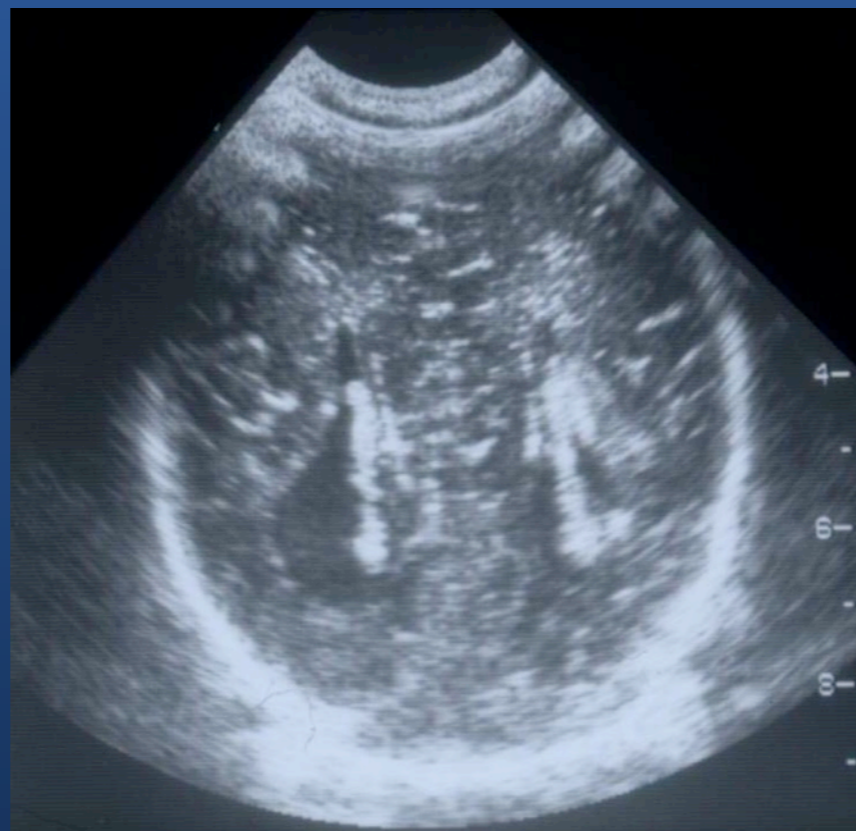
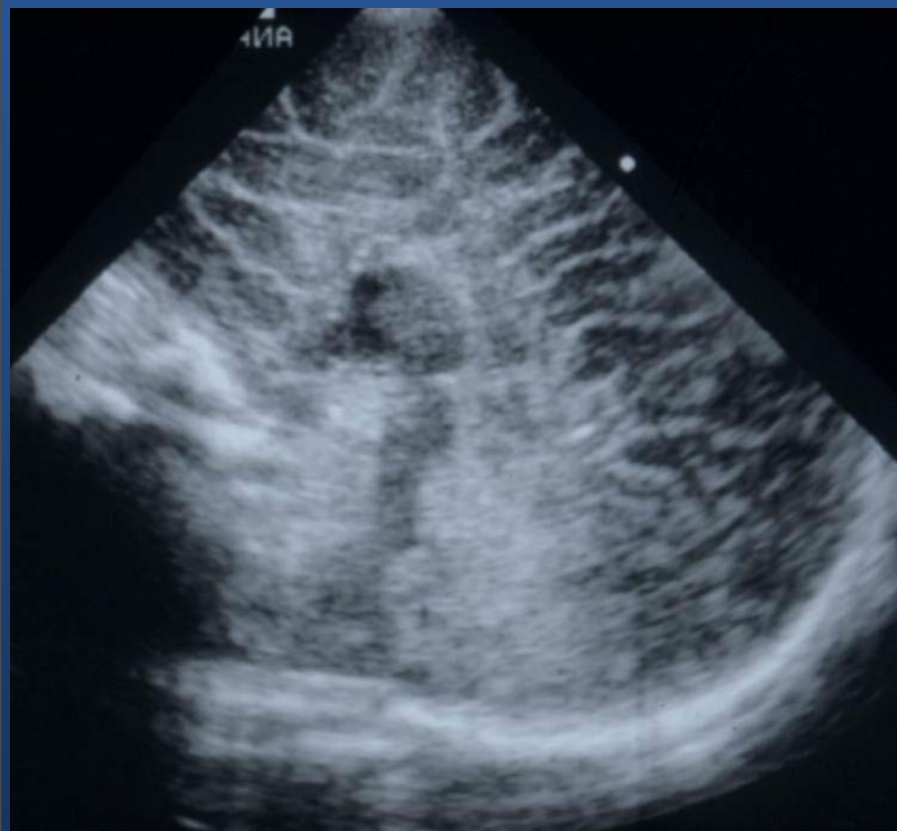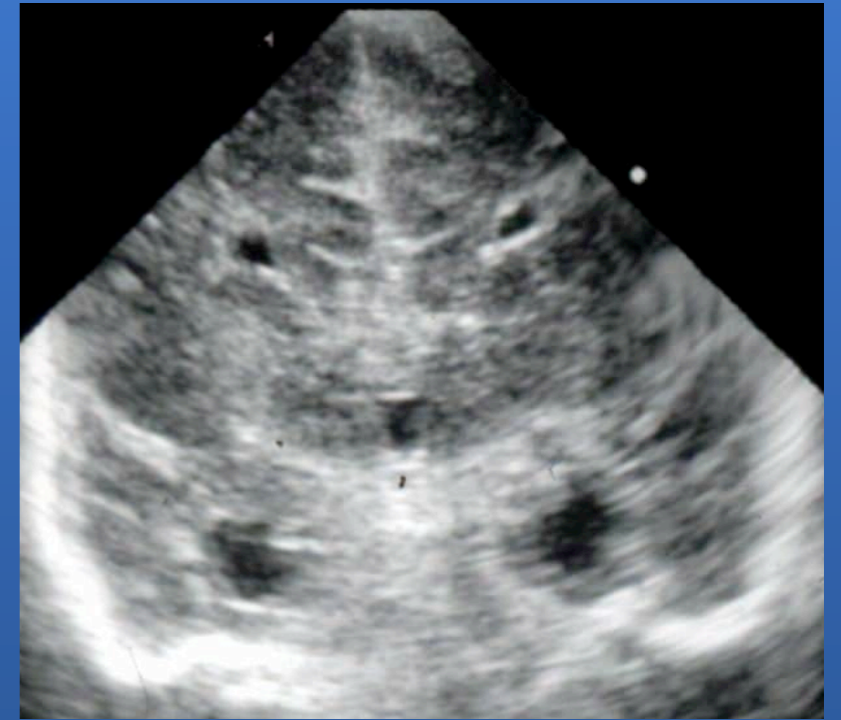
- **Image liquidienne**
 - dilatation ventriculaire
 - malformation de la fosse postérieure
- **Anomalie de la ligne médiane: corps calleux**
- **Anomalie de la fosse postérieure ?**
- **Anomalie hémisphérique ???**

Agénésie du Corps Calleux

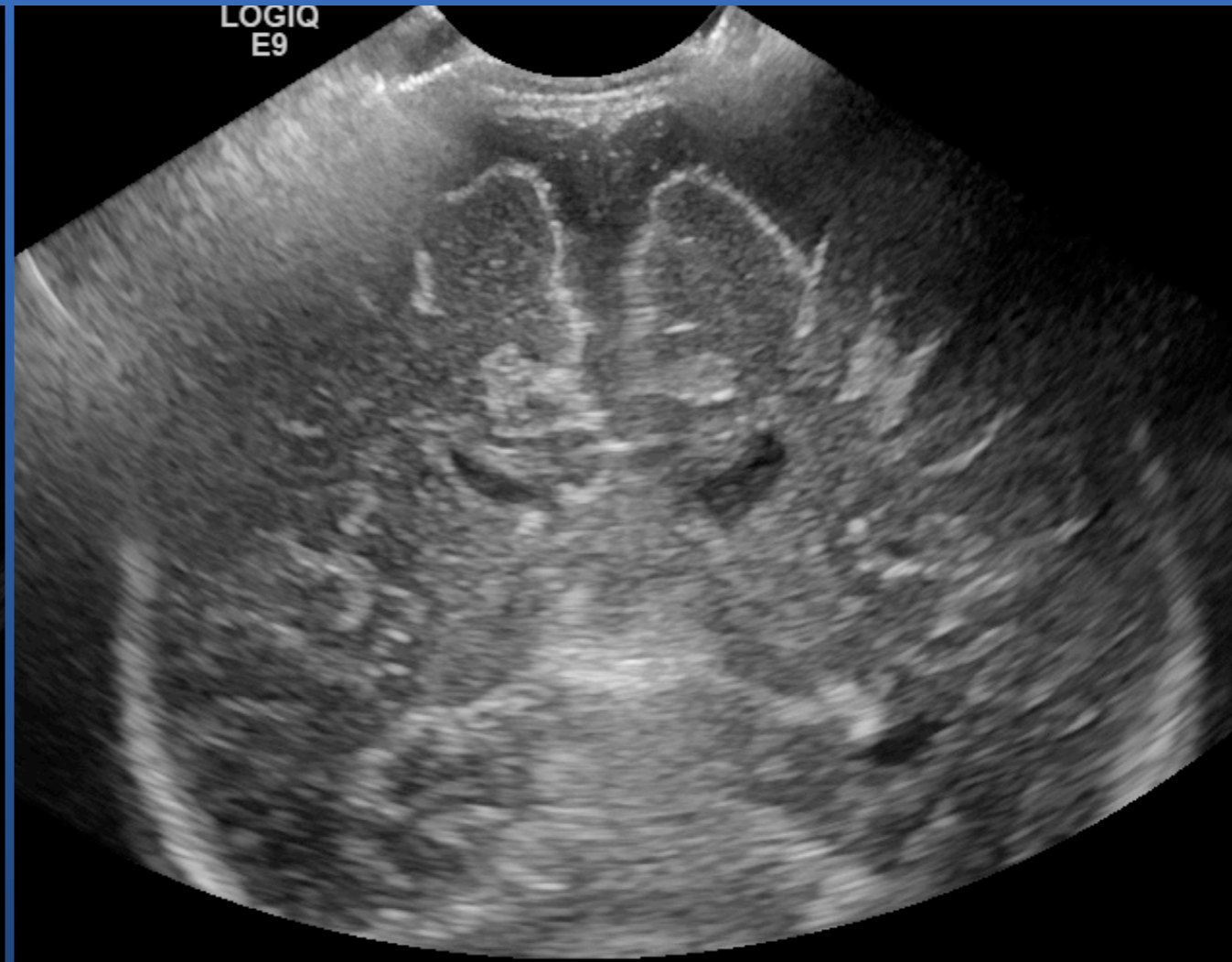
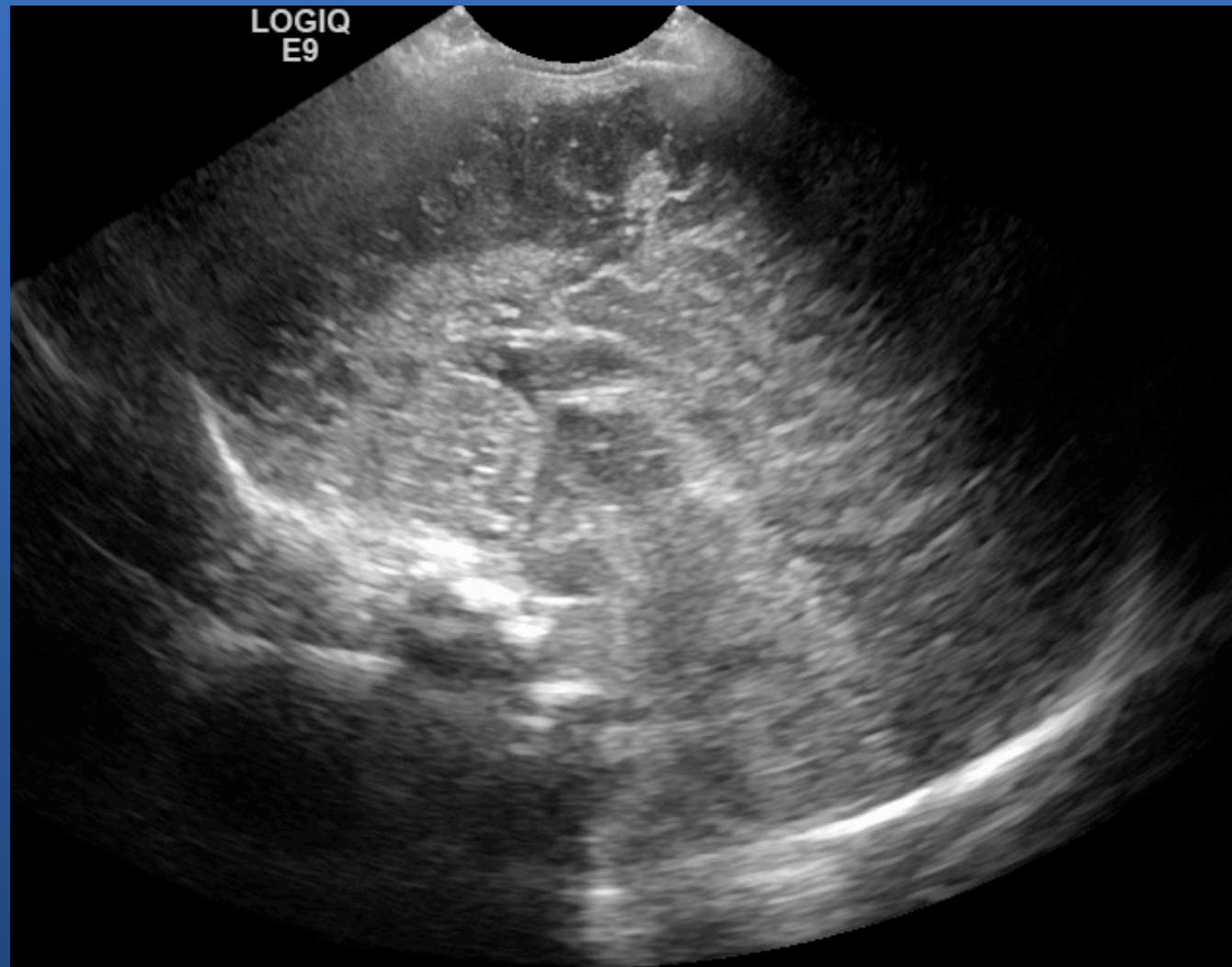
- **Forme totale : diagnostic facile**
- **Forme partielle : difficulté diagnostique**
 - postérieure
 - +/- étendue
- **malformation associée : pronostic**
 - Lipome, kyste interhémisphérique
 - malformation de la fosse postérieure
 - holoprosencéphalie
 - troubles de gyration

Malformations : ACC

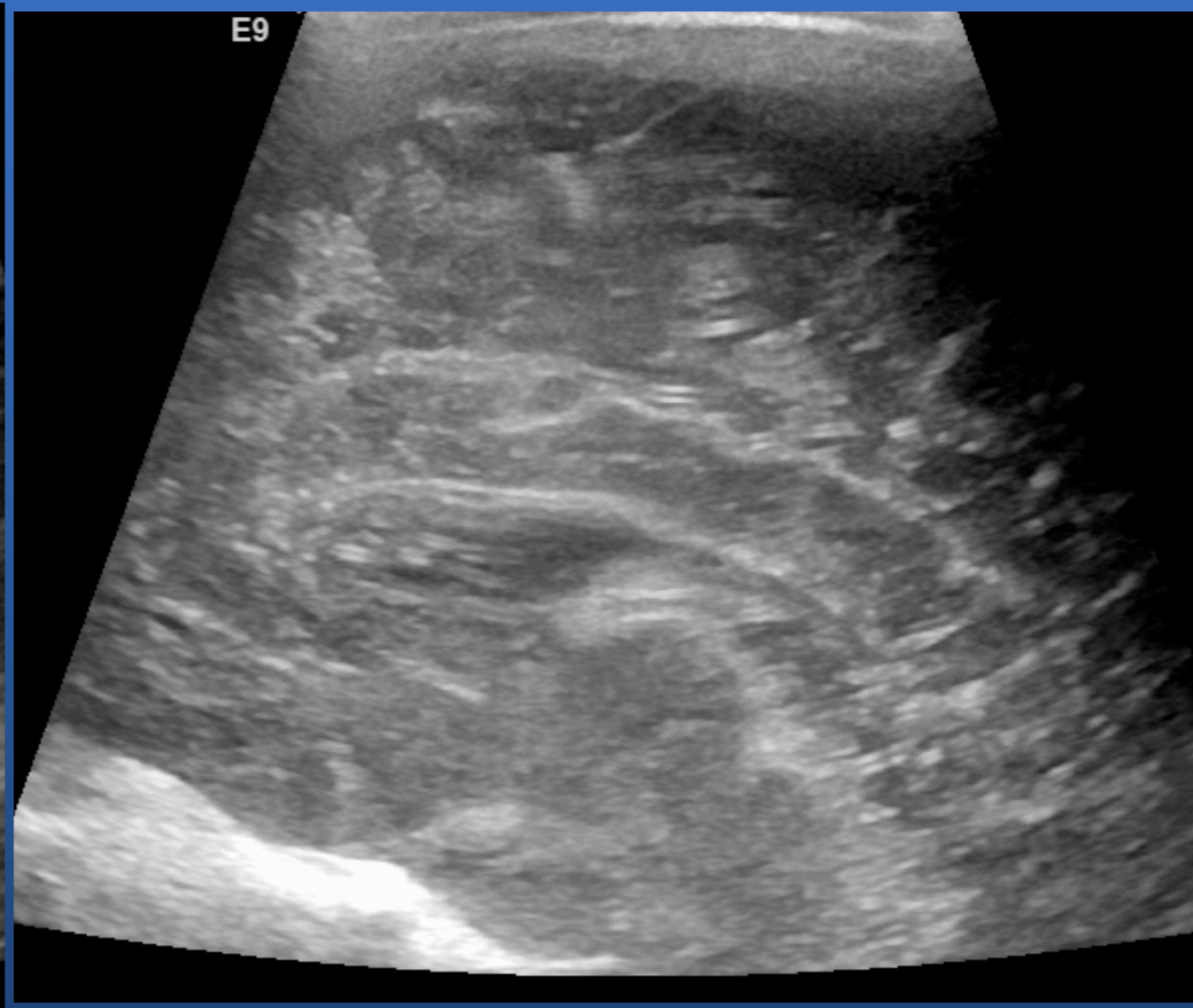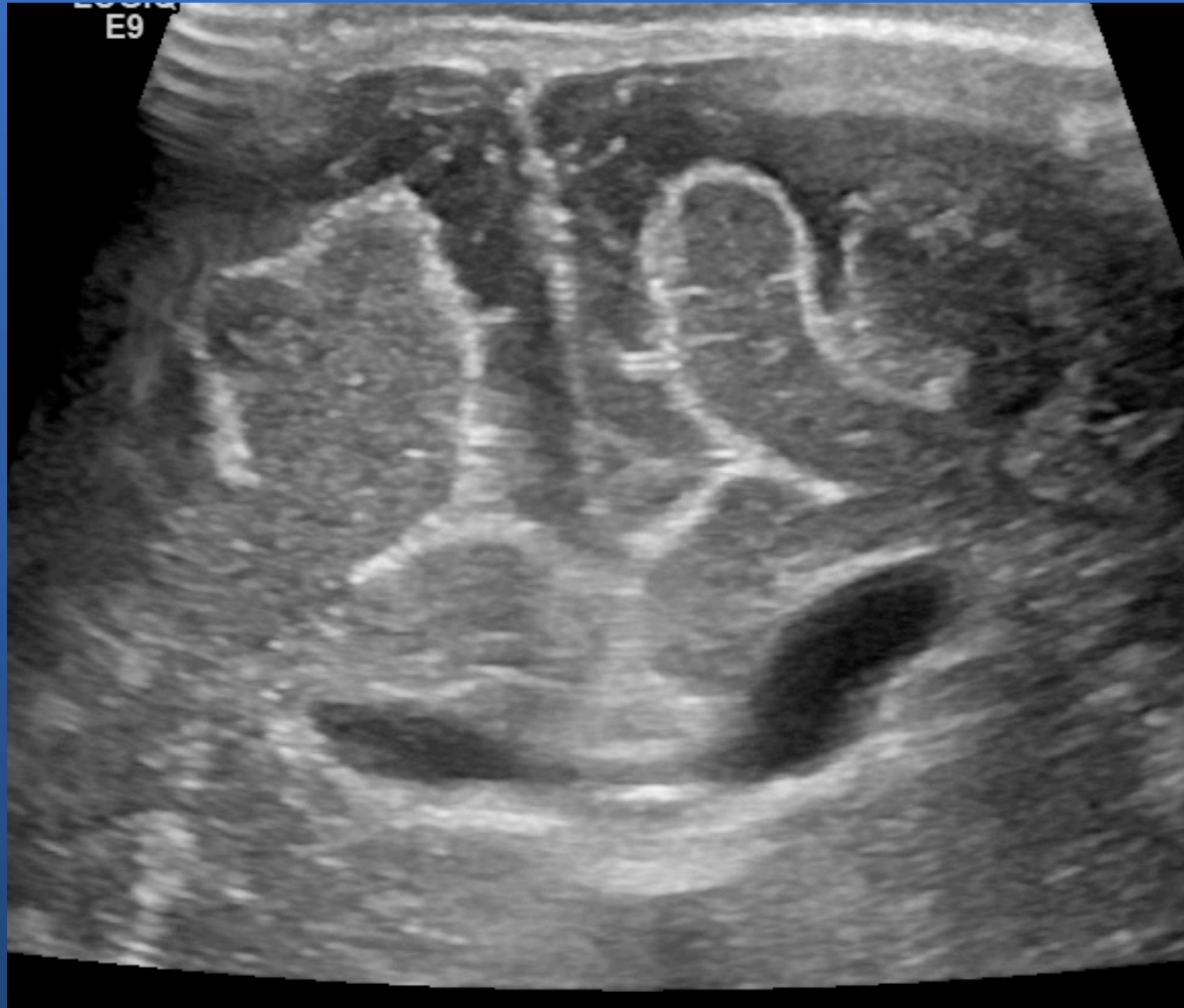- **Signe direct pas de corps calleux**
- **Signes indirects :**
 - **Ventricules parallèles**
 - **En corne de taureau**
 - **+/- Ascension V3**
 - **Sillons en rayon de roue**

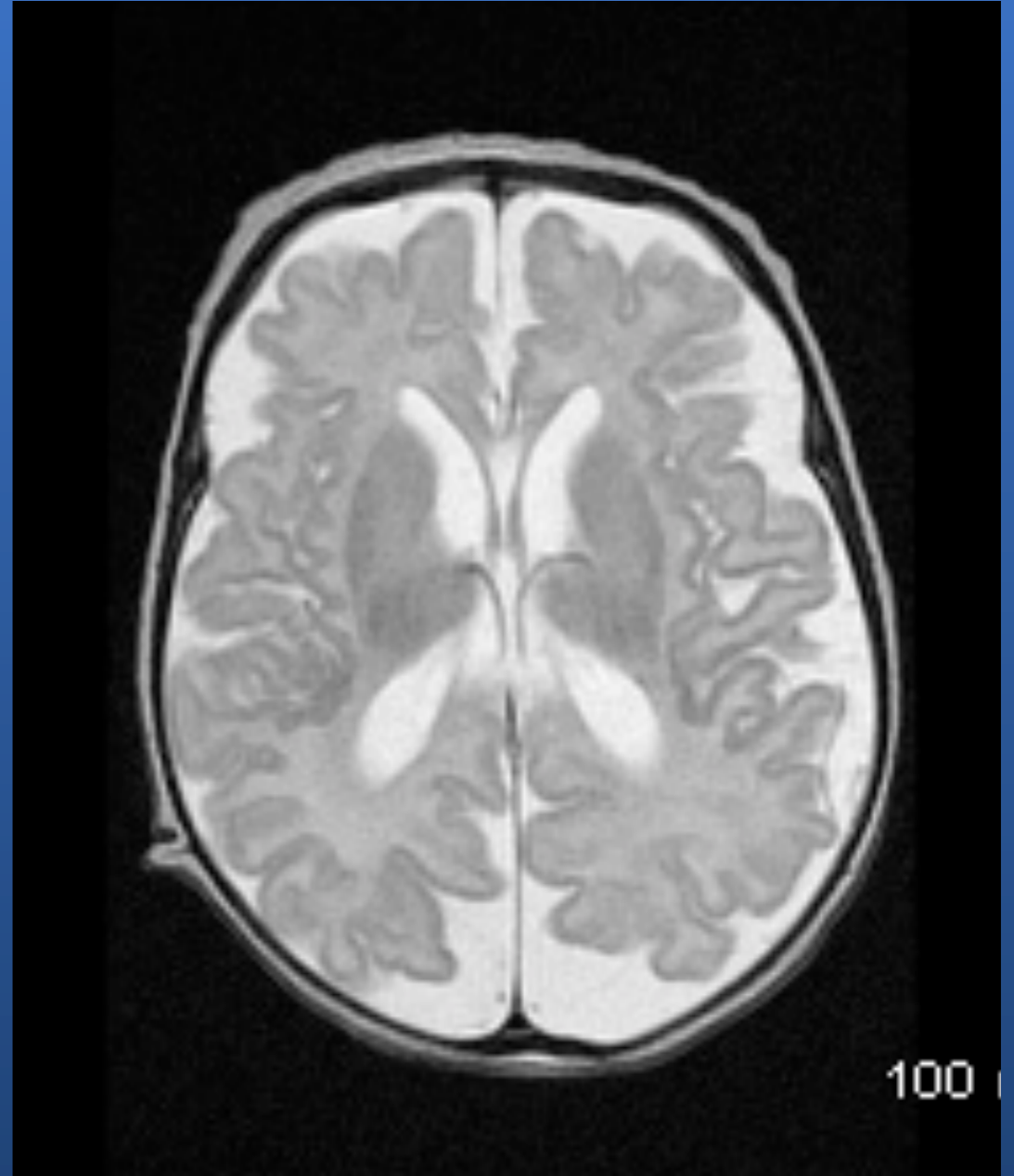
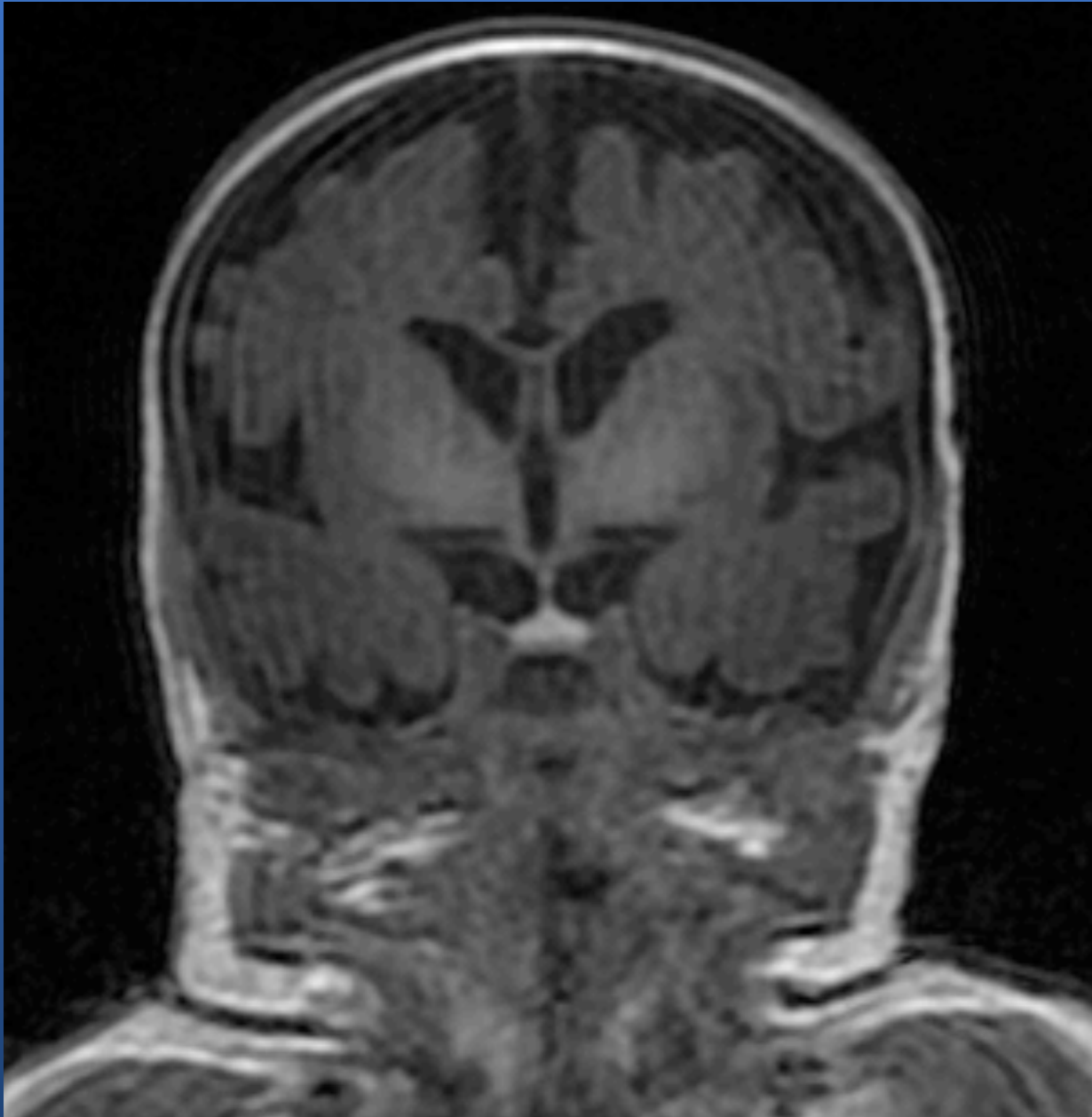


Convulsions ACC?

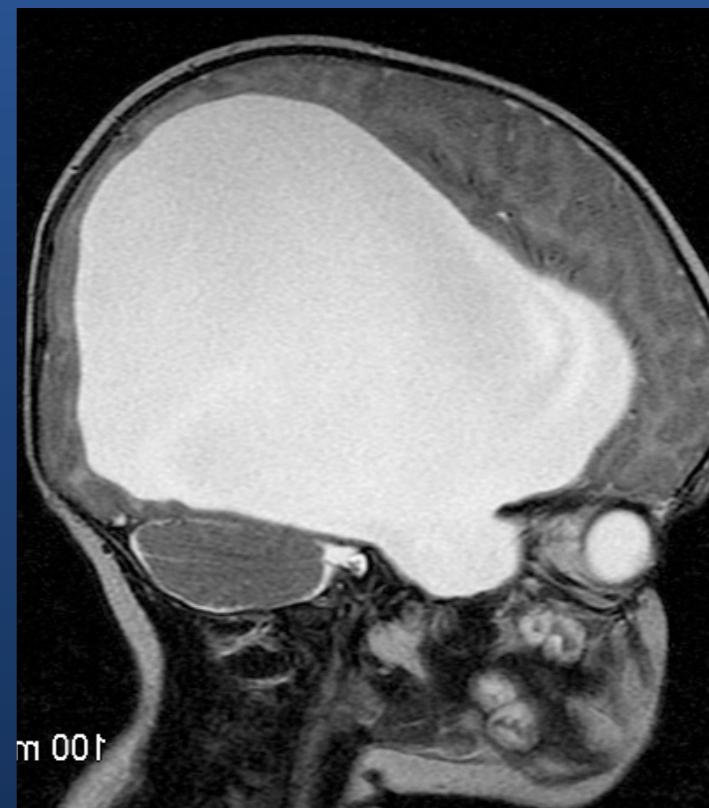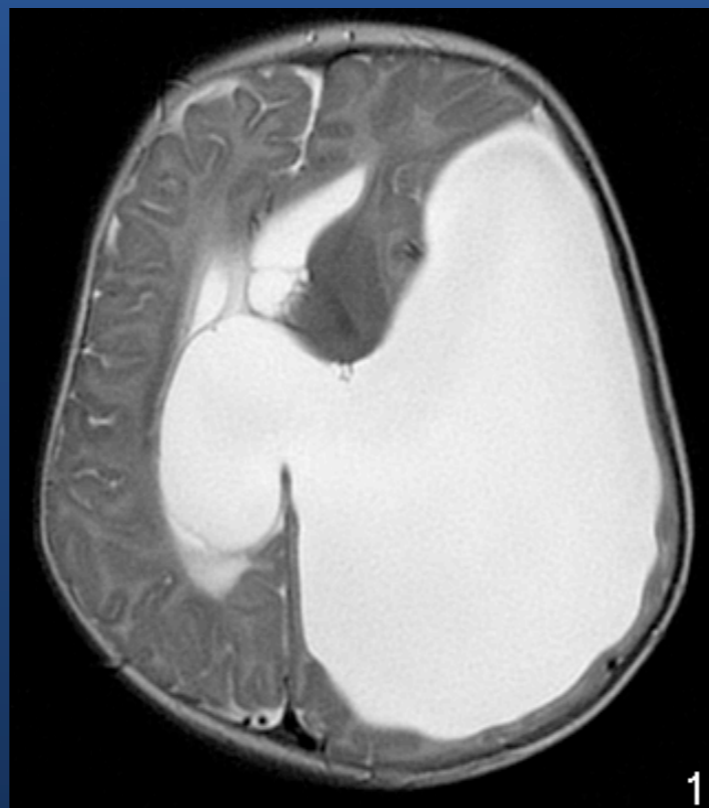
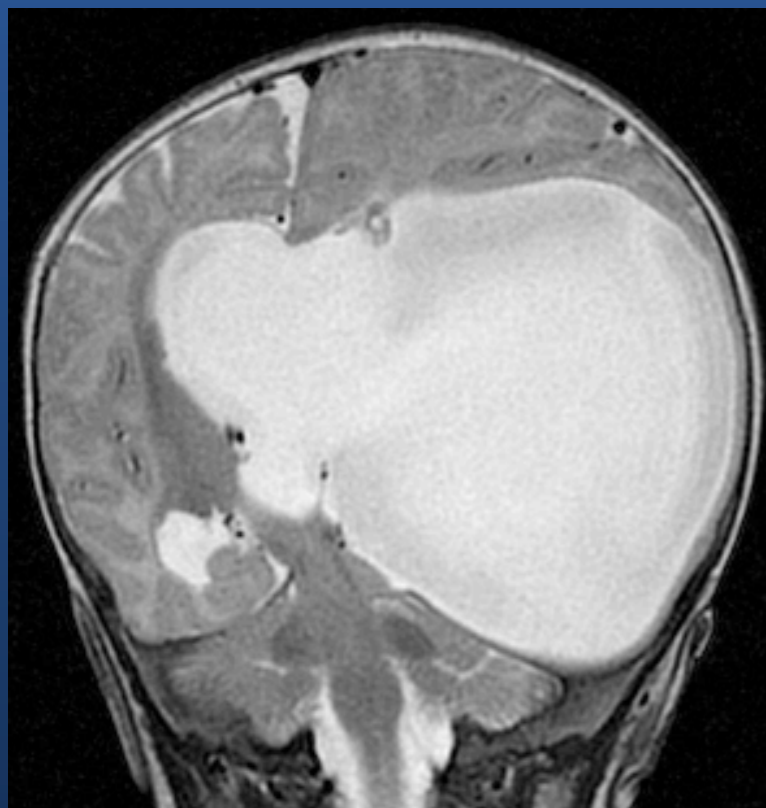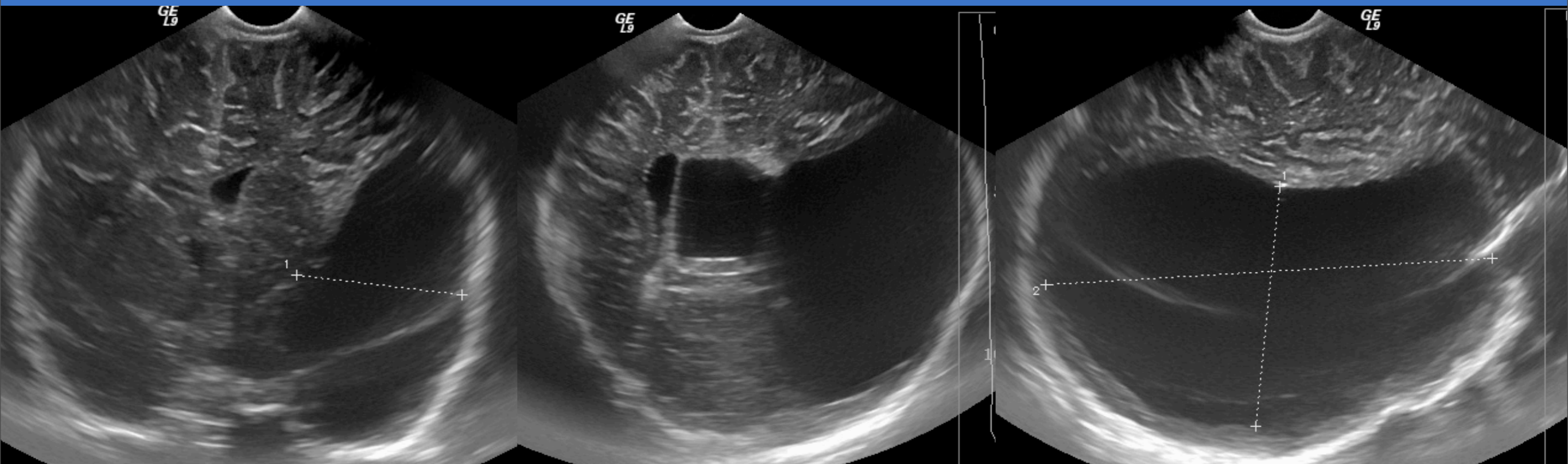


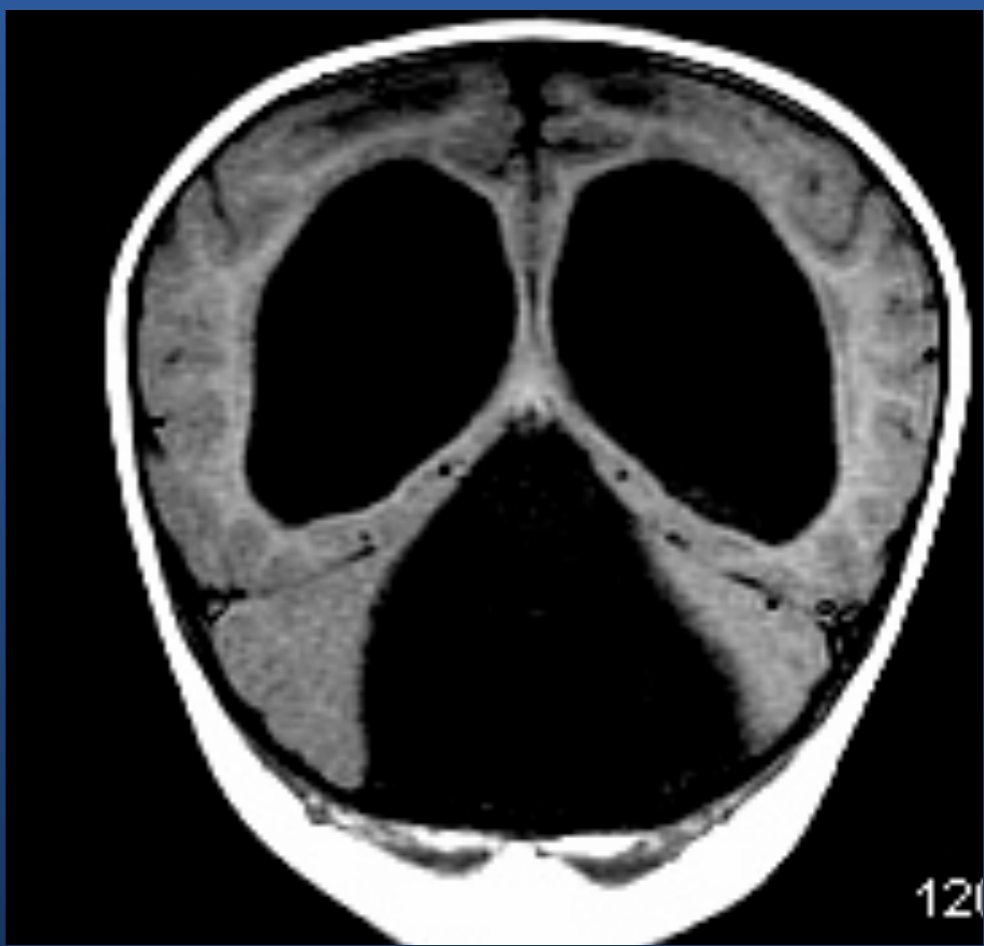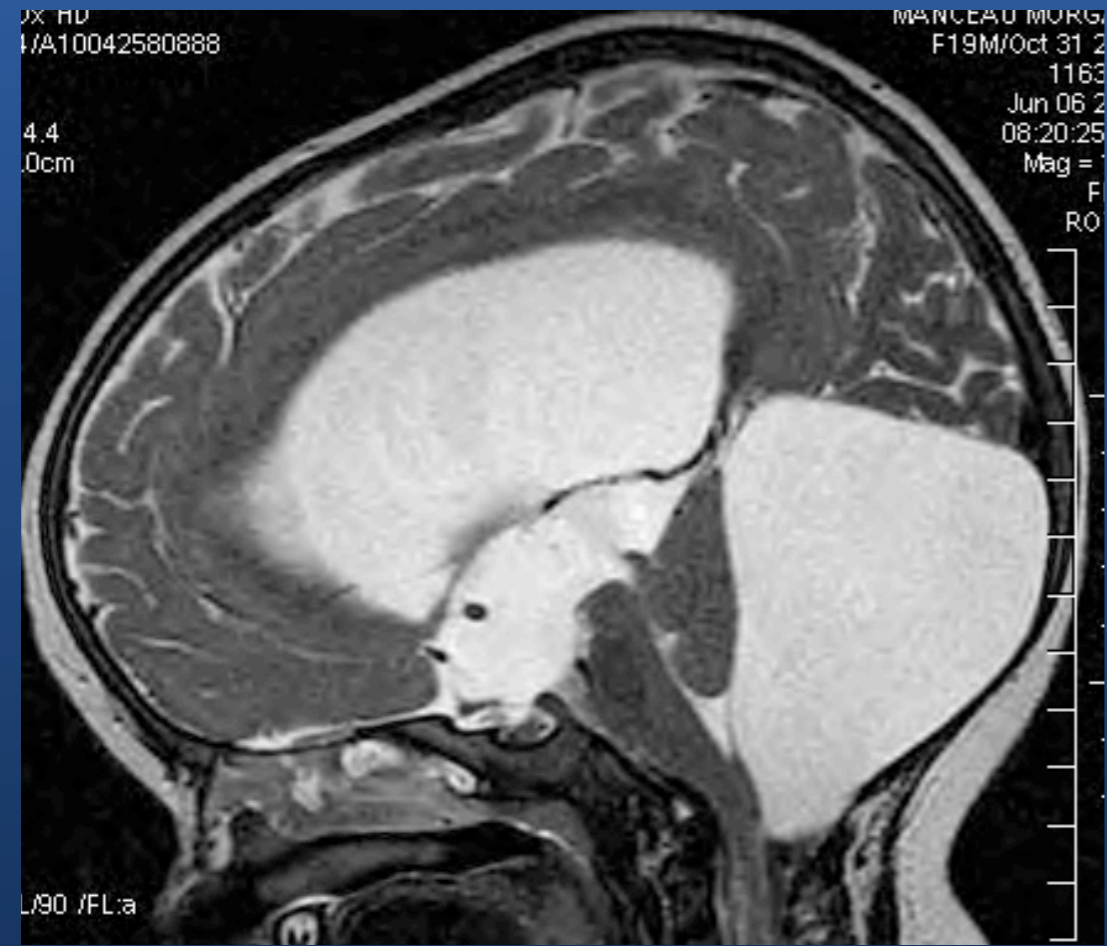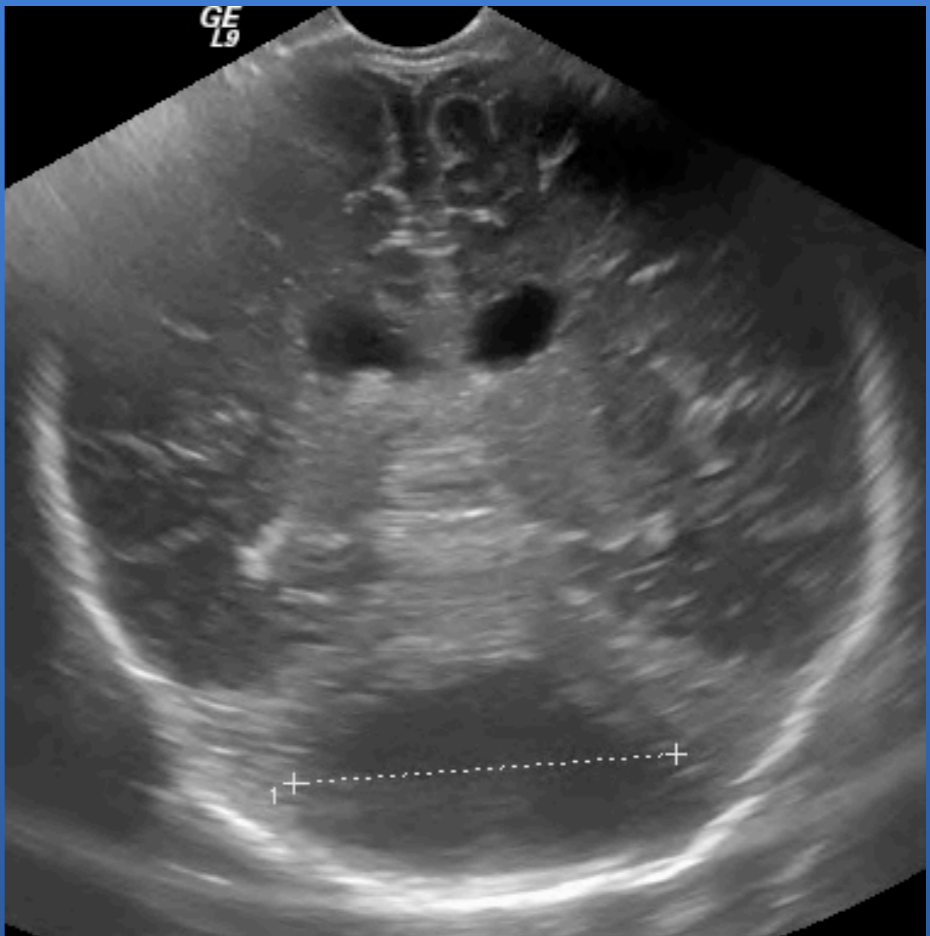
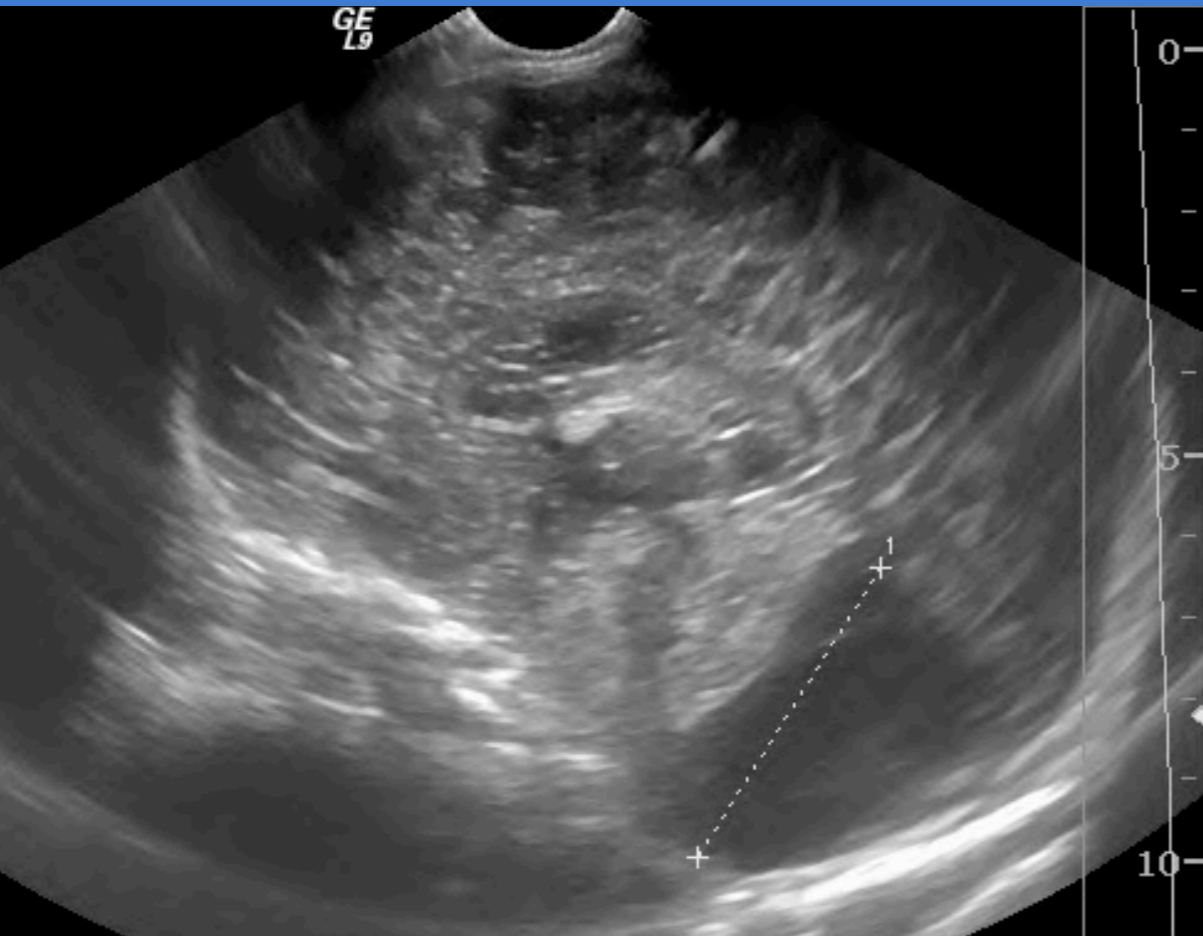
Convulsions ACC?

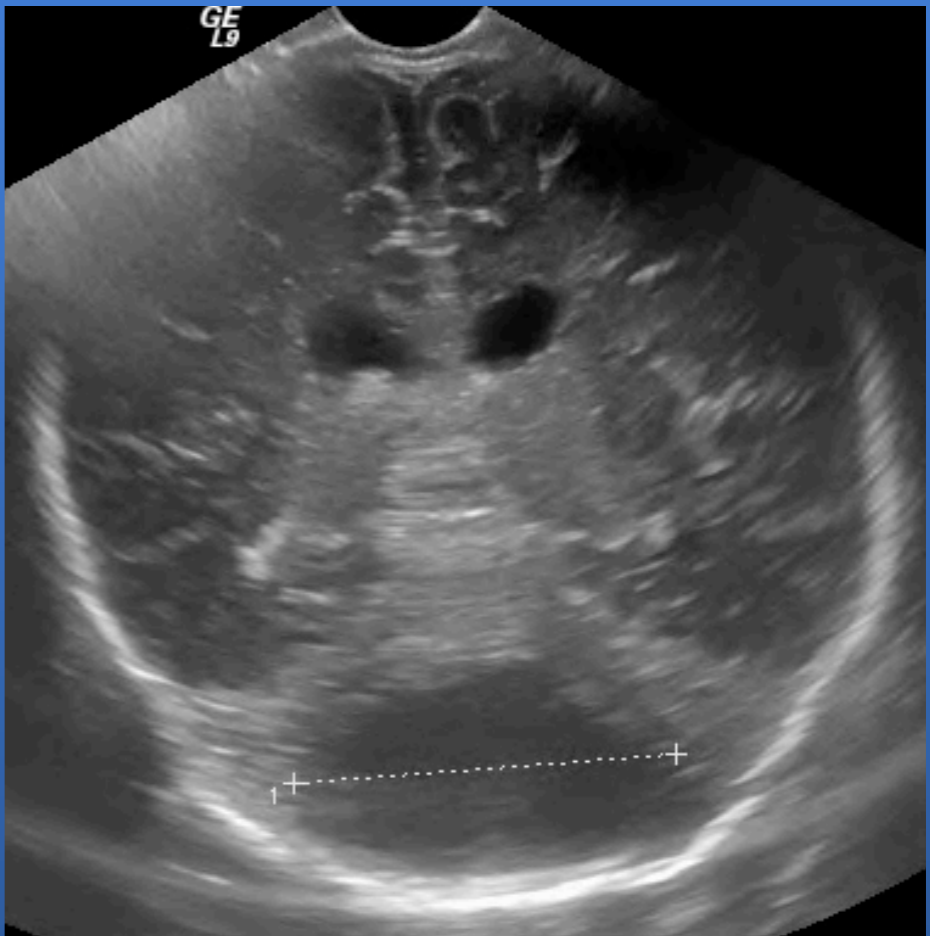
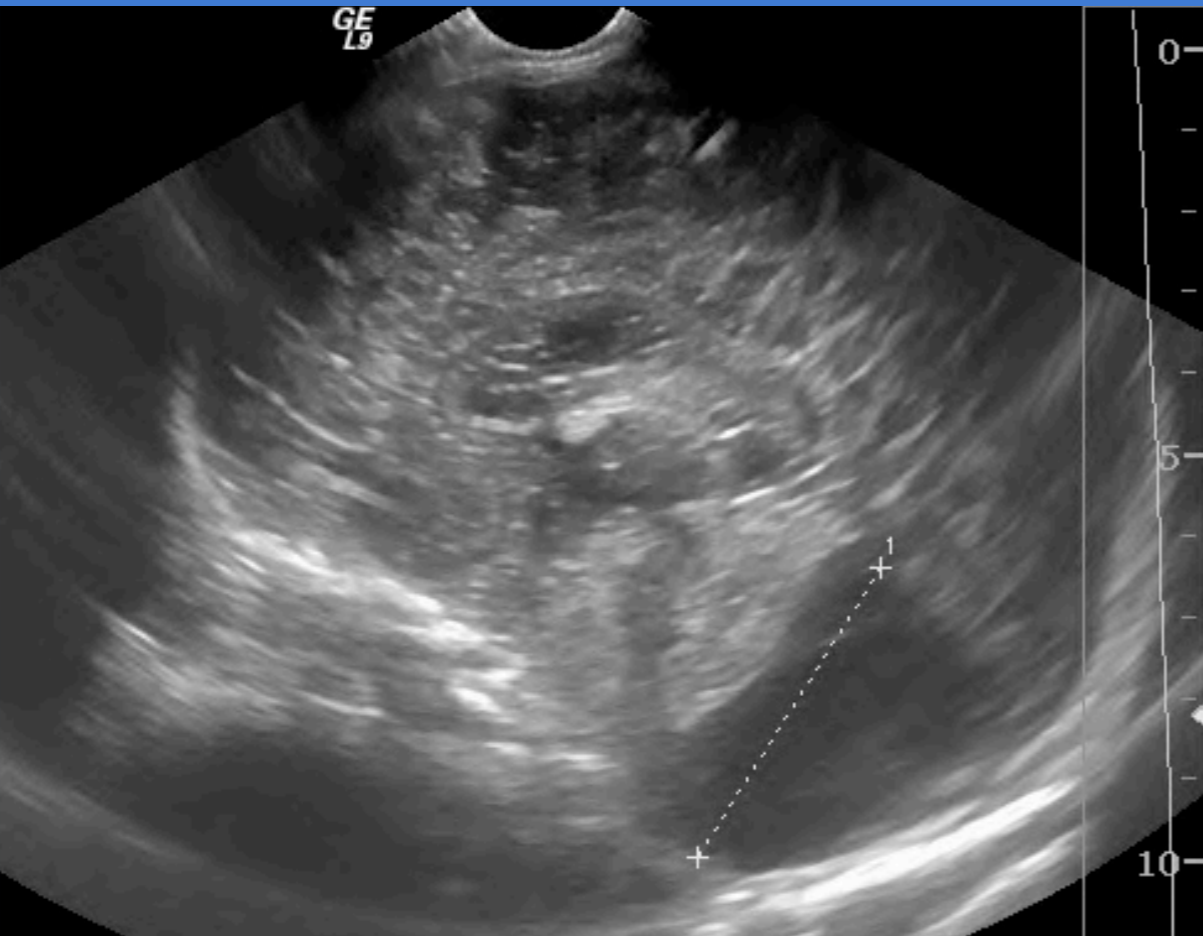




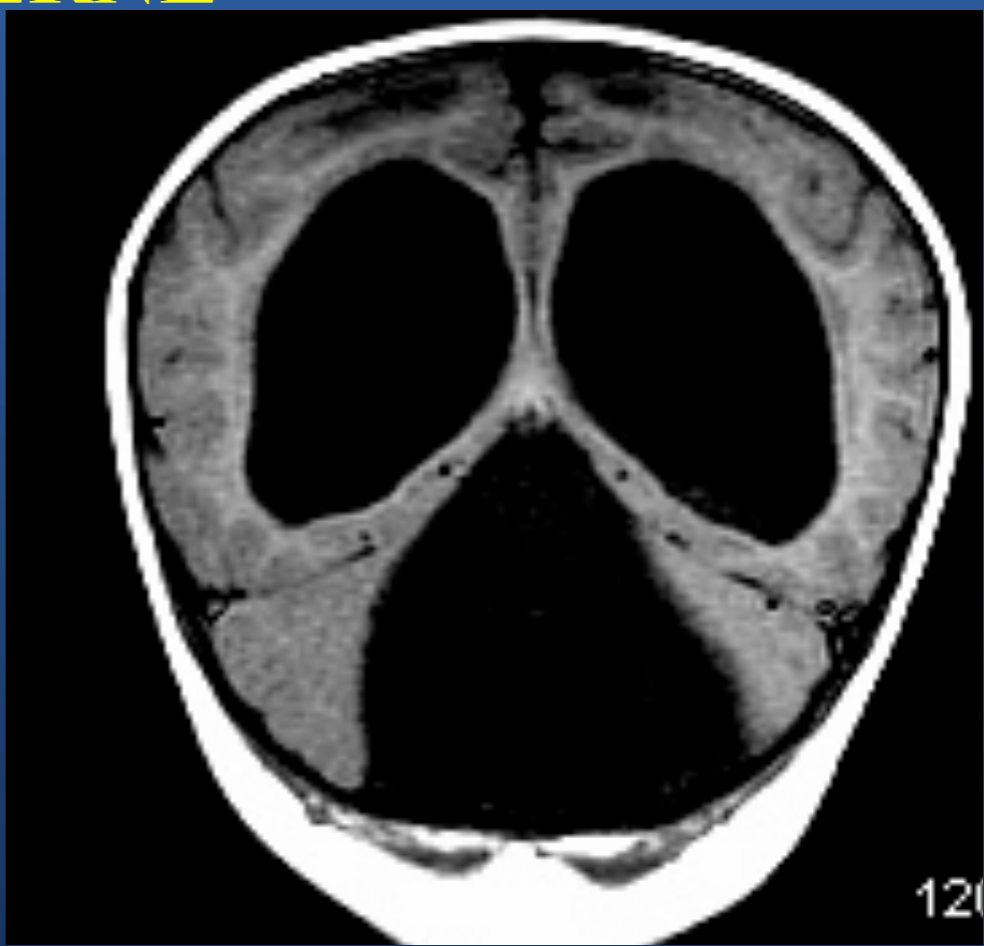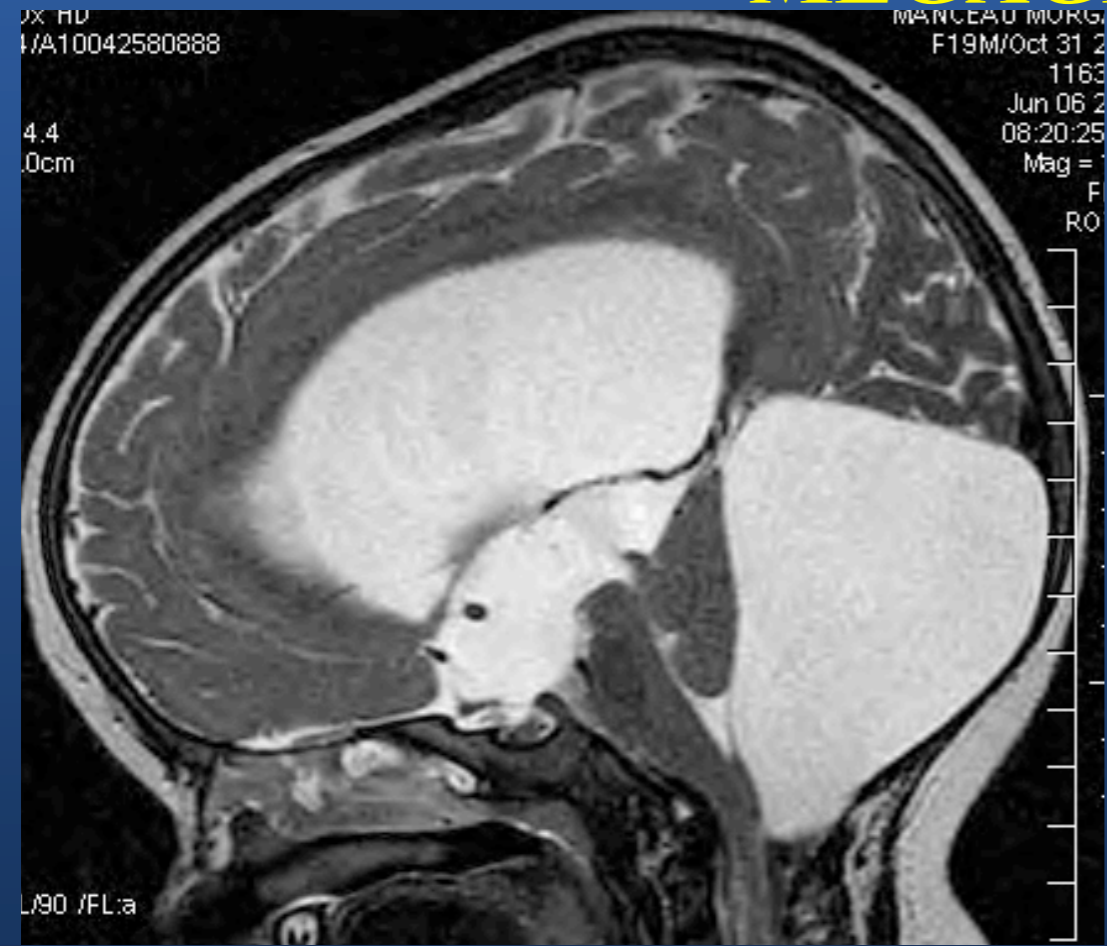100

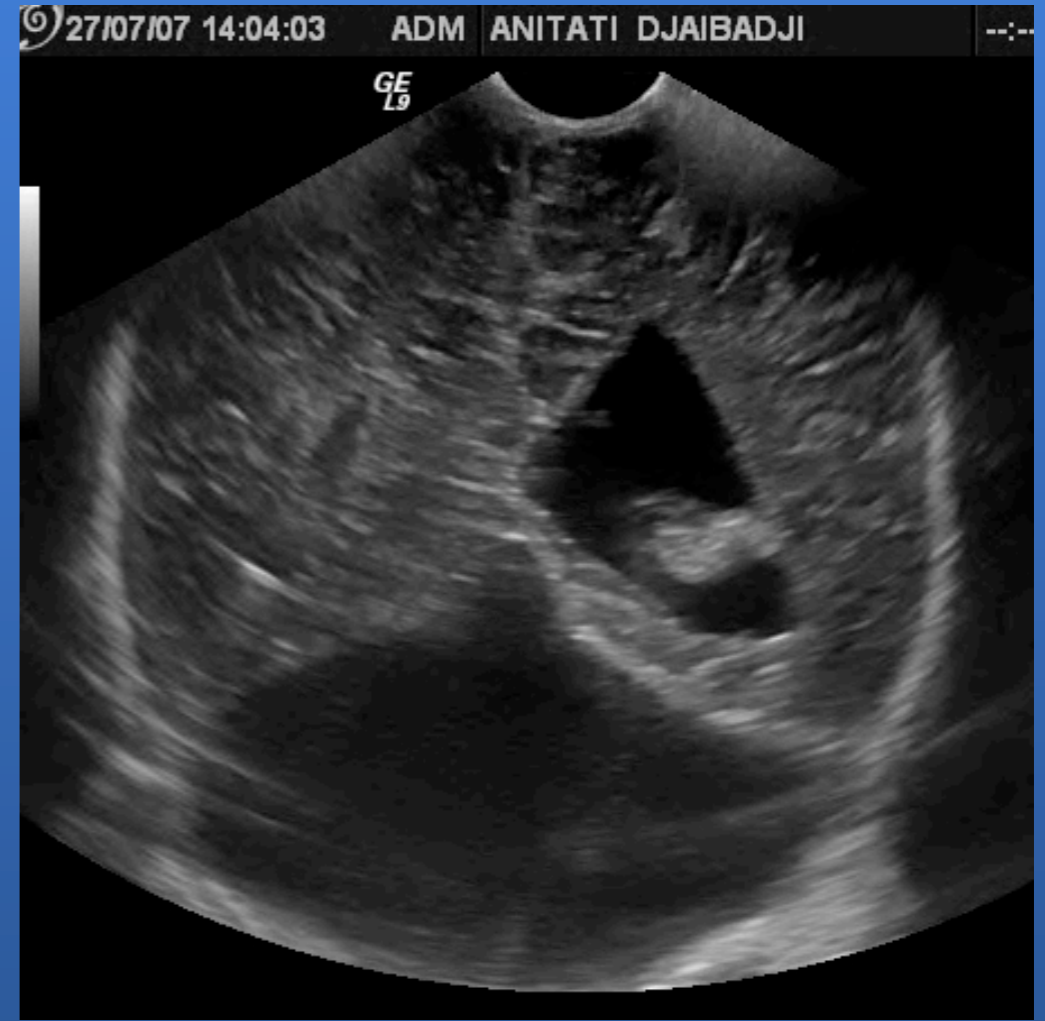
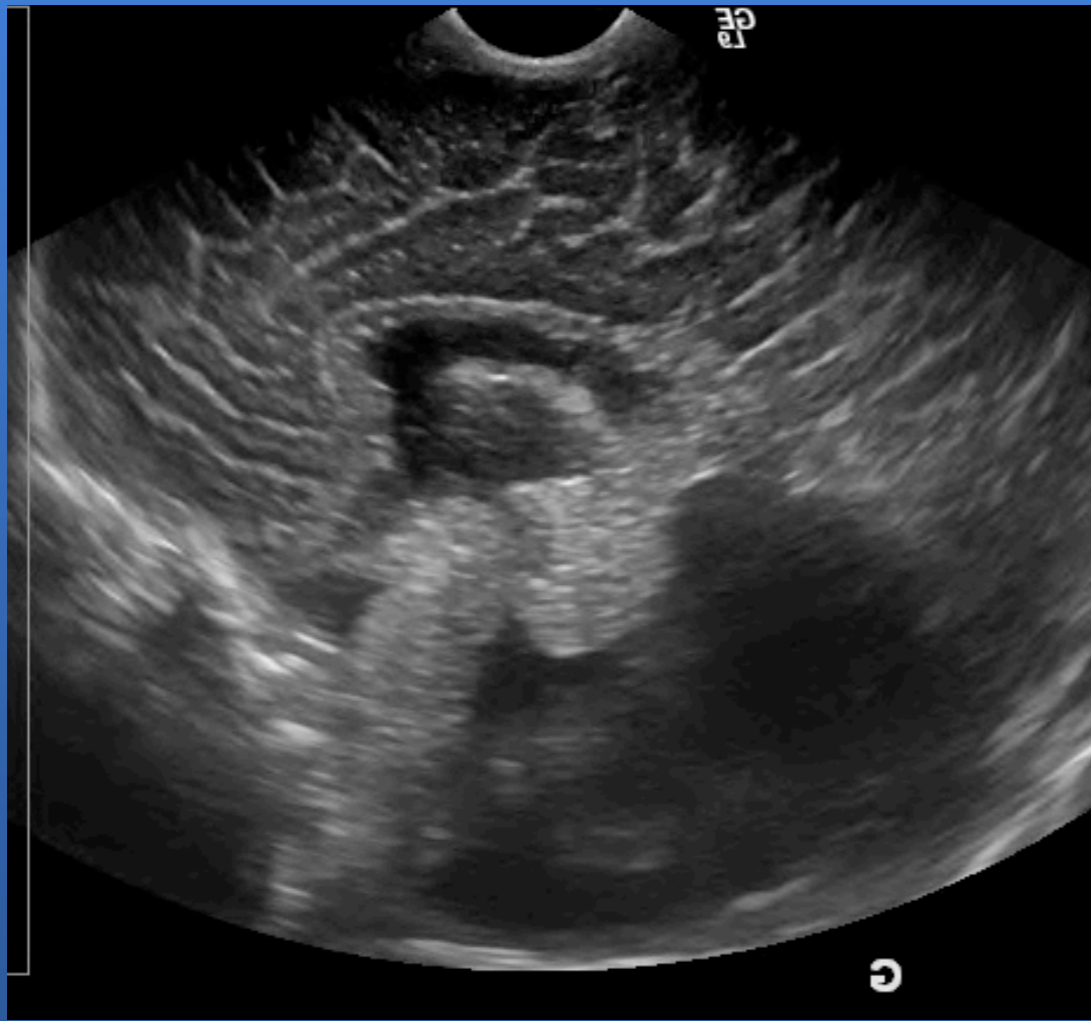


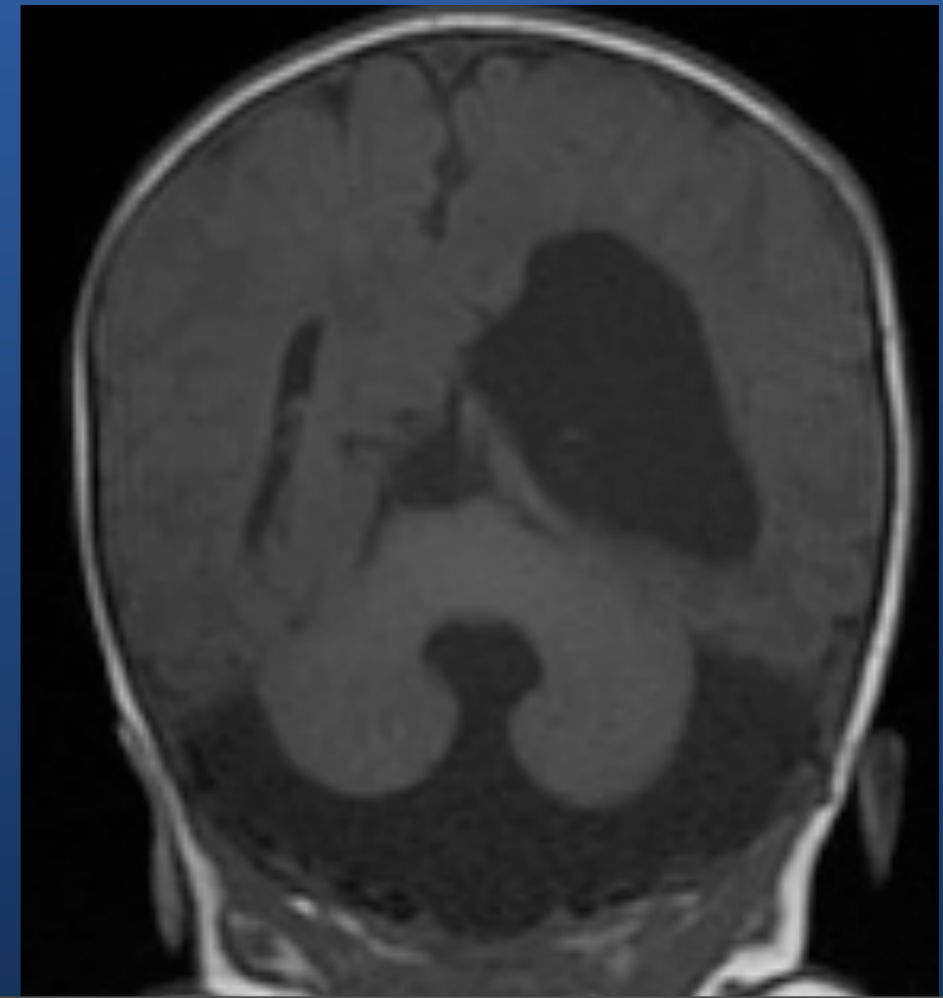
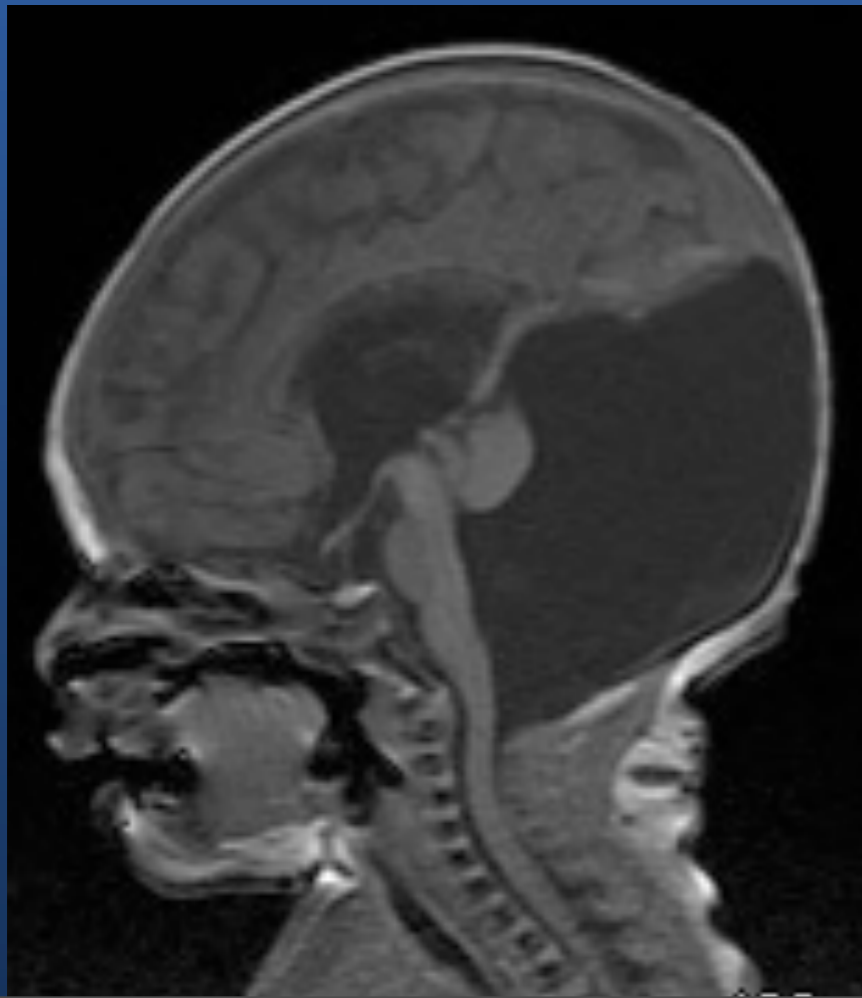
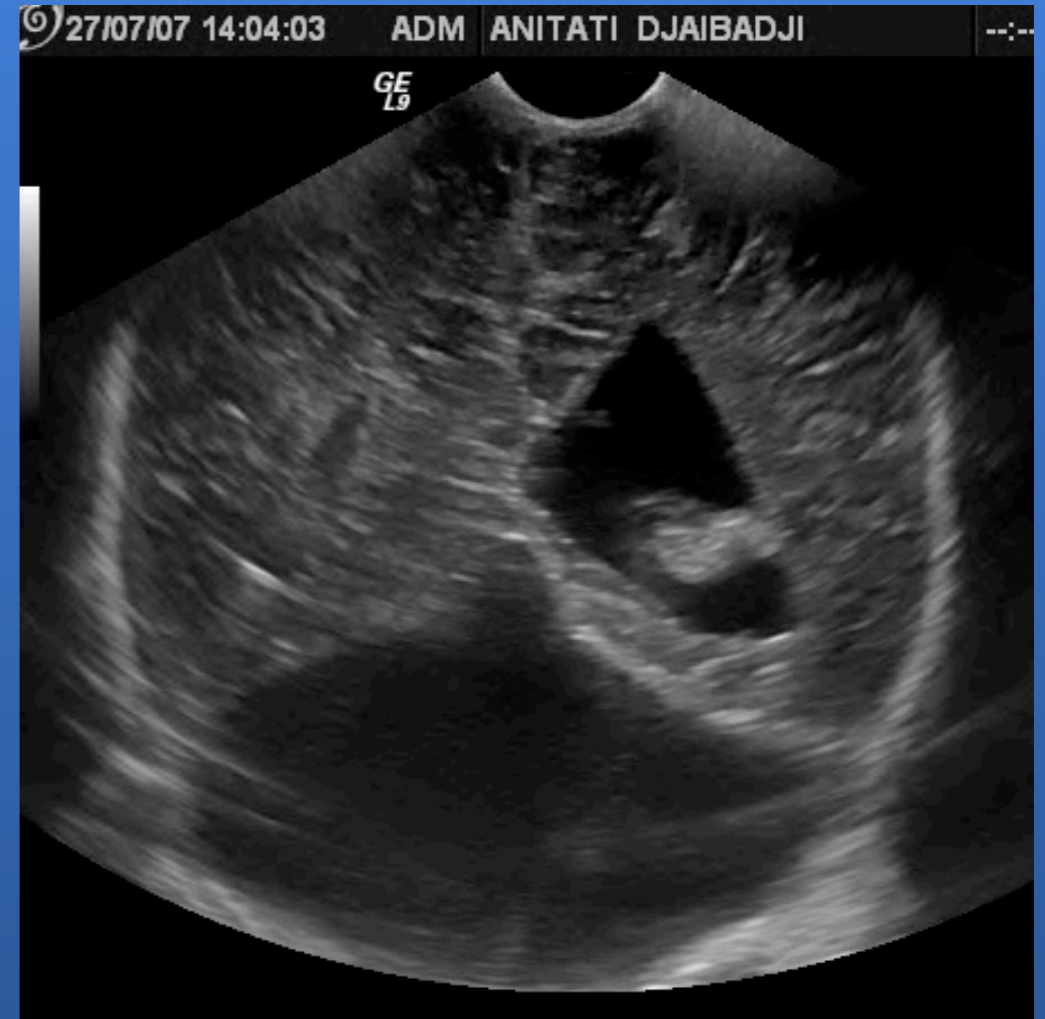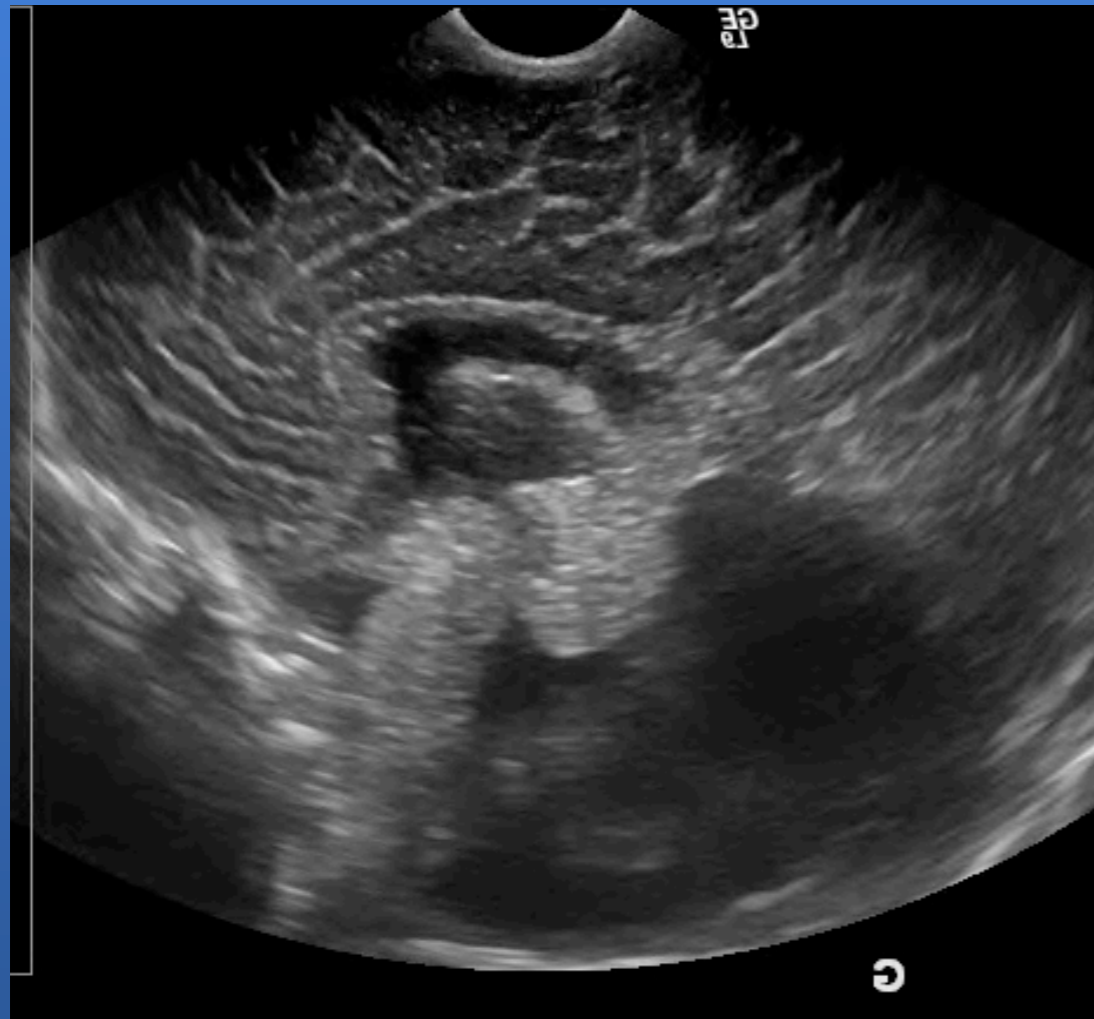


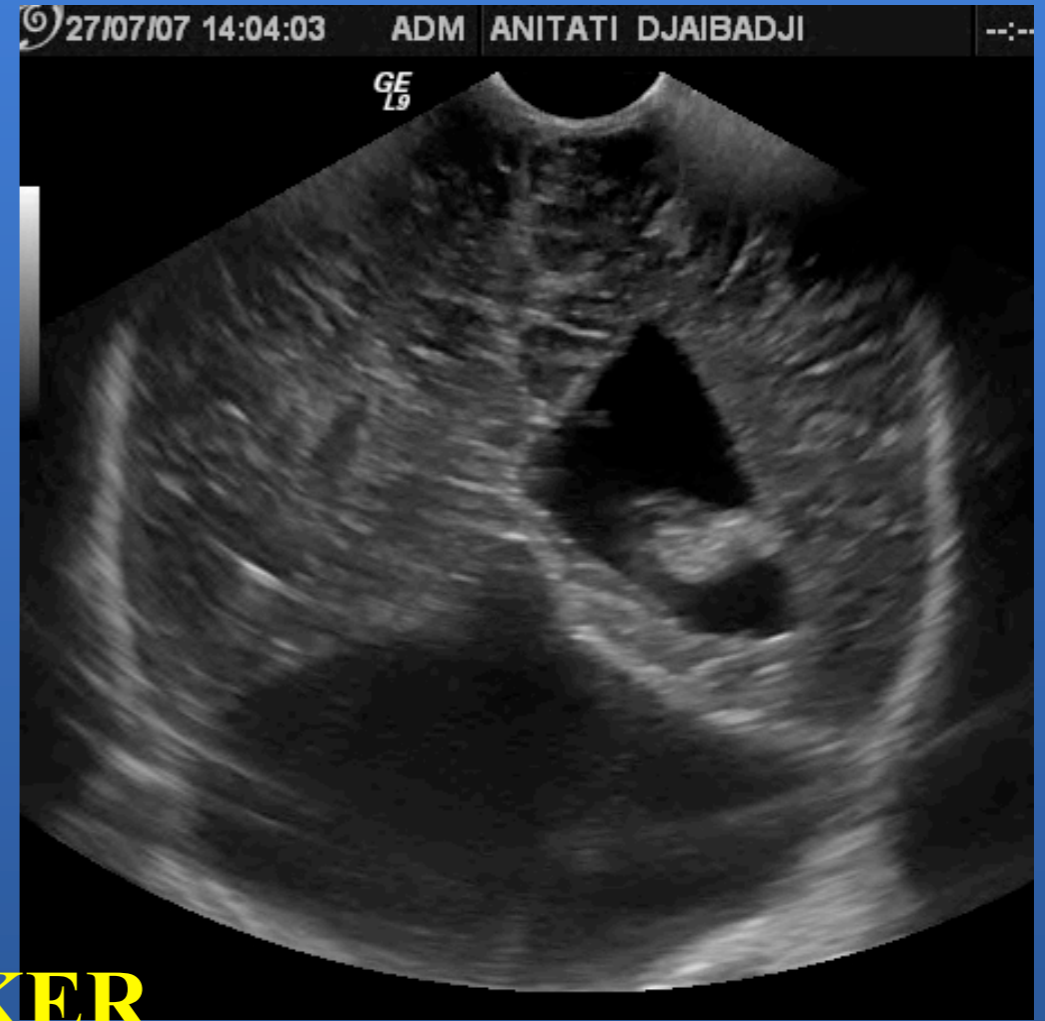
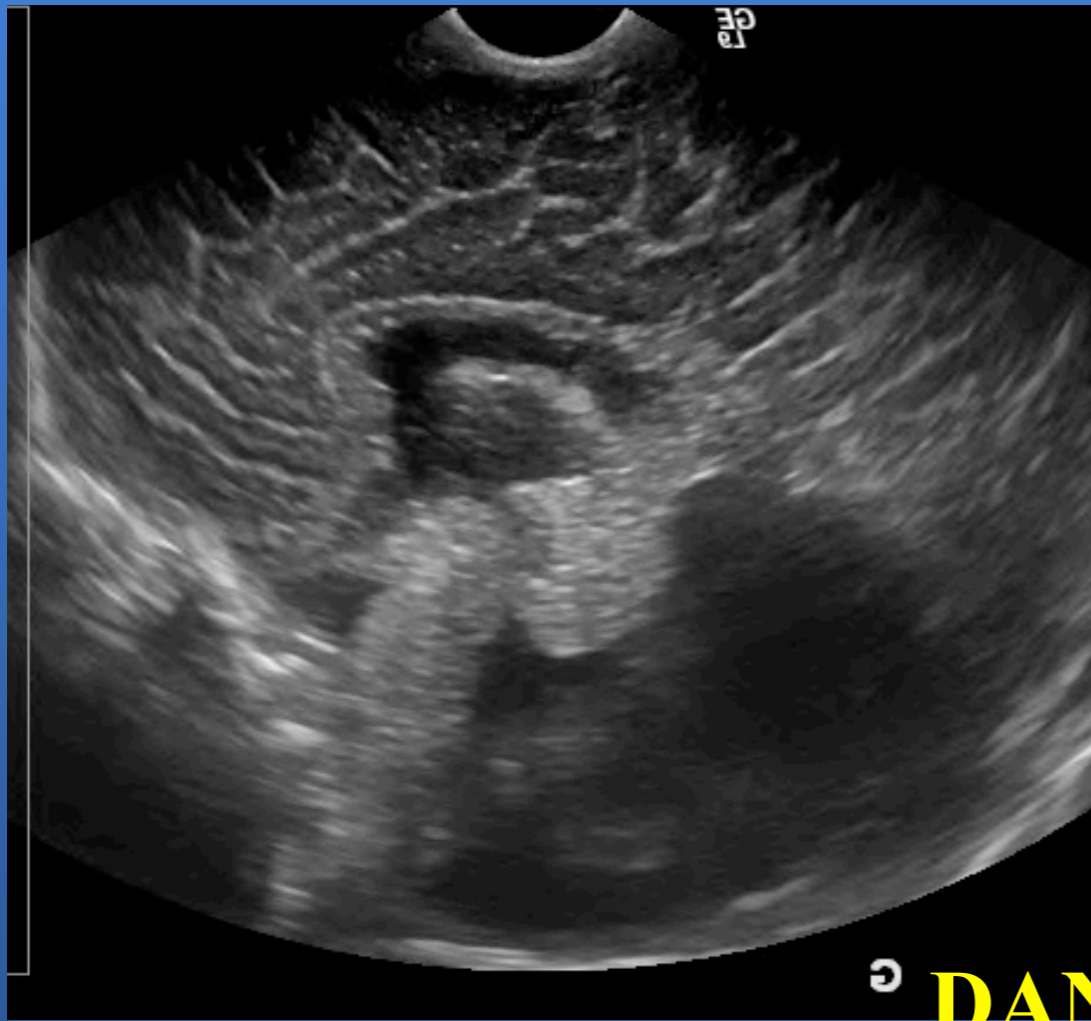


MEGAGRANDE CITERNE

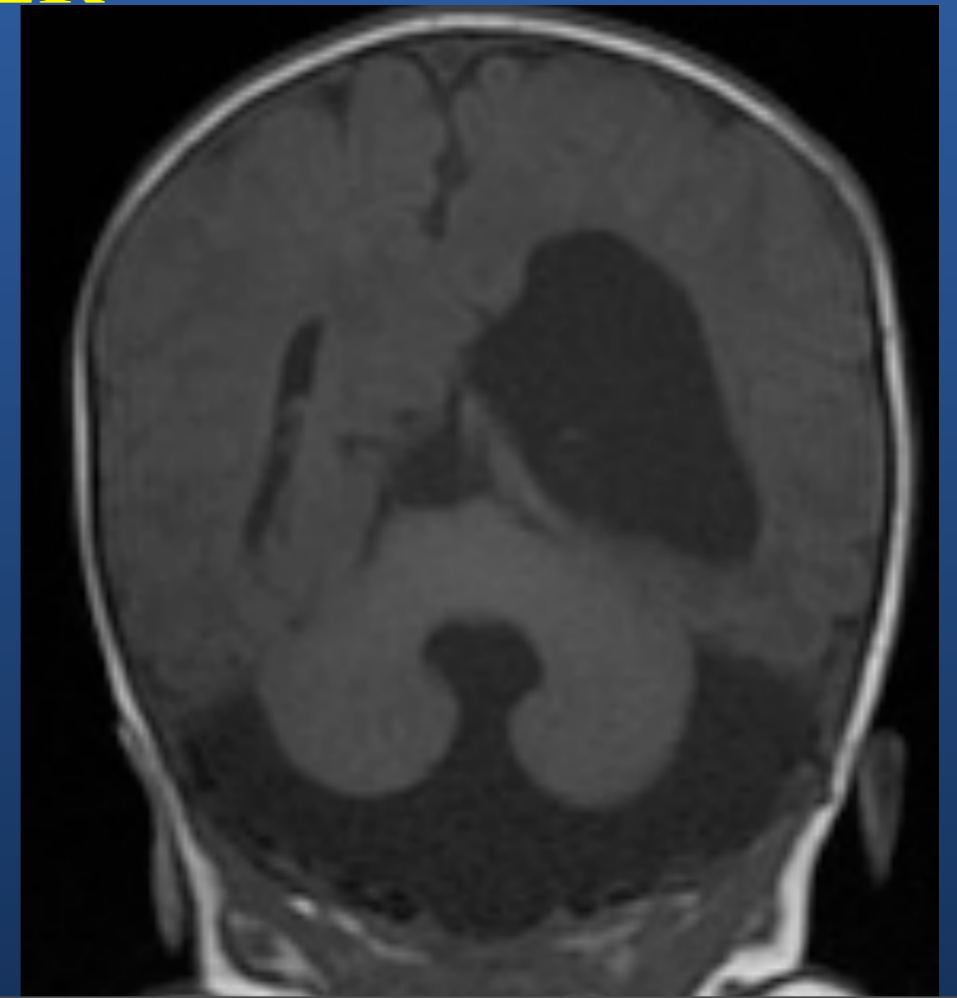
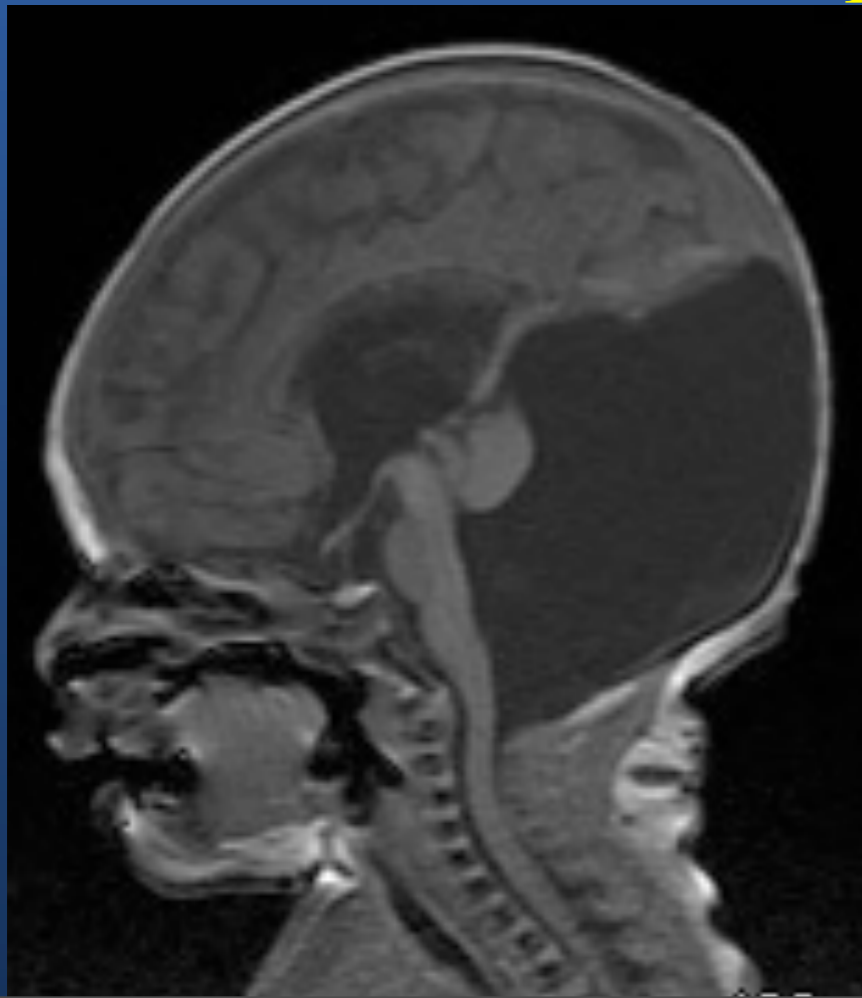




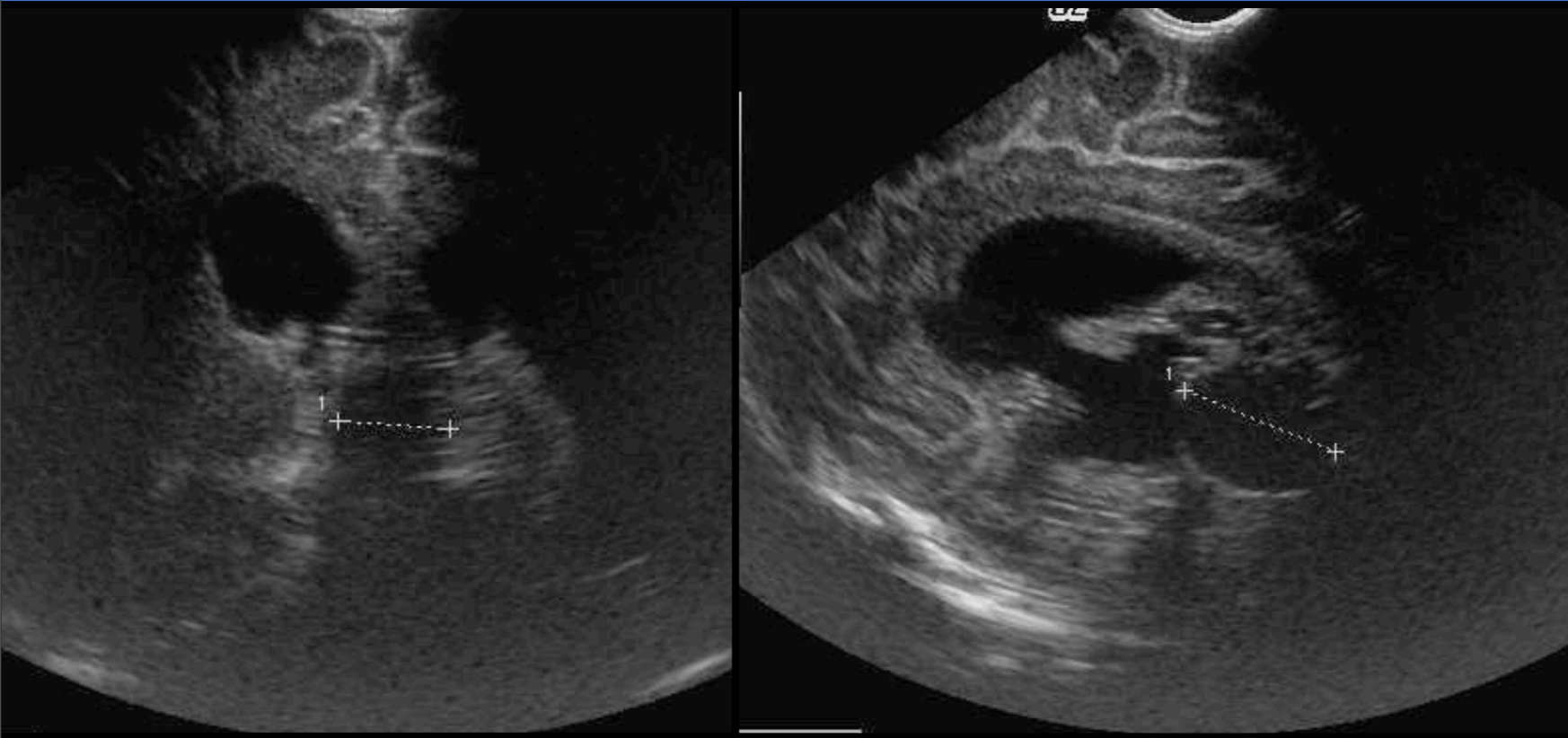




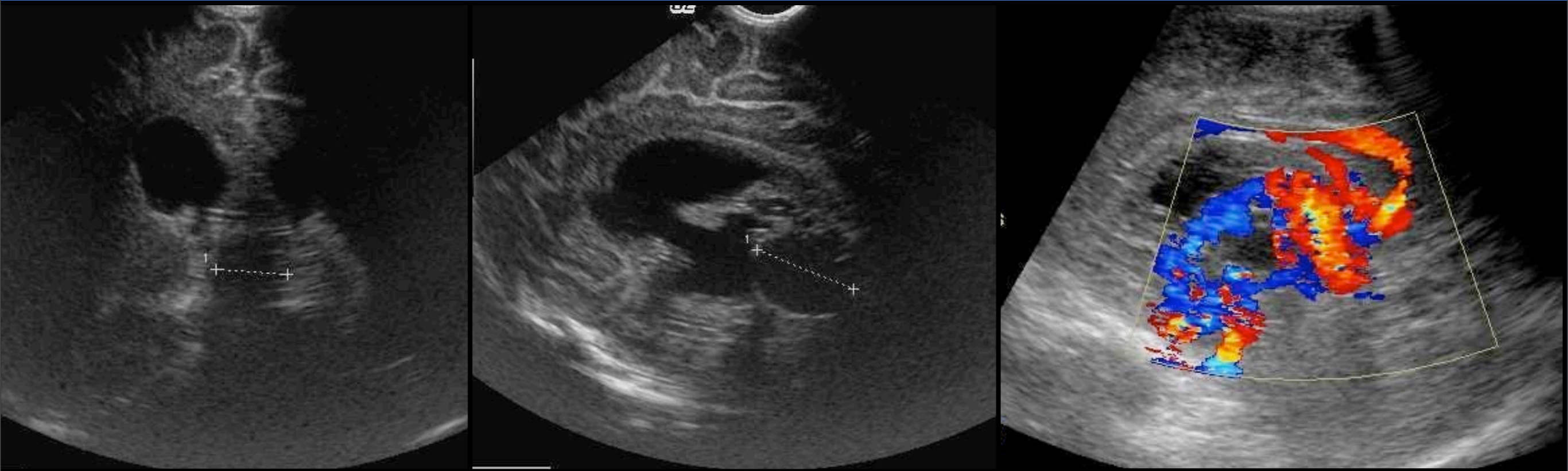
DANDY WALKER



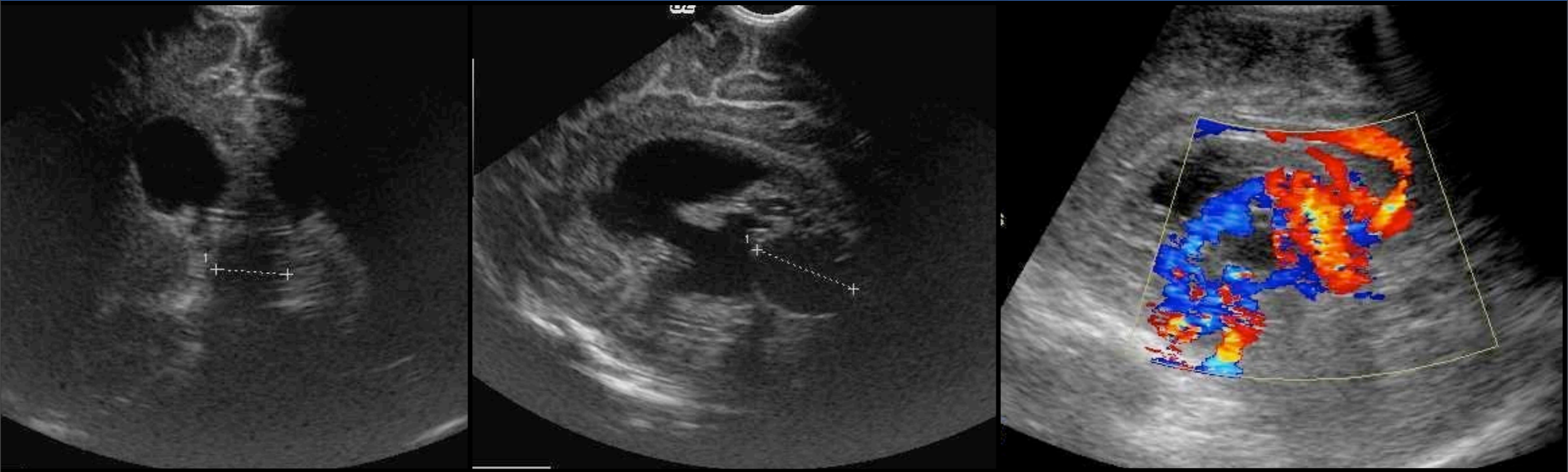
Malformations



Malformations

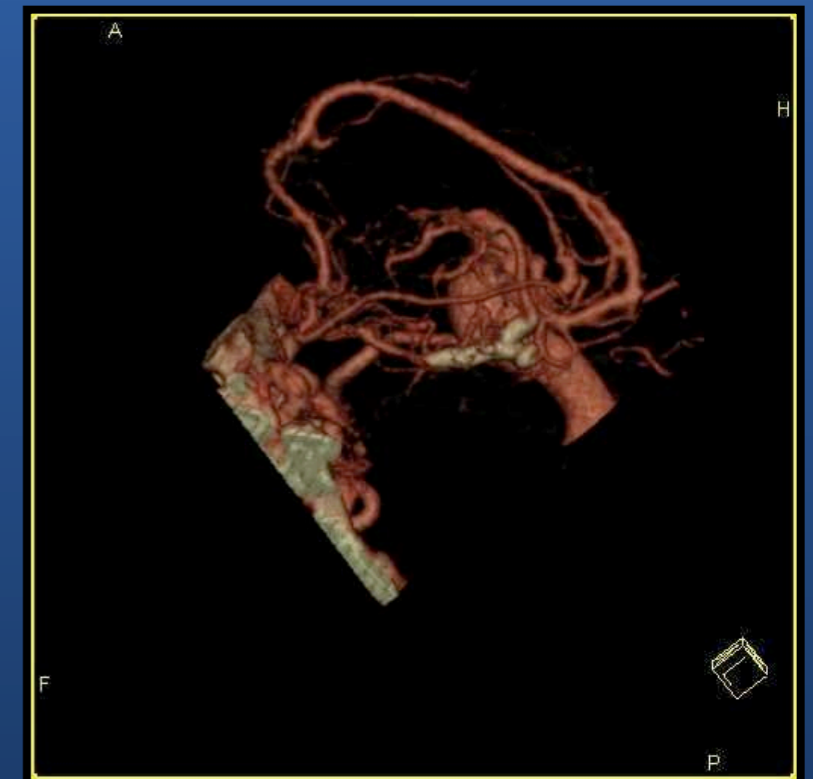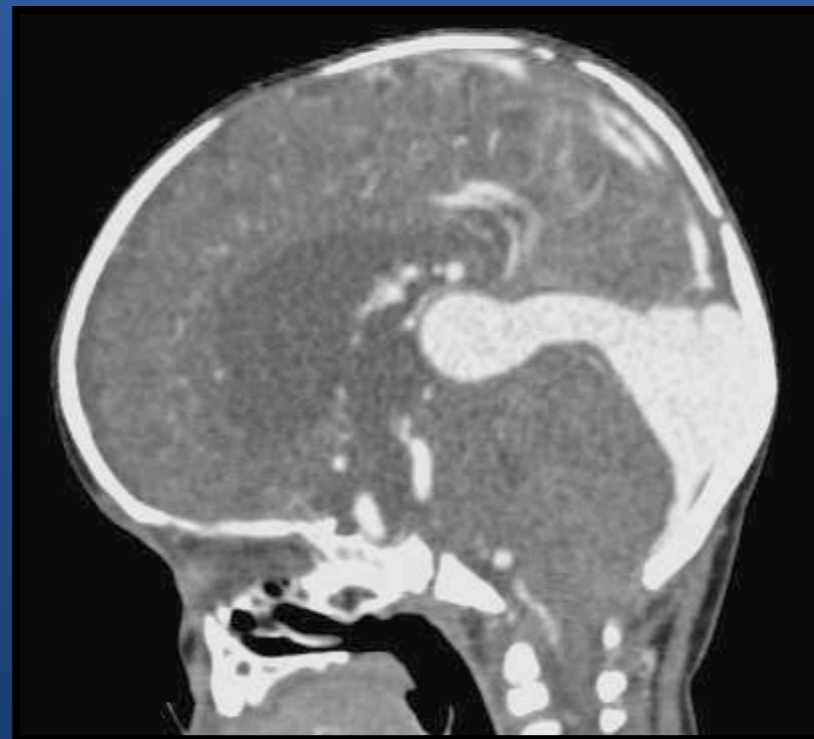
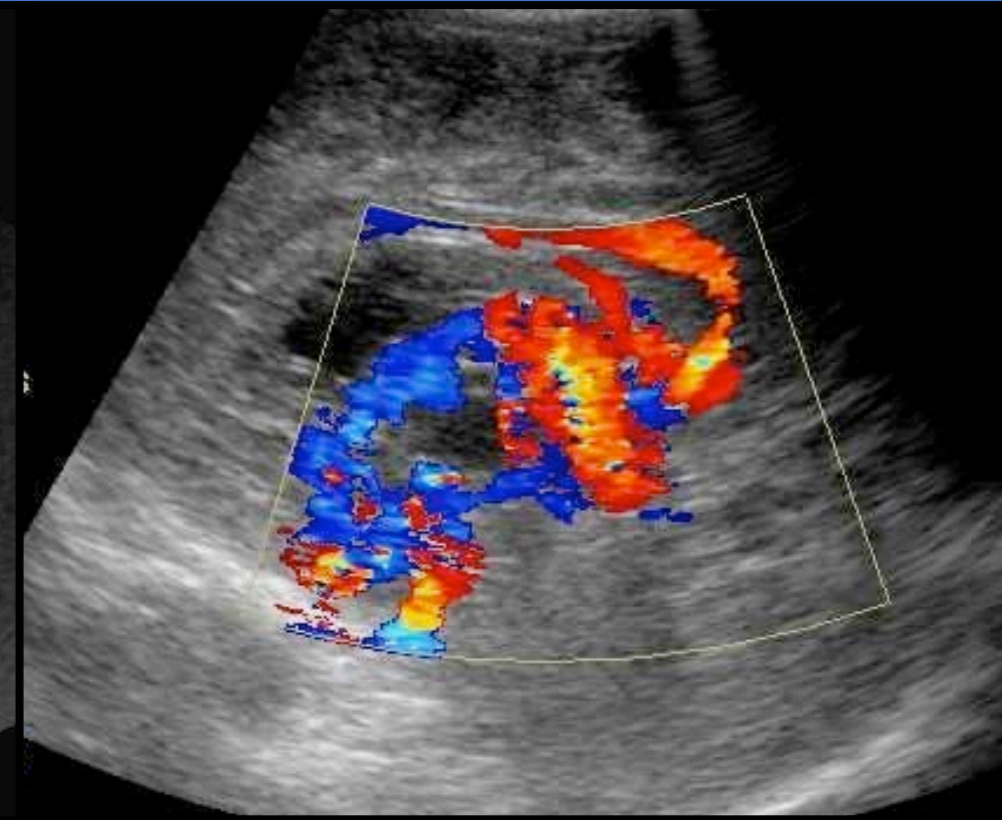

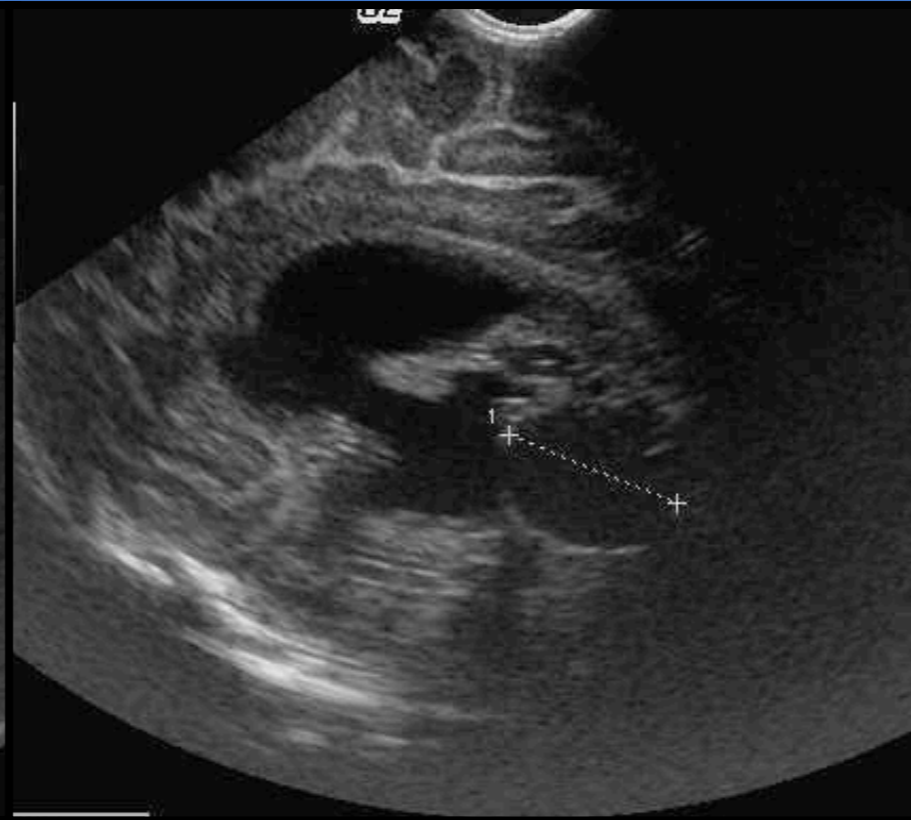
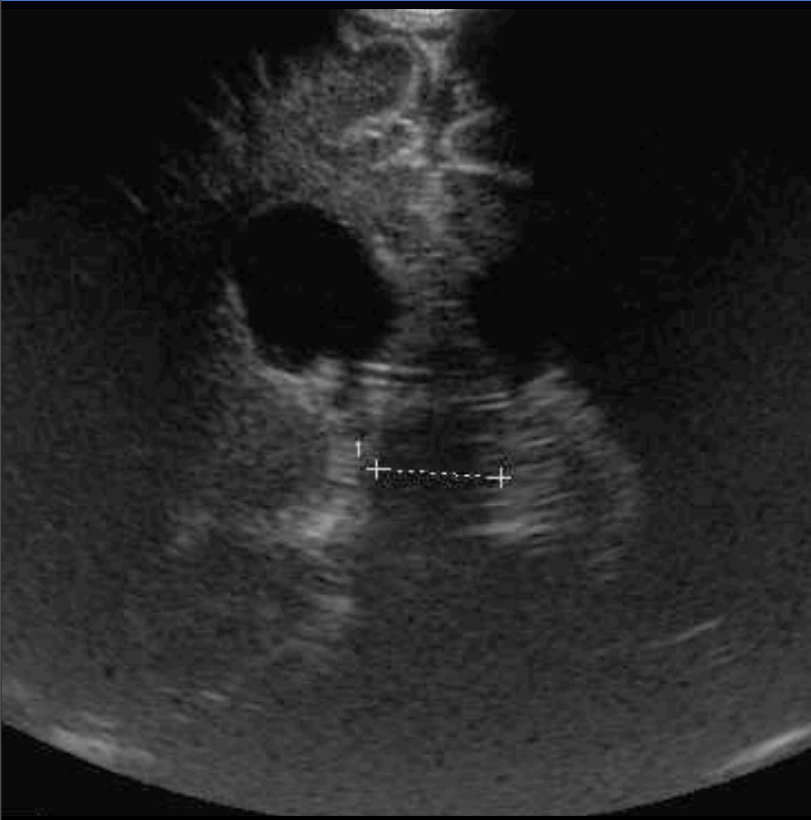Malformations



MALFORMATION DE L'AMPOULE DE GALIEN

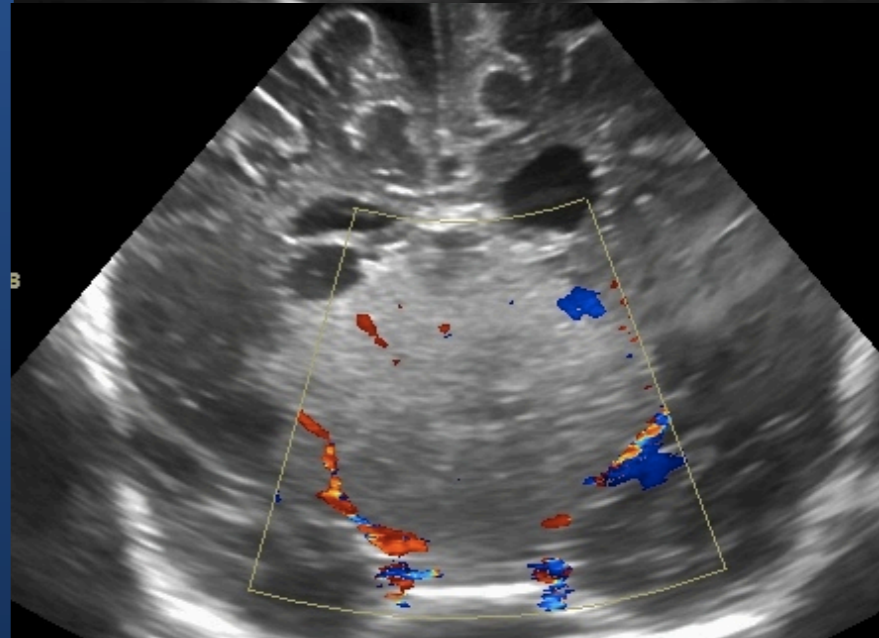
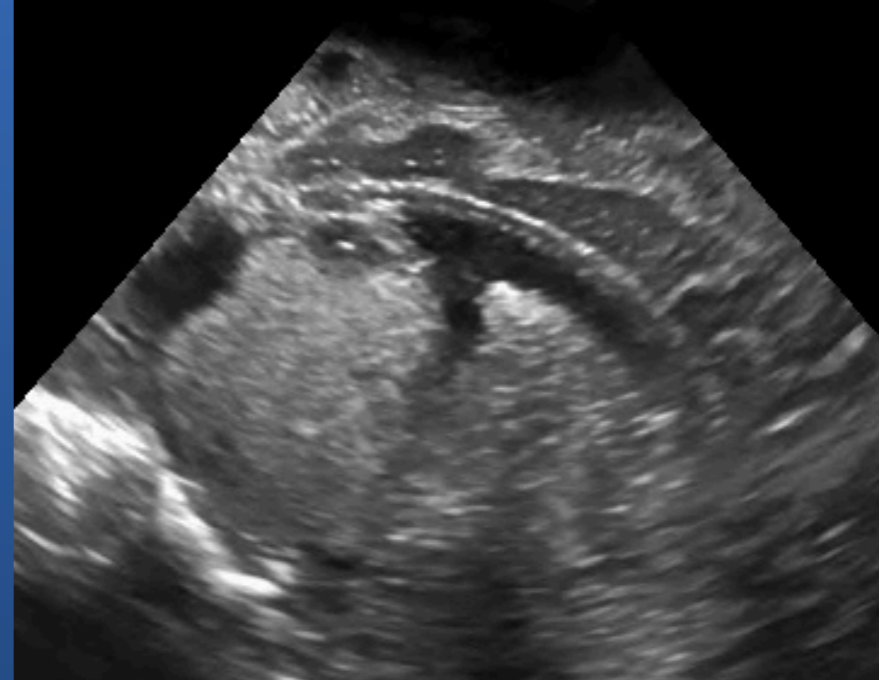
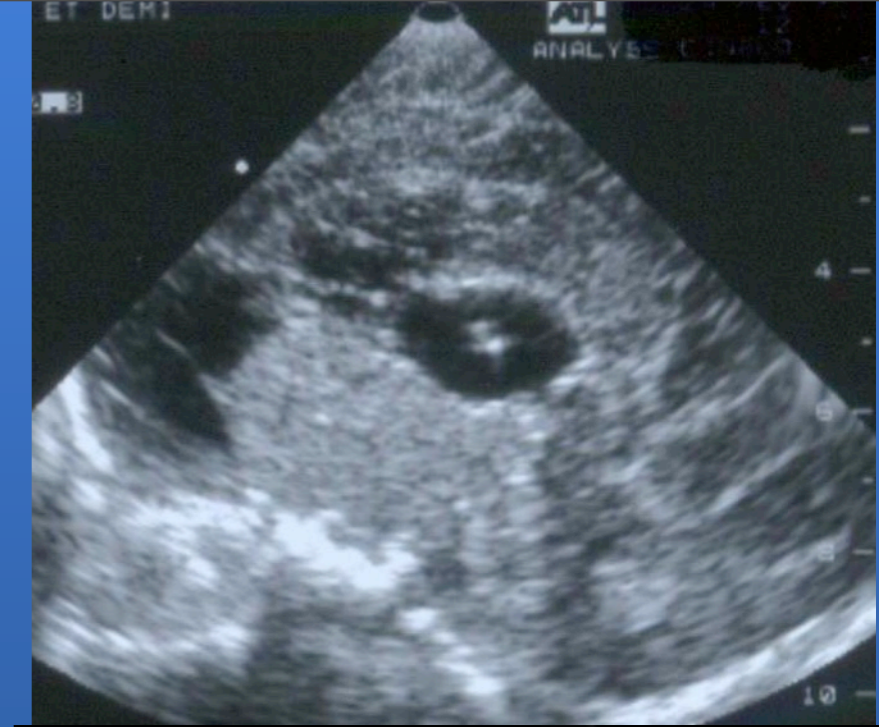Malformations



MALFORMATION DE L'AMPOULE DE GALIEN

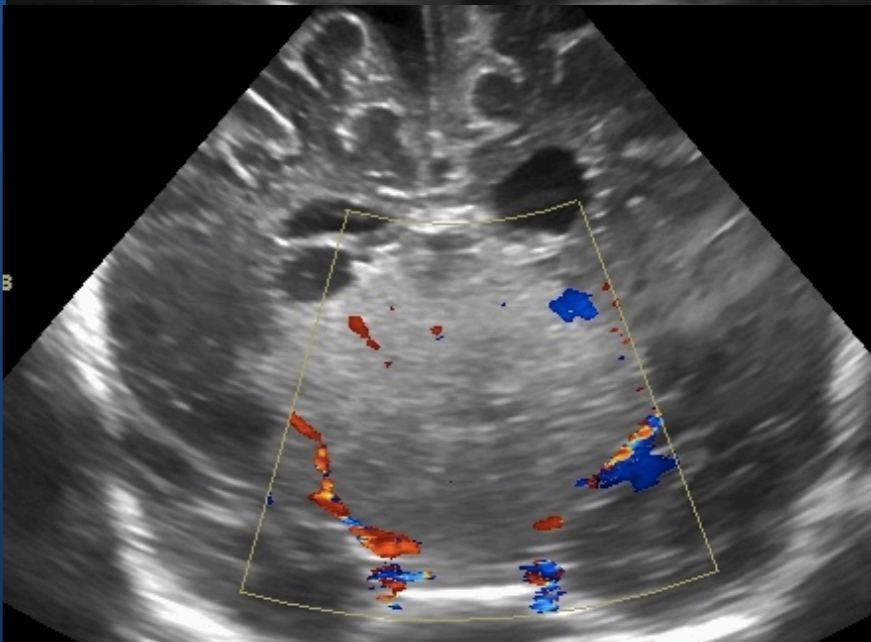
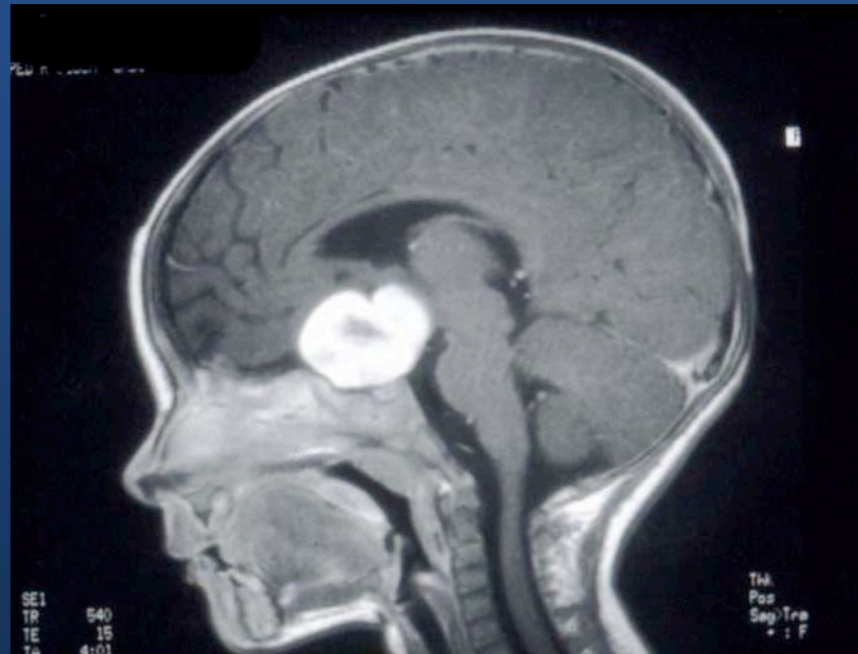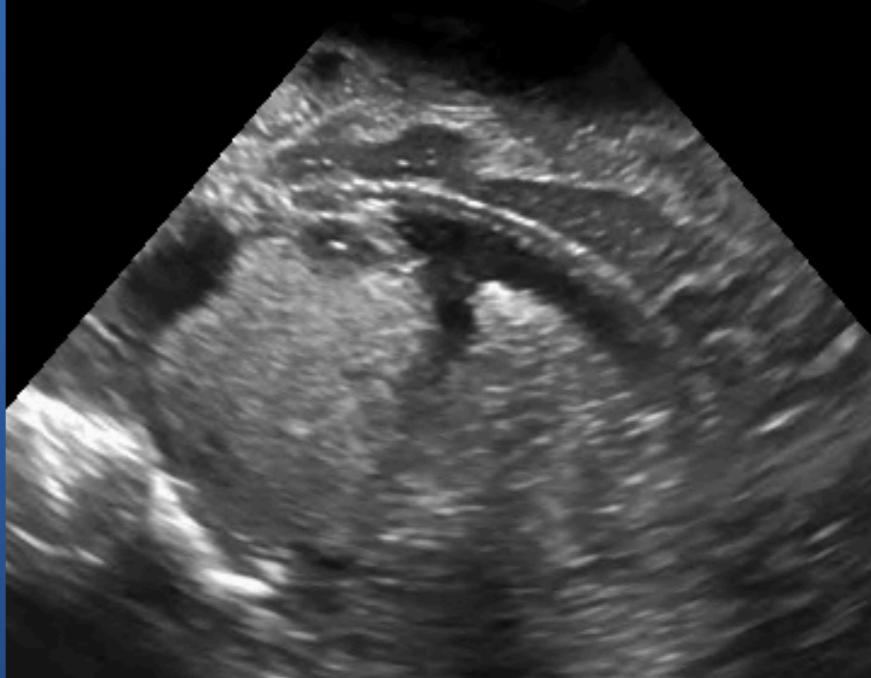
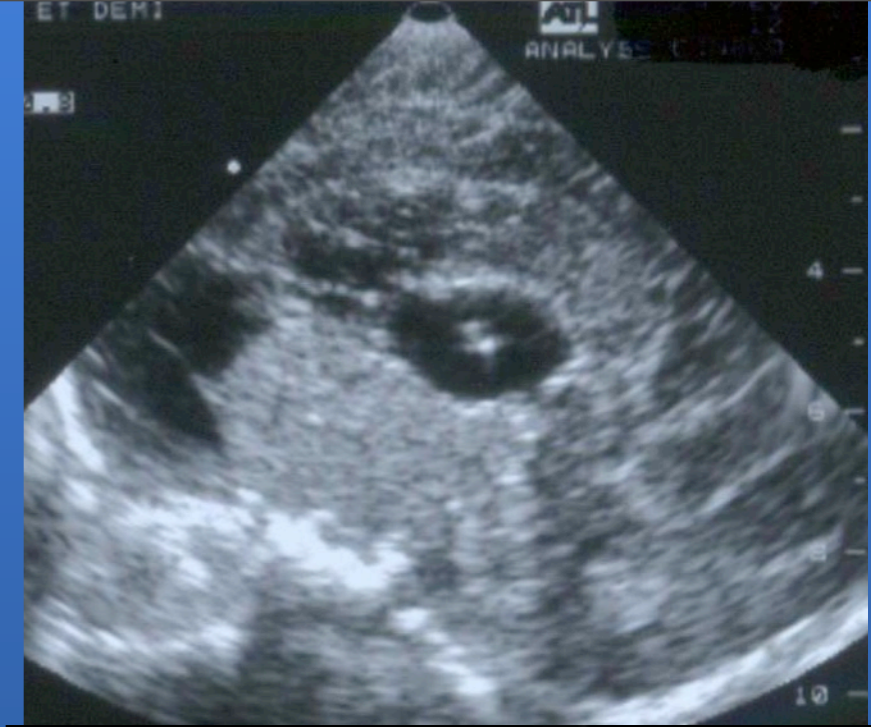
TUMEURS

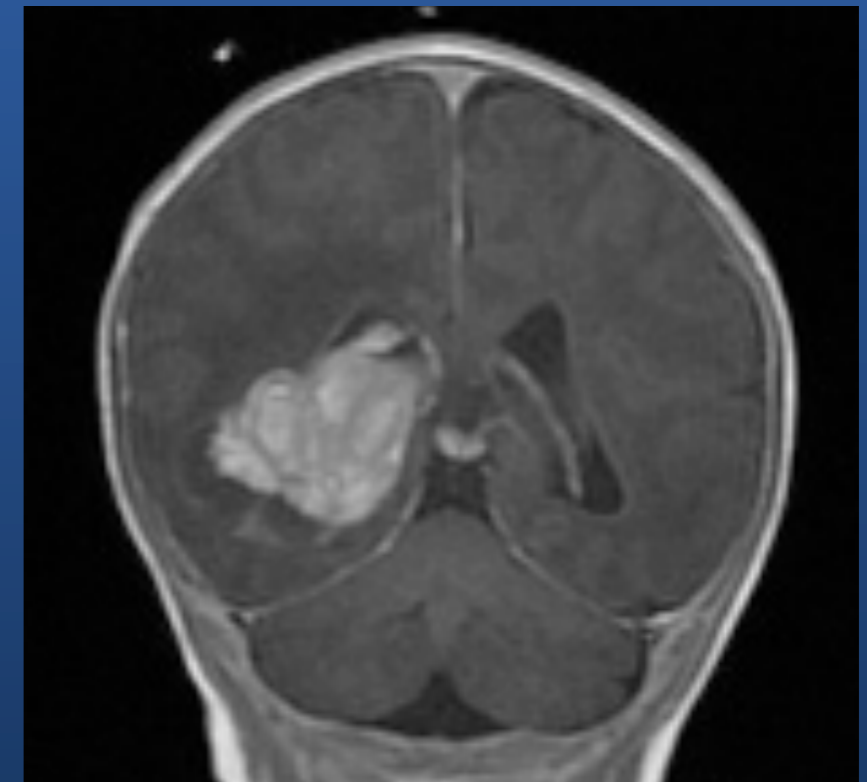
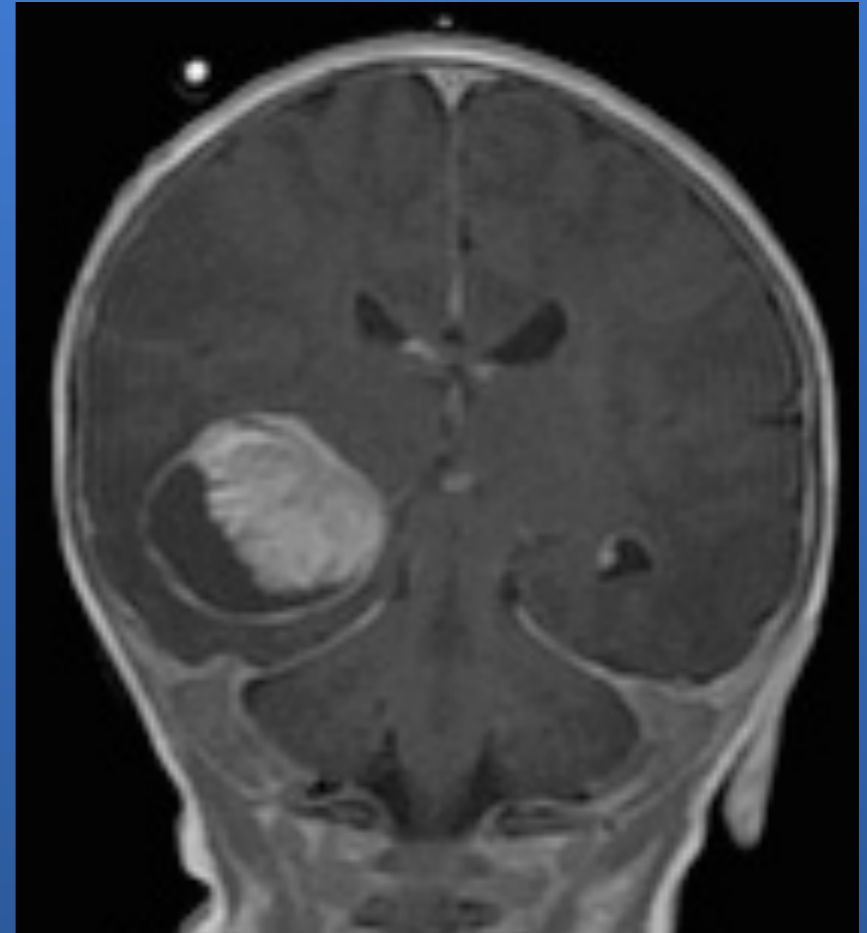
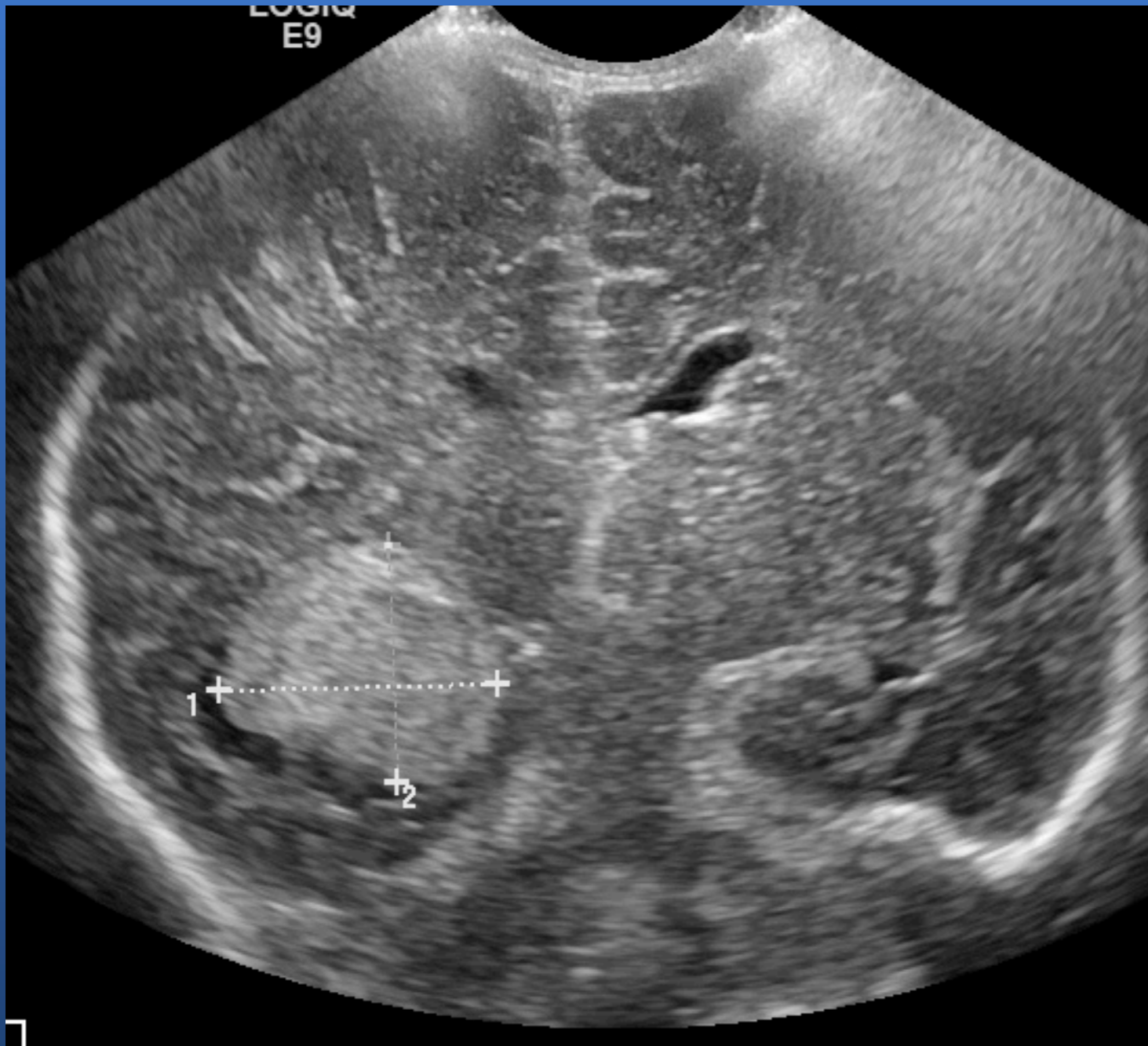
- **Diagnostic ante et post-natal**
- **Echographie < TDM < IRM**
 - **Signes directs**
 - **masse échogène ou kystique**
 - **Signes indirects**
 - **effet de masse : ligne médiane**
 - **Dilatation ventriculaire**



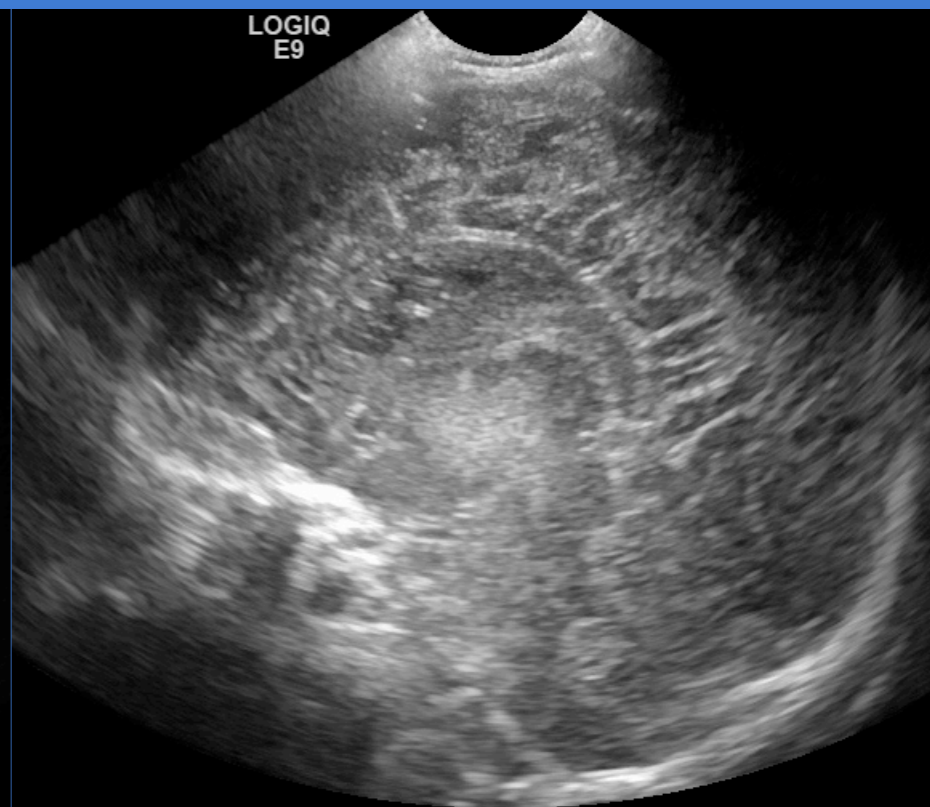
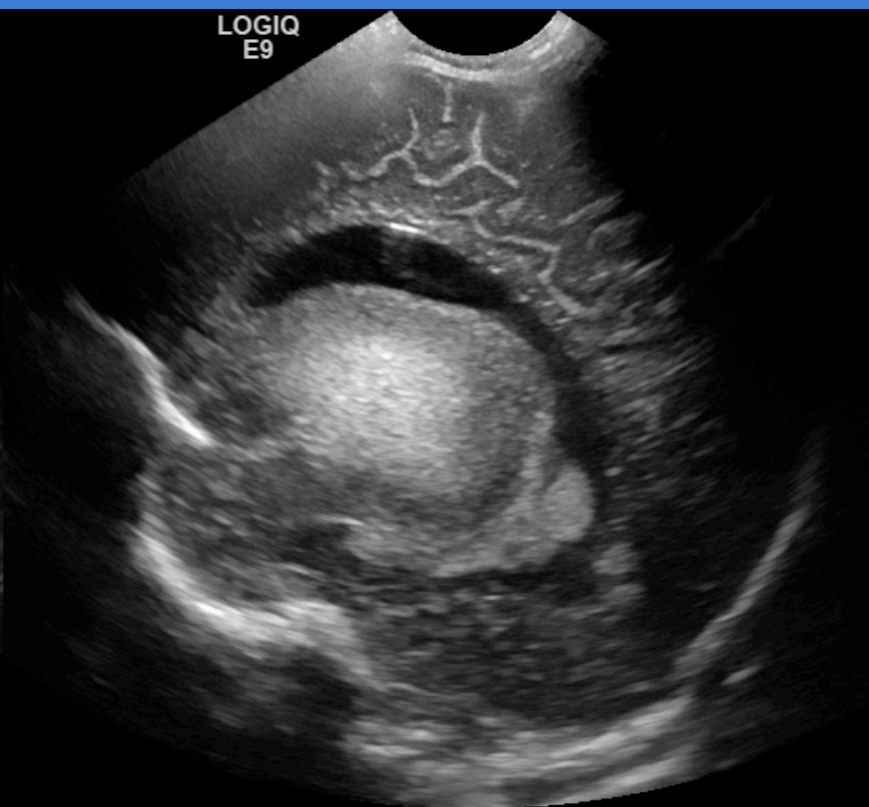
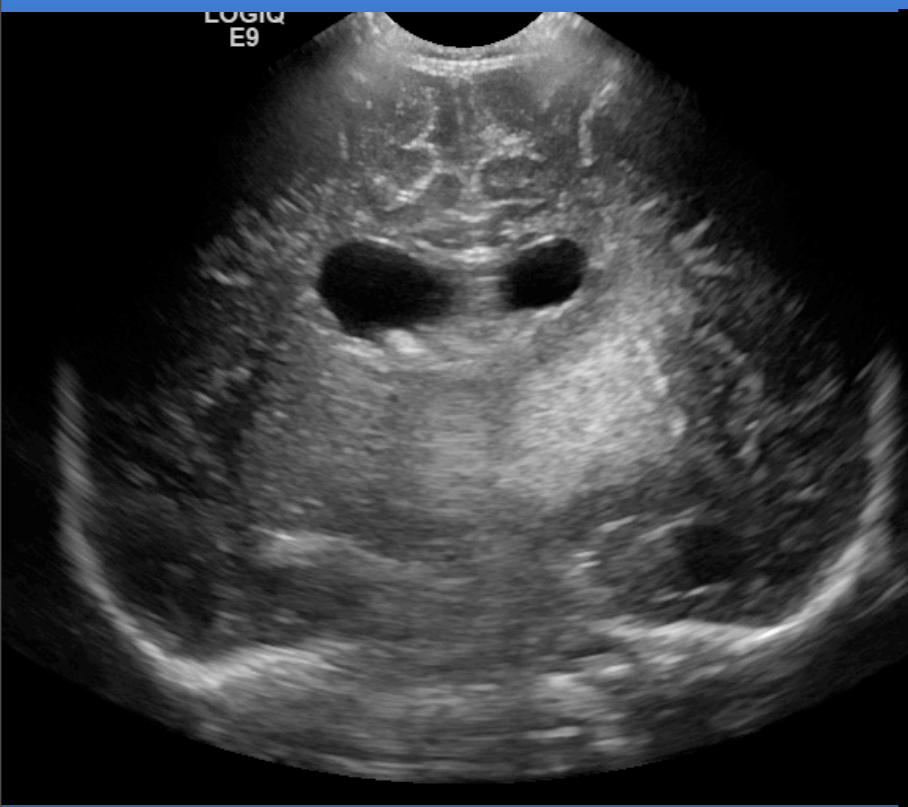
TUMEURS

- **Diagnostic ante et post-natal**
- **Echographie < TDM < IRM**
 - **Signes directs**
 - **masse échogène ou kystique**
 - **Signes indirects**
 - **effet de masse : ligne médiane**
 - **Dilatation ventriculaire**

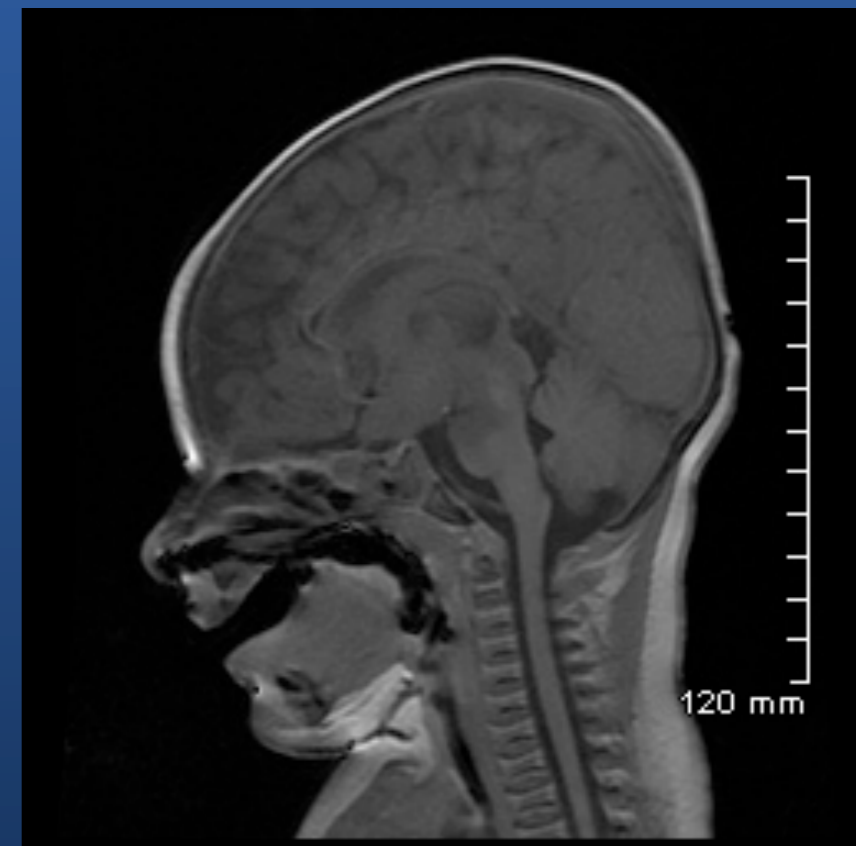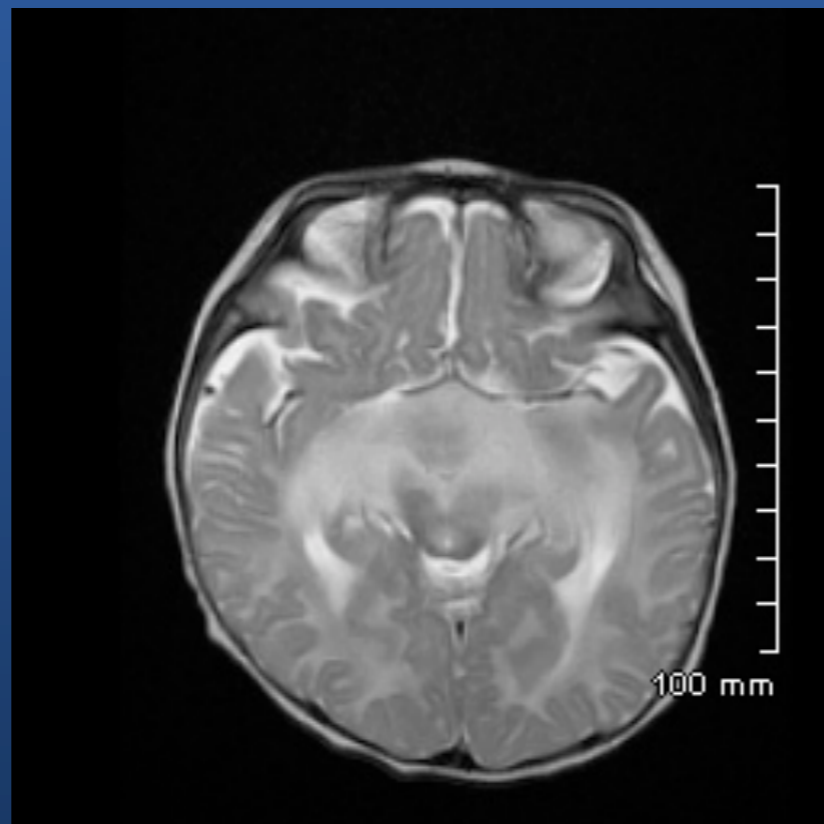
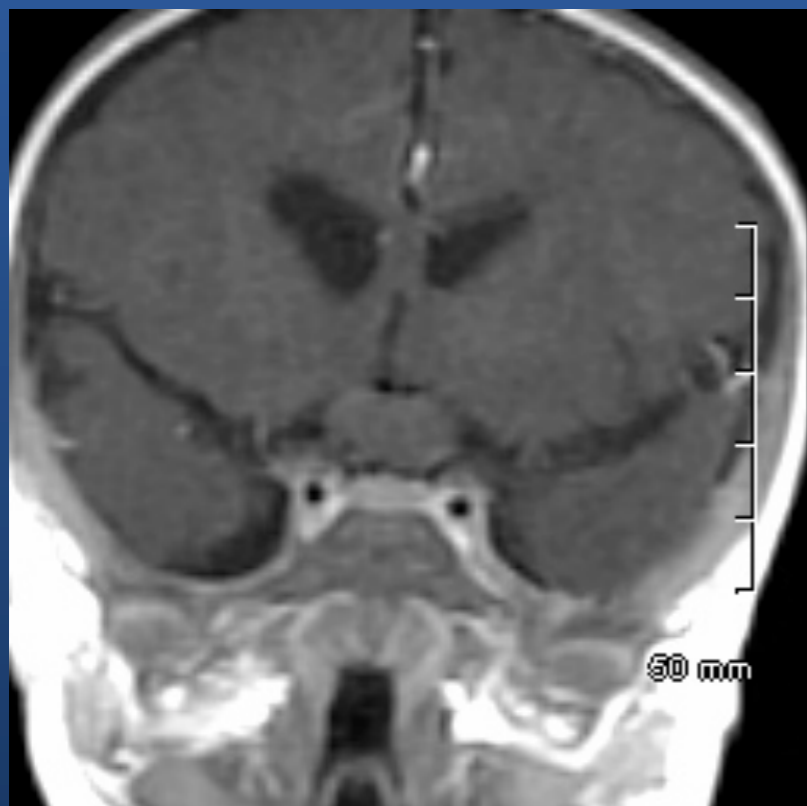




106

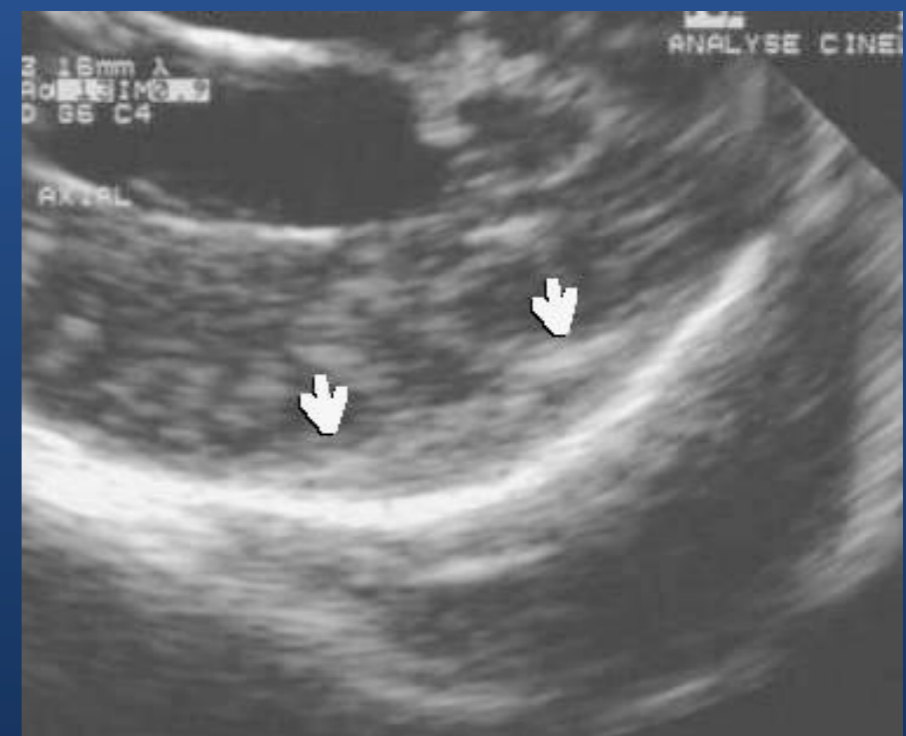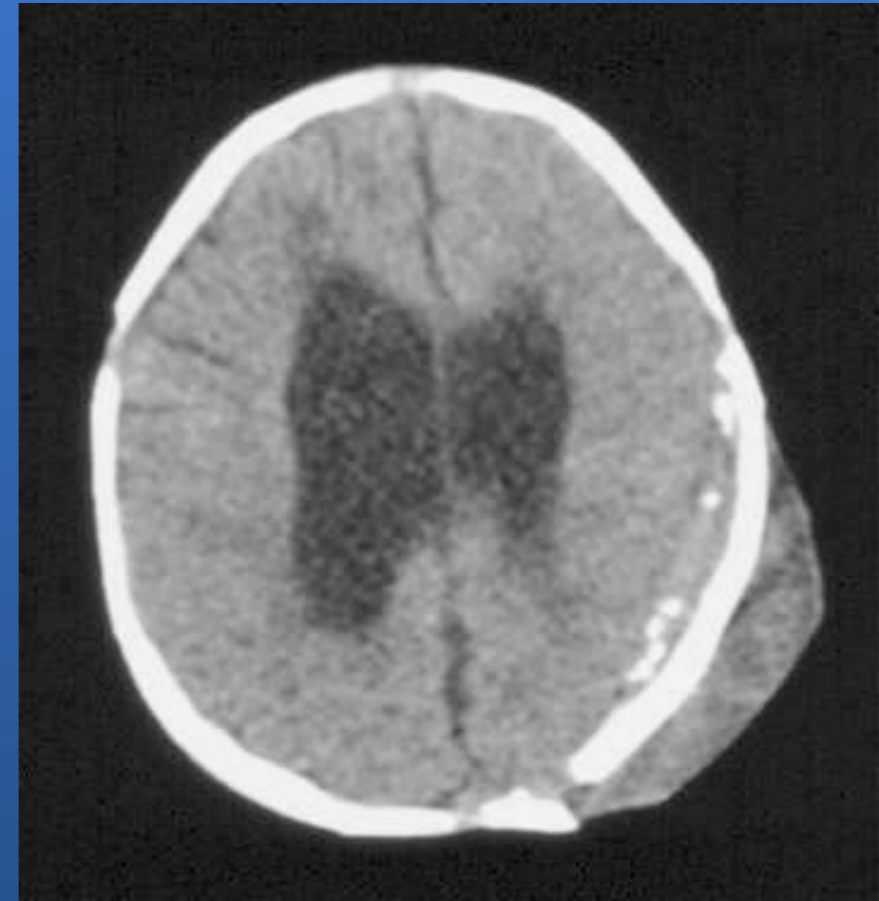


AUGMENTATION DU PC



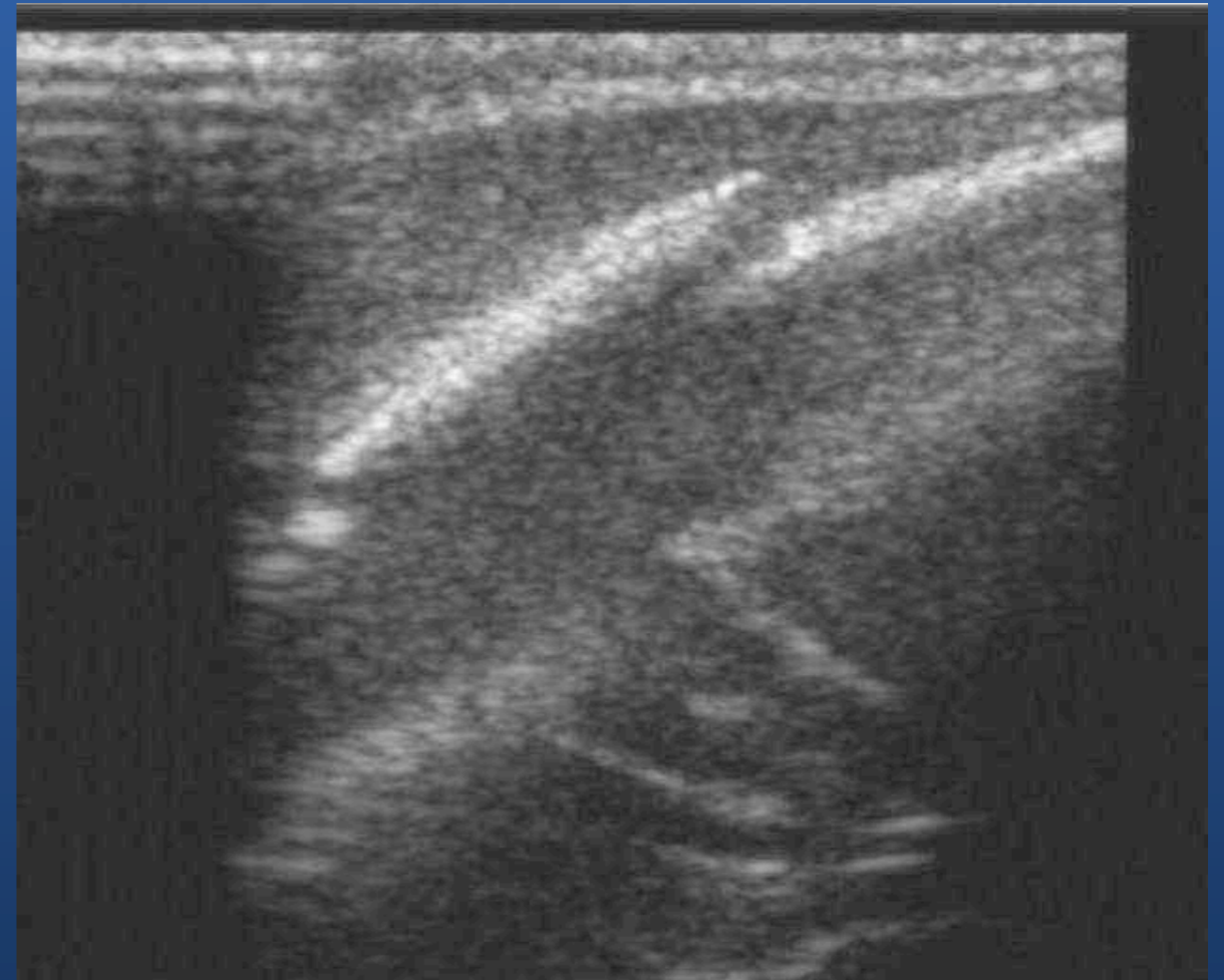LESIONS TRAUMATIQUES

- Difficultés diagnostiques
- TDM au moindre doute
- Echographie
 - phase initiale
 - surveillance

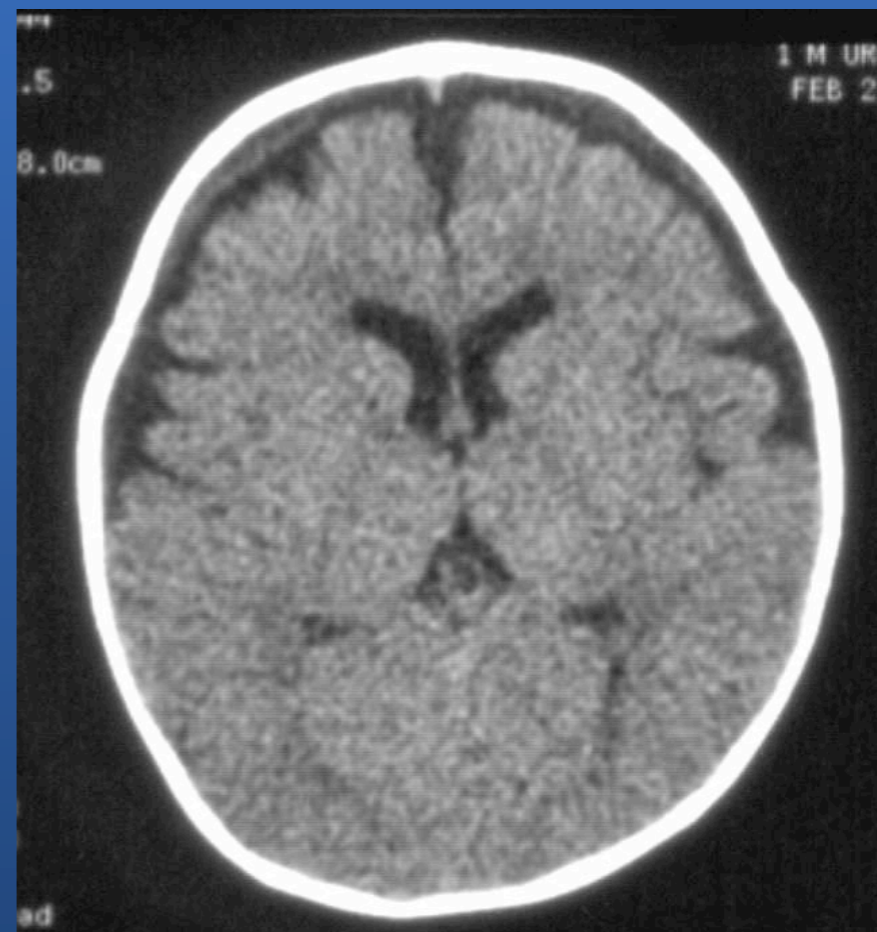
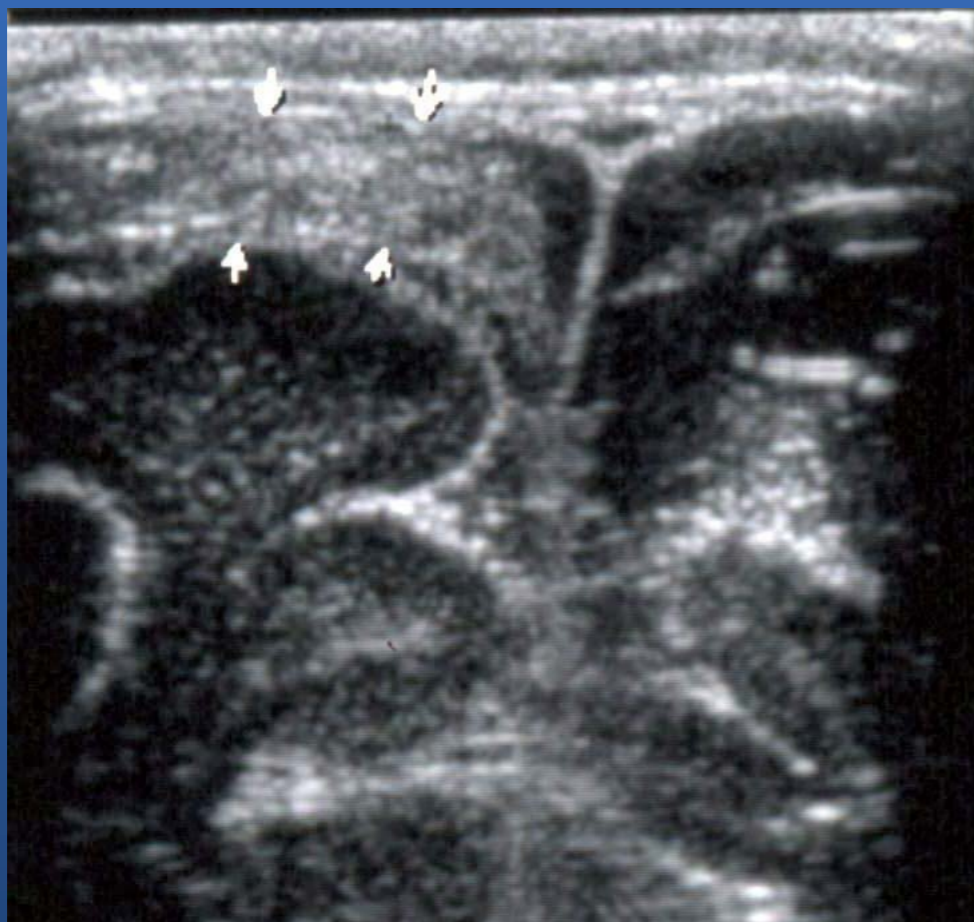
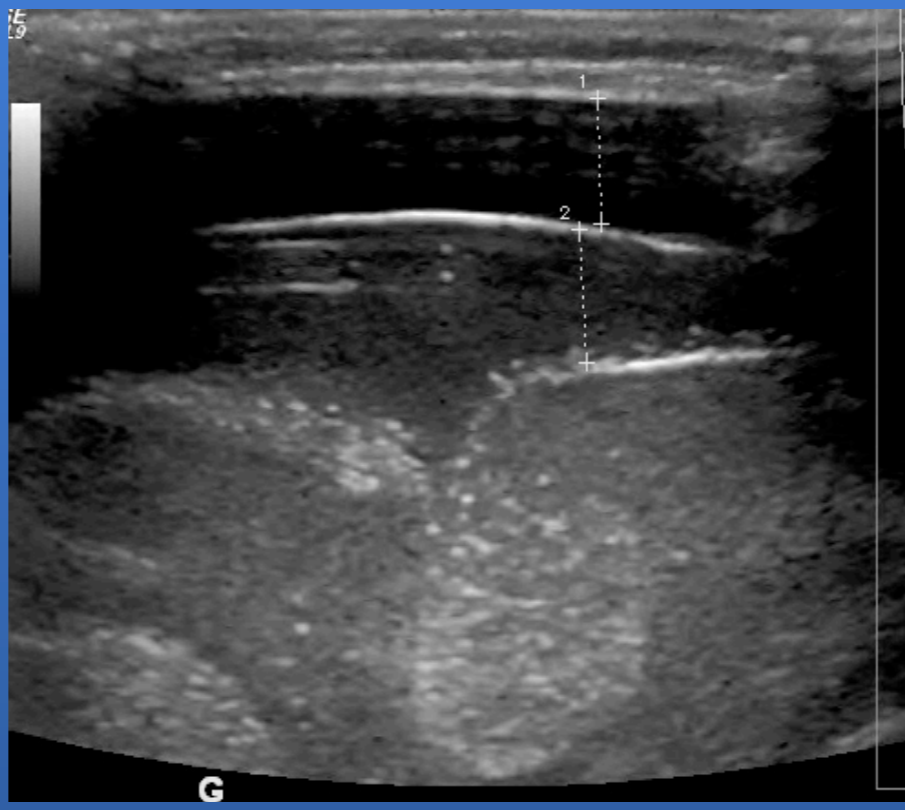
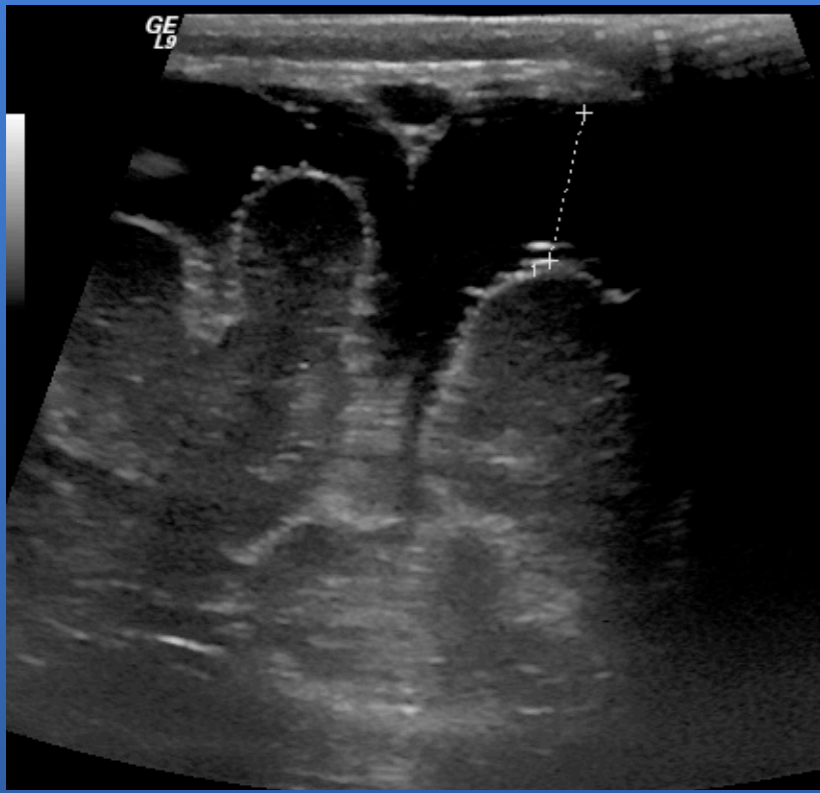
TRAUMATISMES : SEMIOLOGIE

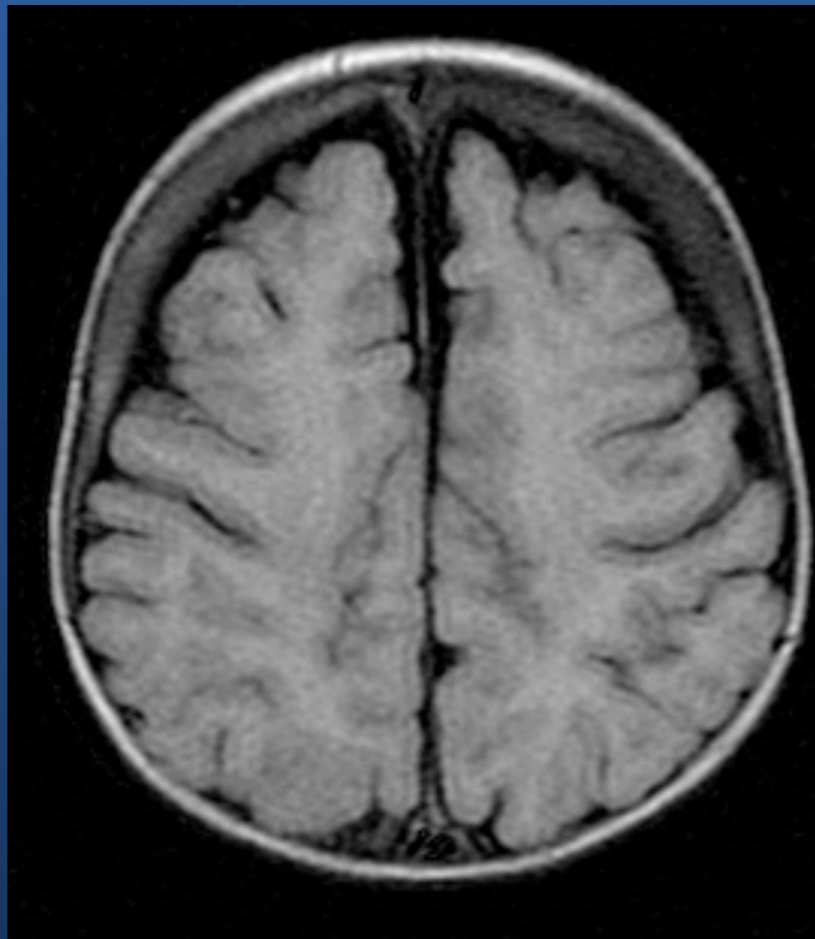
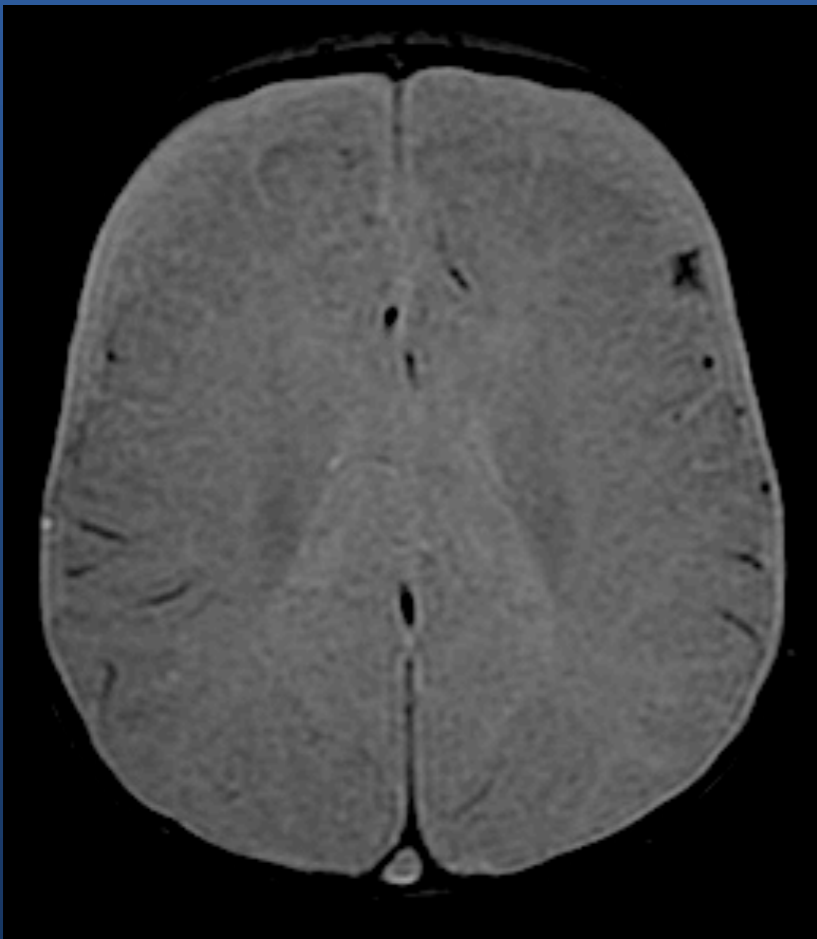
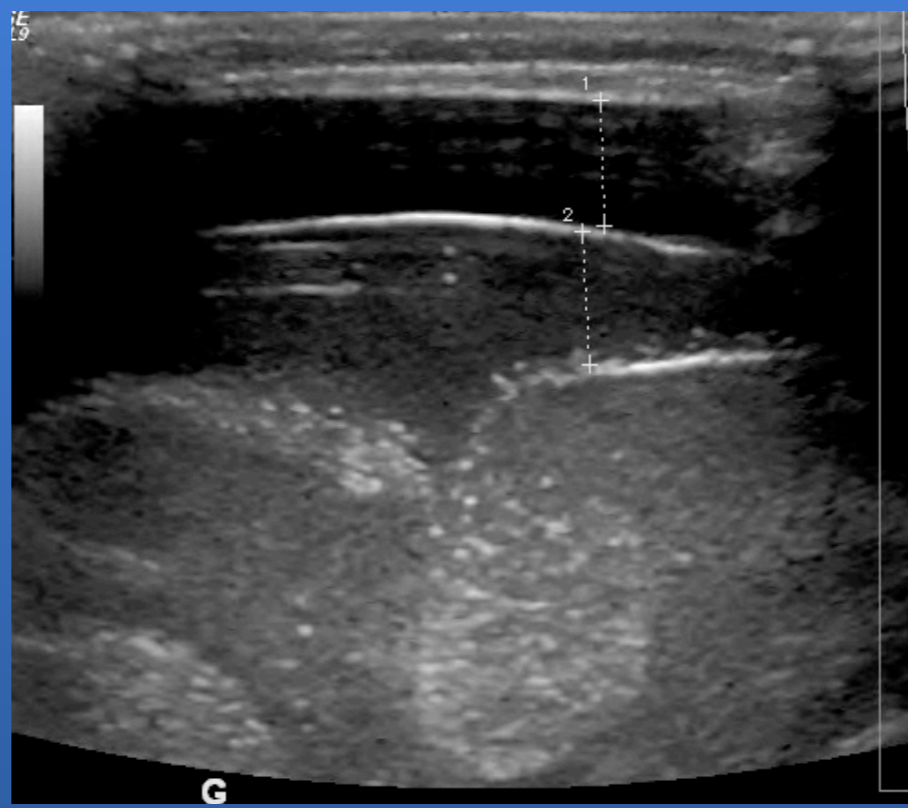
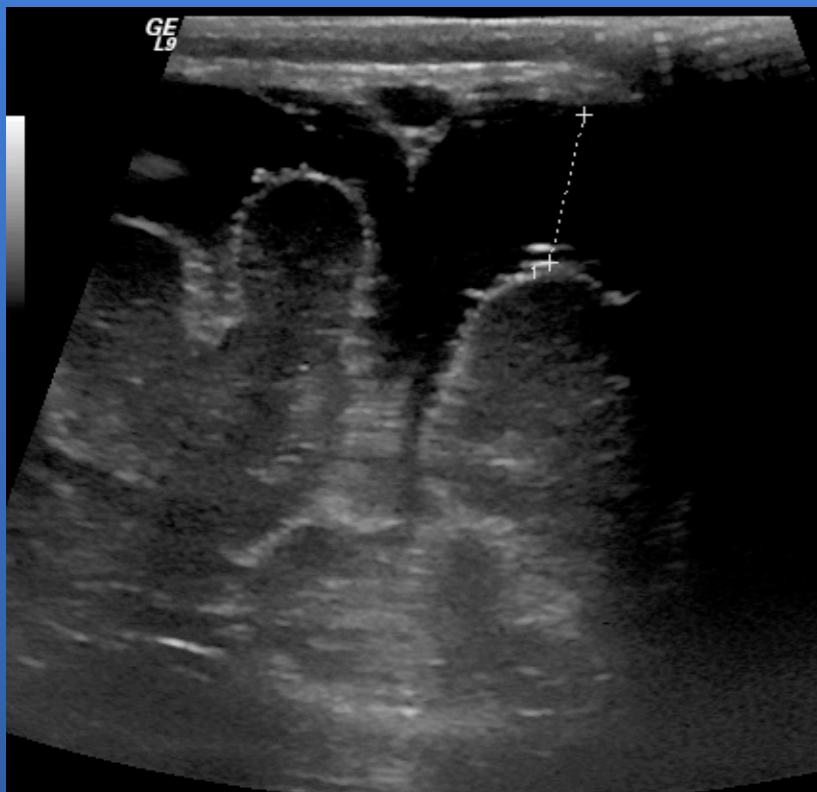
- **Signes directs**
 - collection péri-cérébrale
 - hématome intracrânien
- **Signes indirects**
 - effet de masse
 - dilatation ventriculaire

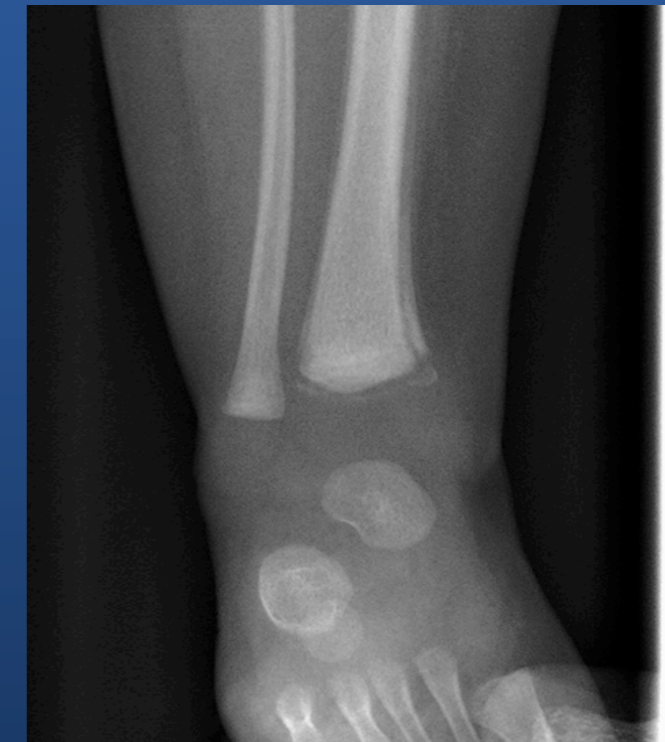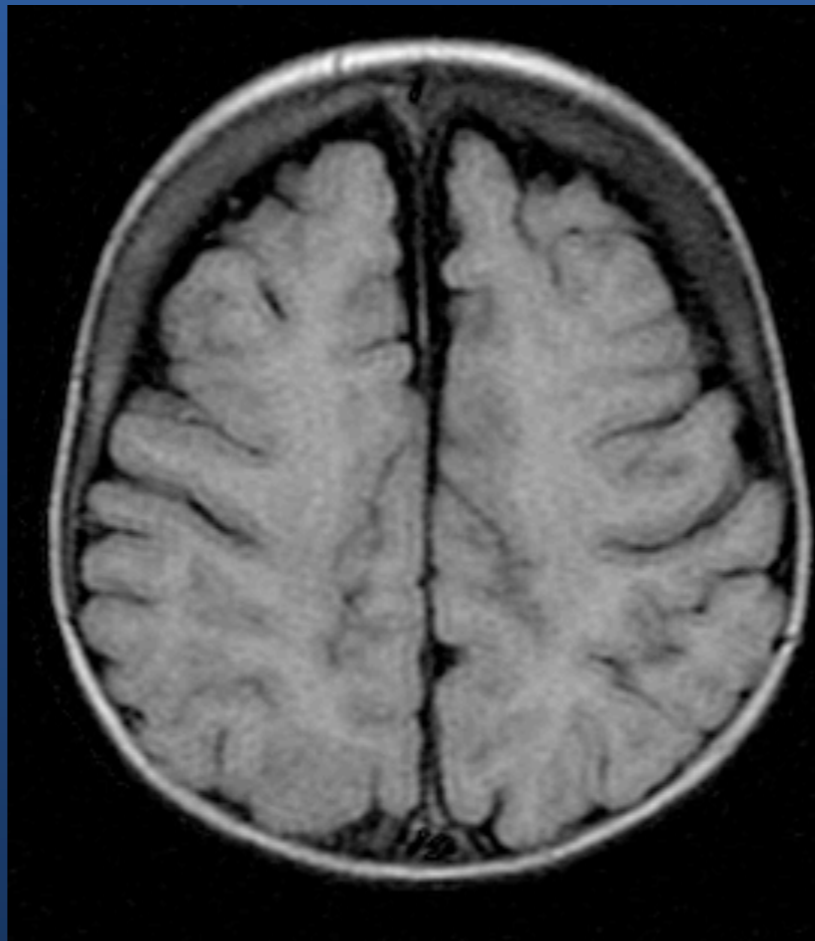
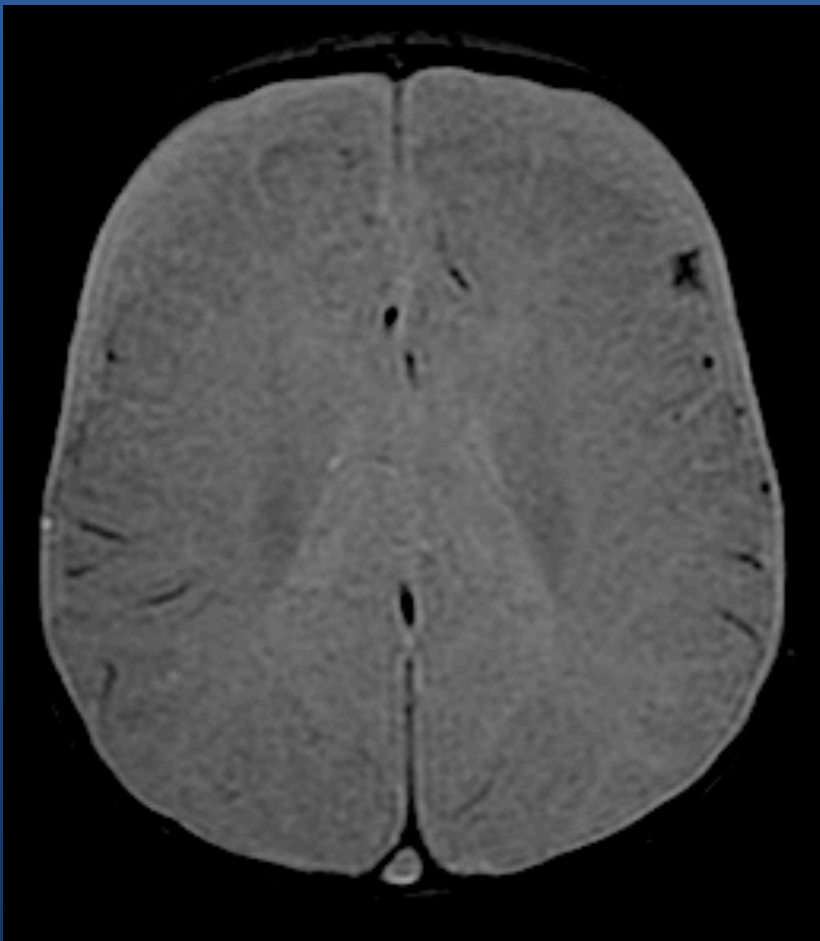
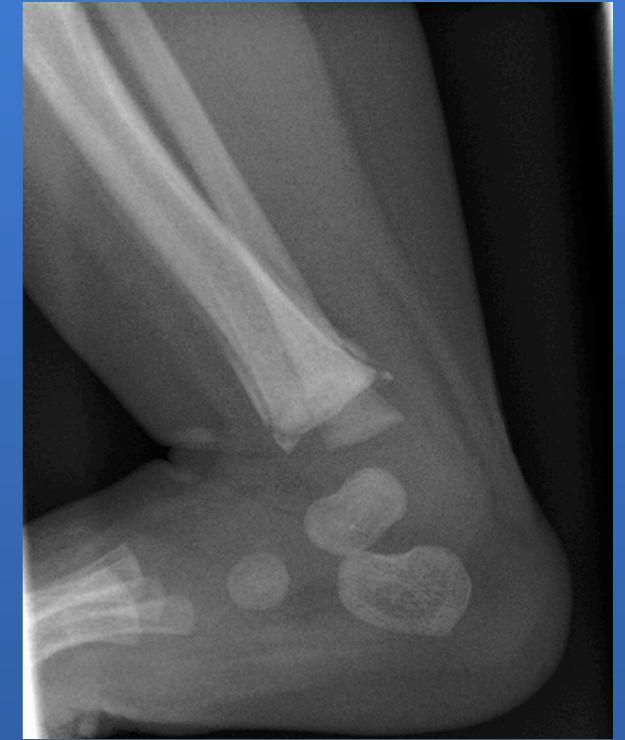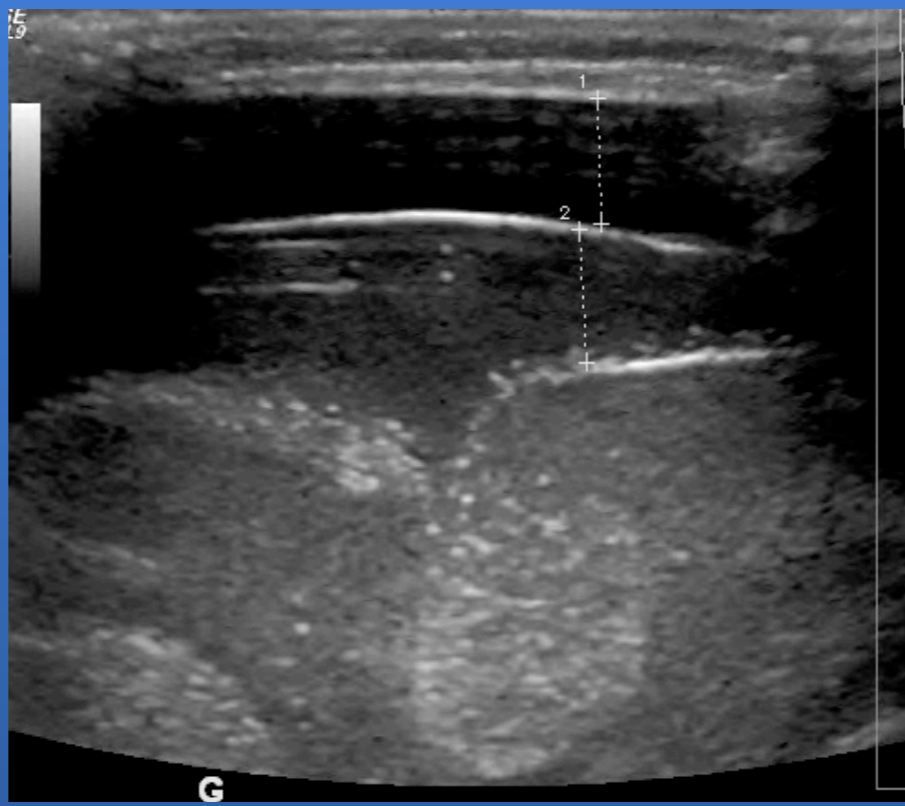
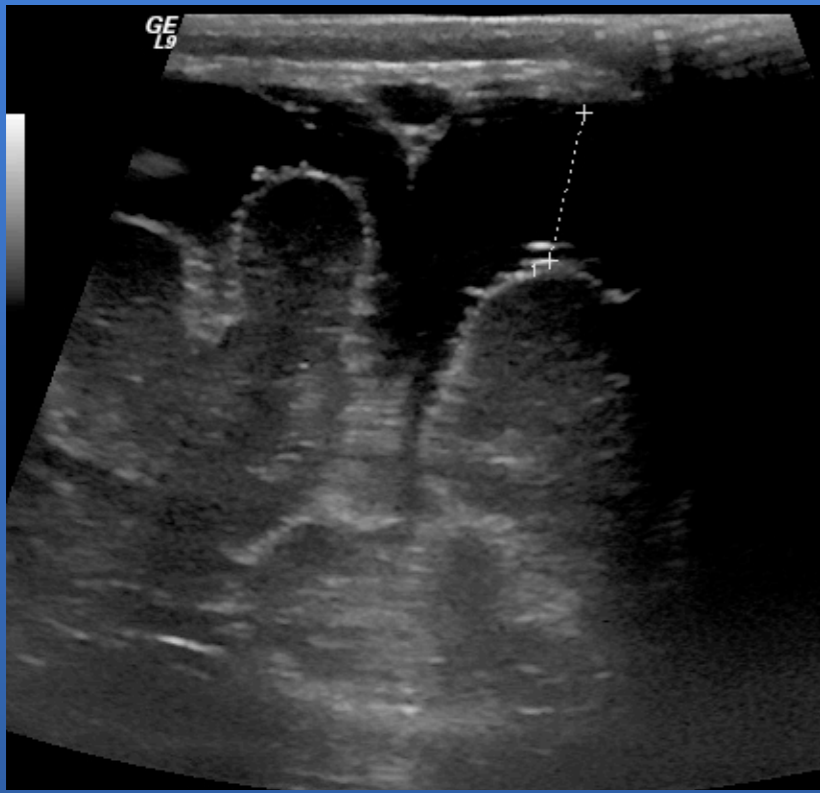


TRAUMATISMES



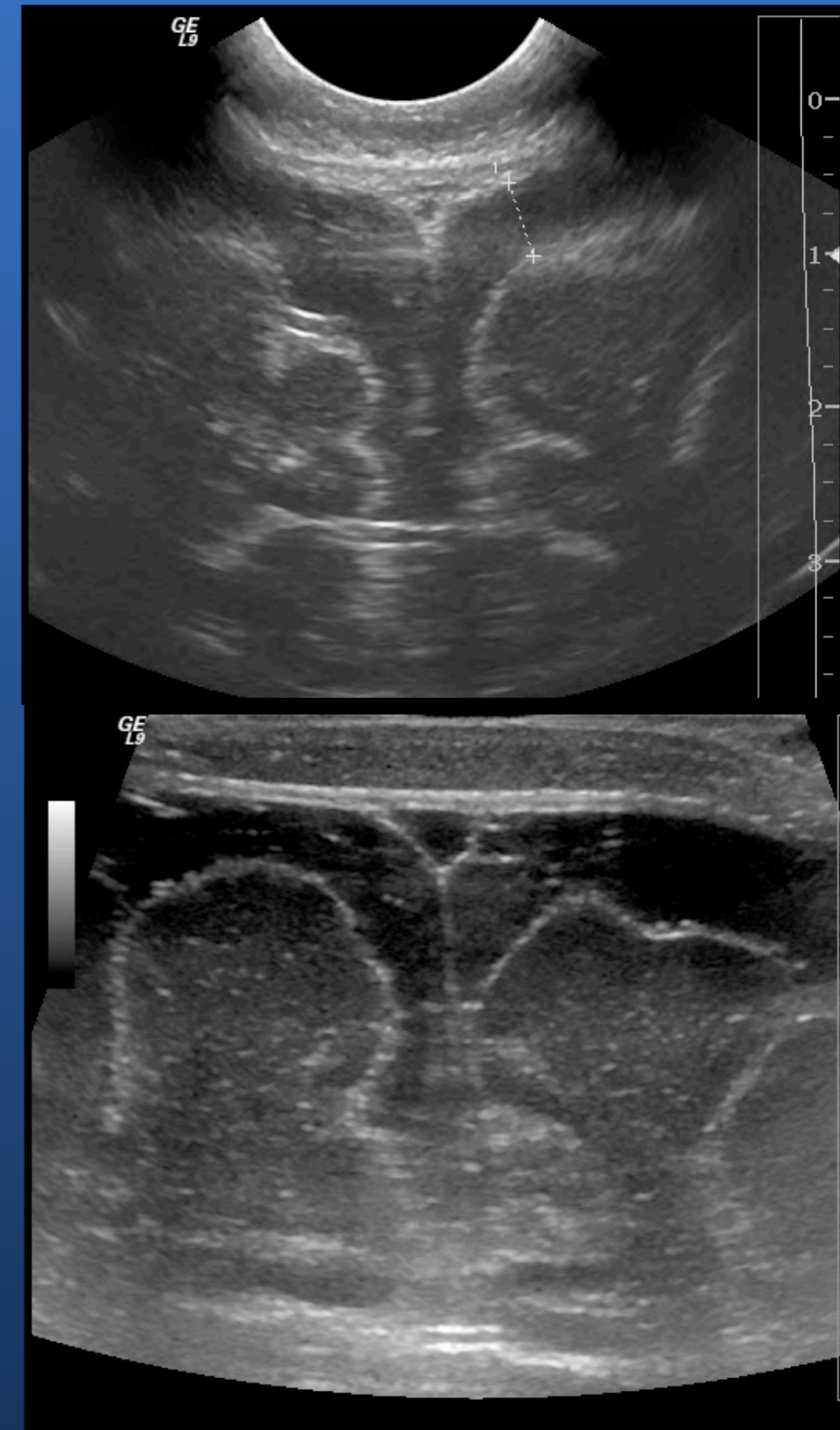






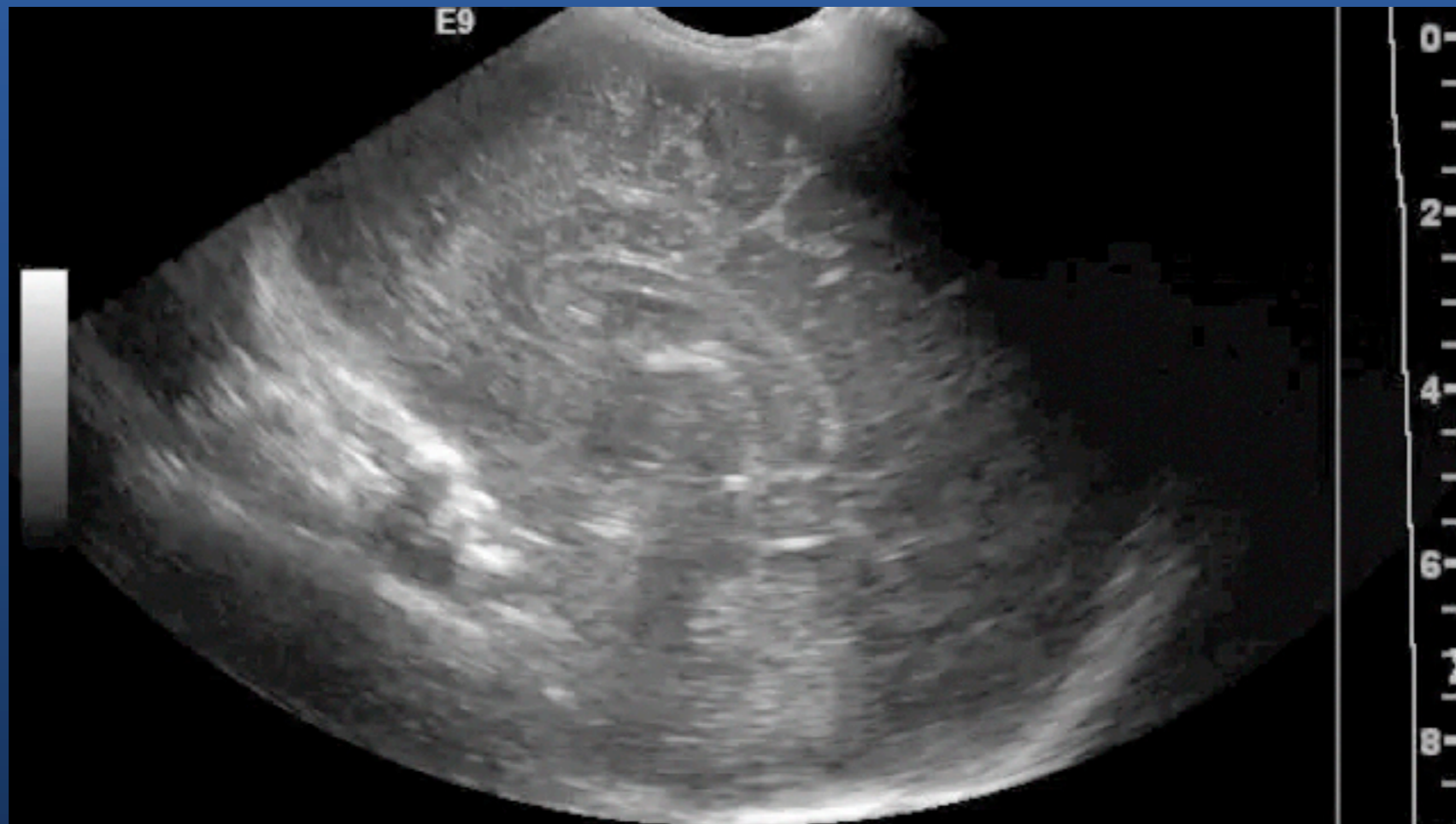
MACROCRANIE FAMILIALE

- Augmentation progressive du PC
- Isolée
- ATCD familiaux ?
- Dilatation modérée des espaces péricérébraux
- Sous arachnoïdiens
- Pas d'autre anomalie
- Simple surveillance

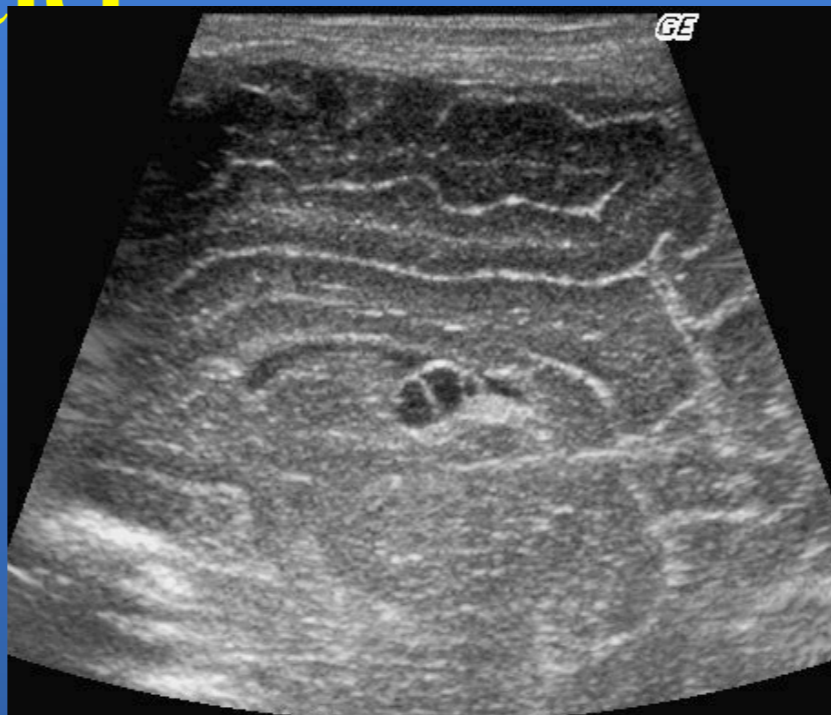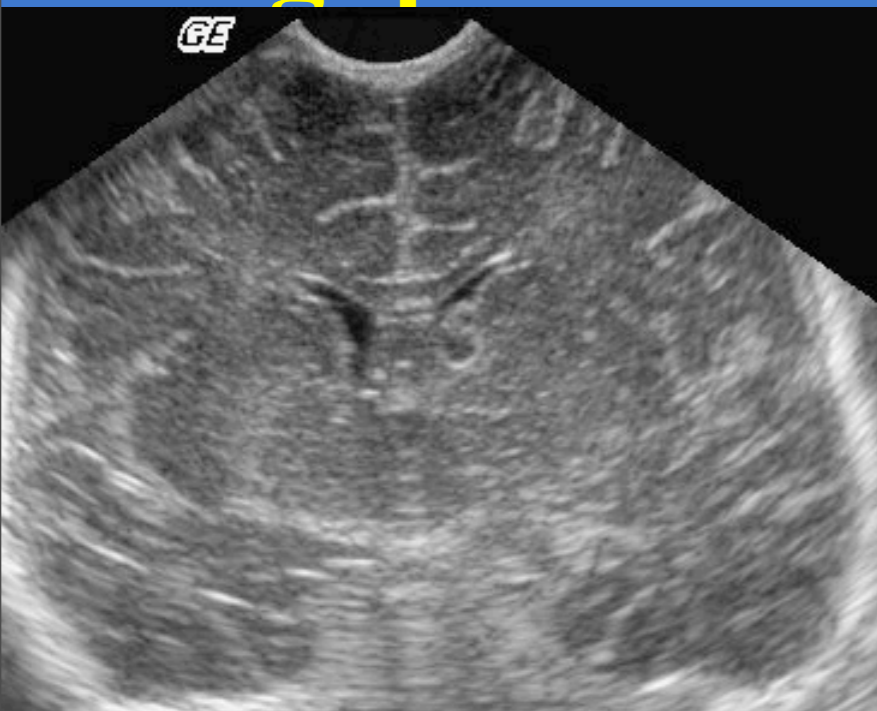


CONCLUSION

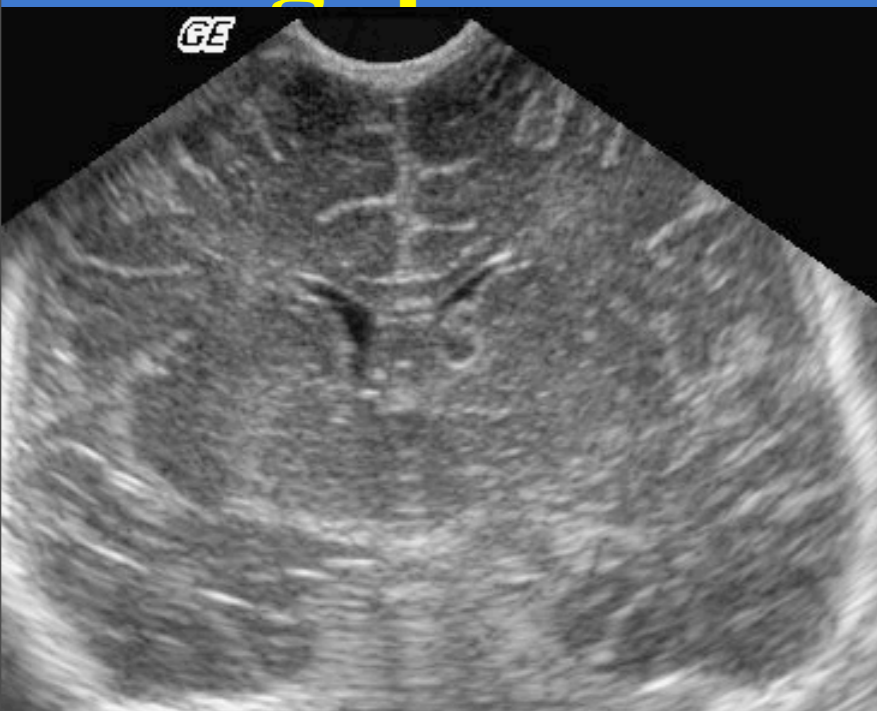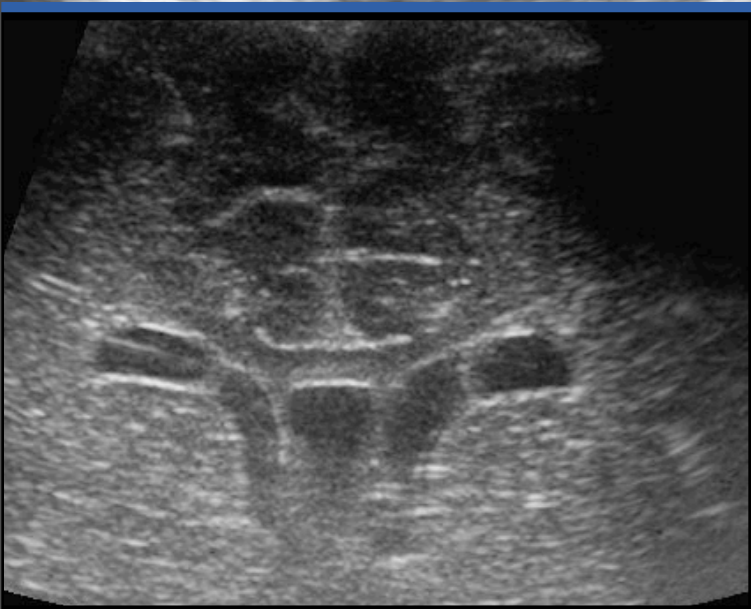
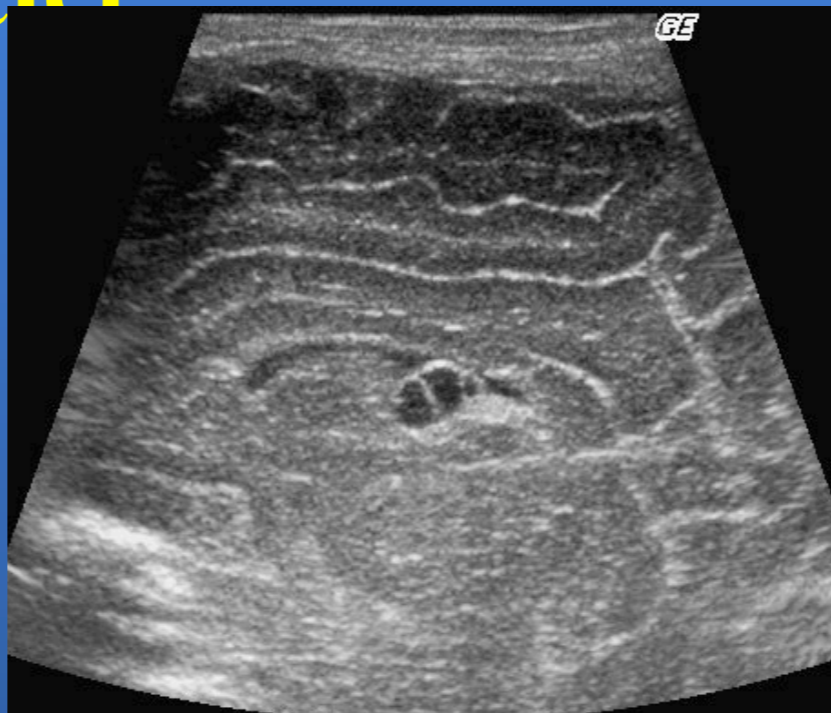- **E.T.F examen clé dans le dépistage des principales pathologies du nouveau né et du nourrisson**
- **Examen clé dans la surveillance des pathologies**



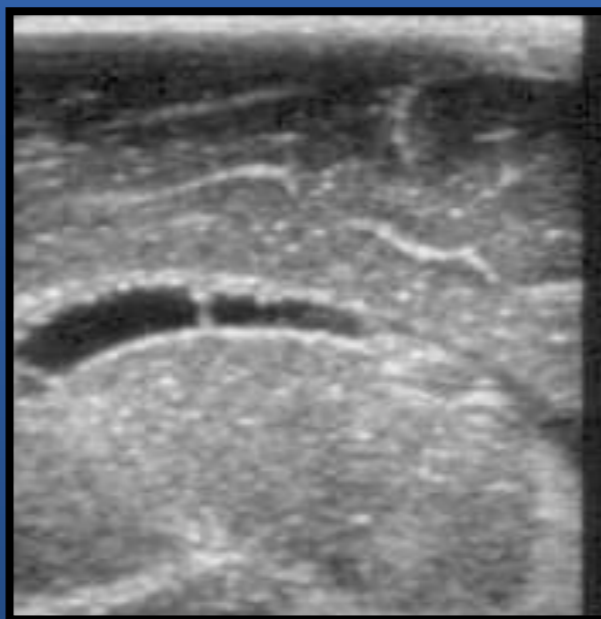
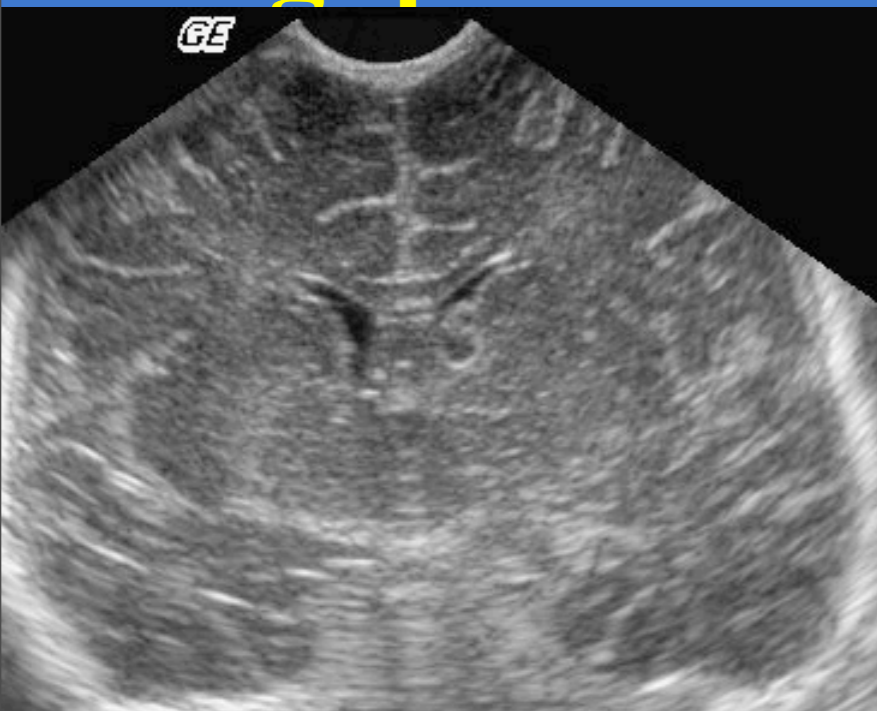
• Diagnostic différentiel •



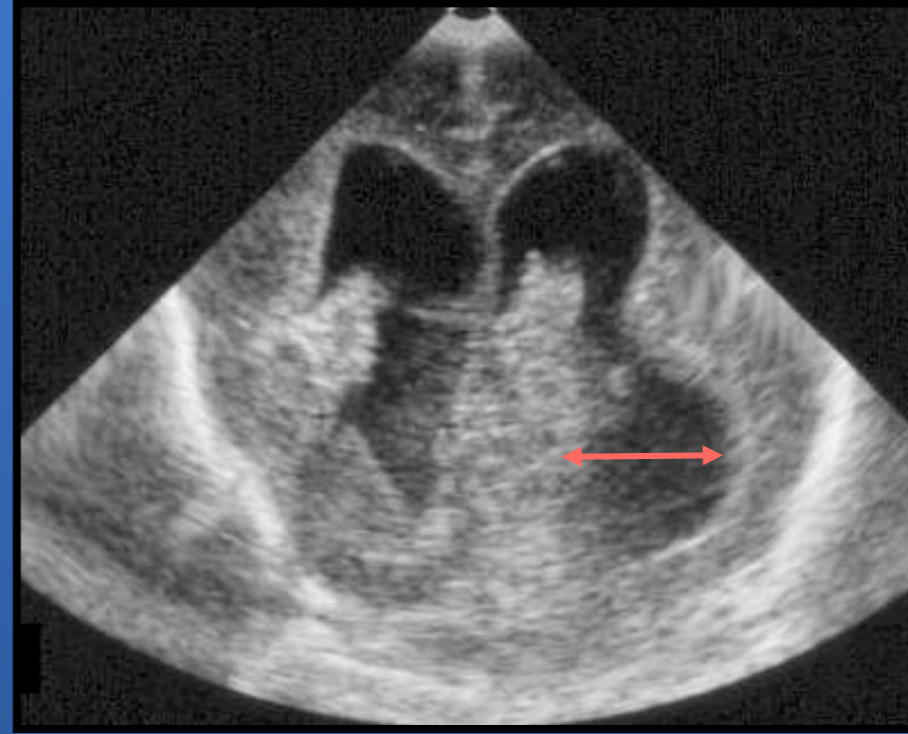
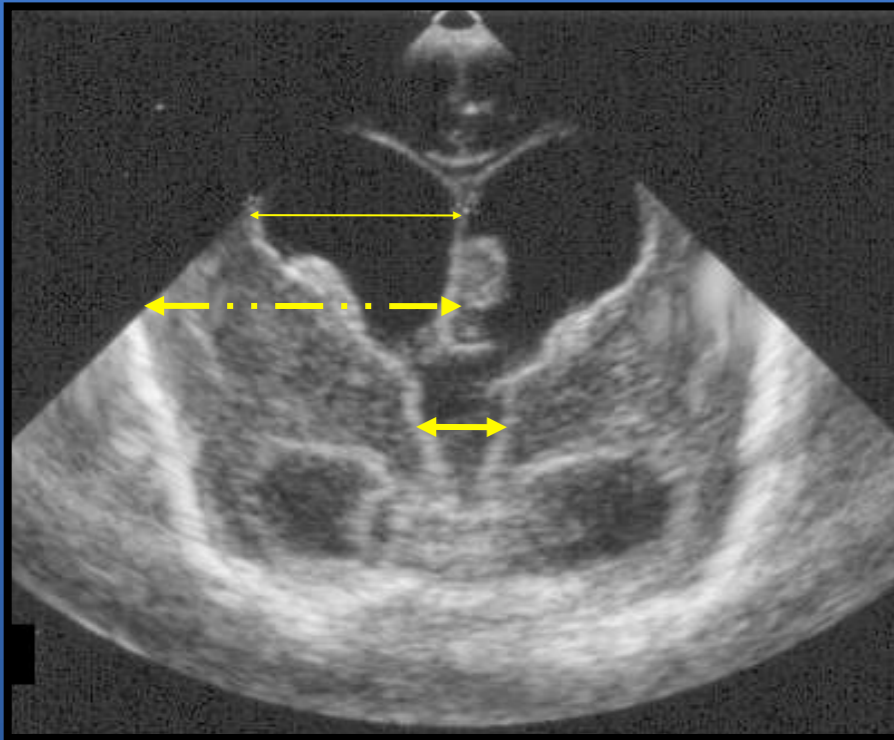
• Diagnostic différentiel •



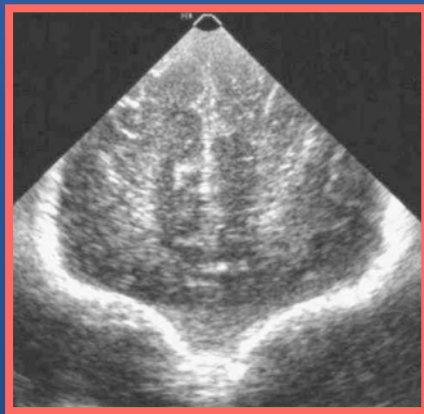
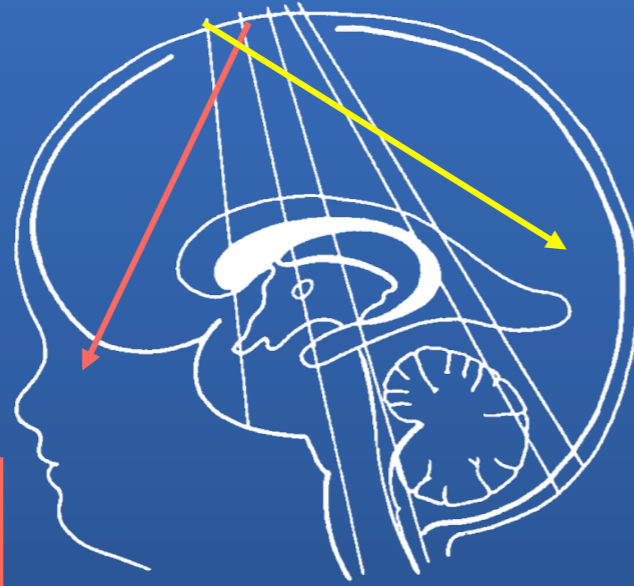
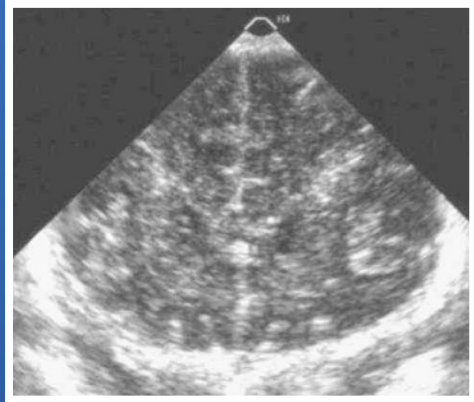
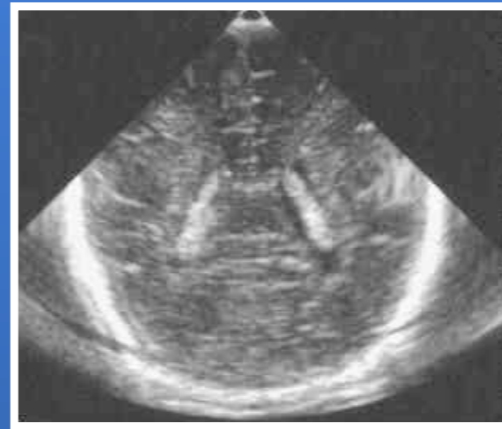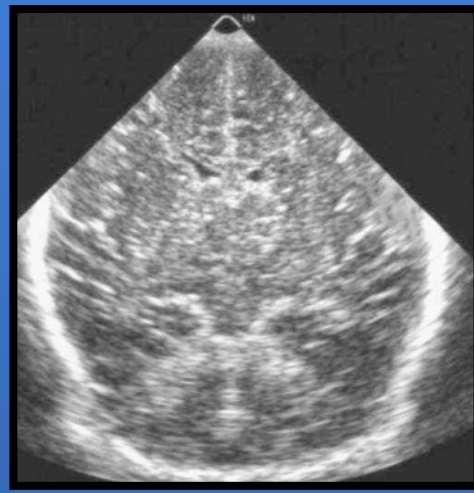
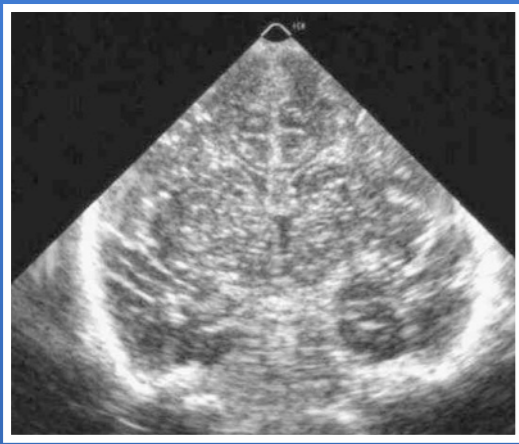• Diagnostic différentiel •



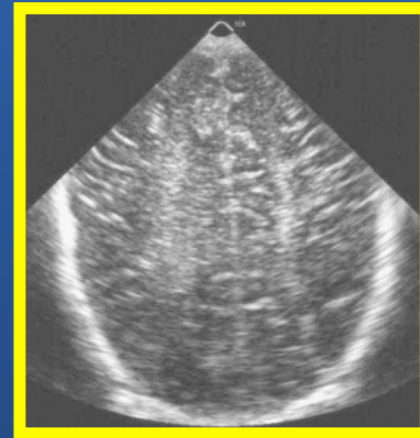
DILATATION VENTRICULAIRE

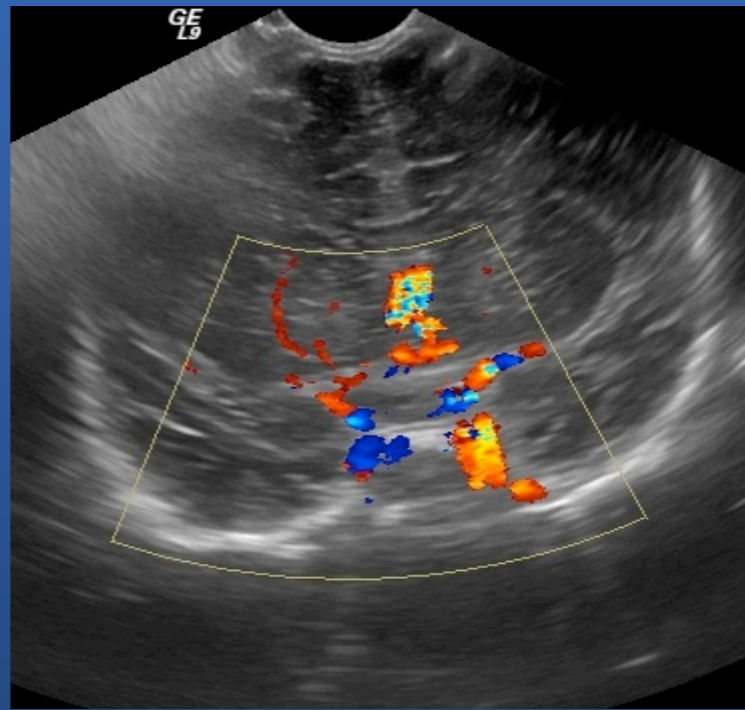
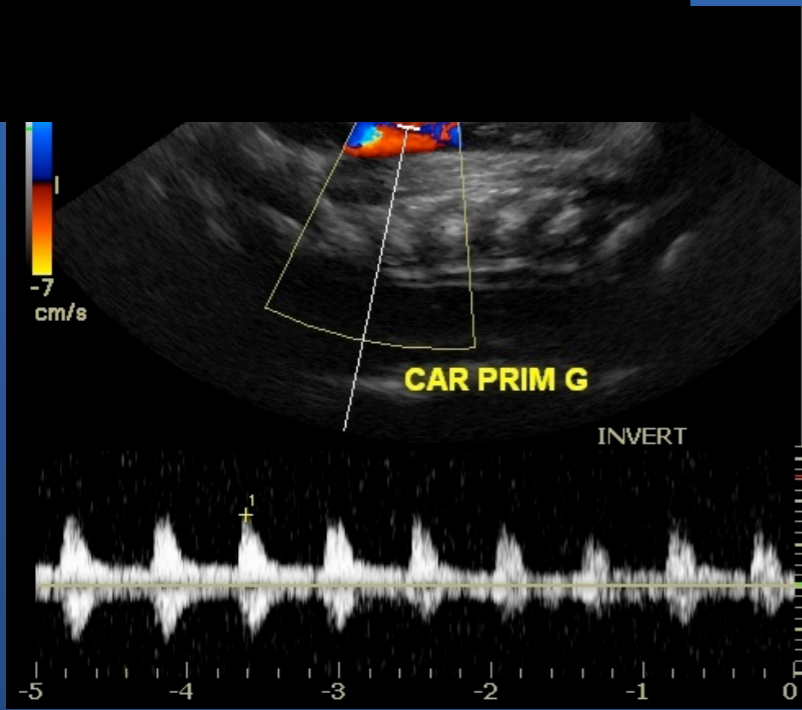
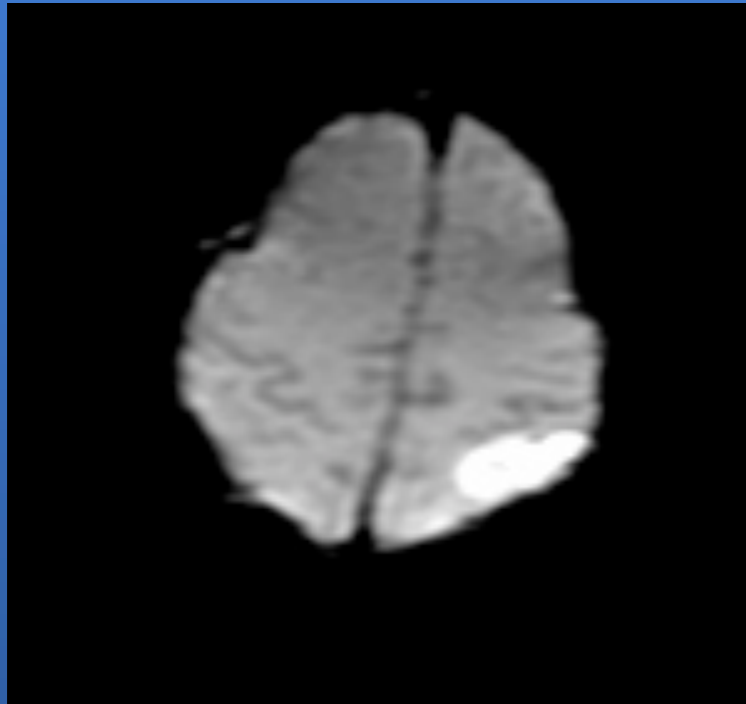


- **Biométrie normale**
 - V3 : 3-4 mm
 - V latéraux :
 - carrefour : 6-8 mm
 - Rapport ventriculo-hémisphérique



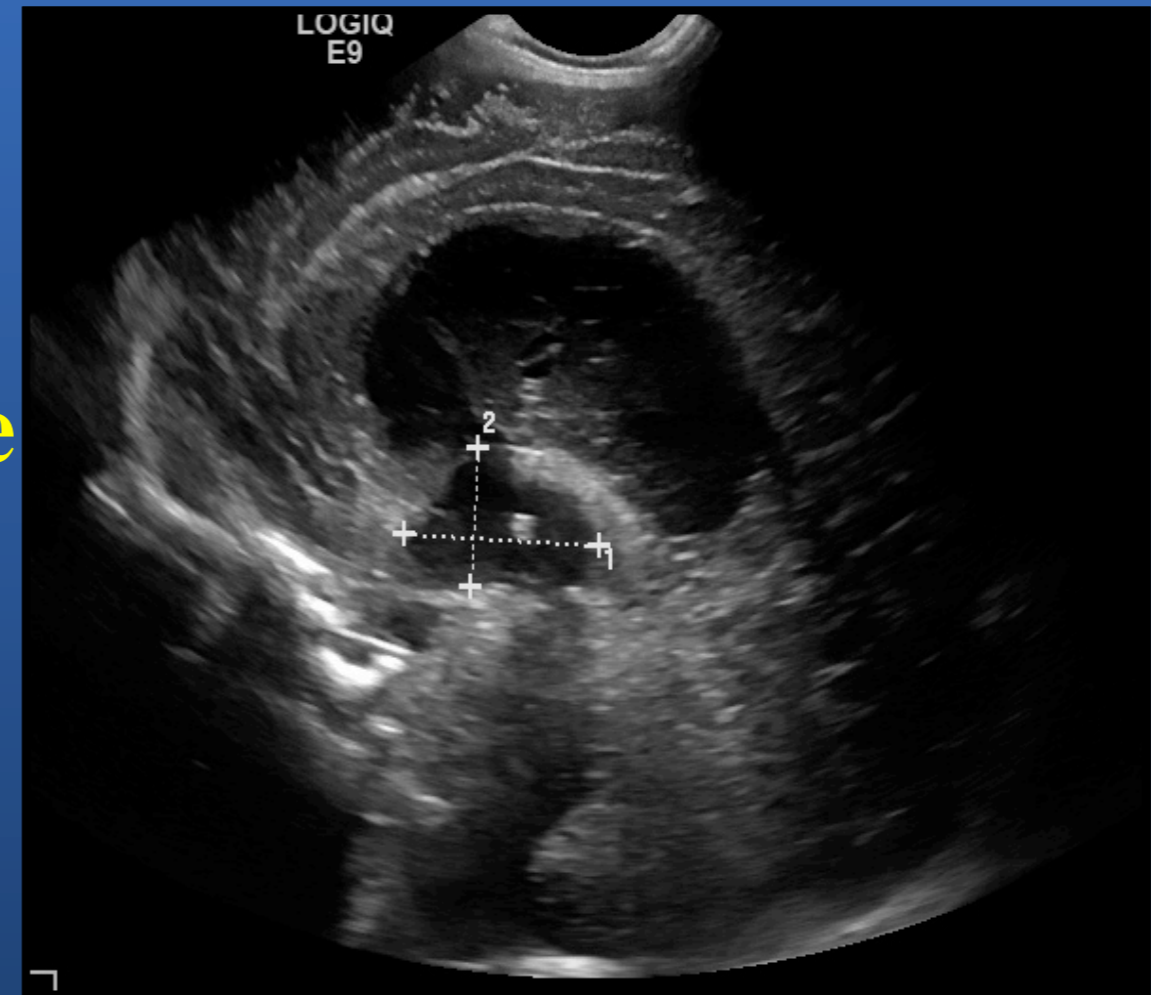
coupes





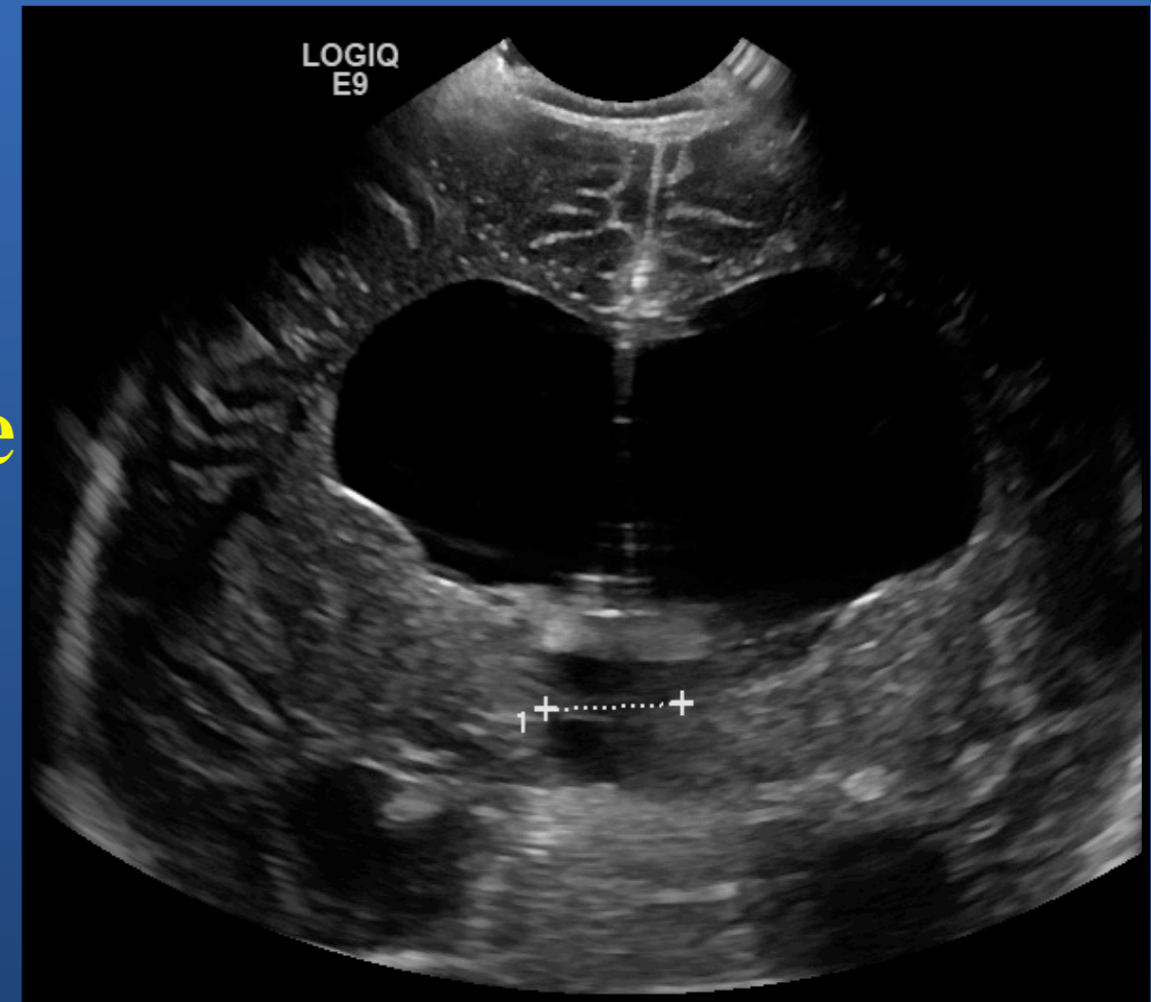
DILATATION VENTRICULAIRE

- **Topographie**
 - VL, V3, V4
- **Quantification**
- **Pathologie sous-jacente ?**
 - Malformative : lésion associée
 - Séquelle ?
 - Atteinte infectieuse ?
 - Hémorragie ?
 - Pathologie tumorale ?
- **État des espaces pericérébraux ?**



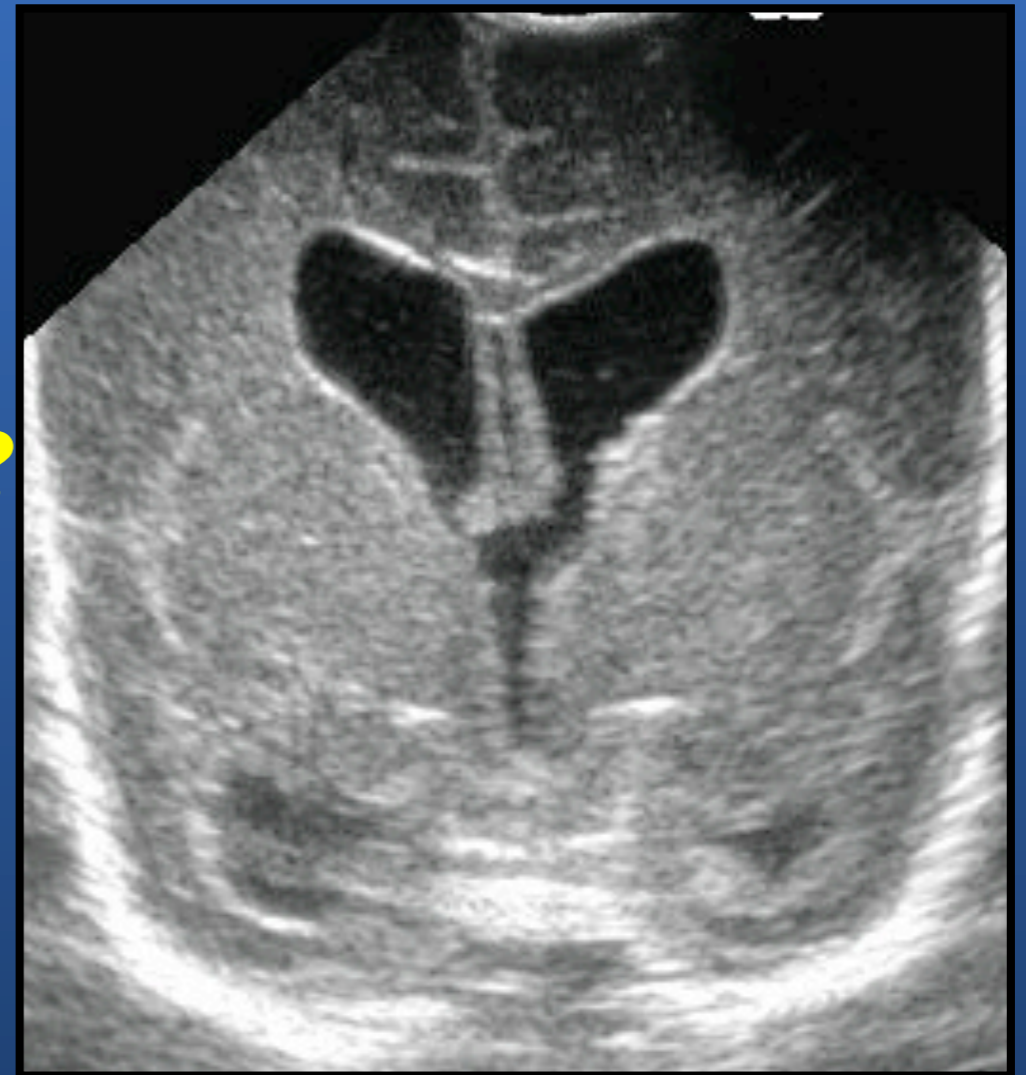DILATATION VENTRICULAIRE

- **Topographie**
 - VL, V3, V4
- **Quantification**
- **Pathologie sous-jacente ?**
 - Malformative : lésion associée
 - Séquelle ?
 - Atteinte infectieuse ?
 - Hémorragie ?
 - Pathologie tumorale ?
- **État des espaces pericérébraux ?**



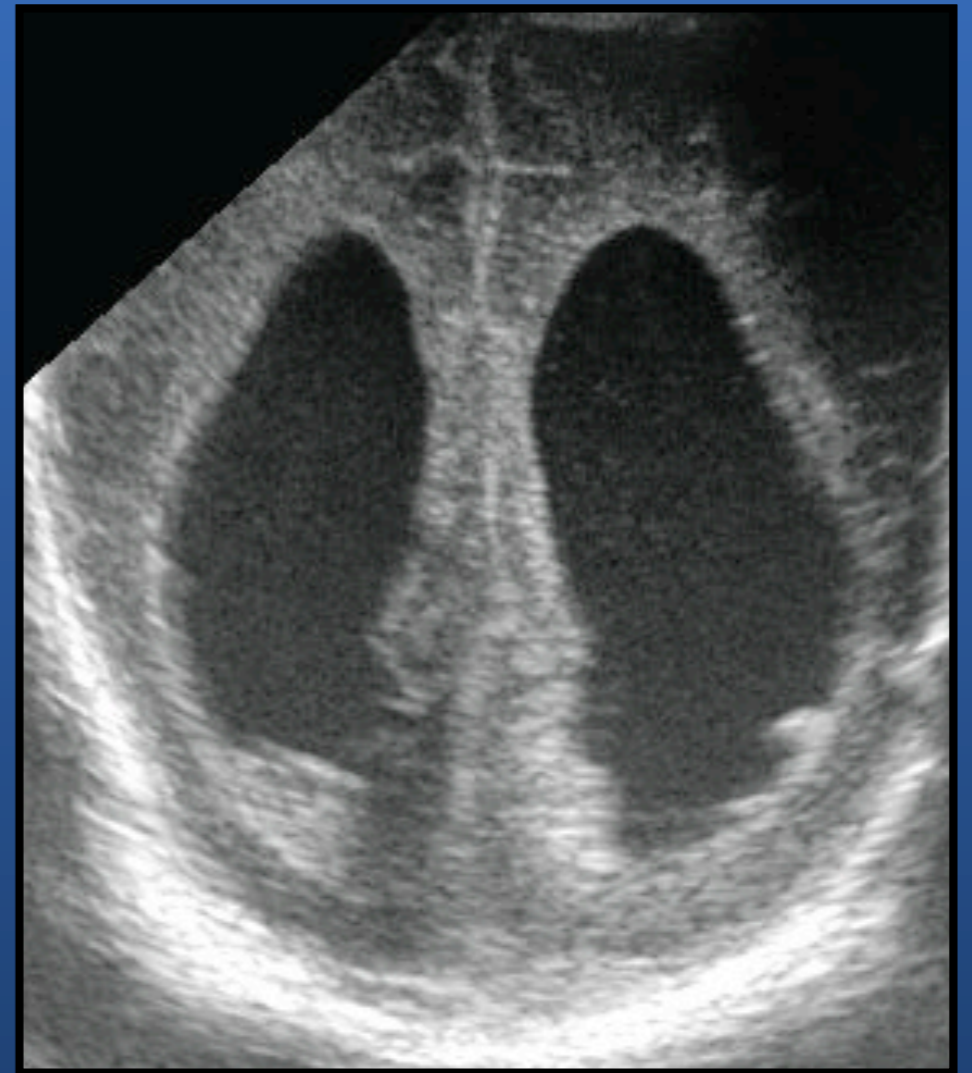
DILATATION VENTRICULAIRE

- **Topographie**
 - VL, V3, V4
- **Quantification**
- **Pathologie sous-jacente ?**
 - Malformative : lésion associée ?
 - Séquelle ?
 - Atteinte infectieuse ?
 - Hémorragie ?
 - Pathologie tumorale ?
- **État des espaces pericérébraux !**



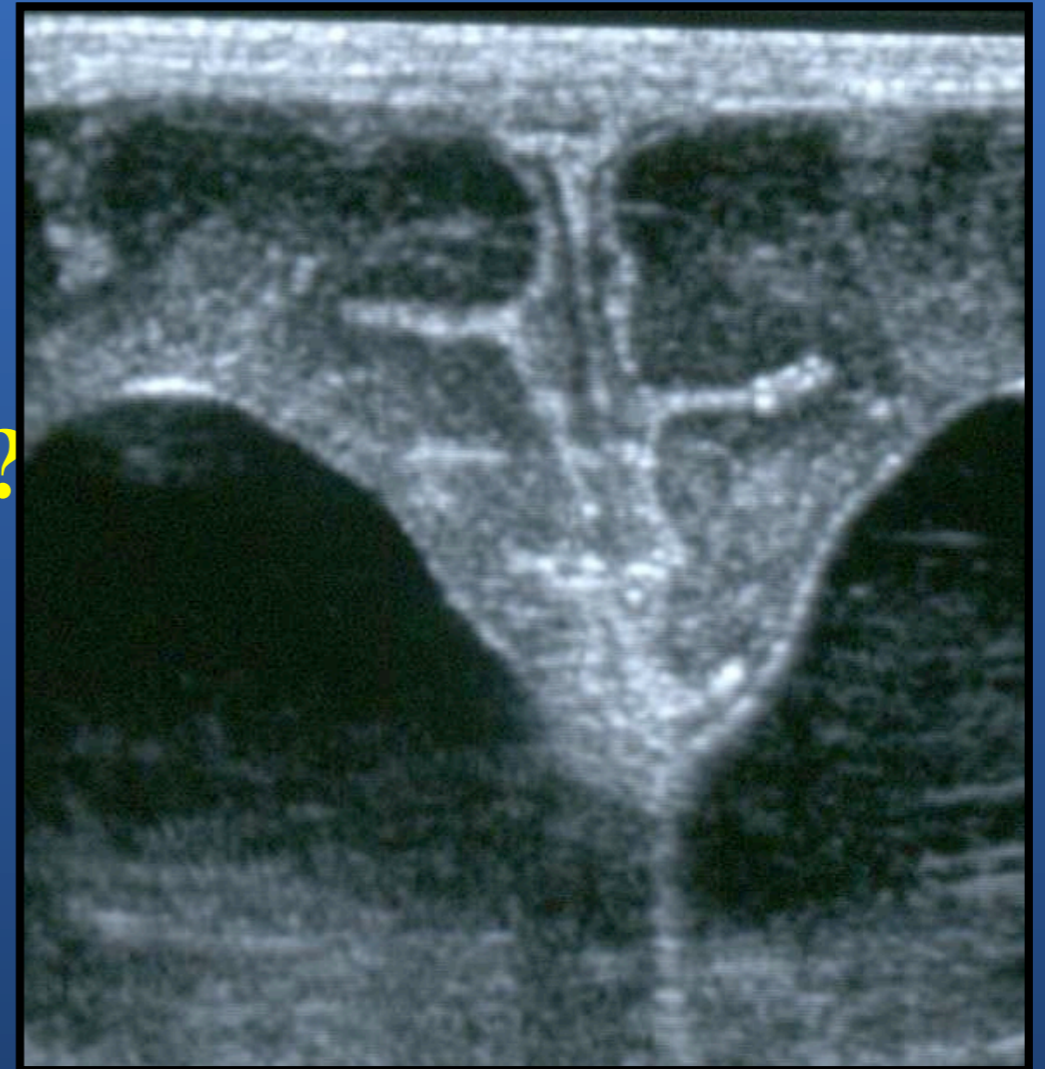
DILATATION VENTRICULAIRE

- **Topographie**
 - VL, V3, V4
- **Quantification**
- **Pathologie sous-jacente ?**
 - Malformative : lésion associée ?
 - Séquelle ?
 - Atteinte infectieuse ?
 - Hémorragie ?
 - Pathologie tumorale ?
- **État des espaces pericérébraux ?**



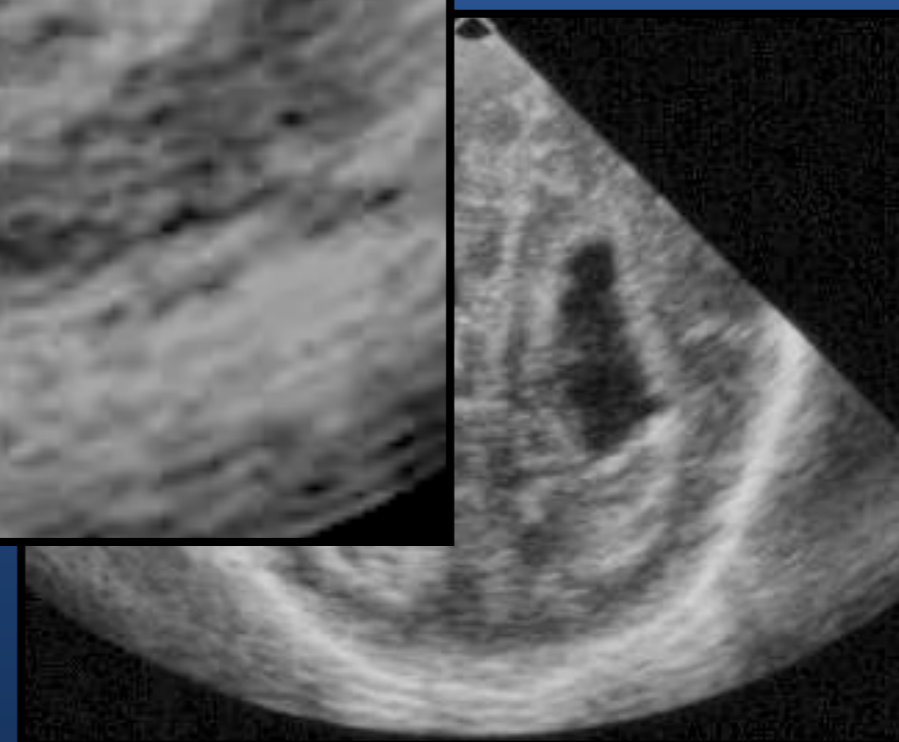
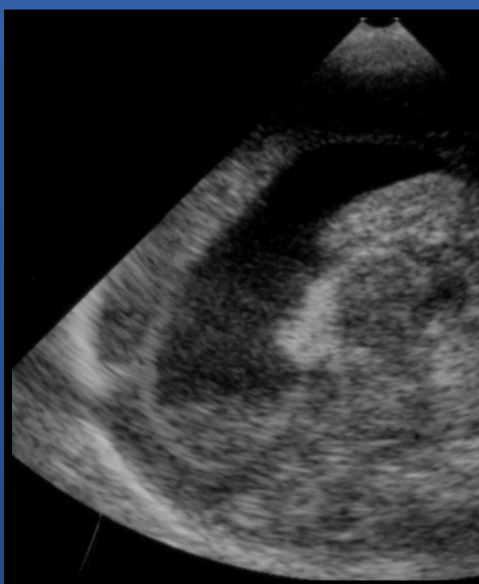
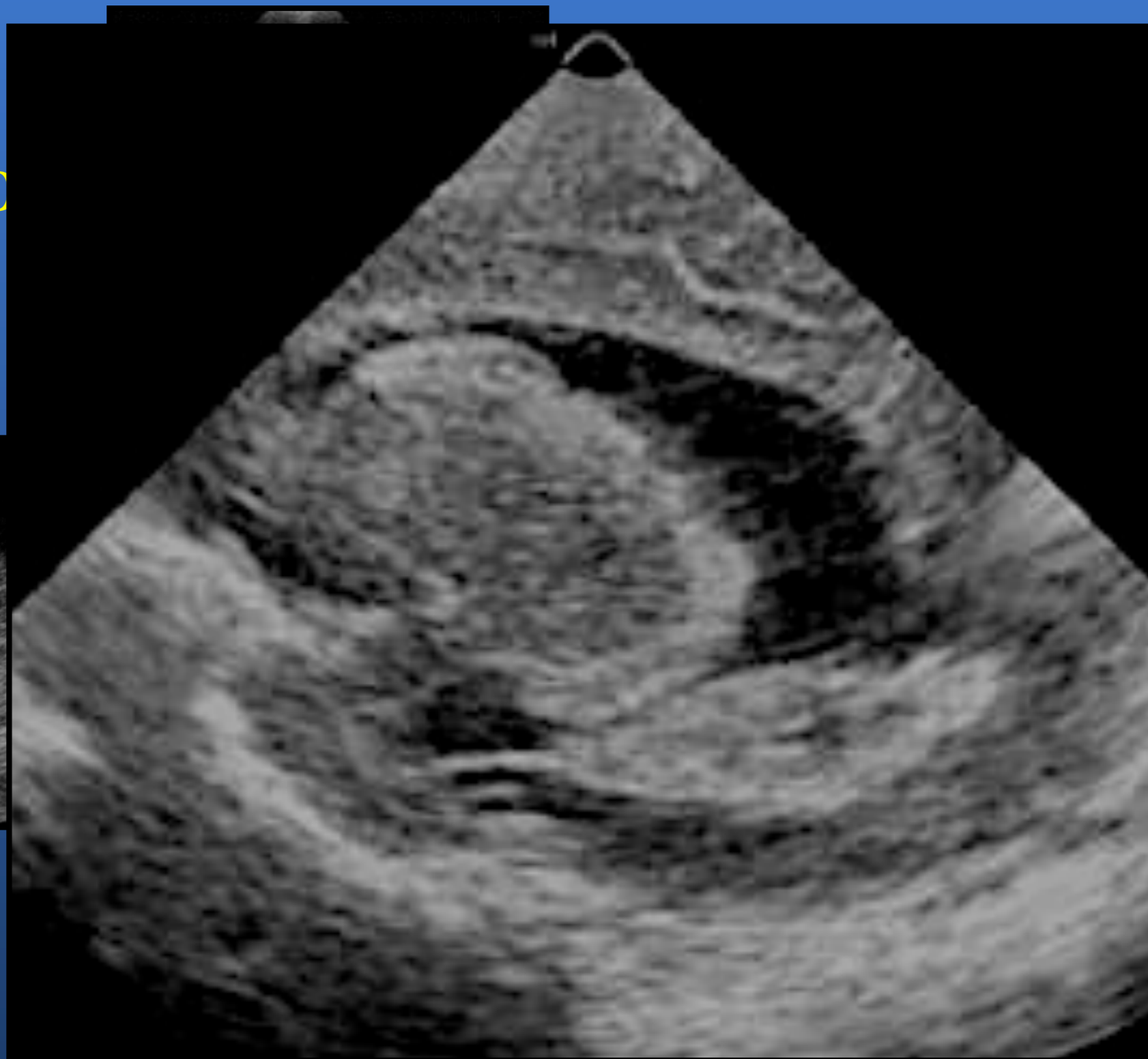
DILATATION VENTRICULAIRE

- **Topographie**
 - VL, V3, V4
- **Quantification**
- **Pathologie sous-jacente ?**
 - Malformative : lésion associée ?
 - Séquelle ?
 - Atteinte infectieuse ?
 - Hémorragie ?
 - Pathologie tumorale ?
- **État des espaces pericérébraux ?**



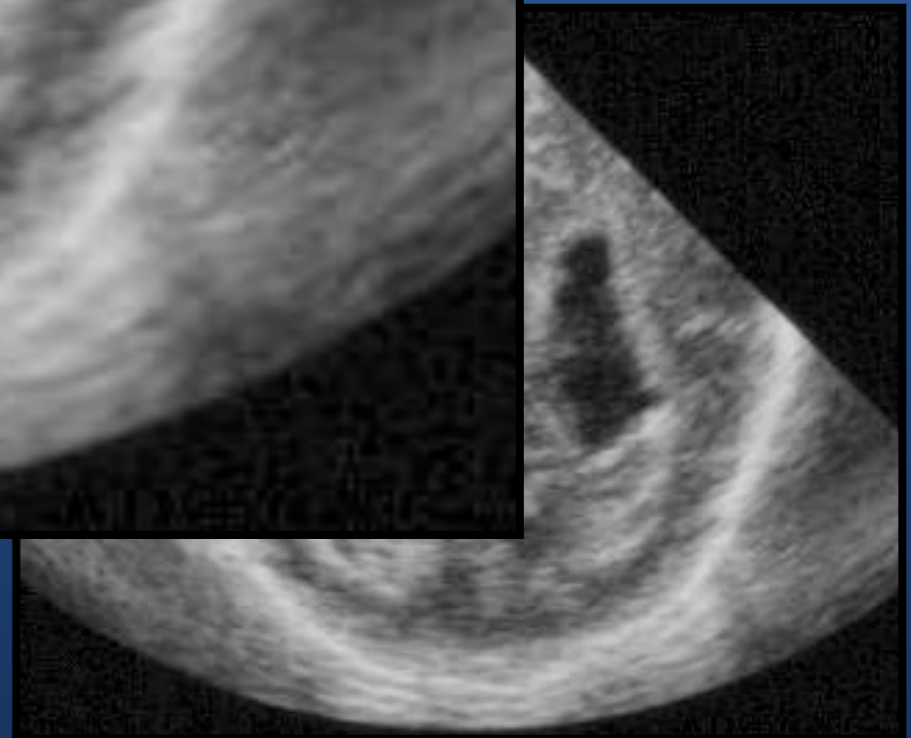
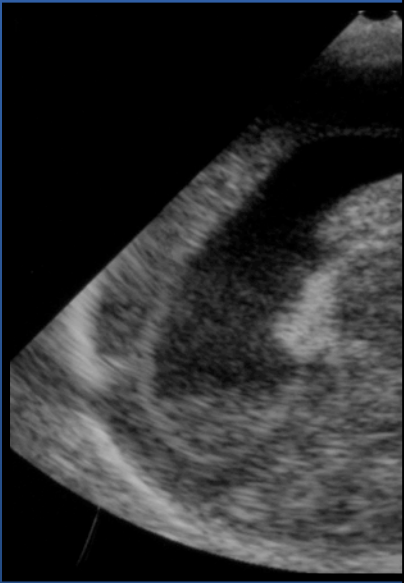
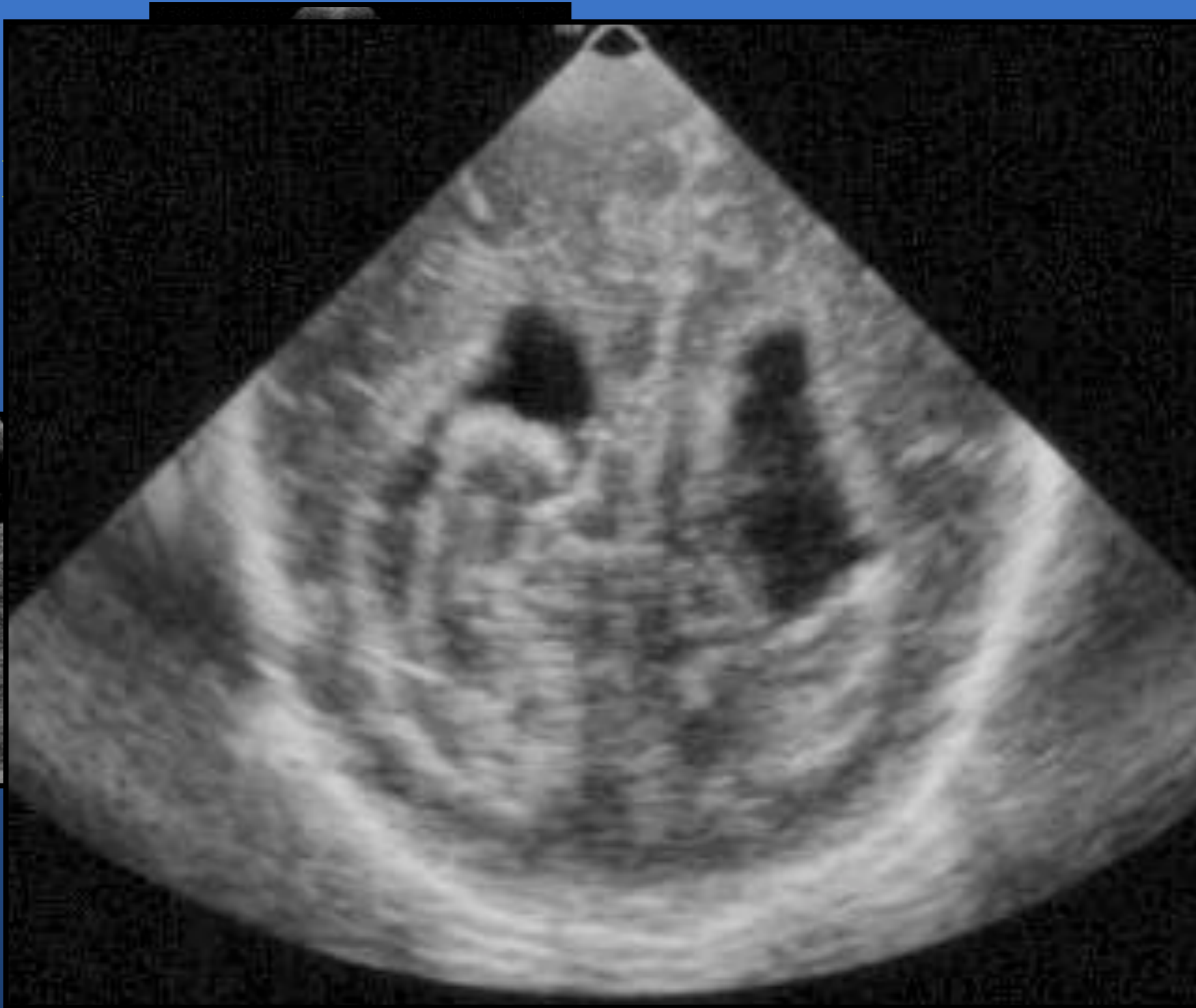
HEMORRAGIE VENTRICULAIRE :

DILATATION



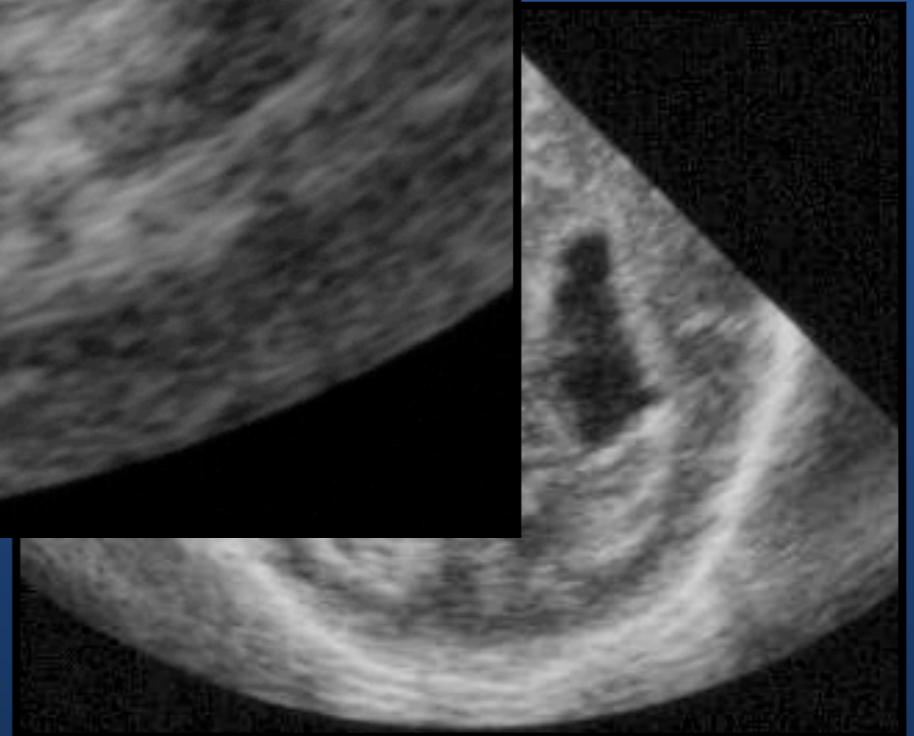
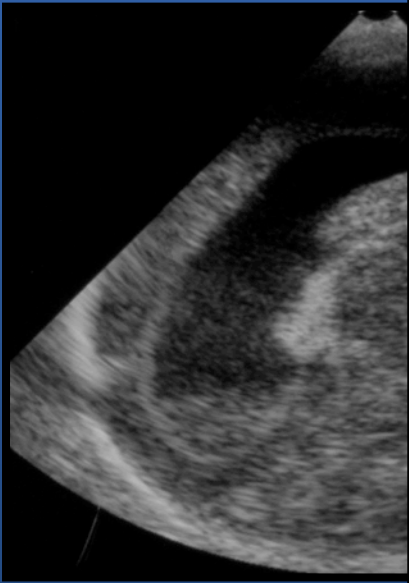
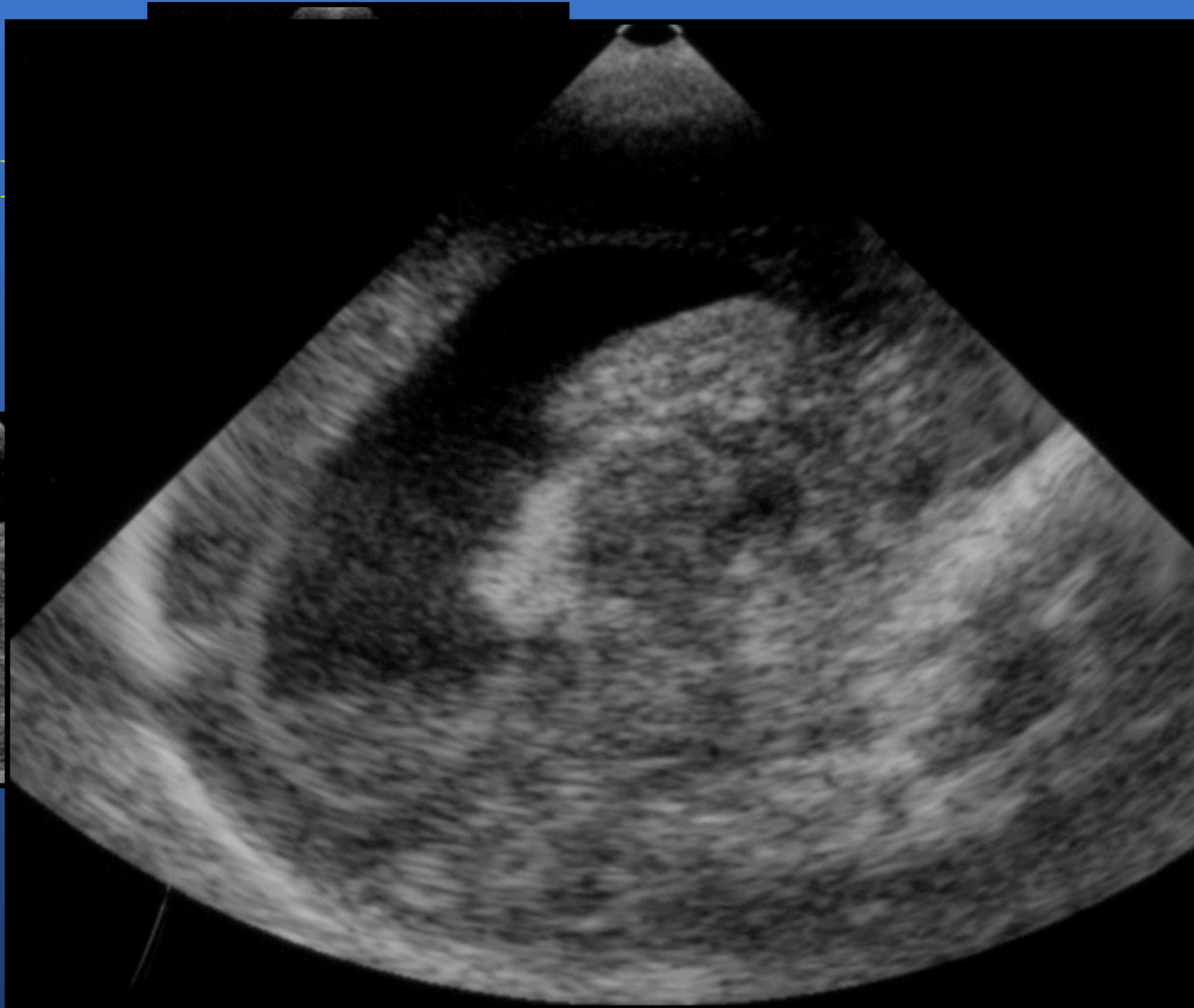
HEMORRAGIE VENTRICULAIRE :

DILATAT



HEMORRAGIE VENTRICULAIRE :

DILATAT



HEMORRAGIE VENTRICULAIRE :

DILATATION

