

IMAGERIE EN URGENCE TRAUMATISME CRANIEN



CHU DE NANTES

LA FIN DES STANDARDS



LE SCANNER

Mai 1979 à Mai 2009

30 ans de scanner à Nantes

Coupes rapides

Coupes jointives

Fenêtres

→ osseuse

→ parenchymateuse

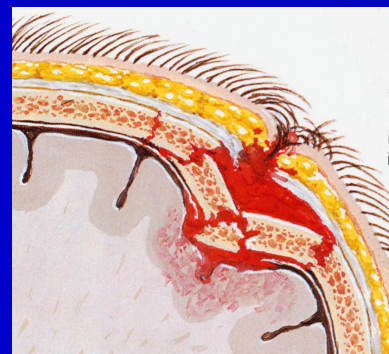LE SCANNER

- Lésion neurochirurgicale
- Pronostic

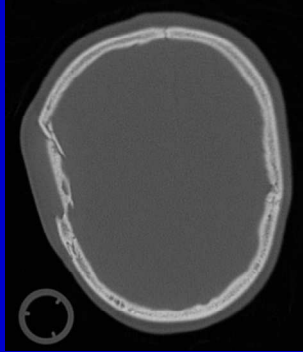
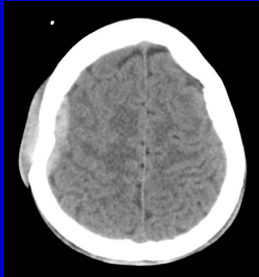
ÉTUDE DE LA BOÎTE

- Fracture
- Embarrure

EMRARURE



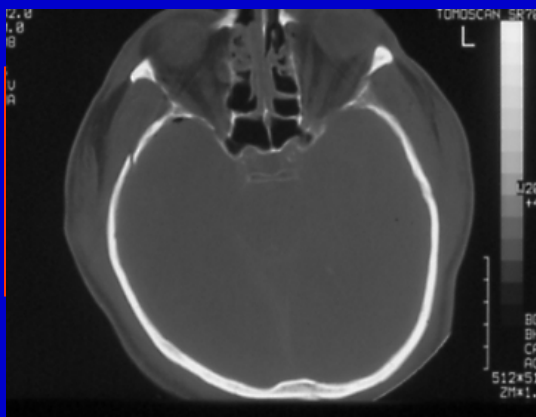
EMRARURE



CHERCHER LA BULLE NOIRE

=

FRACTURE OUVERTE



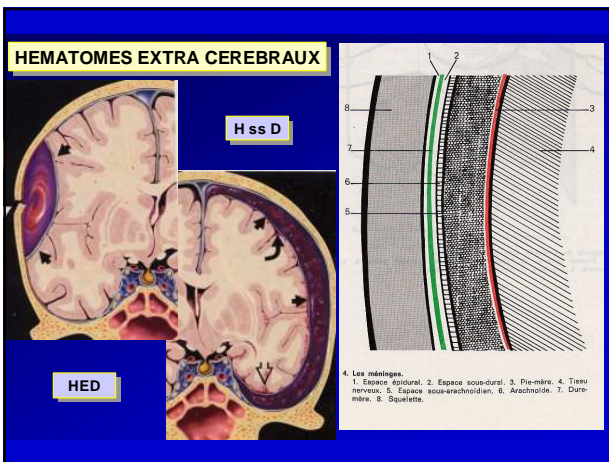
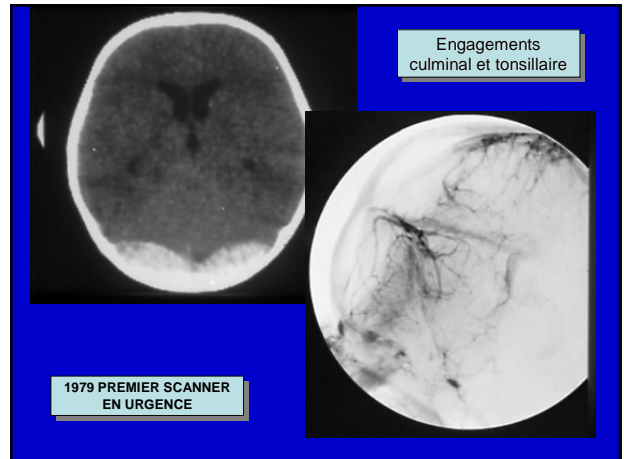
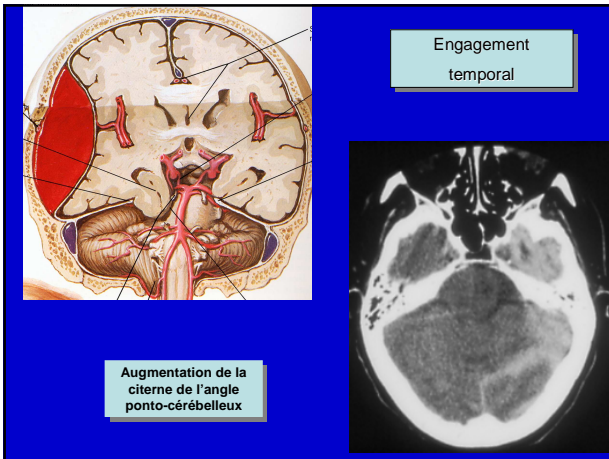
LE CONTENU CRÂNIEN

LES LÉSIONS INTRACRÂNIENNES

- Extra-cérébrales

EFFET DE MASSE LES ENGAGEMENTS

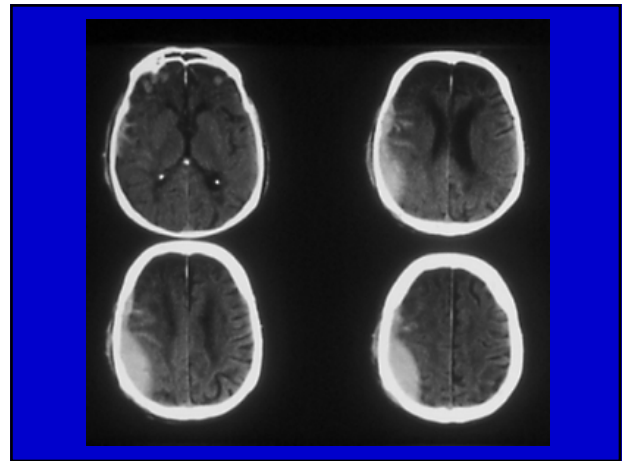
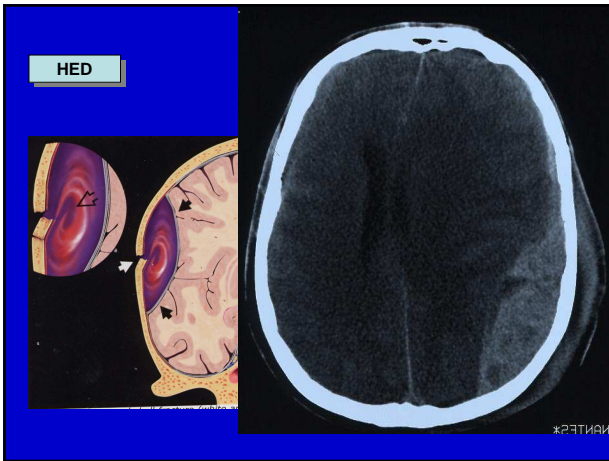
- Faux du cerveau
- Incisure tentorielle
- Tonsillaire
- Culminal



Chercher
 LE BLANC
 et LE NOIR

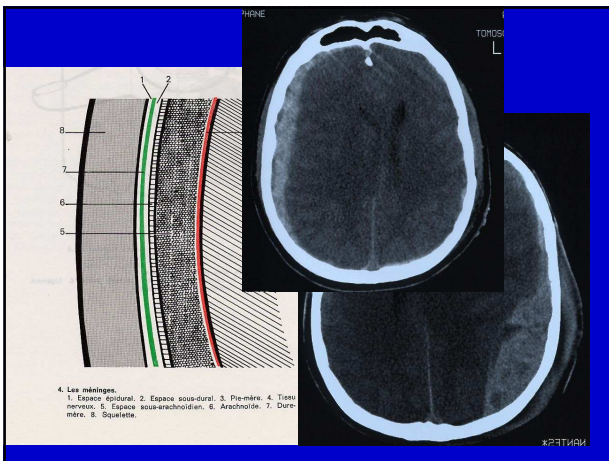
L'HÉMATOME
 EXTRA DURAL

LENTILLE BICONVEXE

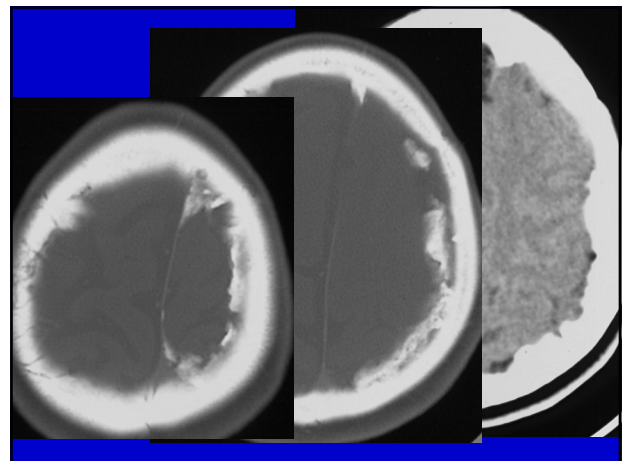
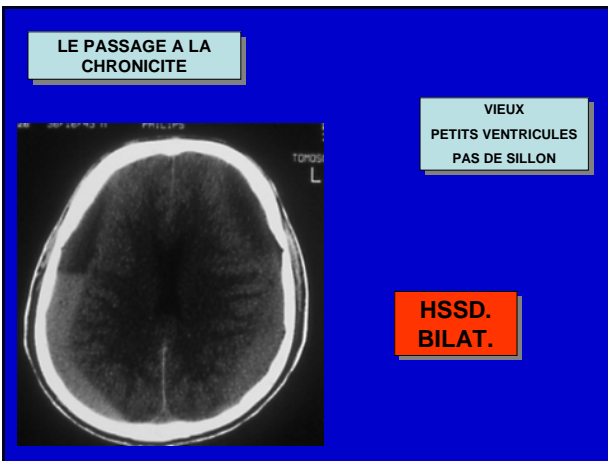
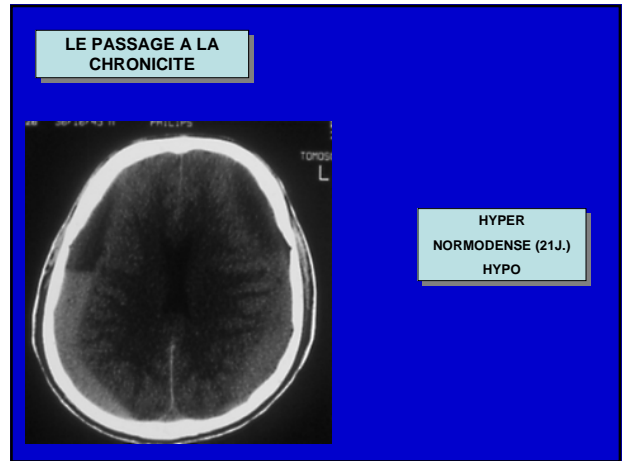
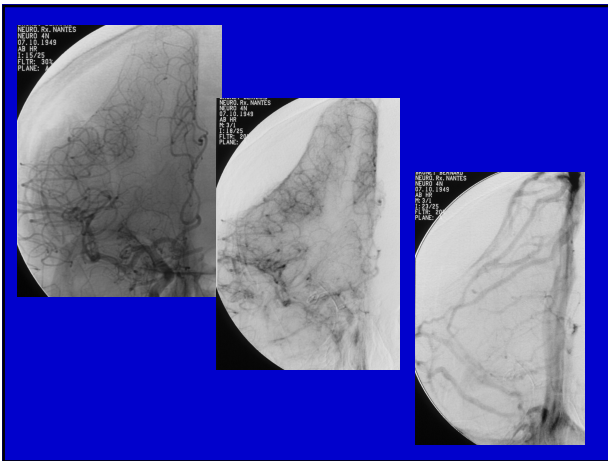
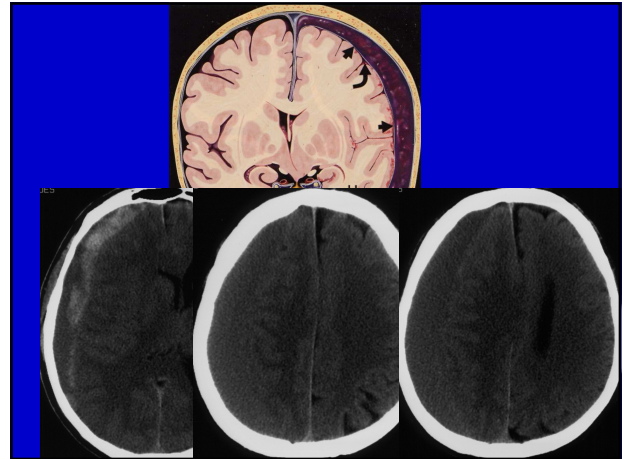
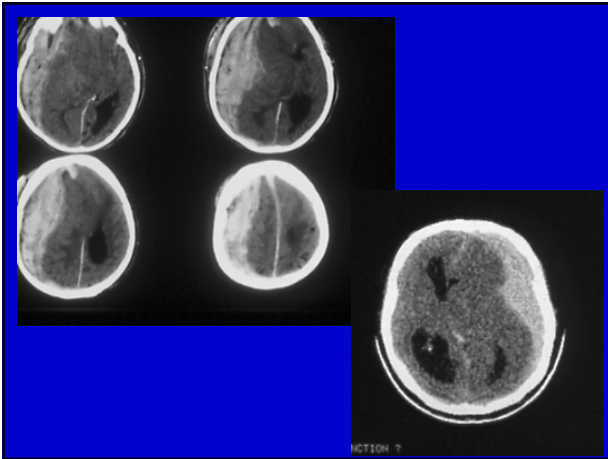


L'HÉMATOME
SOUS-DURAL AIGU

PLUS ÉTENDU
MOINS ÉPAIS

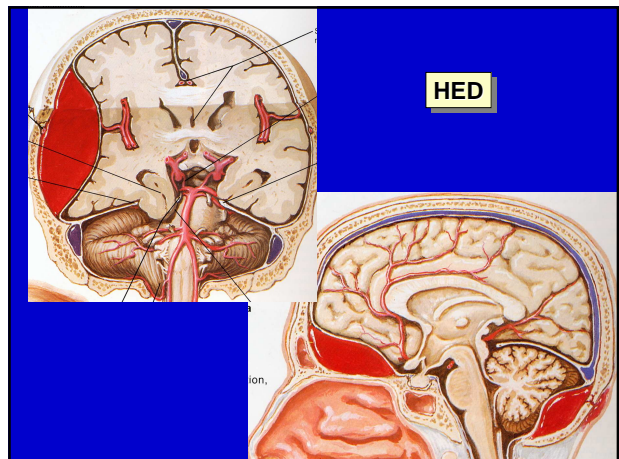


LE BLANC ■
devient
NOIR ■



EN CAS DE DOUTE

- Hématome extra dural
- Hématome sous dural



ET SI ON DOUTE ?

ON PERCE

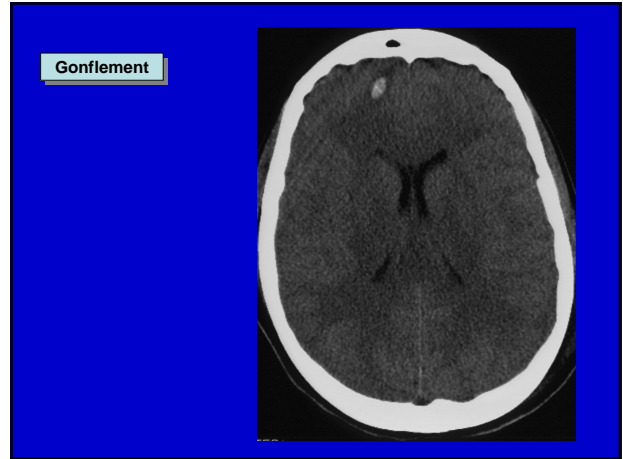
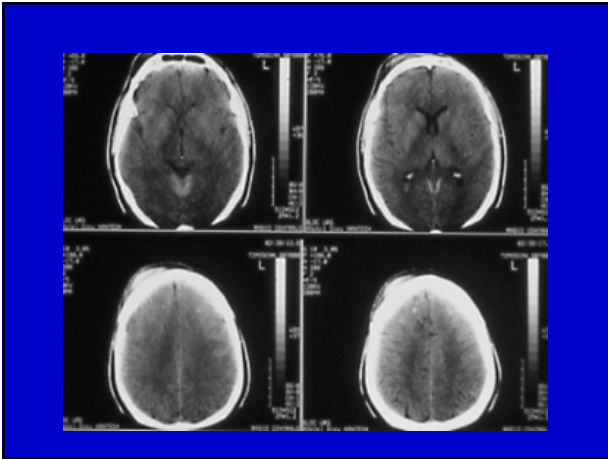
LES LÉSIONS CÉRÉBRALES TRAUMATIQUES

- Hémorragiques
- Non hémorragiques

BLANC
NOIR
Vaisseaux

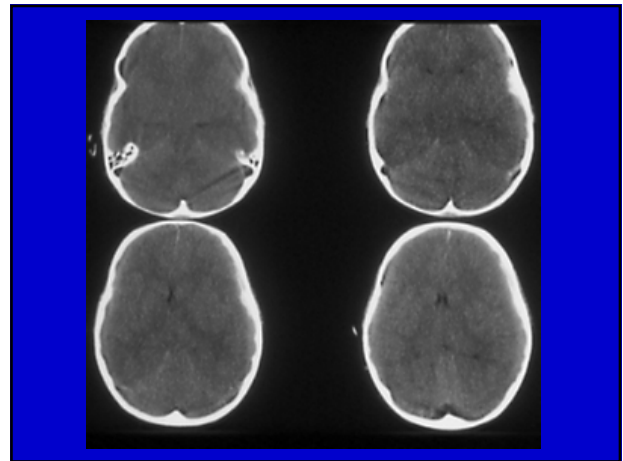
LES LÉSIONS CÉRÉBRALES NON HÉMORRAGIQUES

- Contusion oedémateuse
- Gonflement cérébral diffus
- Cisaillement axonal



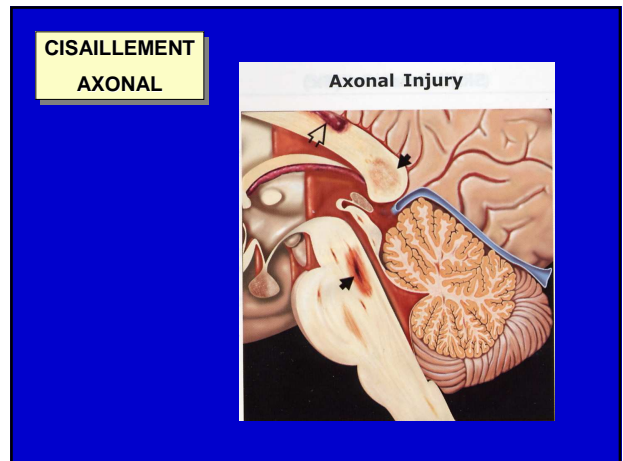
LES LÉSIONS CÉRÉBRALES NON HÉMORRAGIQUES

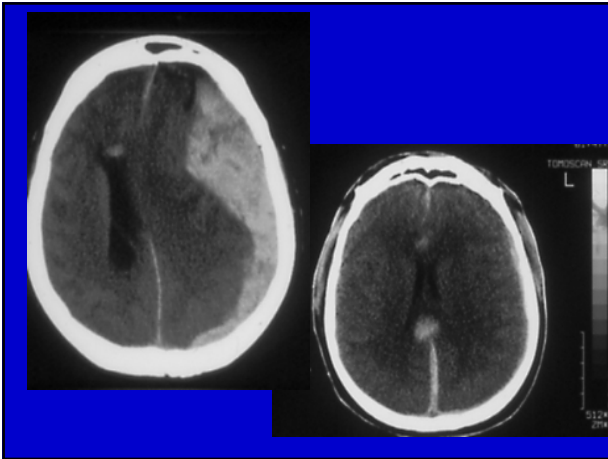
- Contusion oedémateuse
- Gonflement cérébral diffus
- Cisaillement axonal



LES LÉSIONS CÉRÉBRALES NON HÉMORRAGIQUES

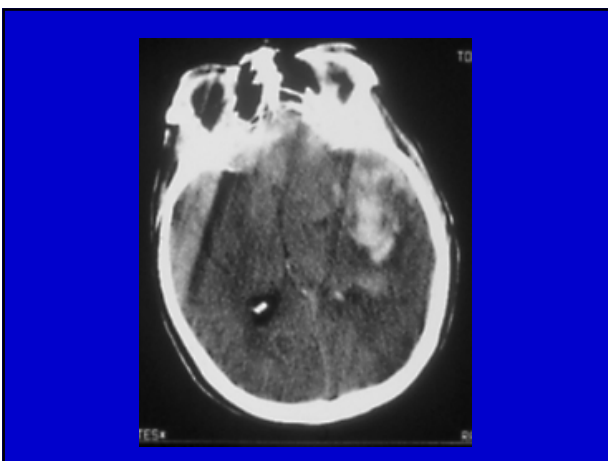
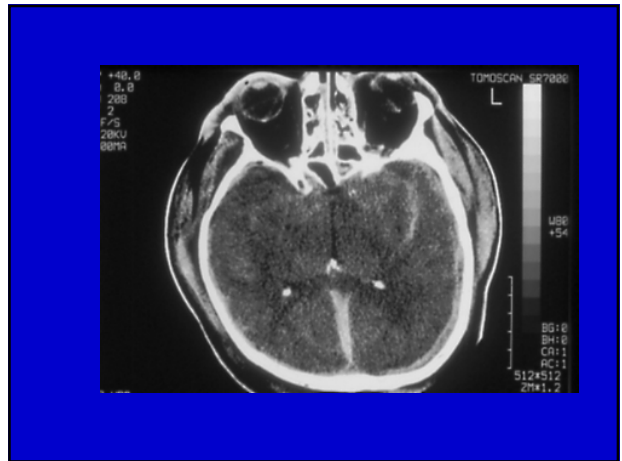
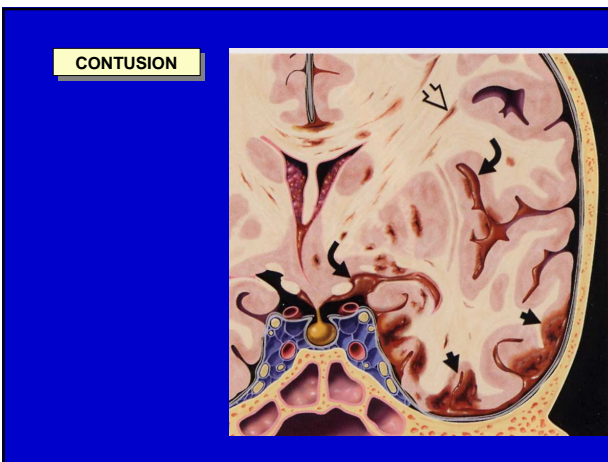
- Contusion oedémateuse
- Gonflement cérébral diffus
- Cisaillement axonal





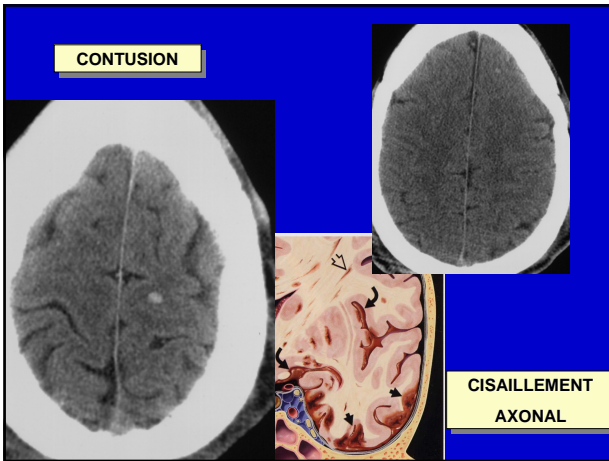
LES LÉSIONS CÉRÉBRALES HÉMORRAGIQUES

- Contrecoup sur les orbites
- Cortico sous corticales
- Hématome
- Attrition



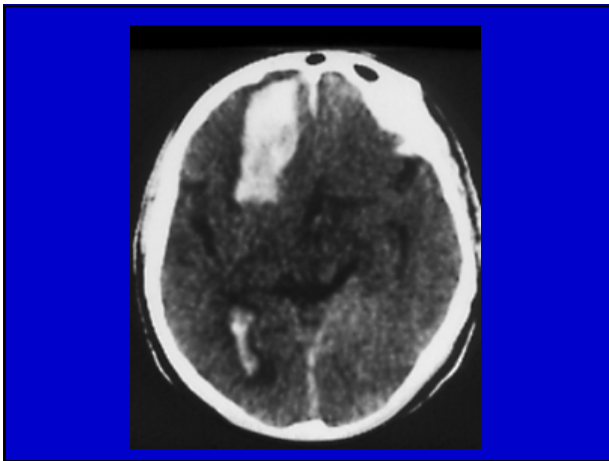
LES LÉSIONS CÉRÉBRALES HÉMORRAGIQUES

- Contre coup sur les orbites
- Cortico sous corticales
- Hématome
- Attrition



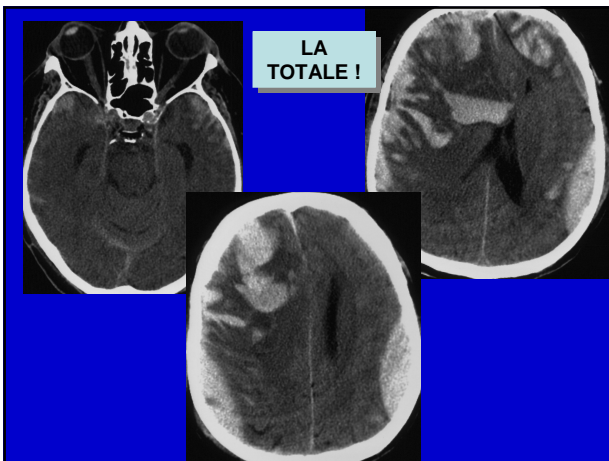
LES LÉSIONS CÉRÉBRALES HÉMORRAGIQUES

- Contrecoup sur les orbites
- Cortico sous corticales
- Hématome
- Attrition



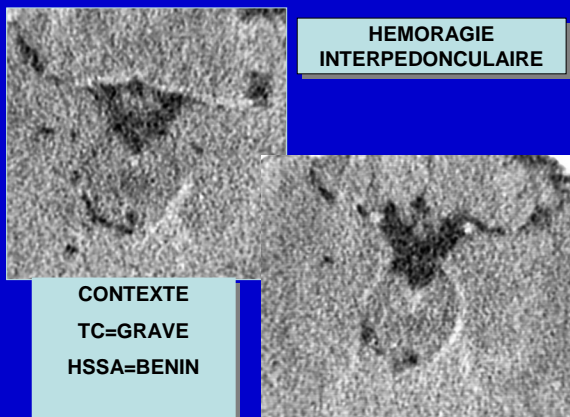
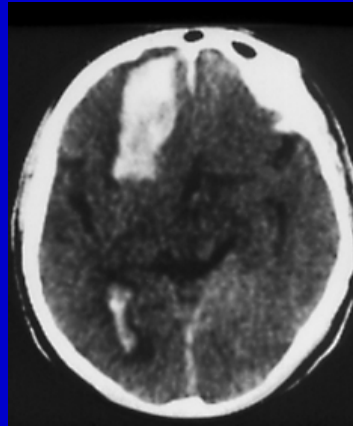
LES LÉSIONS CÉRÉBRALES HÉMORRAGIQUES

- Contrecoup sur les orbites
- Cortico sous corticales
- Hématome
- Attrition

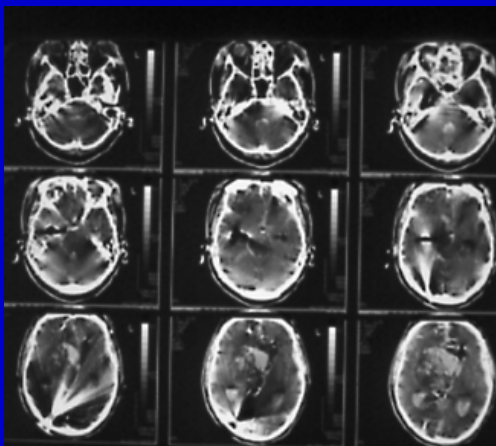
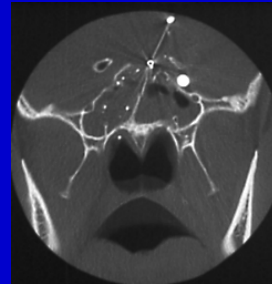


LA CONTAMINATION DU LIQUIDE CÉRÉBRO-SPINAL par le sang

HÉMORRAGIE MÉNINGÉE
HÉMORRAGIE VENTRICULAIRE



PLAIE PAR PROJECTILE



LES LÉSIONS VASCULAIRES

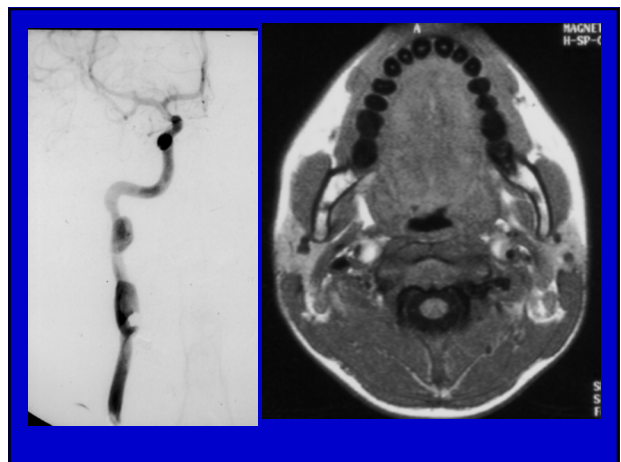
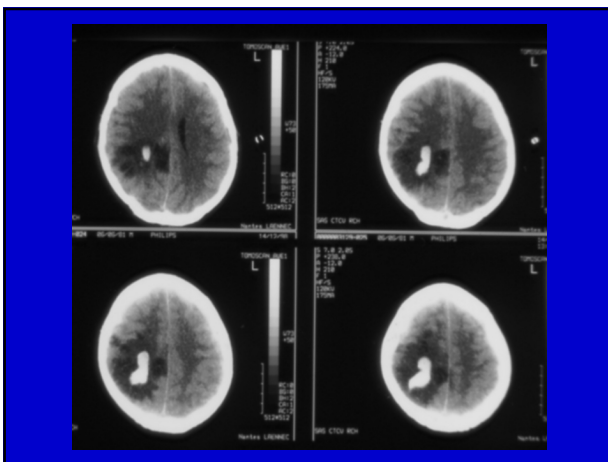
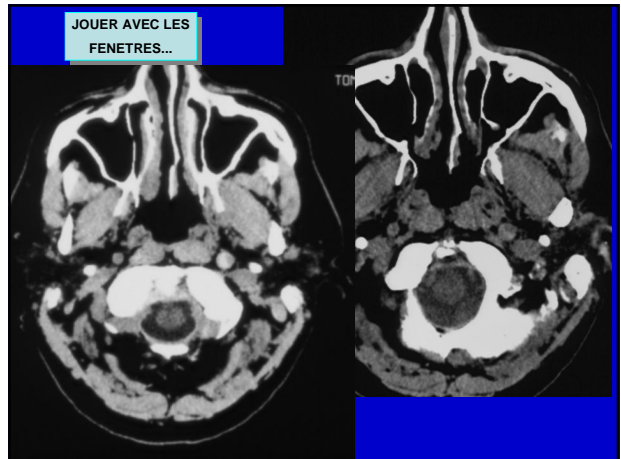
- Dissection
- Fistules
- Ruptures

LES LÉSIONS VASCULAIRES

Dissections

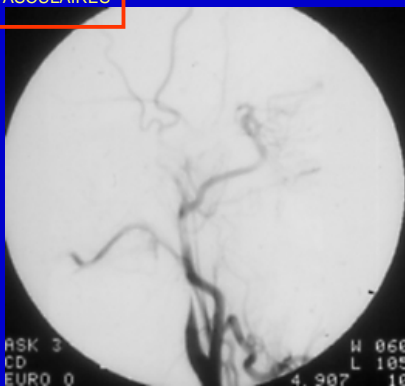- Carotidienne
- Vertébrale
- Anévrisme post-traumatique

JOUER AVEC LES FENETRES...



LES LÉSIONS VASCULAIRES

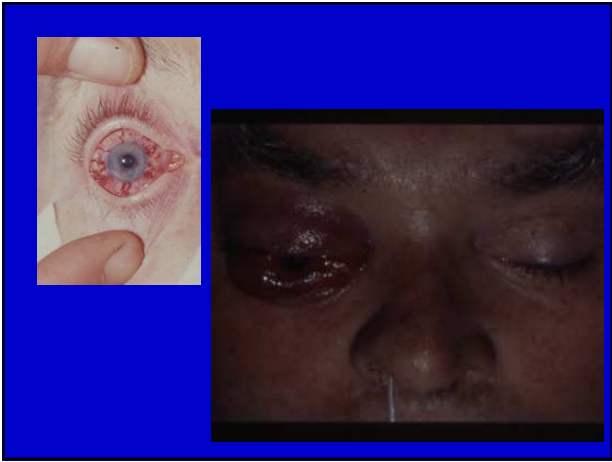- Dissection



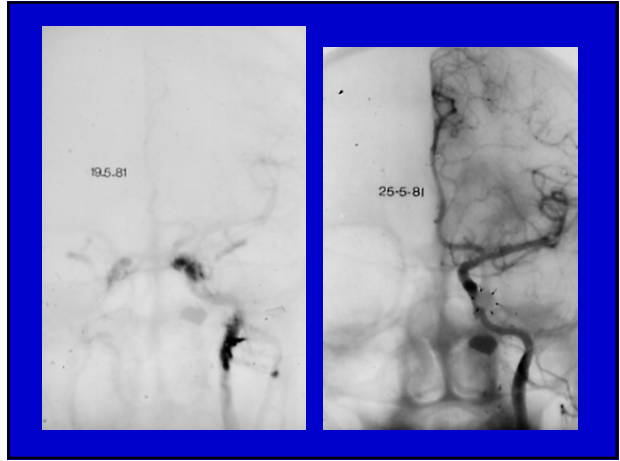
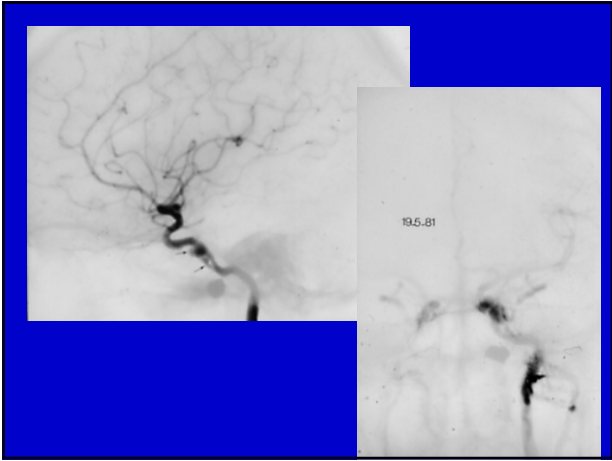
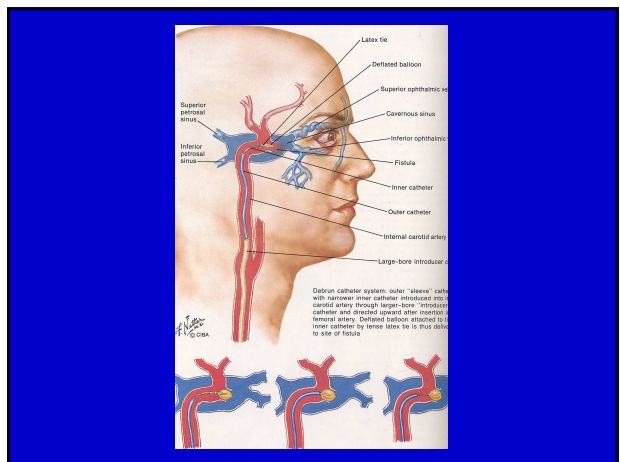
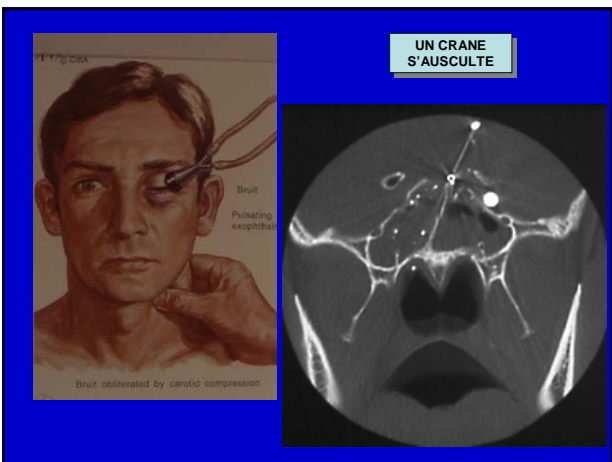
LES LÉSIONS VASCULAIRES

Fistules

- Carotido-caverneuse
- Vertébro-vertébrale



UN CRÂNE S'AUSCULTE



LES LÉSIONS VASCULAIRES

Fistules

- Carotido-caverneuse
- Vertébro-vertébrale

📁 Observation n°3

Mme P...H..., 32 ans

➤ Antécédents:

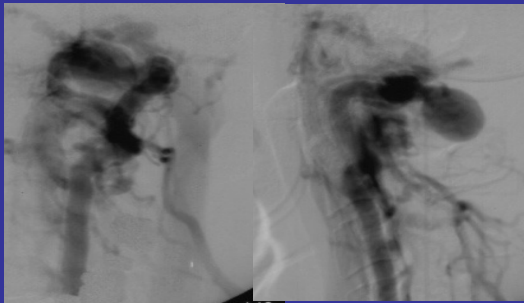
localisation secondaire d'un hémangio-péricytome récidivant à l'arc postérieur de la C1: chirurgie

➤ Signes cliniques:

acouphènes pulsatiles

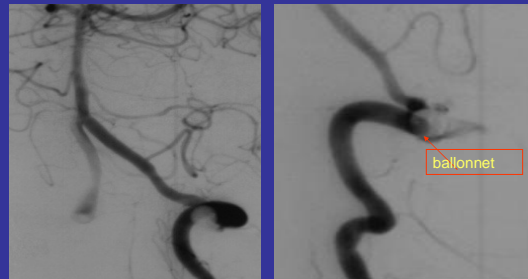
L'artériographie

- FAVV directe de V3 gauche



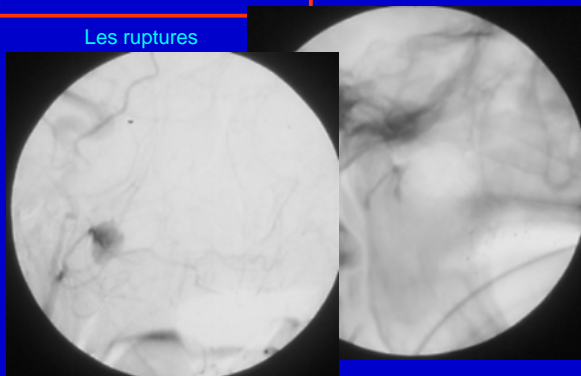
Traitement

Exclusion de la FAVV avec préservation de la vascularisation vertébro-basilaire



LES LÉSIONS VASCULAIRES

Les ruptures



CONCLUSION

et le rachis cervical ?