

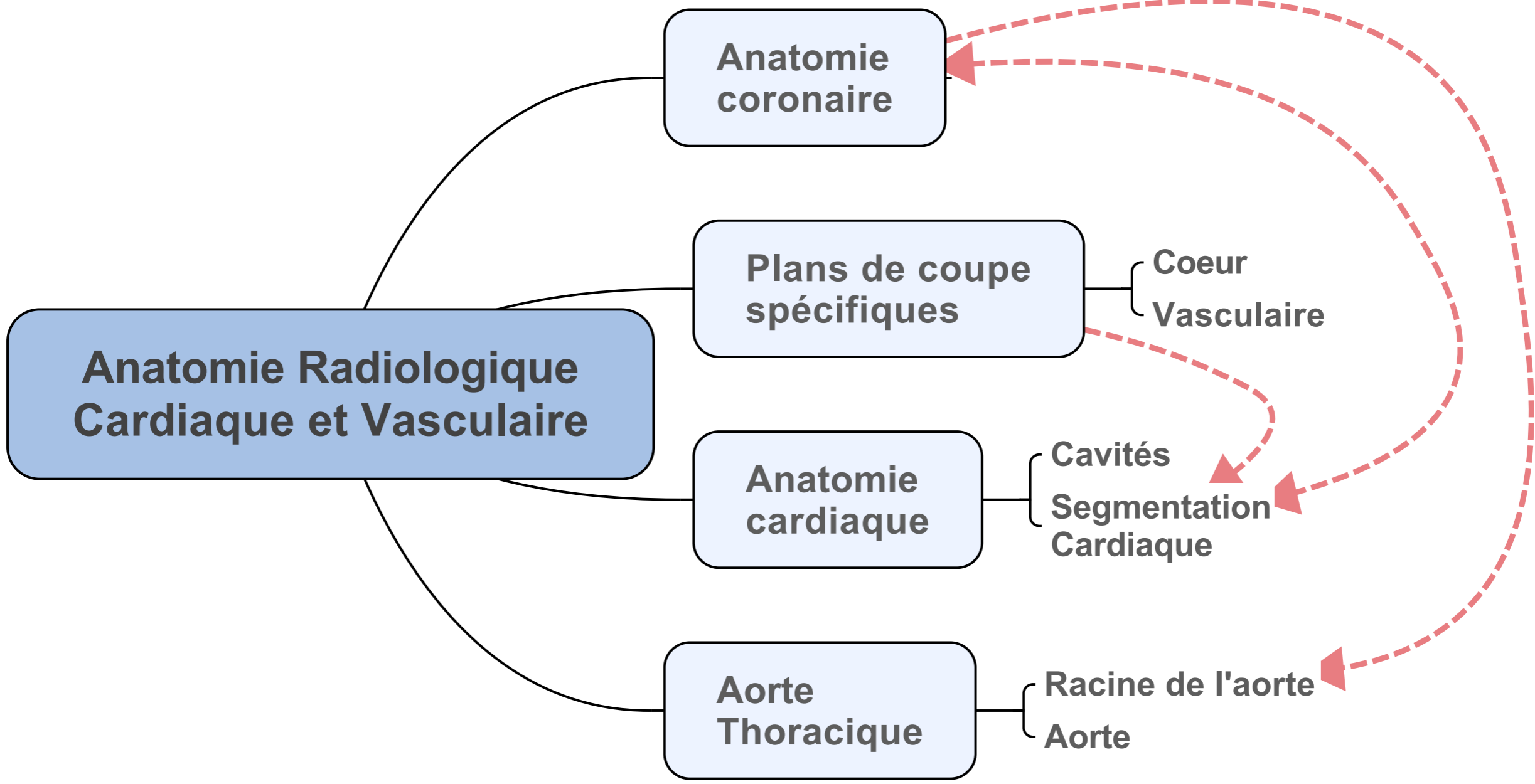
Anatomie Radiologique Cardiaque

S Willoteaux



Service de Radiologie
CHU d'Angers

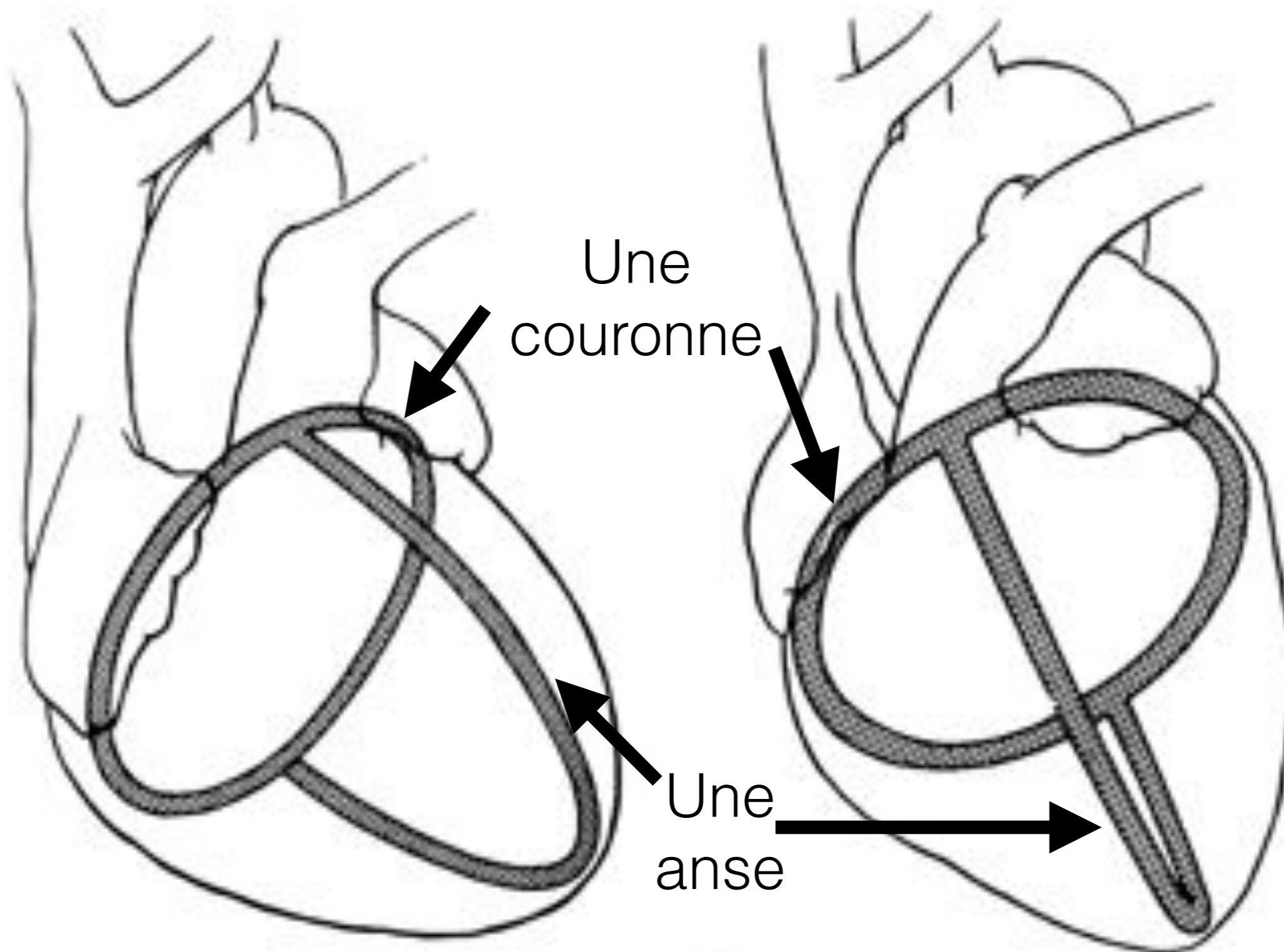




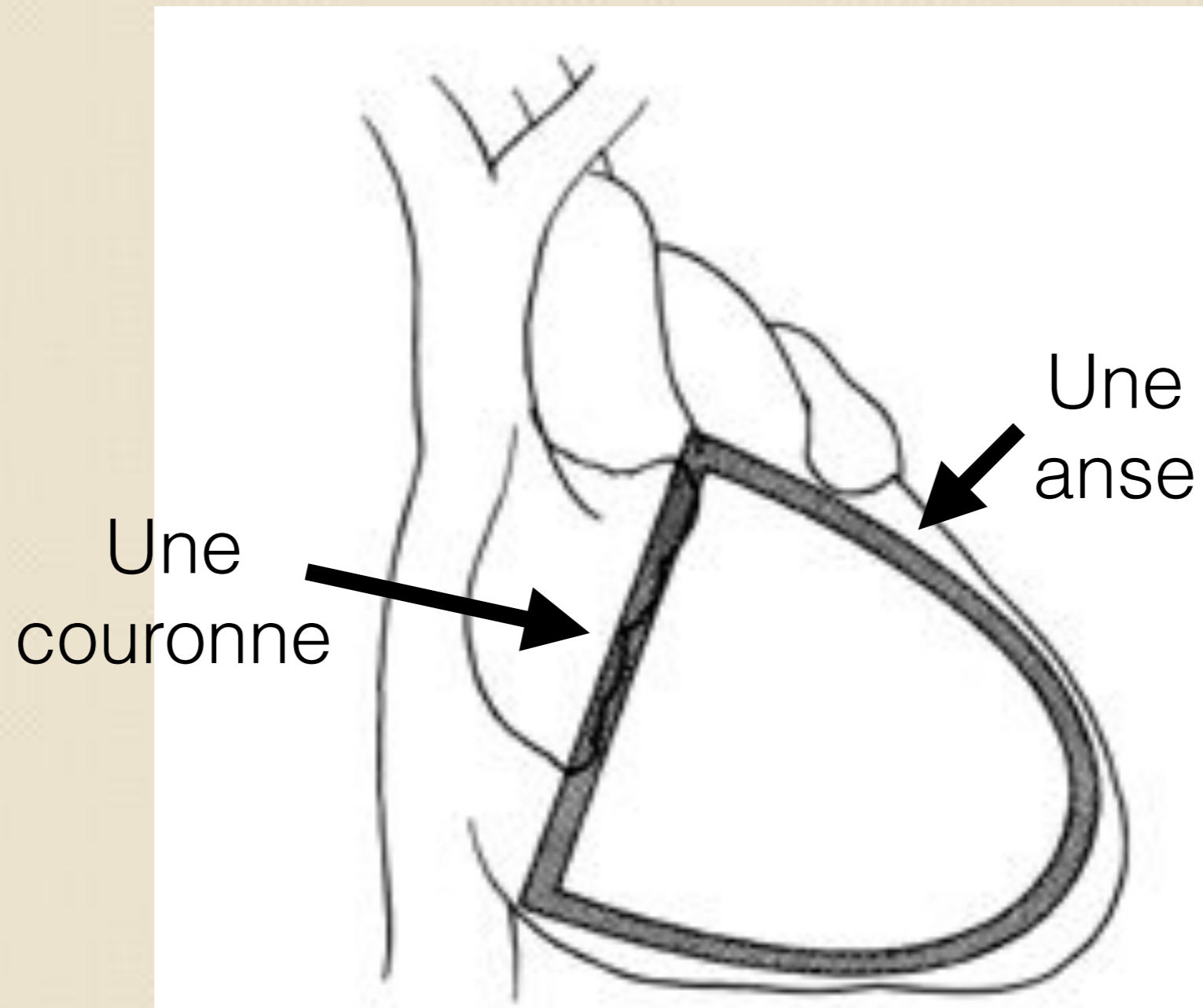


Anatomie des artères coronaires

Anatomie coronaire

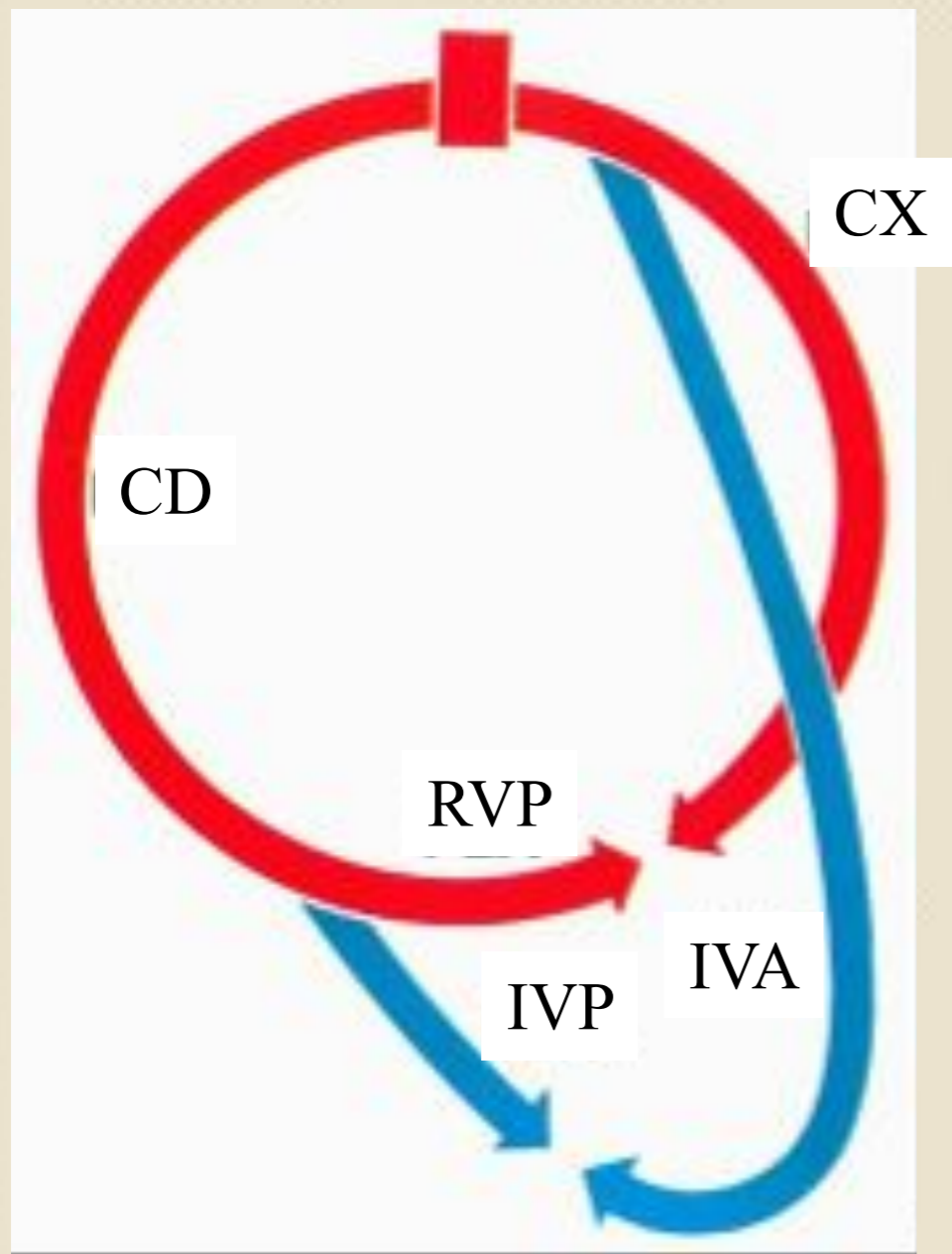


ANATOMIE CORONAIRE



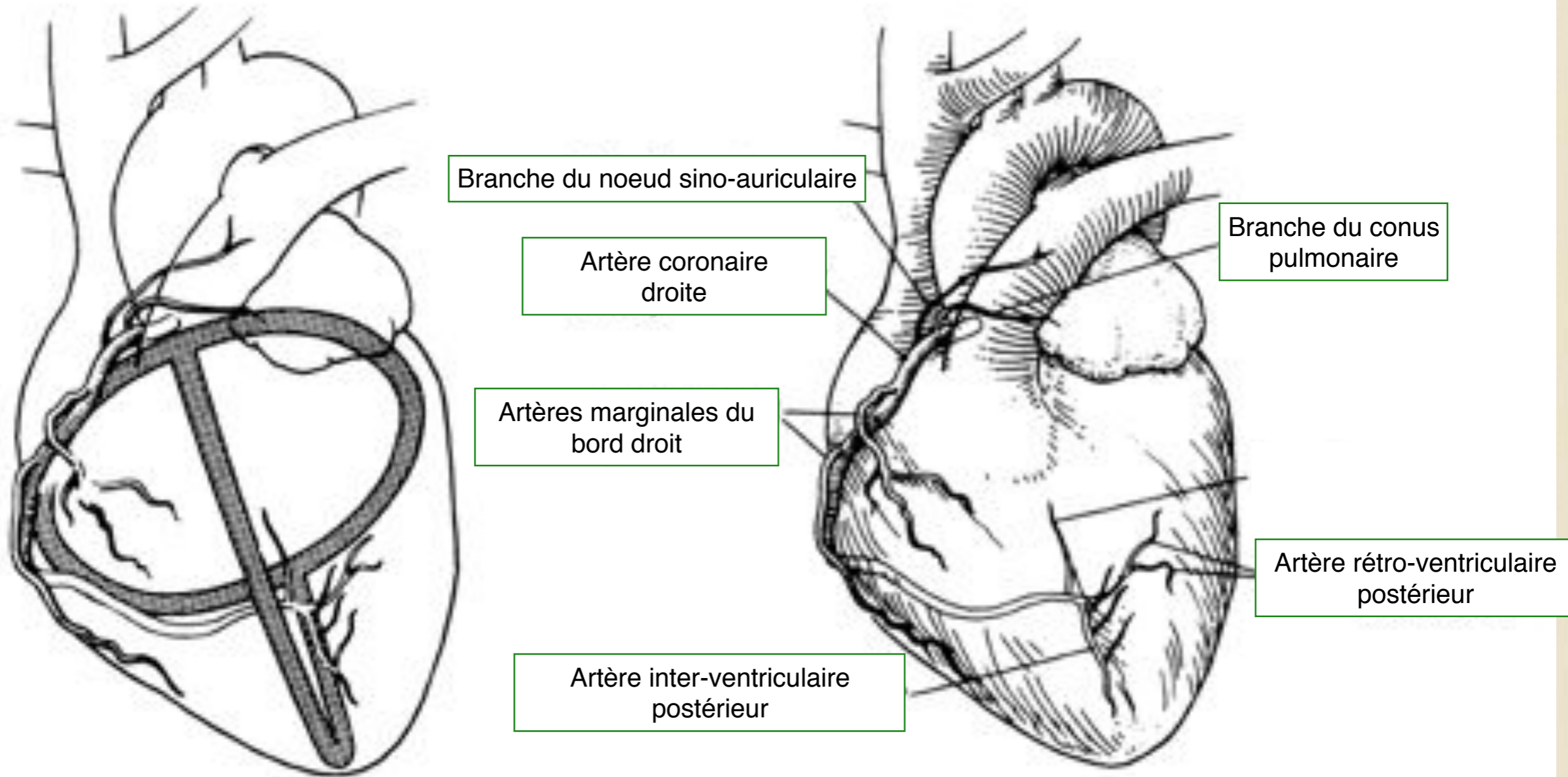
Kubicka Radiographics 1986;6:661-701

ANATOMIE CORONAIRE



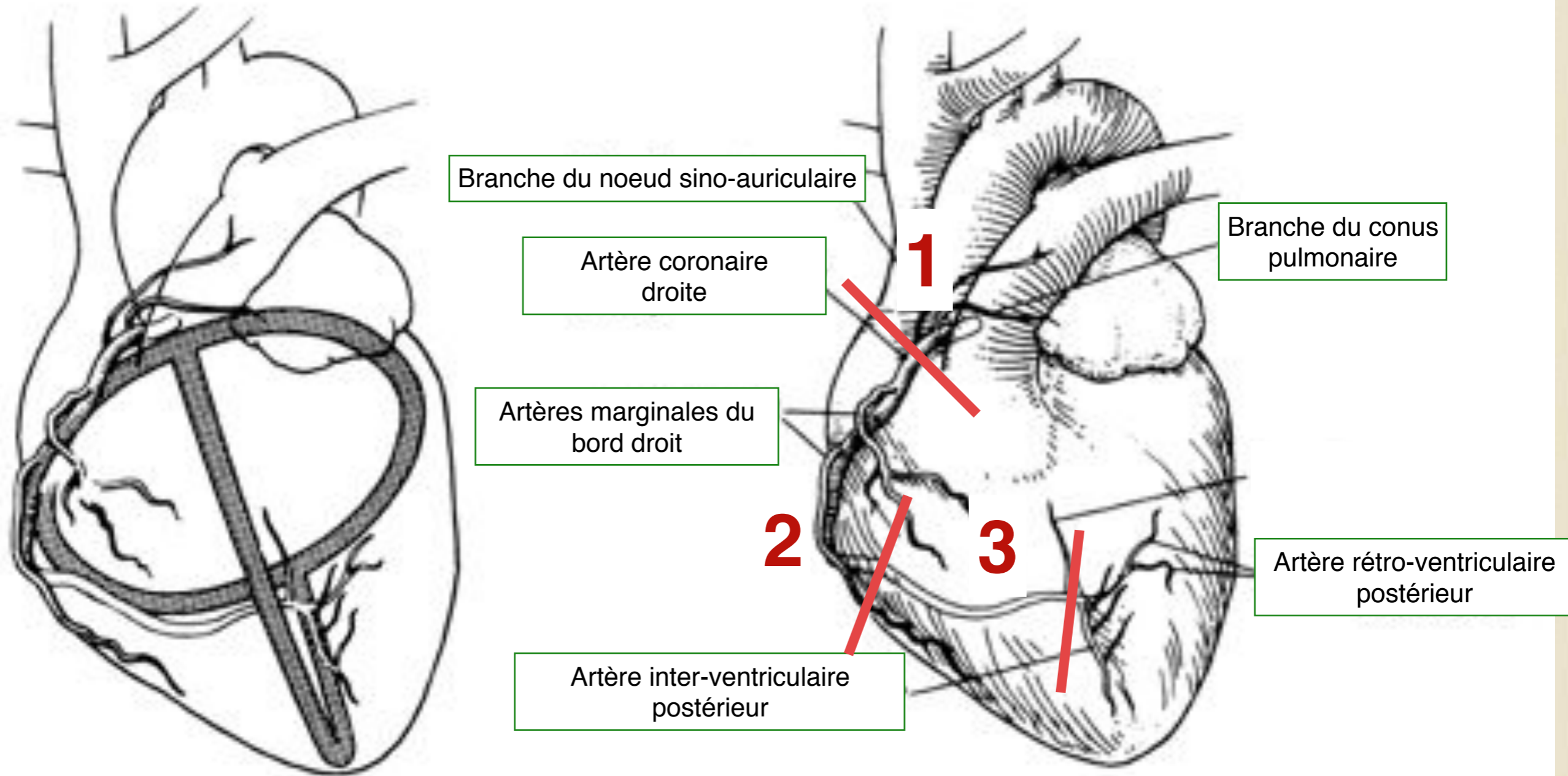
- CD: artère coronaire droite
- RVP: Artère Rétro Ventriculaire Postérieure
- IVP: Artère Inter Ventriculaire Postérieure
- IVA: Artère Inter Ventriculaire antérieure
- CX: Artère circonflexe

RESEAU CORONAIRE DROIT

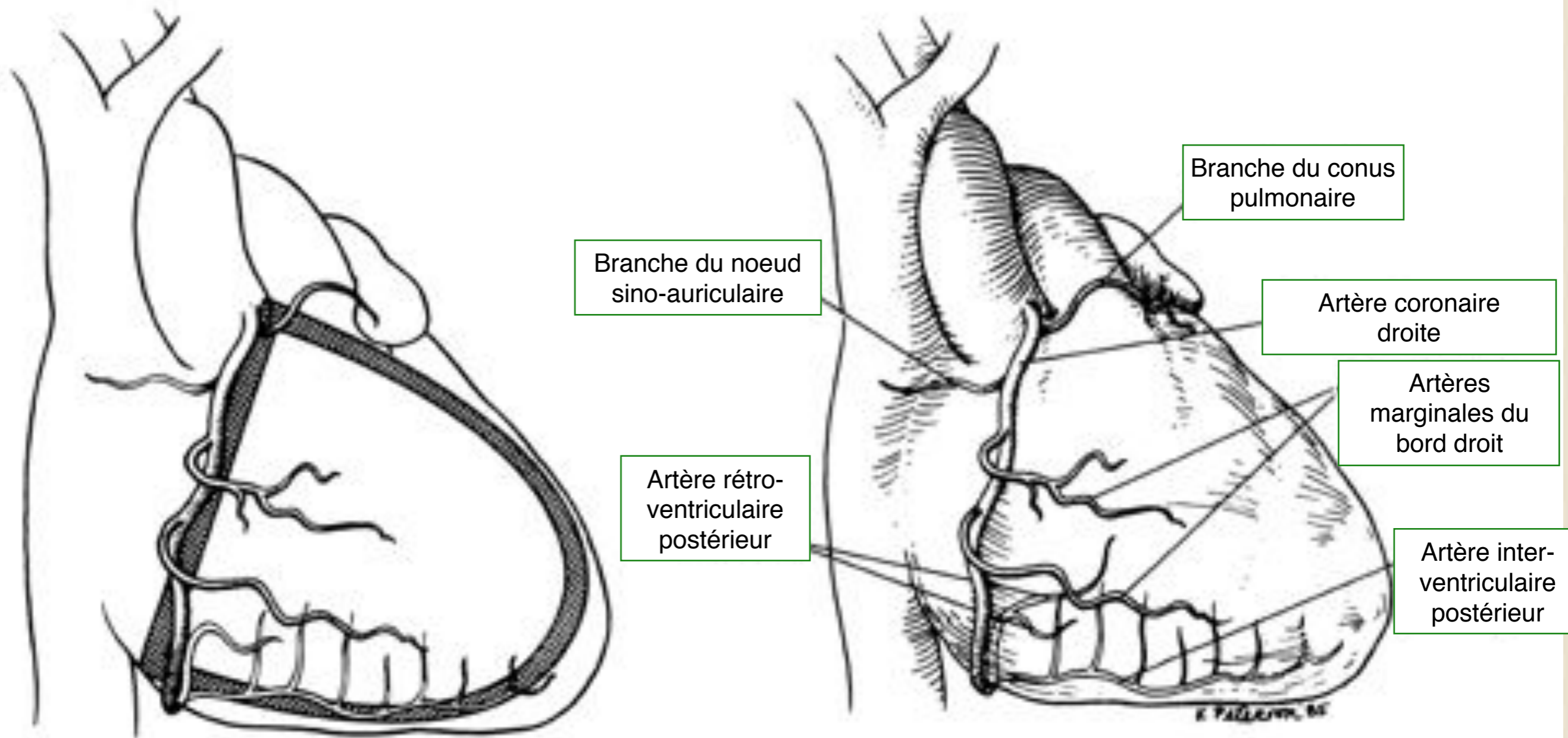


RESEAU CORONAIRE DROIT

Segment 1
Segment 2
Segment 3



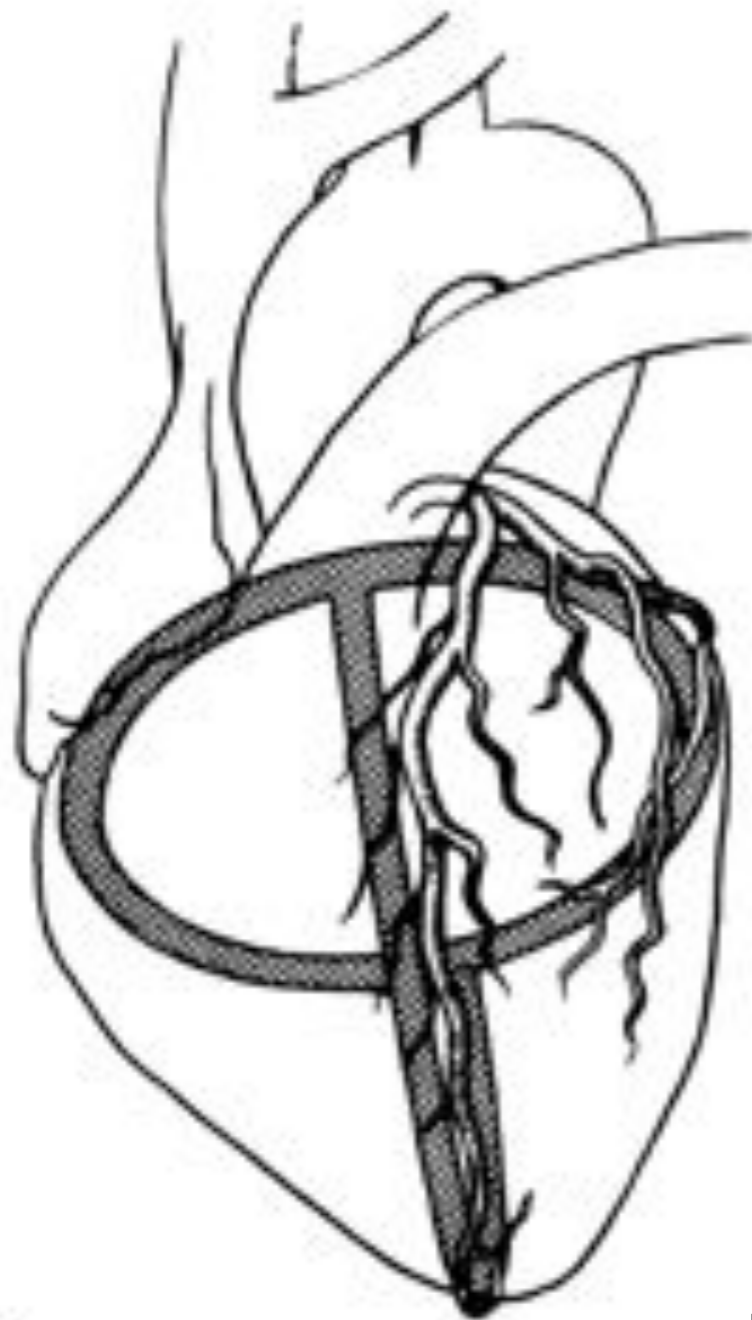
RESEAU CORONAIRE DROIT



3A

Kubicka Radiographics 1986;6:661-701

RESEAU CORONAIRE GAUCHE



Artère inter ventriculaire antérieure (IVA)

Branches septales

Tronc commun (Tc)

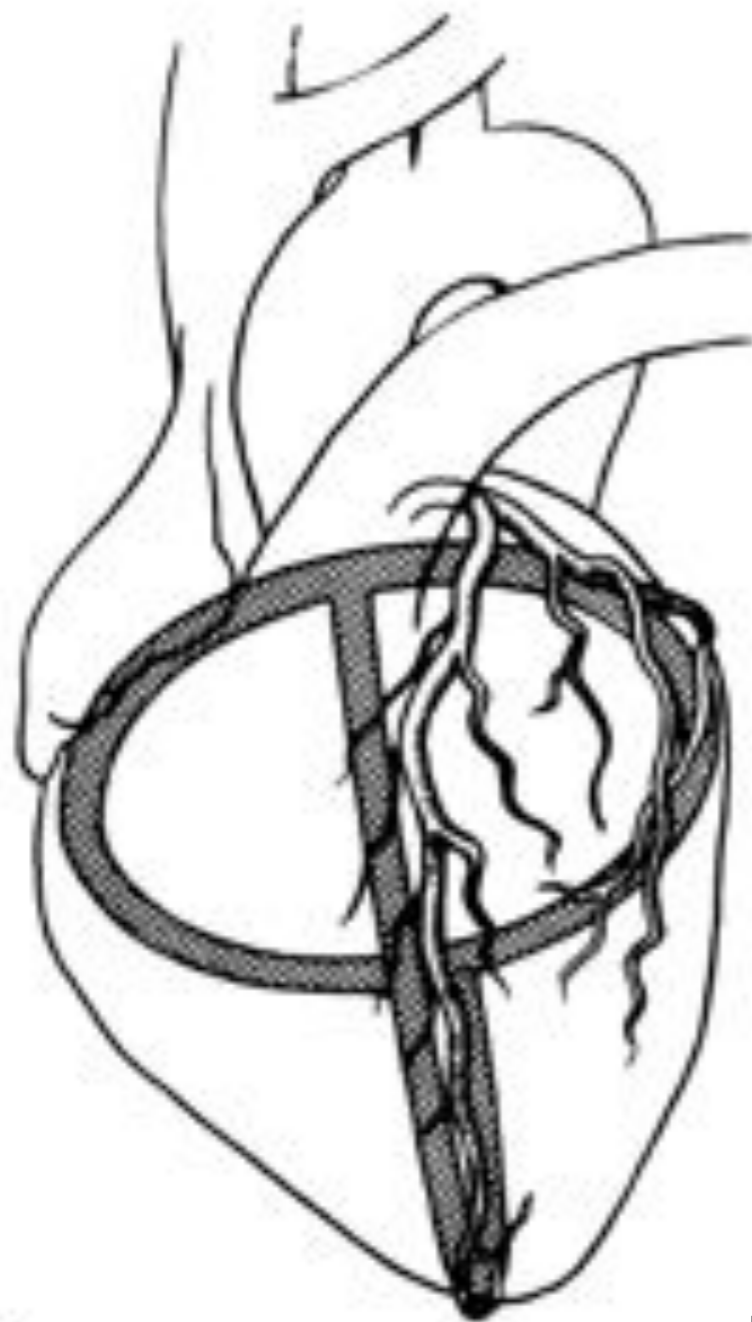
Artère circonflexe (Cx)

Branches diagonales

Branches marginales (M)

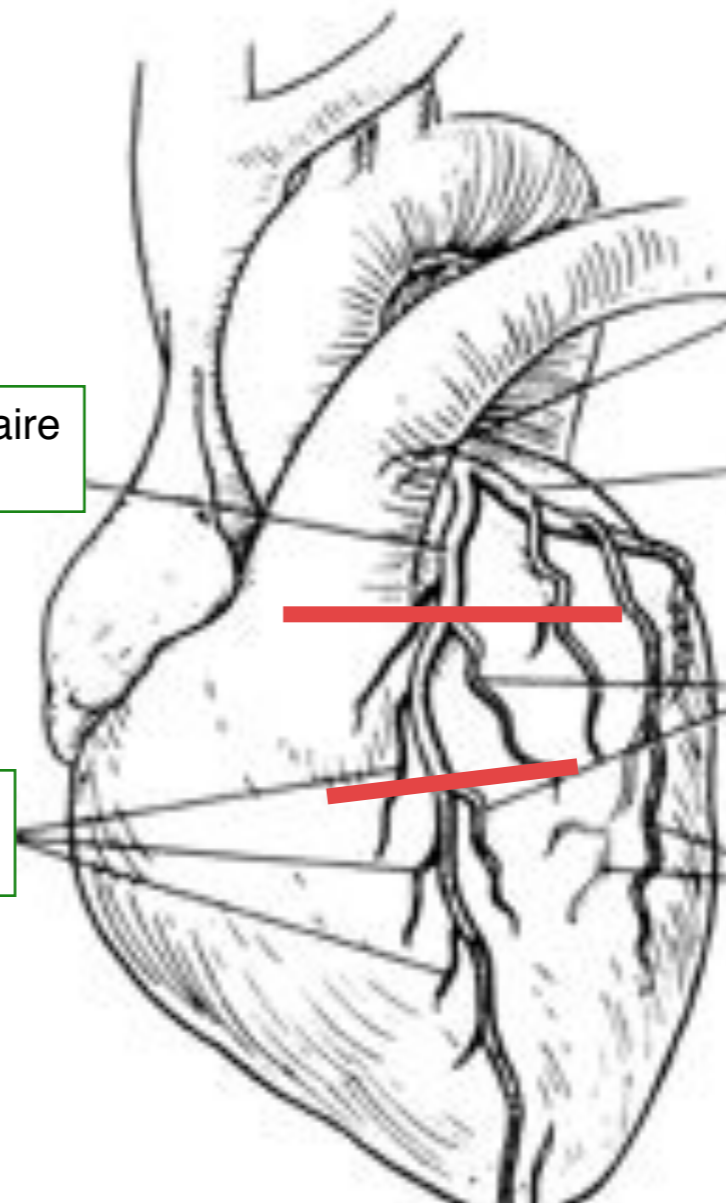
RESEAU CORONAIRE GAUCHE

- IVA Proximale
- IVA Moyenne
- IVA Distale



Artère inter ventriculaire antérieure (IVA)

Branches septales



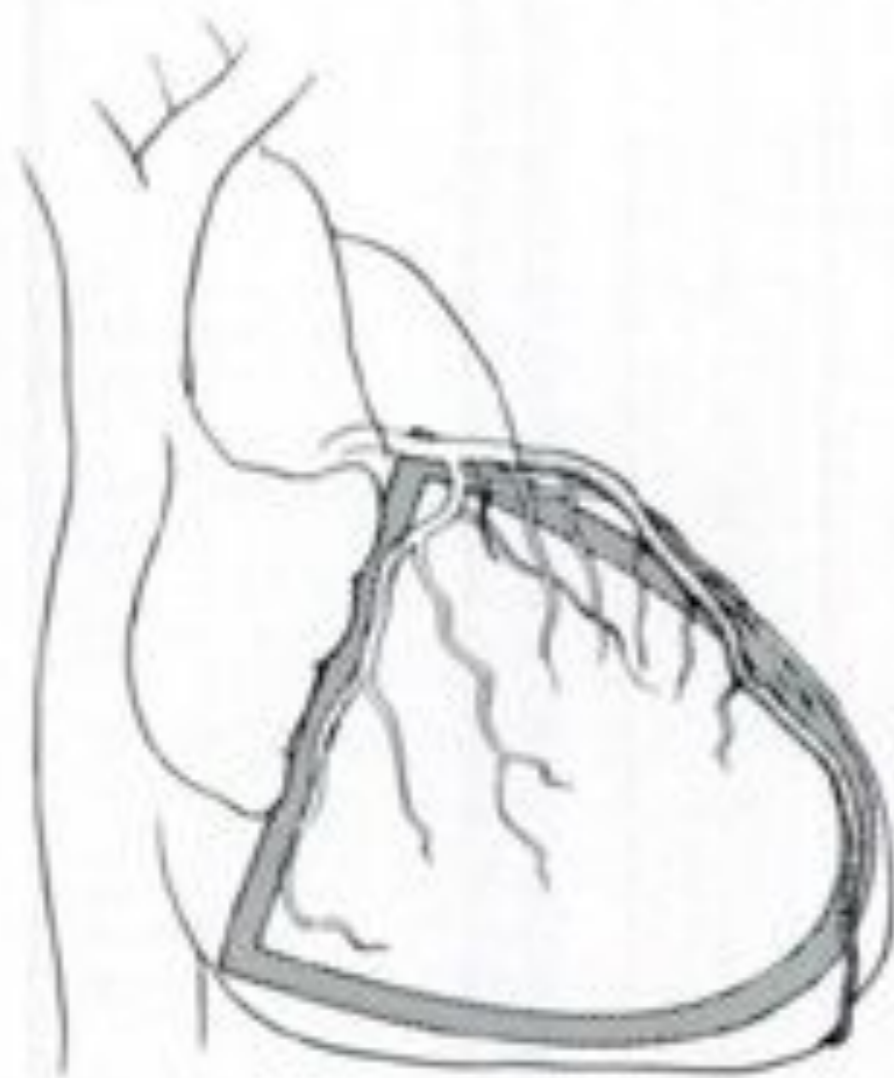Tronc commun (Tc)

Artère circonflexe (Cx)

Branches diagonales

Branches marginales (M)

RESEAU CORONAIRE GAUCHE



Artère
circonflexe
(Cx)

Branches
marginales

Tronc commun
(Tc)

Branche diagonale

Branches septales

Artère inter
ventriculaire
antérieure (IVA)

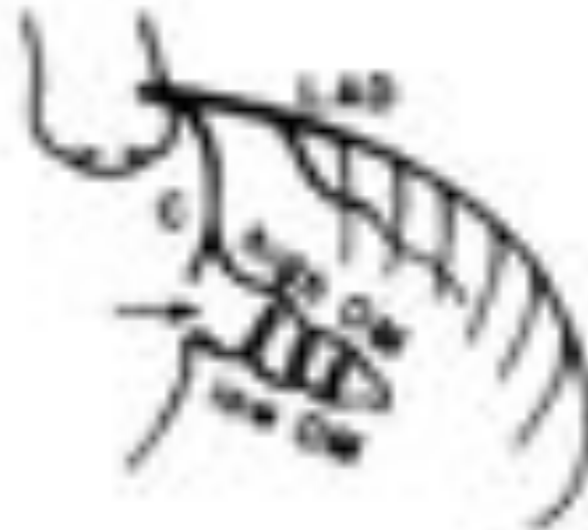Dominance Coronaire

- Définition:
 - Détermination de l'artère vascularisant la paroi diaphragmatique et le septum inférieur
- Types:
 - Dominance droite: 85% des cas
 - Dominance gauche (Circonflexe): 10% des cas
 - Distribution équilibrée: 5% des cas

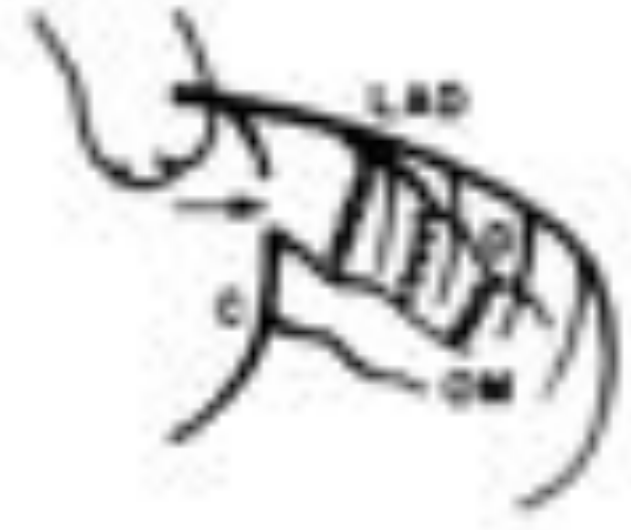OCCLUSION DE CX / COLLATERALES



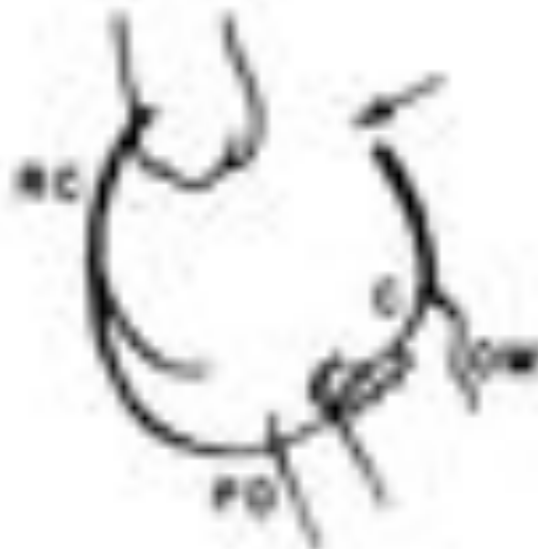A. RAO-LC injection (7)



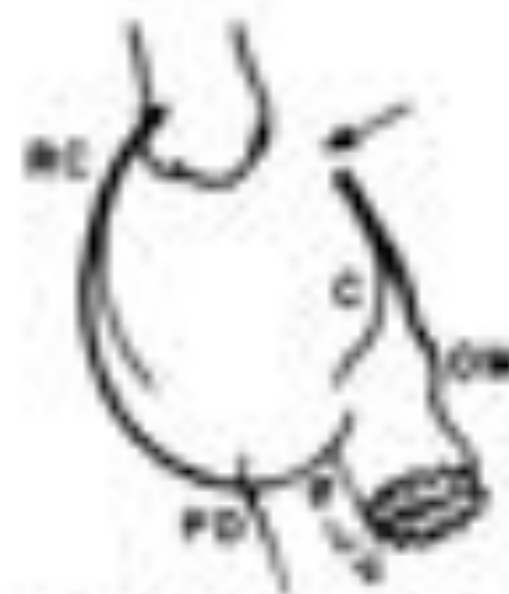B. RAO-LC injection (6)



C. RAO-LC injection (5)

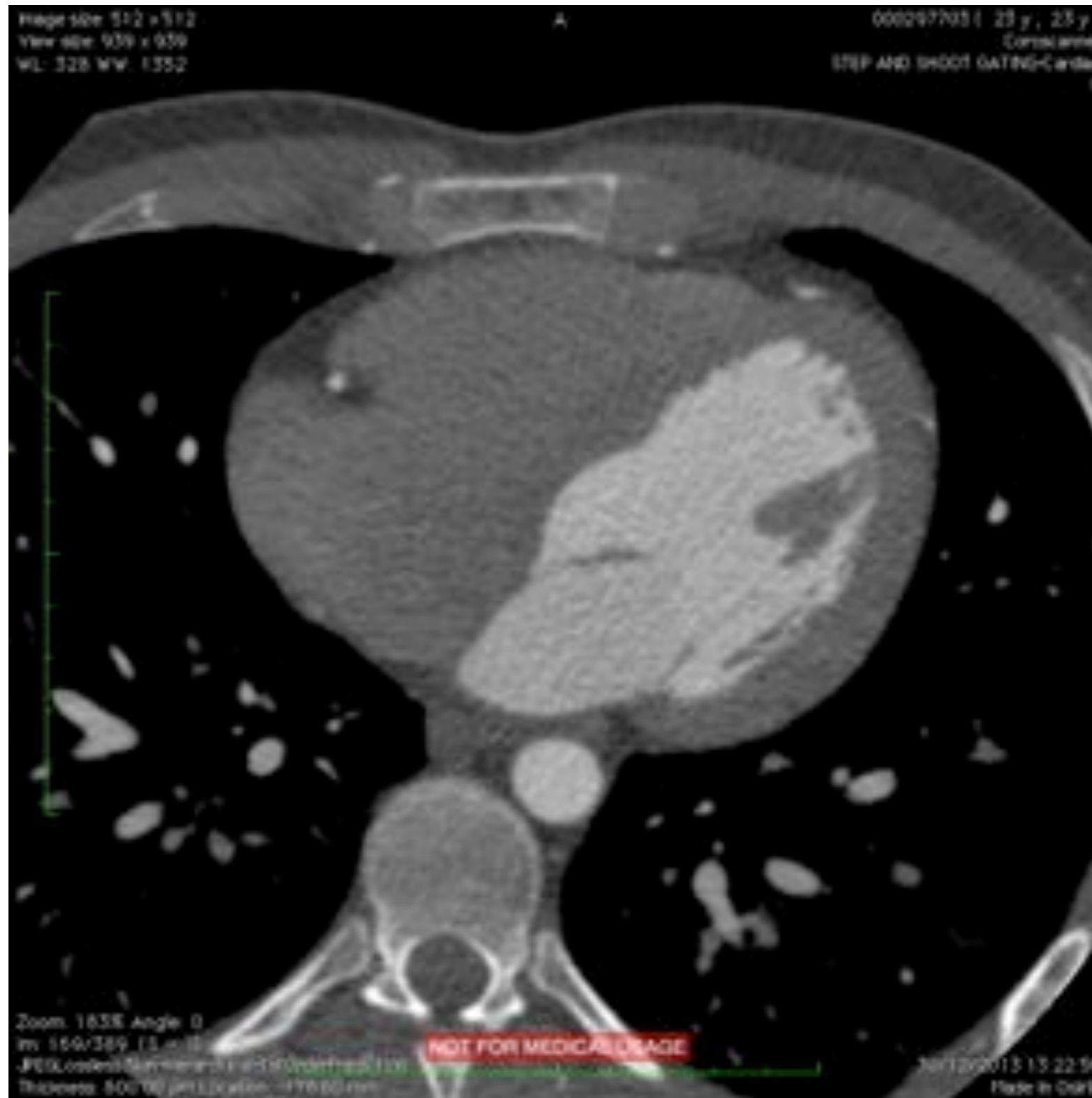


D. LAO-RC injection (2)

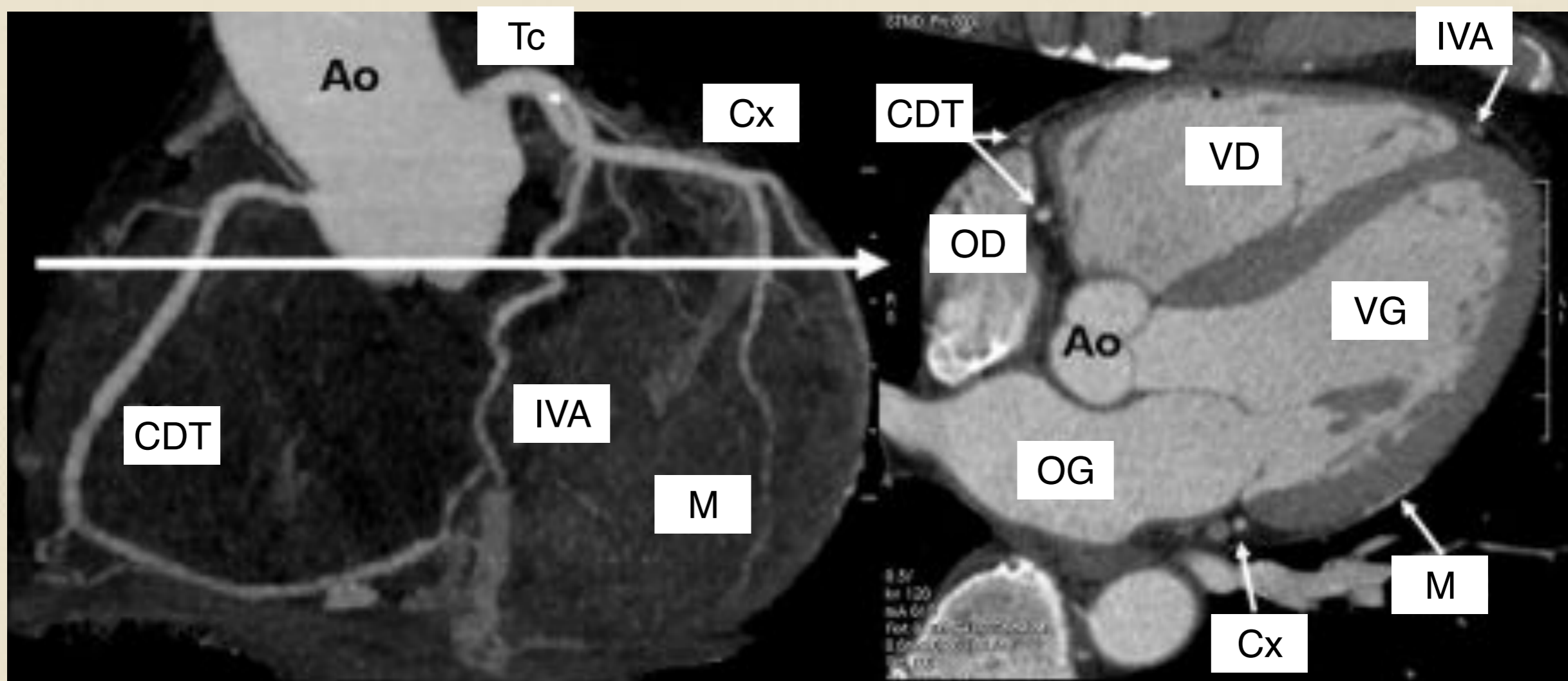


E. LAO-RC injection (2)

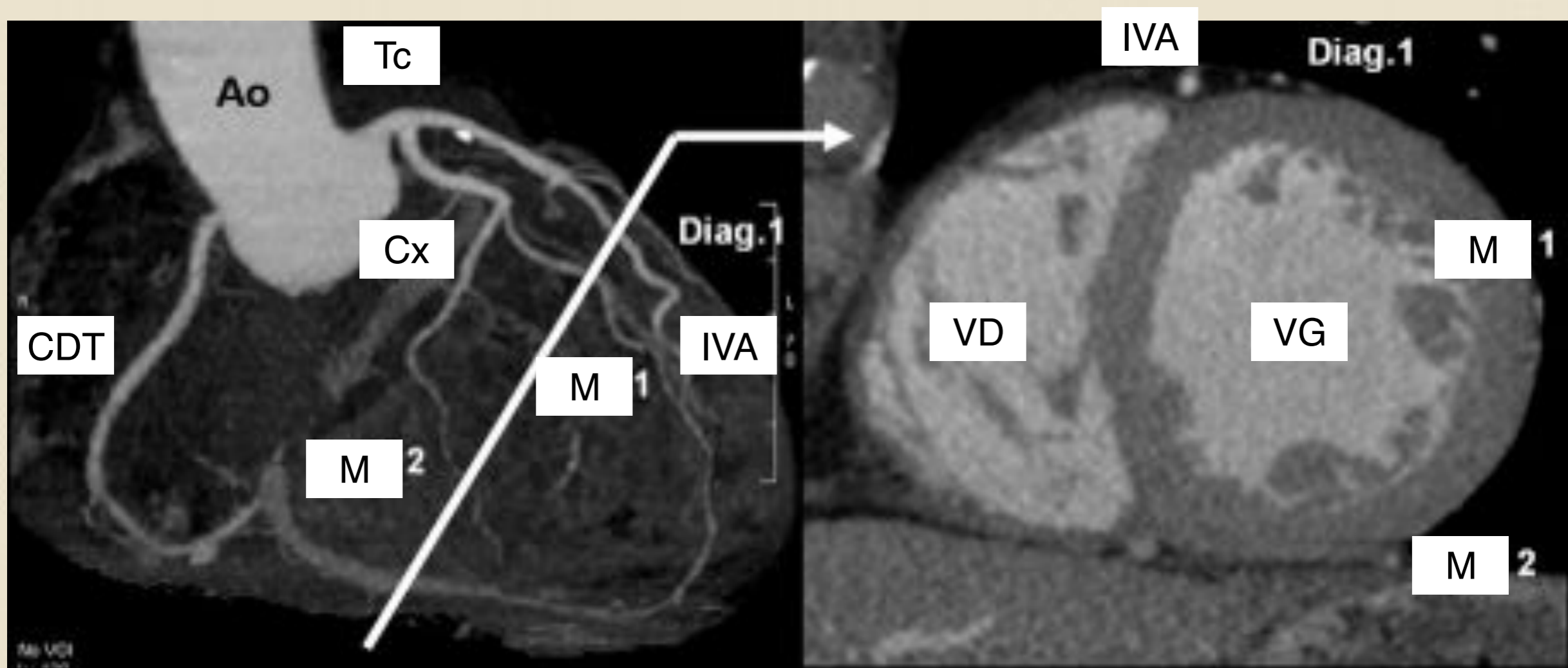Anatomie coronaire / Plan Axial transverse



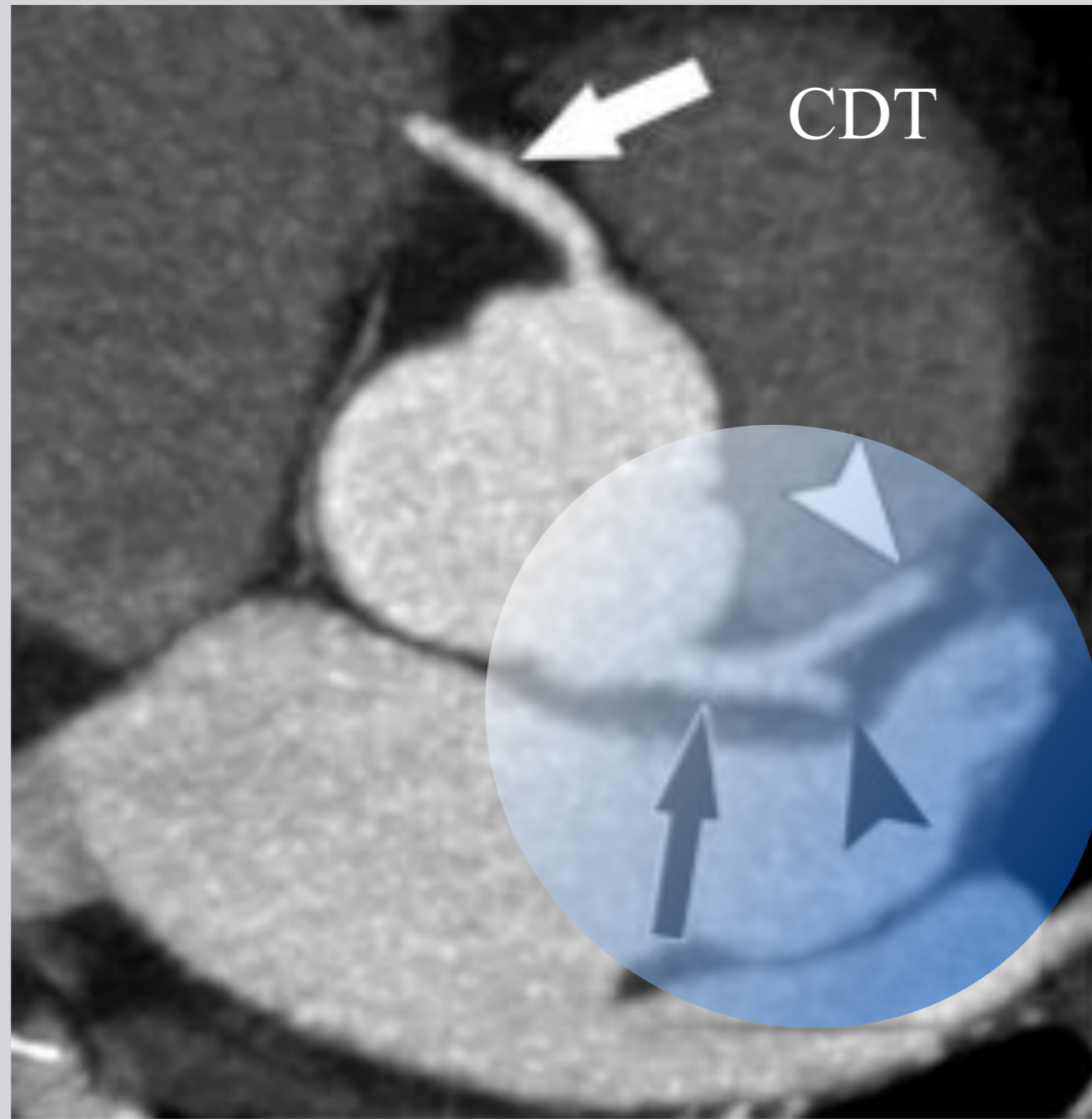
ANATOMIE CORONAIRE



ANATOMIE CORONAIRE



Réseau coronaire droit

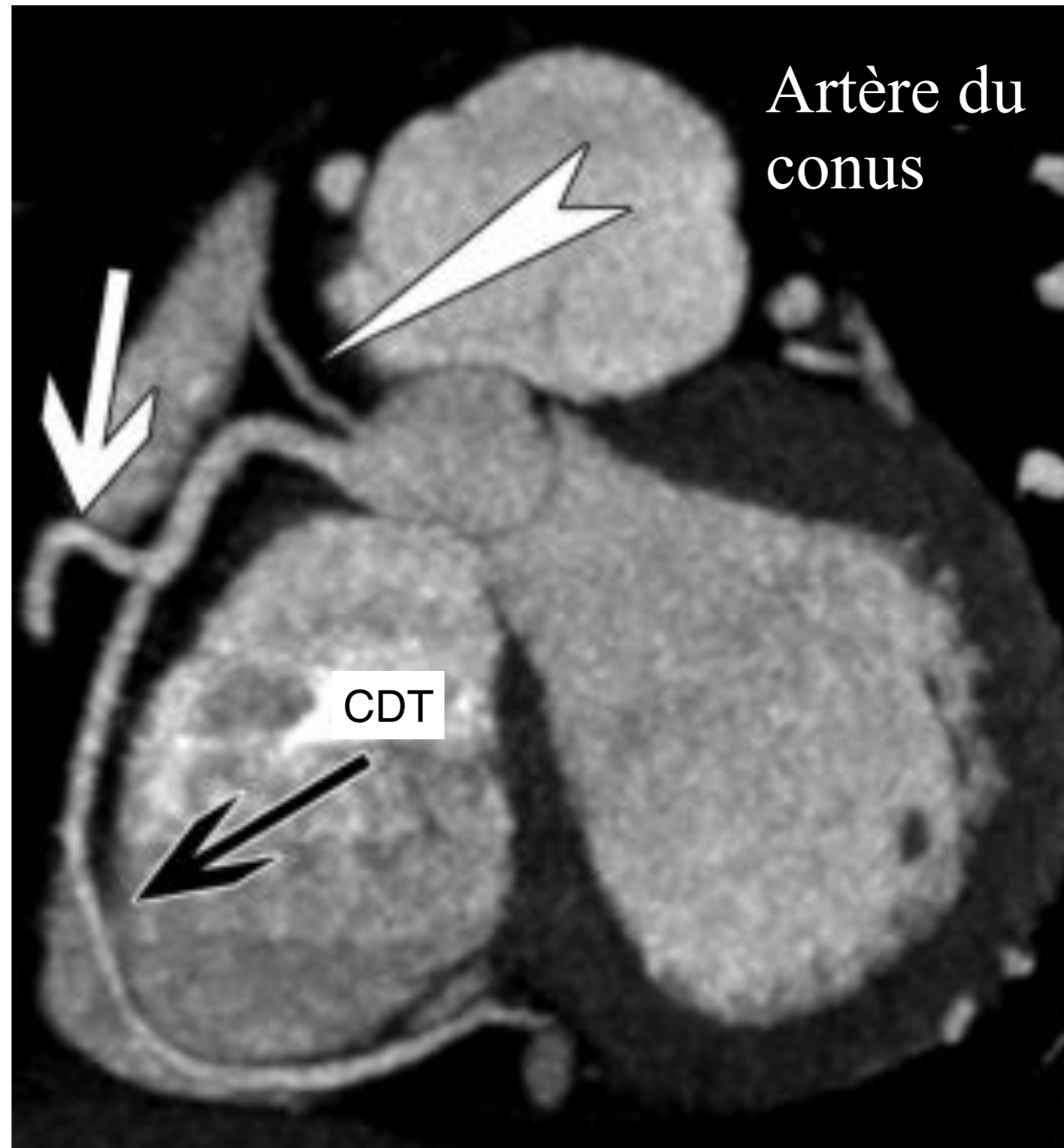


O'Brien, J. P. et al. Radiographics 2007;27:1569-1582

Radiographics

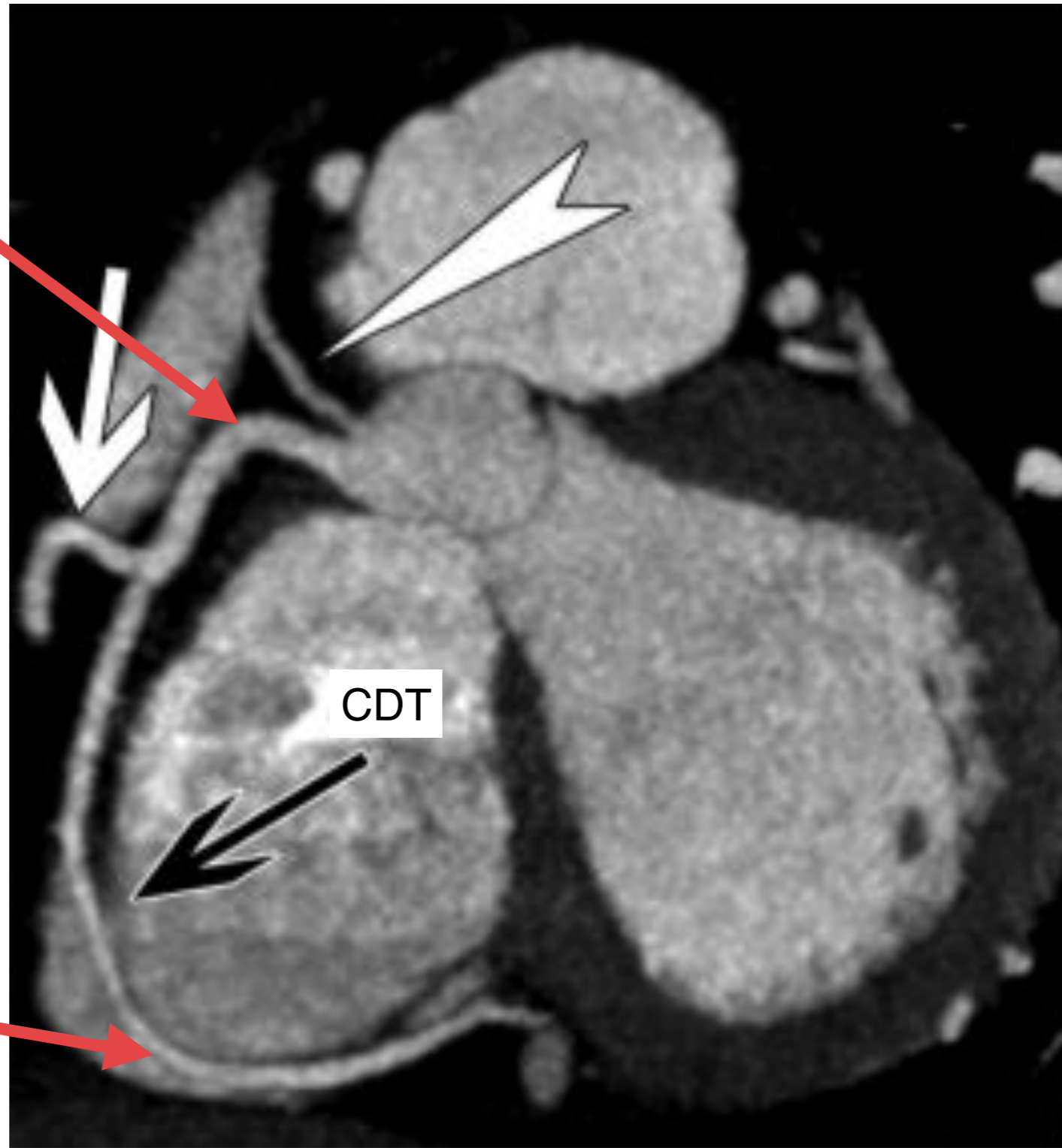
Artère coronaire droite

Artère
marginale
du bord
droit



Artère coronaire droite

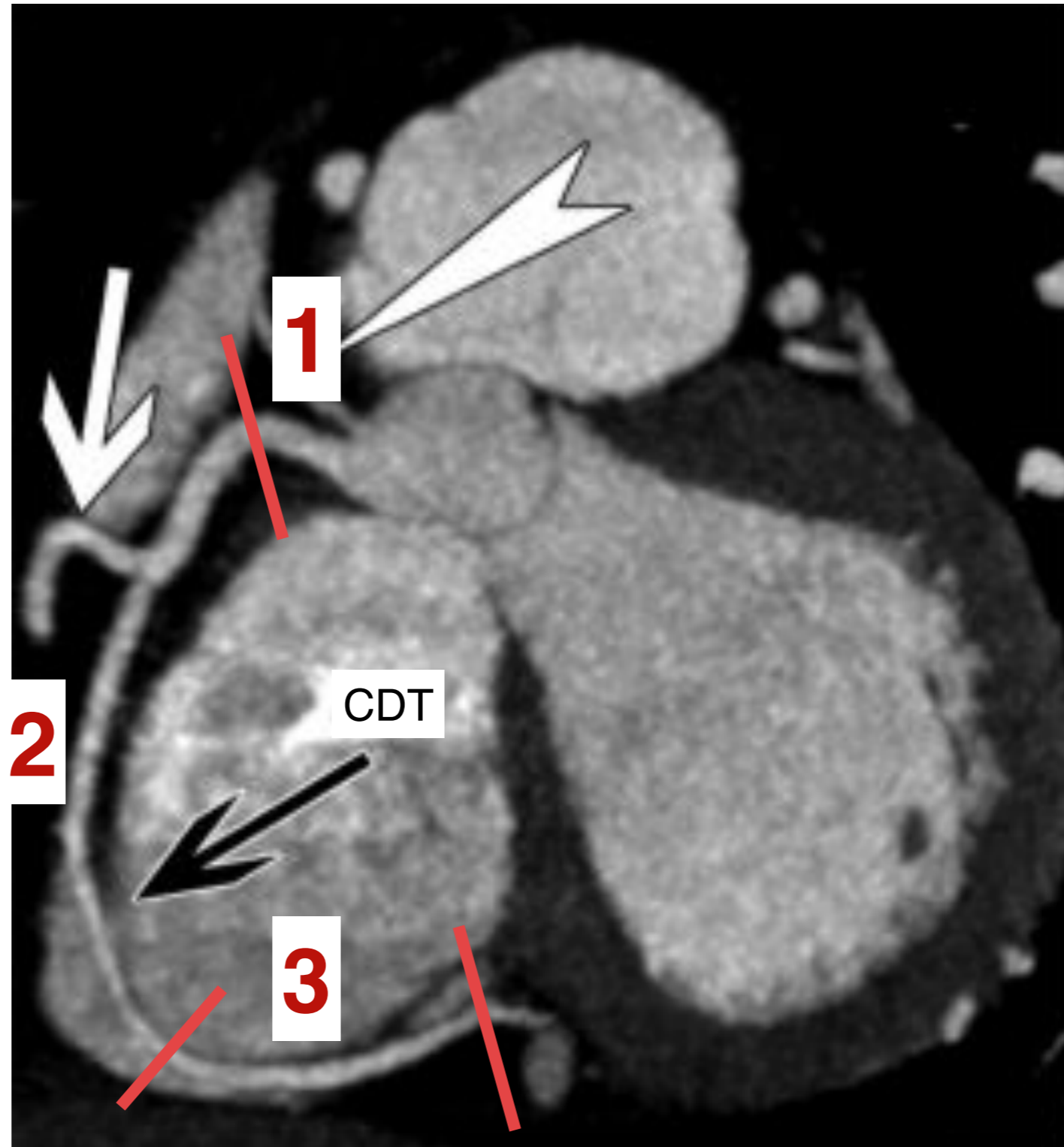
Genu
Superius



Genu
Inferius

Artère coronaire droite

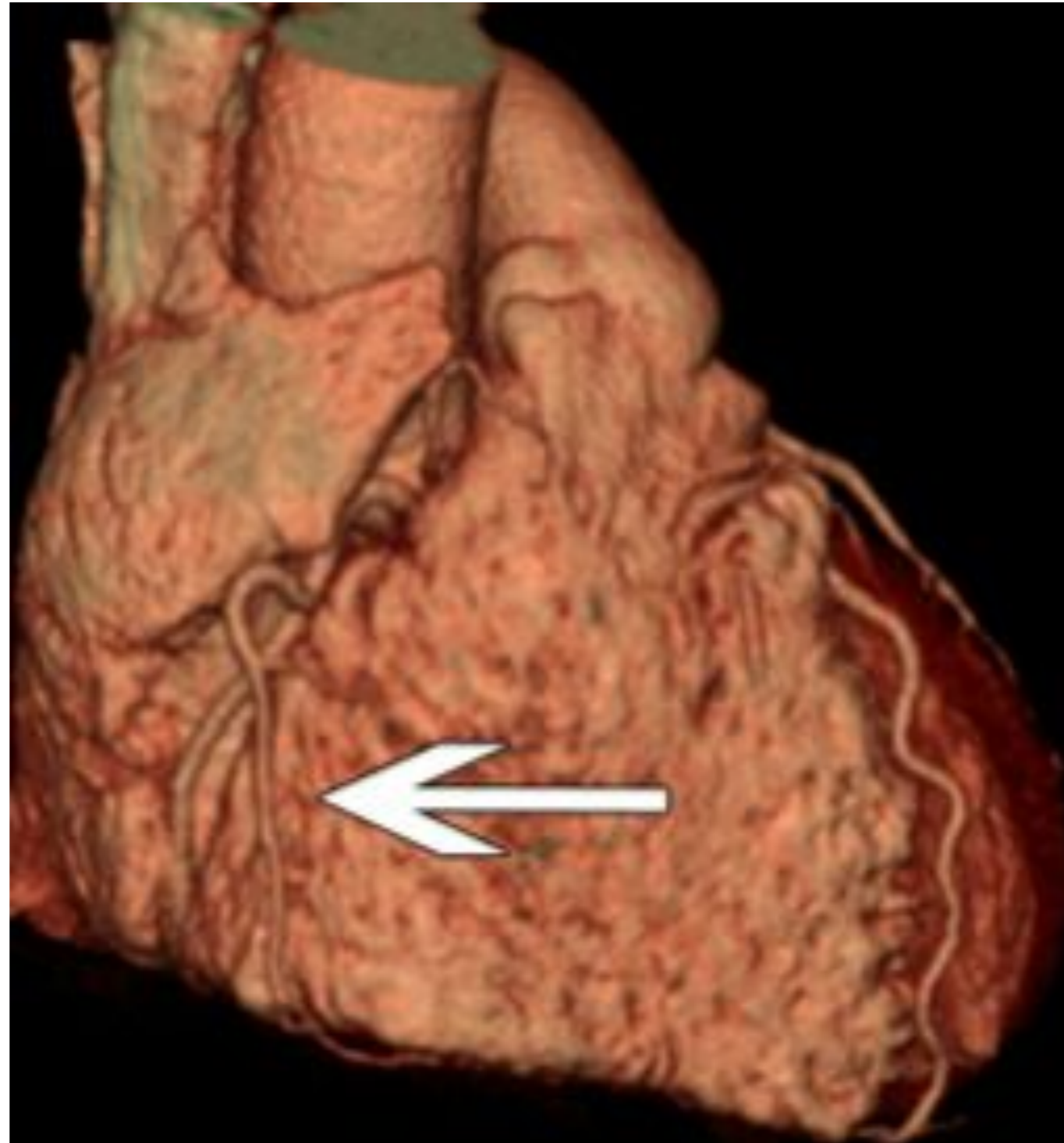Segment 1
Segment 2
Segment 3



O'Brien, J. P. et al. Radiographics 2007;27:1569-1582

nauoGraphics

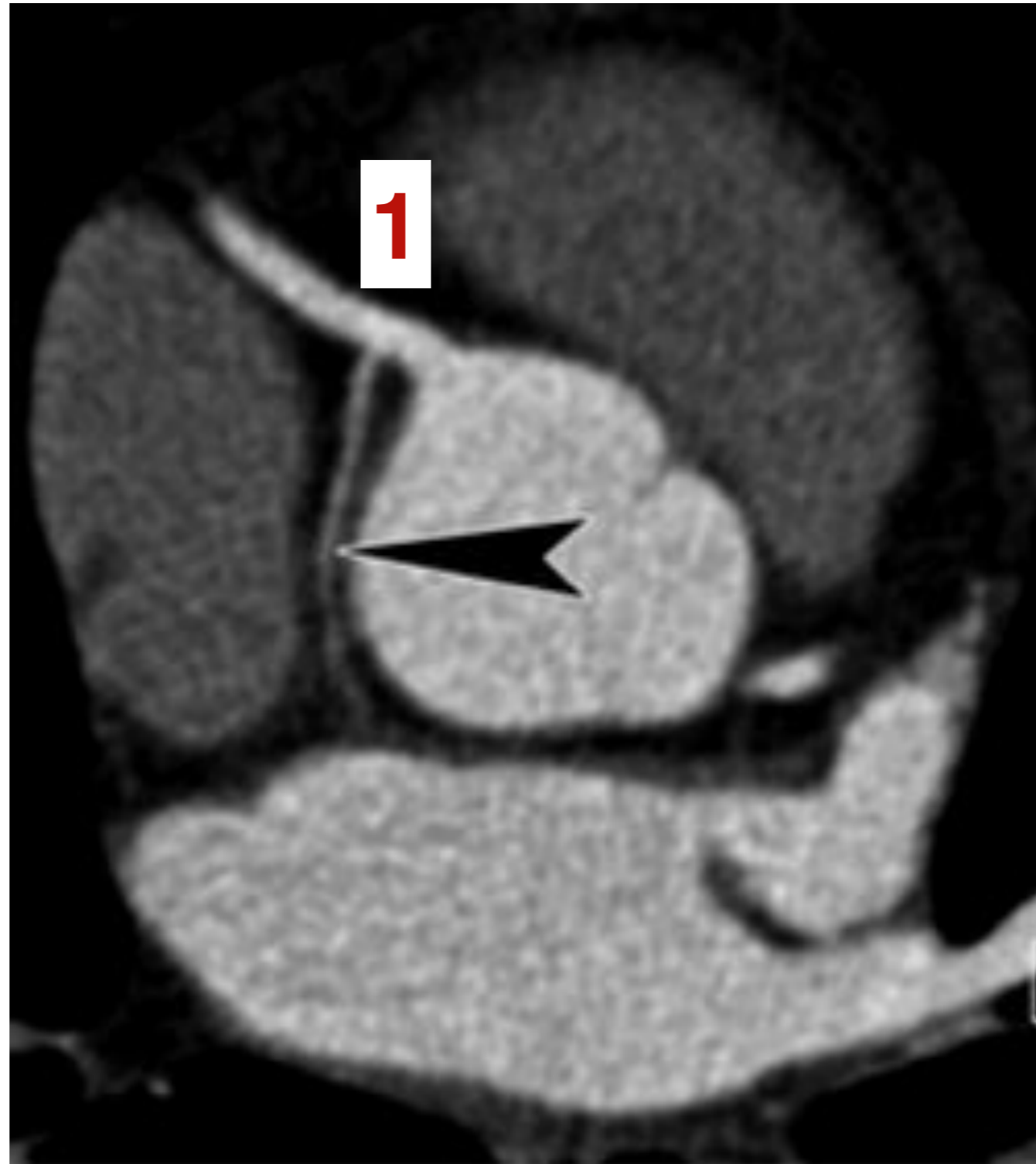
Artère marginale du bord droit



O'Brien, J. P. et al. Radiographics 2007;27:1569-1582

Radiographics

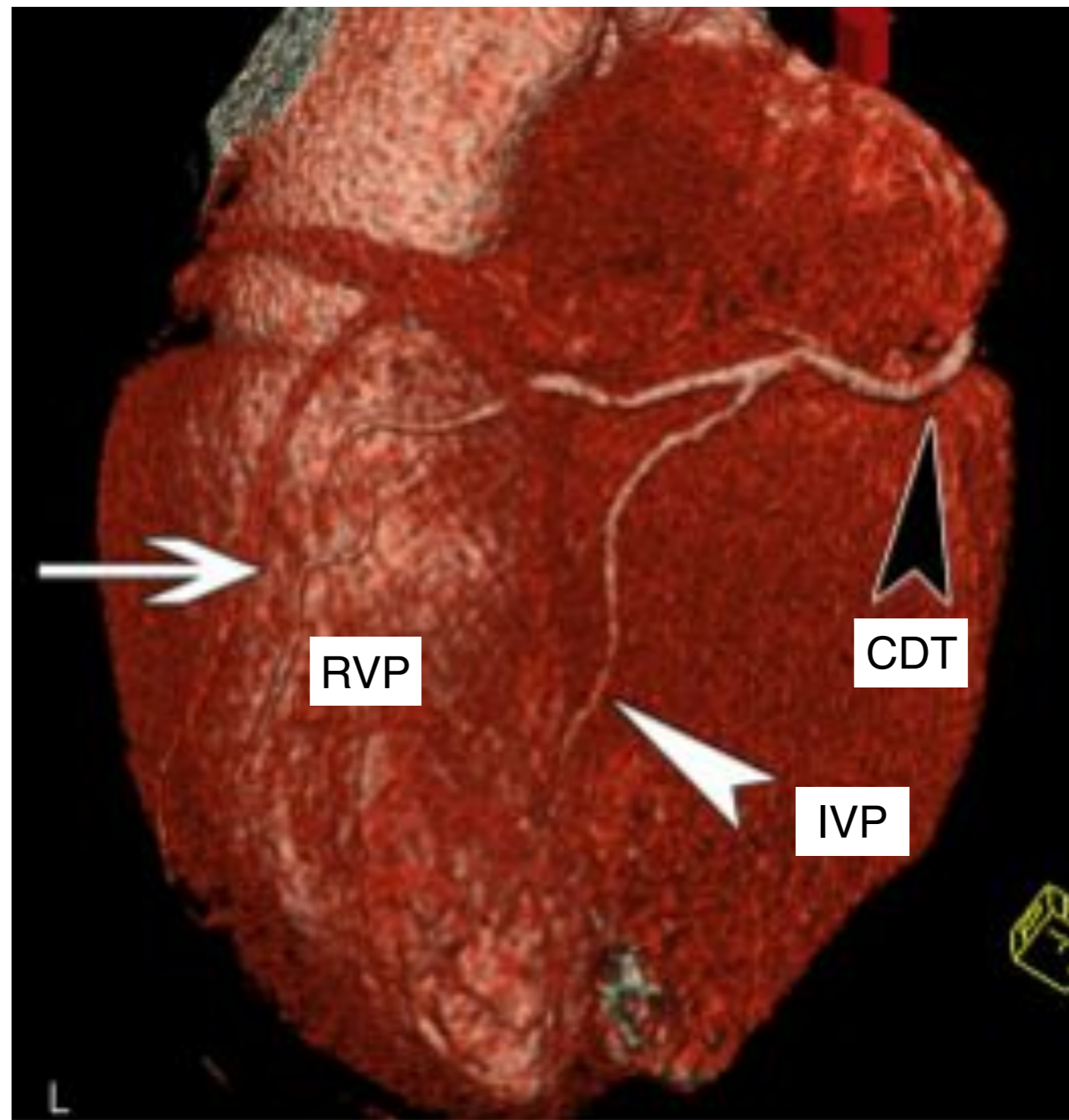
Artère du nœud sino-atrial



O'Brien, J. P. et al. Radiographics 2007;27:1569-1582

Radiographics

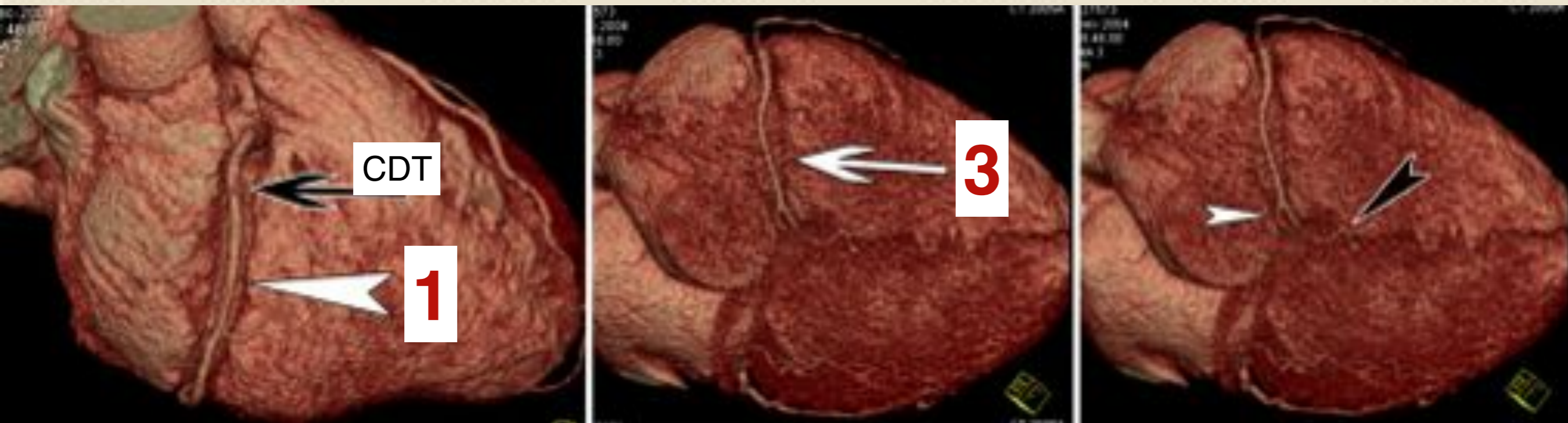
Dominance droite (85% des cas)



O'Brien, J. P. et al. Radiographics 2007;27:1569-1582

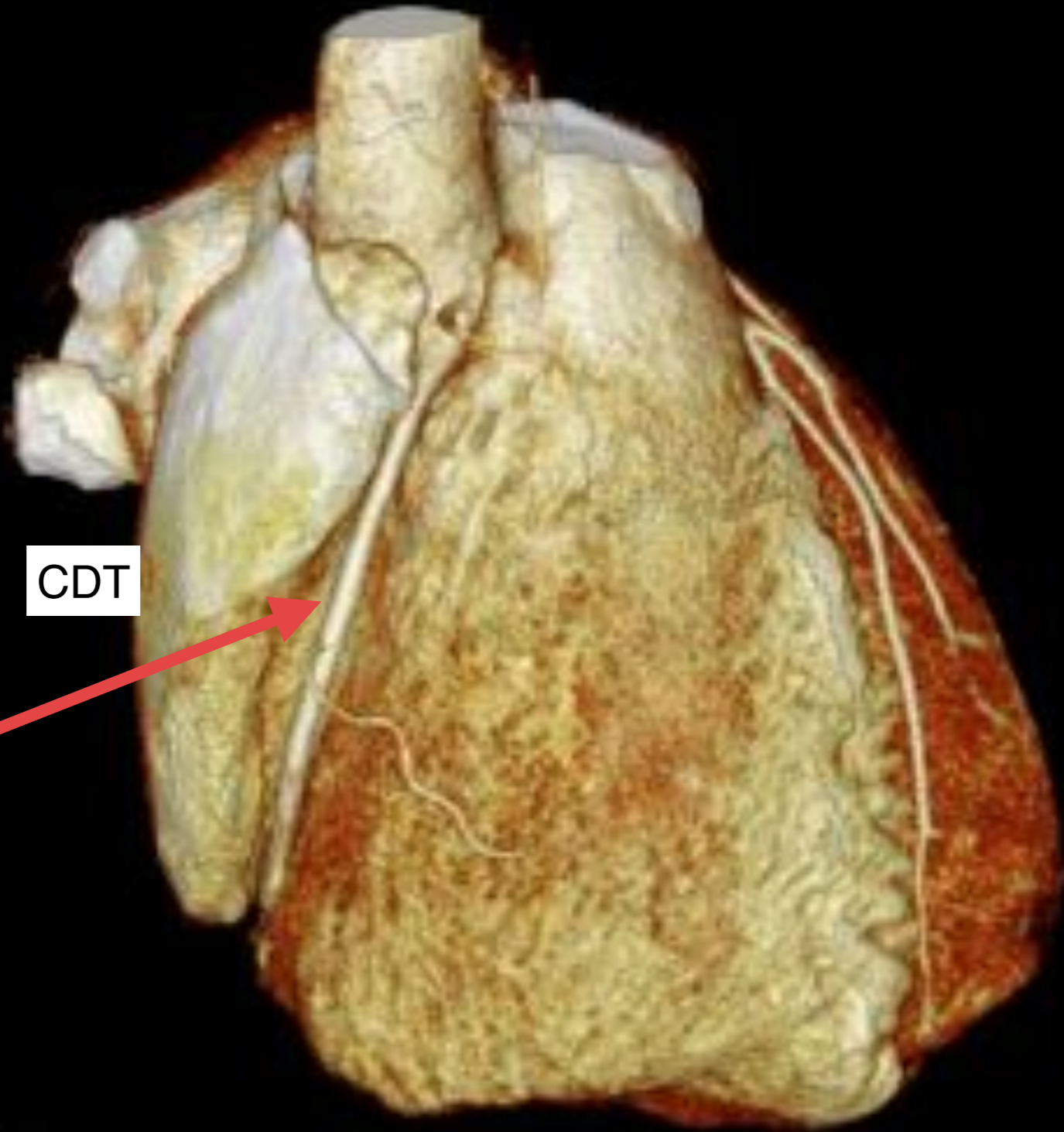
Radiographics

ARTÈRE CORONAIRE DROITE



O'Brien, J. P. et al. Radiographics 2007;27:1569-1582

Radiographics

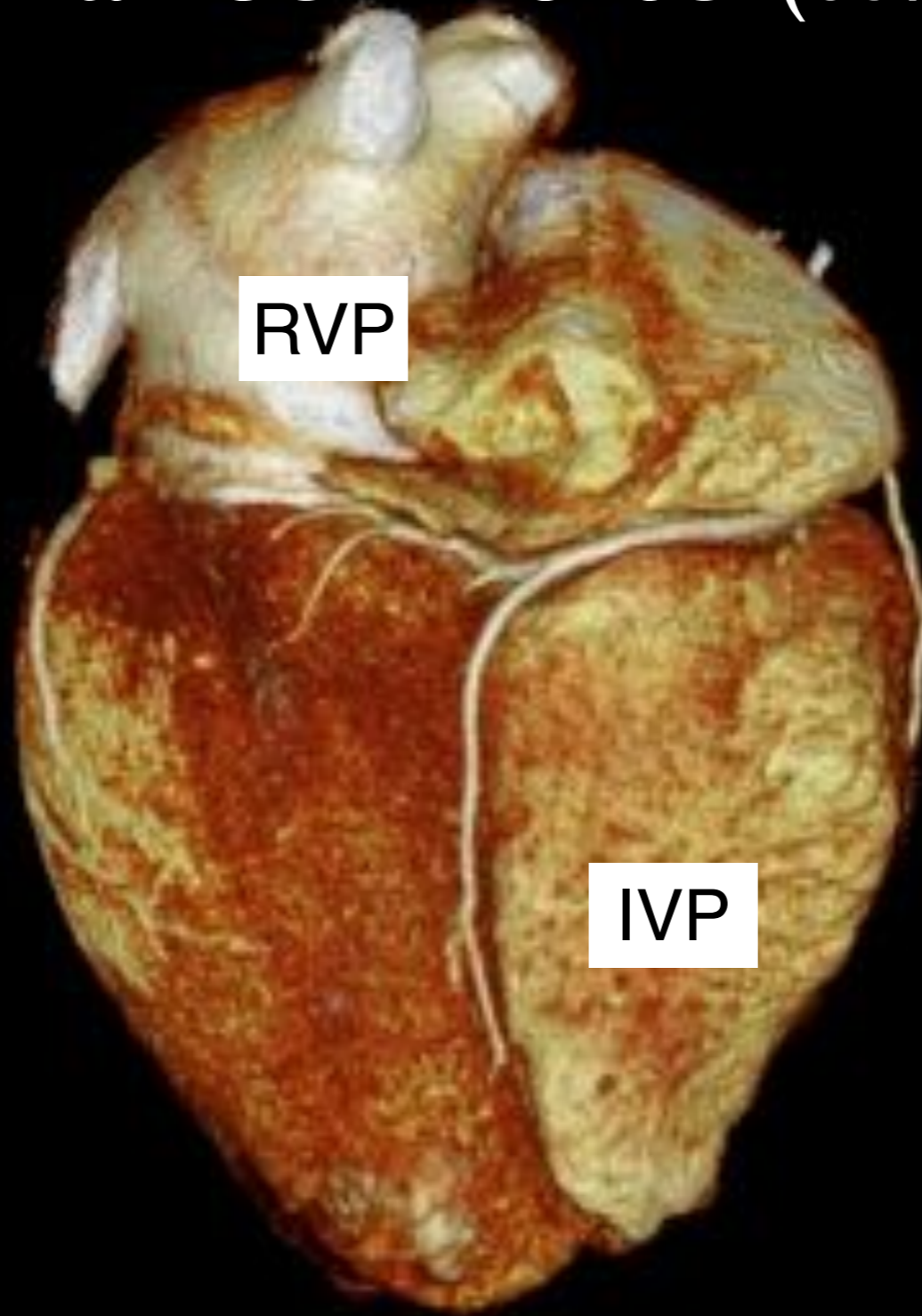


2

CDT



Dominance droite (85% des cas)



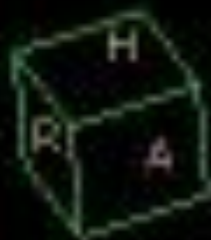
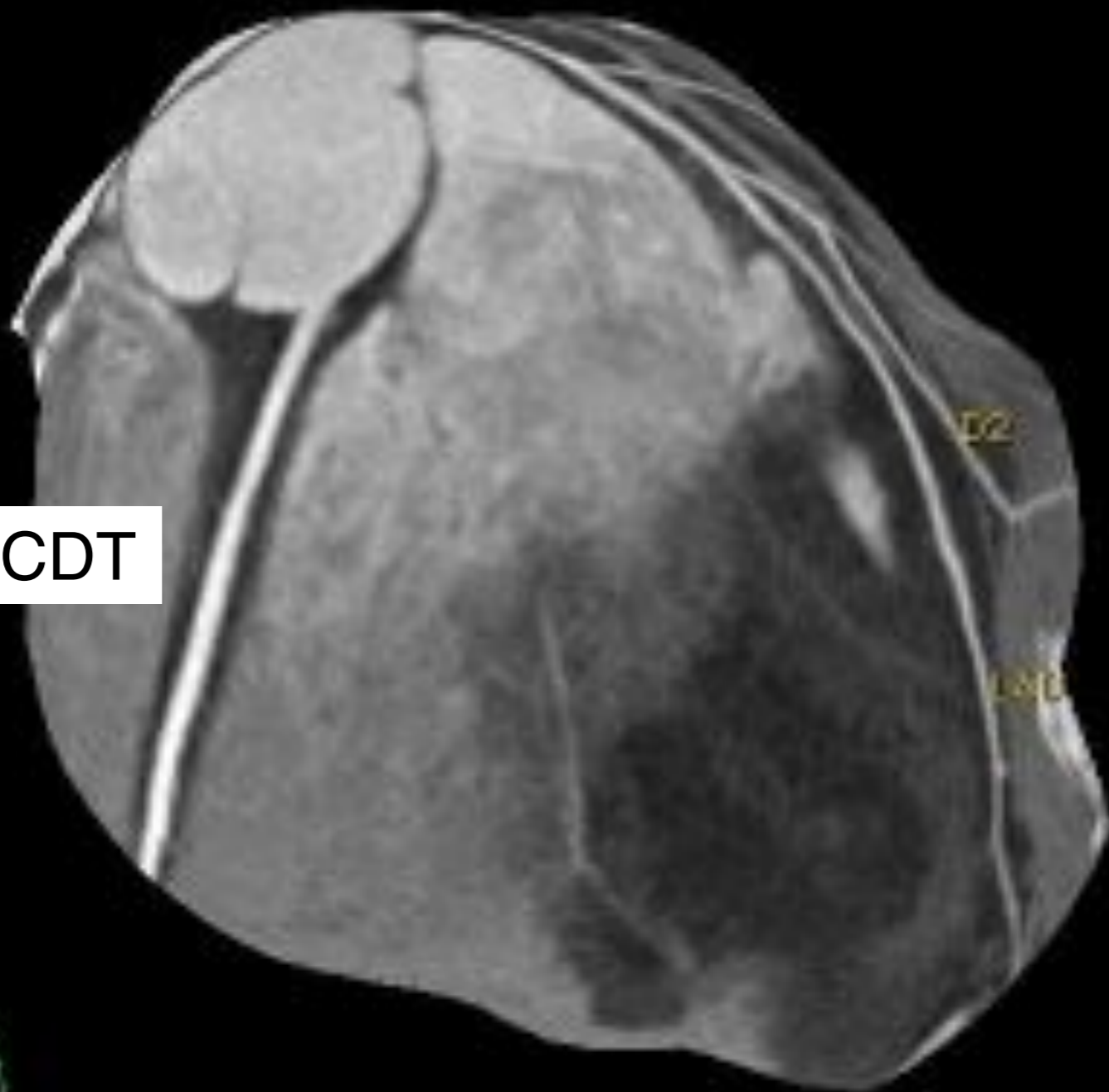RVP

CDT

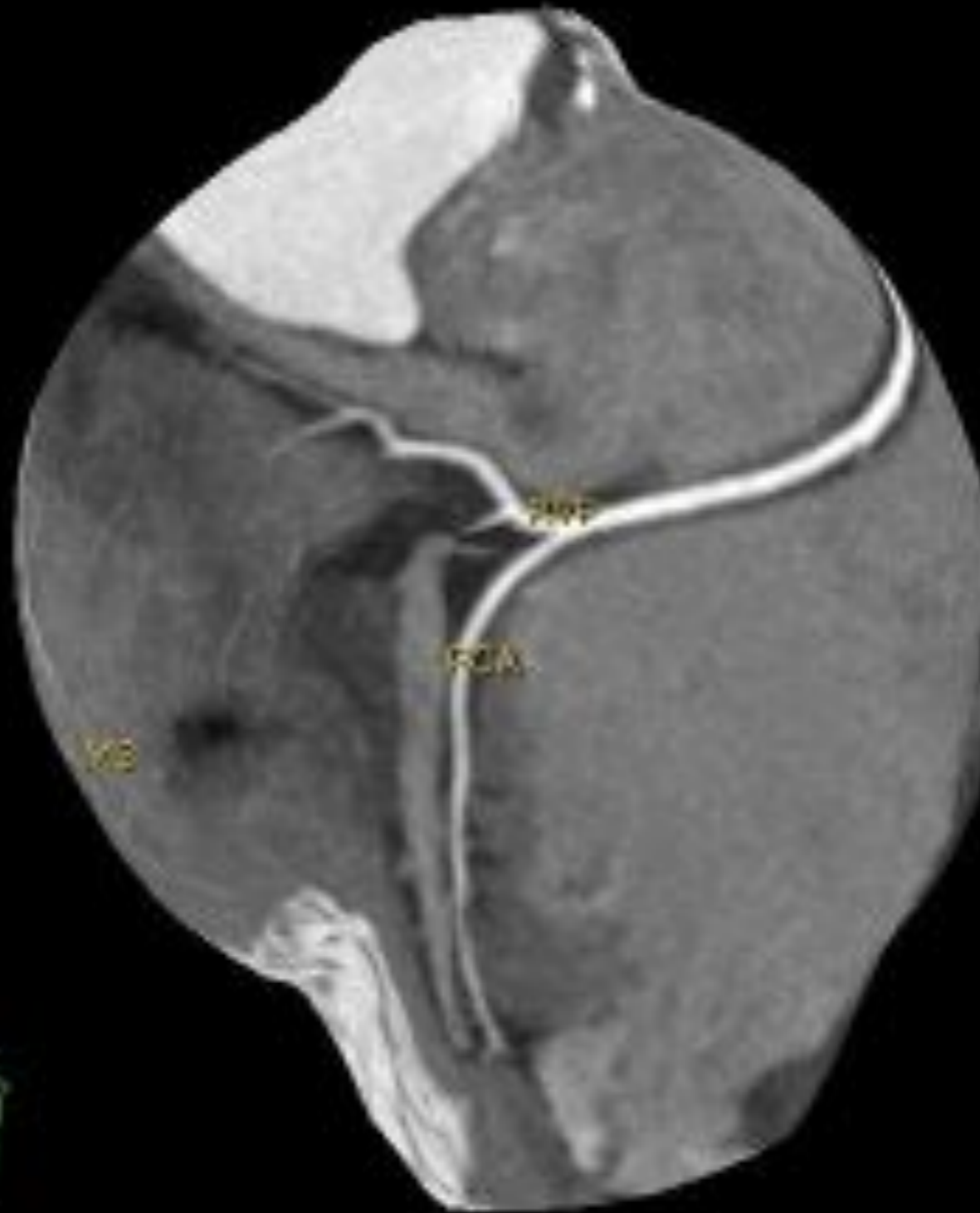IVP



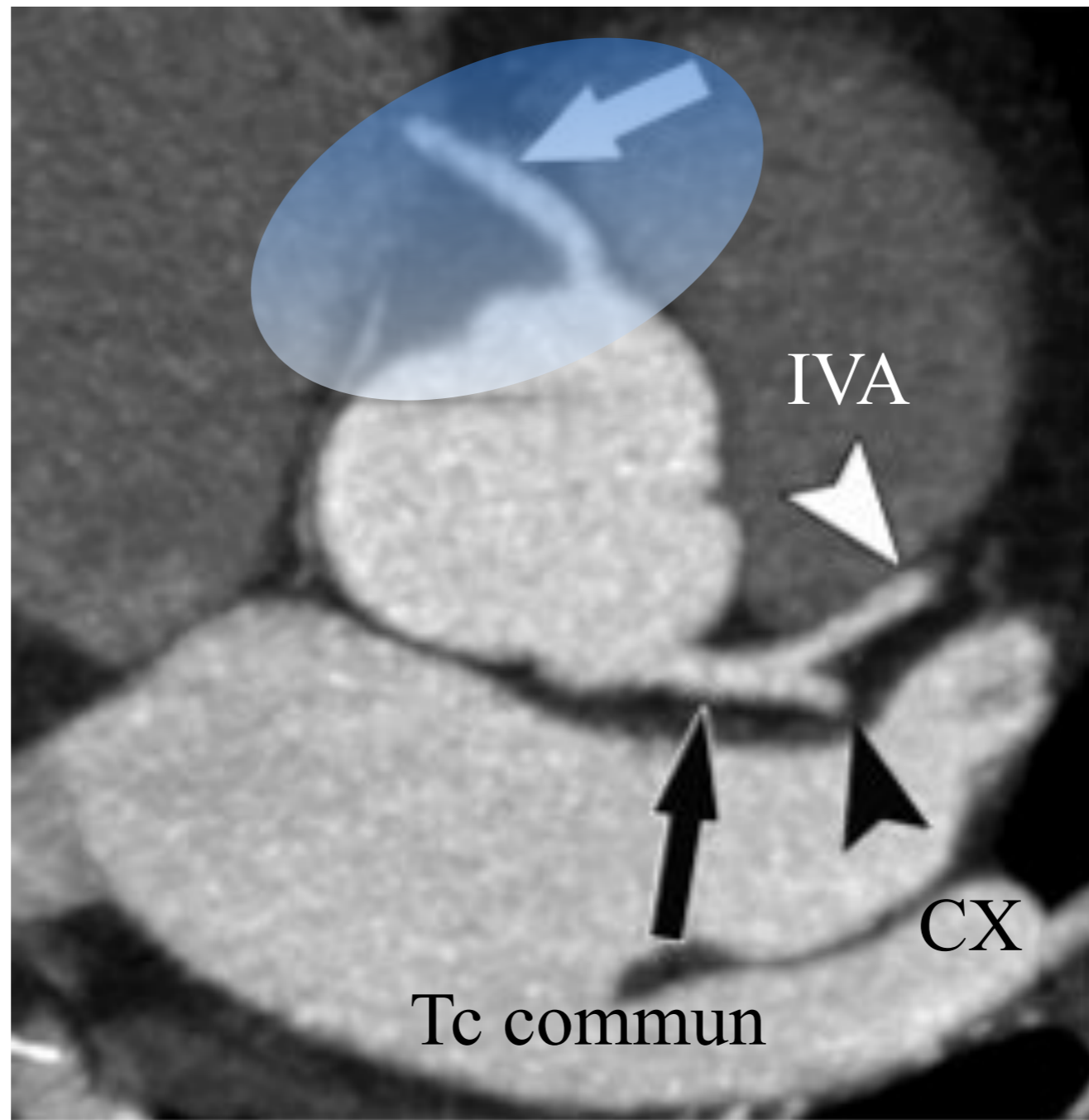
CDT



Dominance droite (85% des cas)



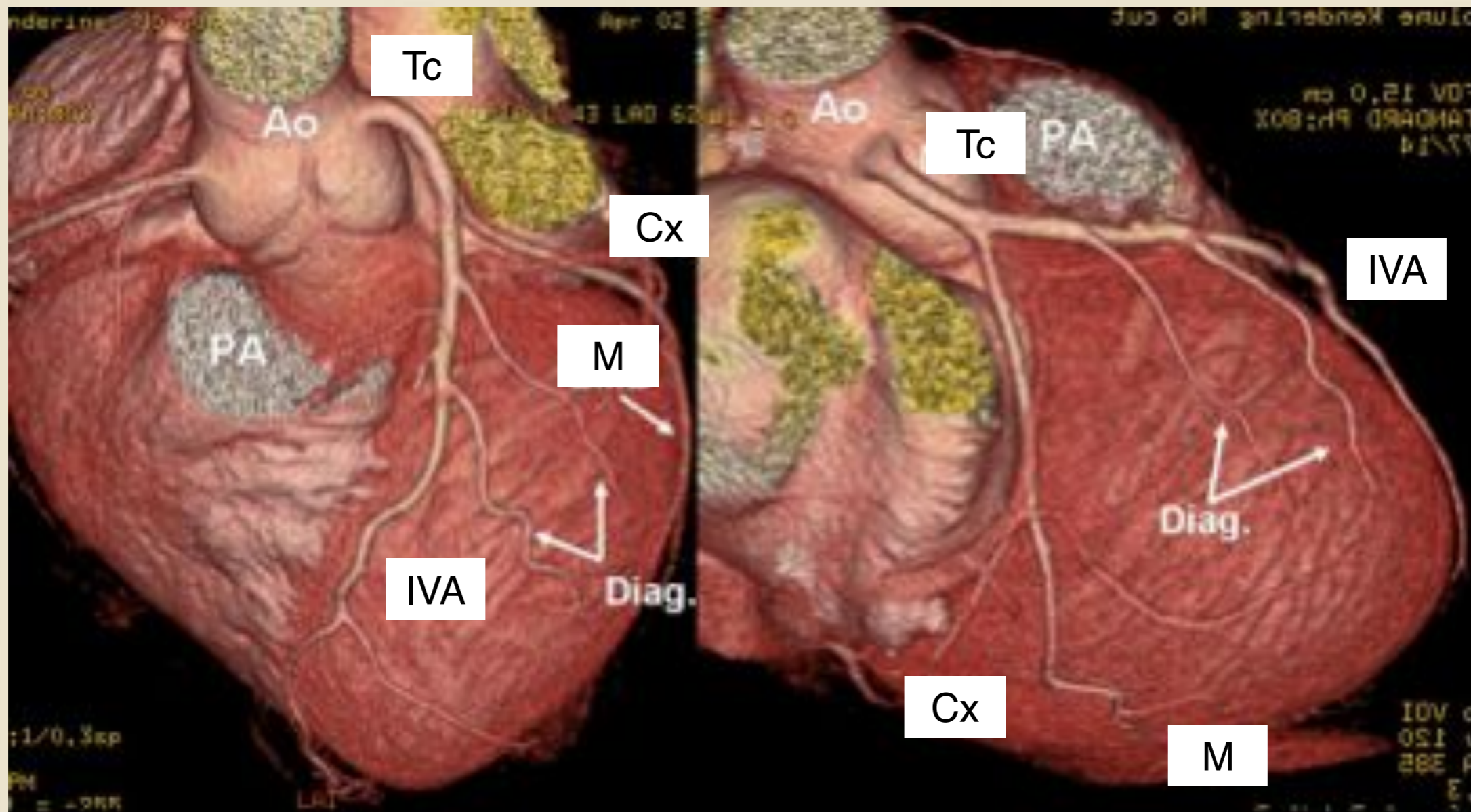
Réseau coronaire gauche



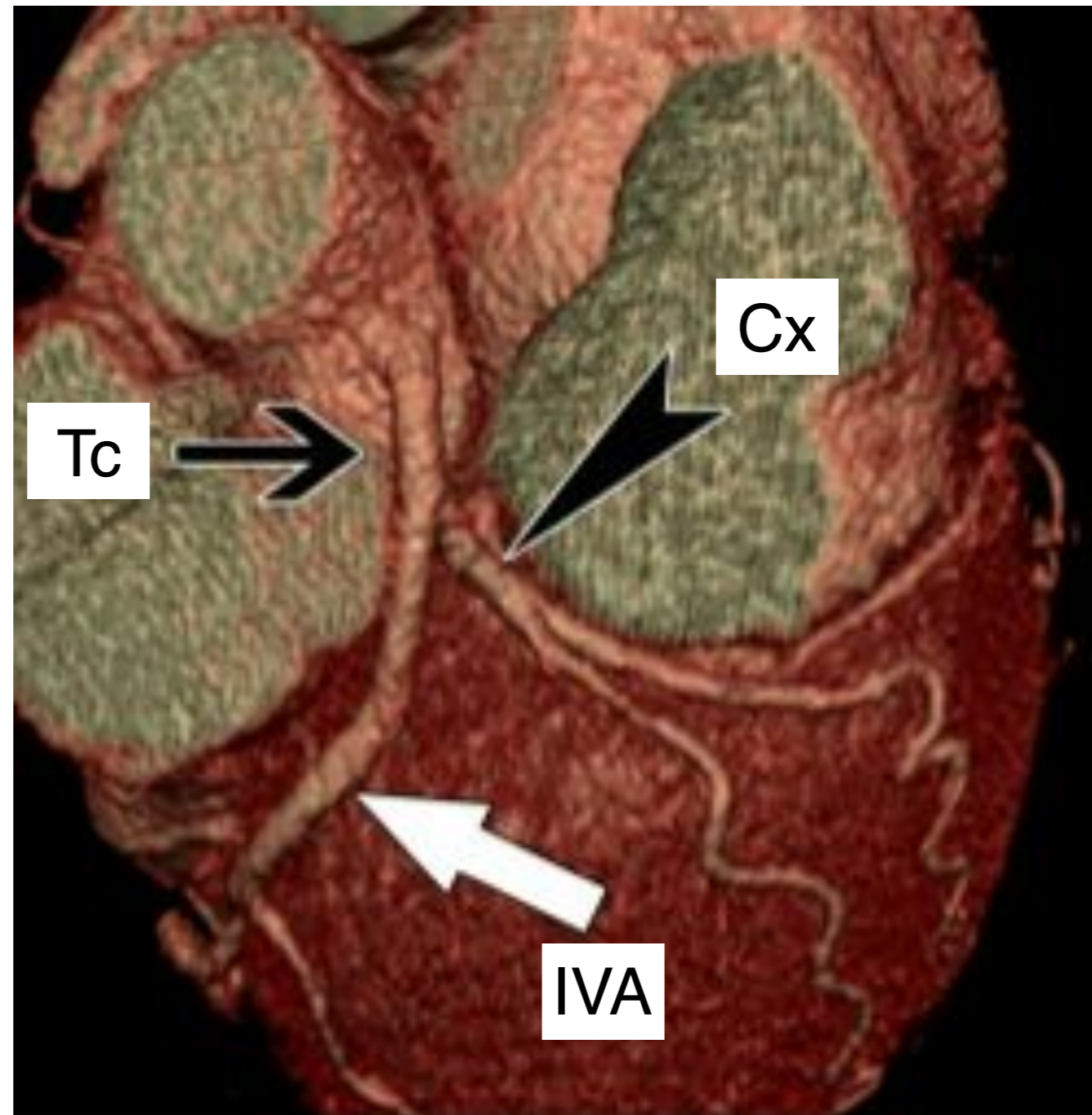
O'Brien, J. P. et al. Radiographics 2007;27:1569-1582

Radiographics

ANATOMIE CORONAIRE



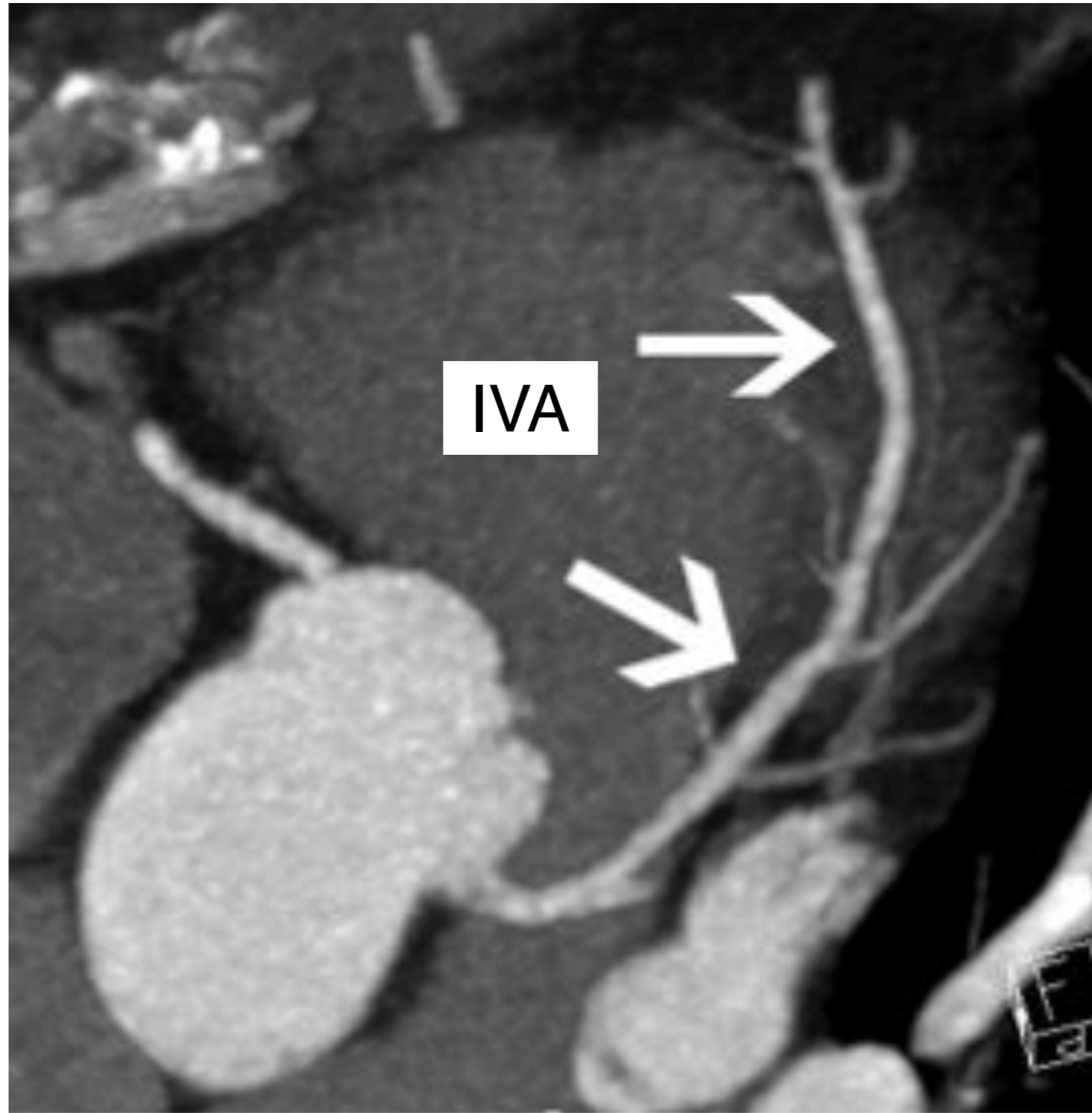
Tronc commun / IVA / CX



O'Brien, J. P. et al. Radiographics 2007;27:1569-1582

Radiographics

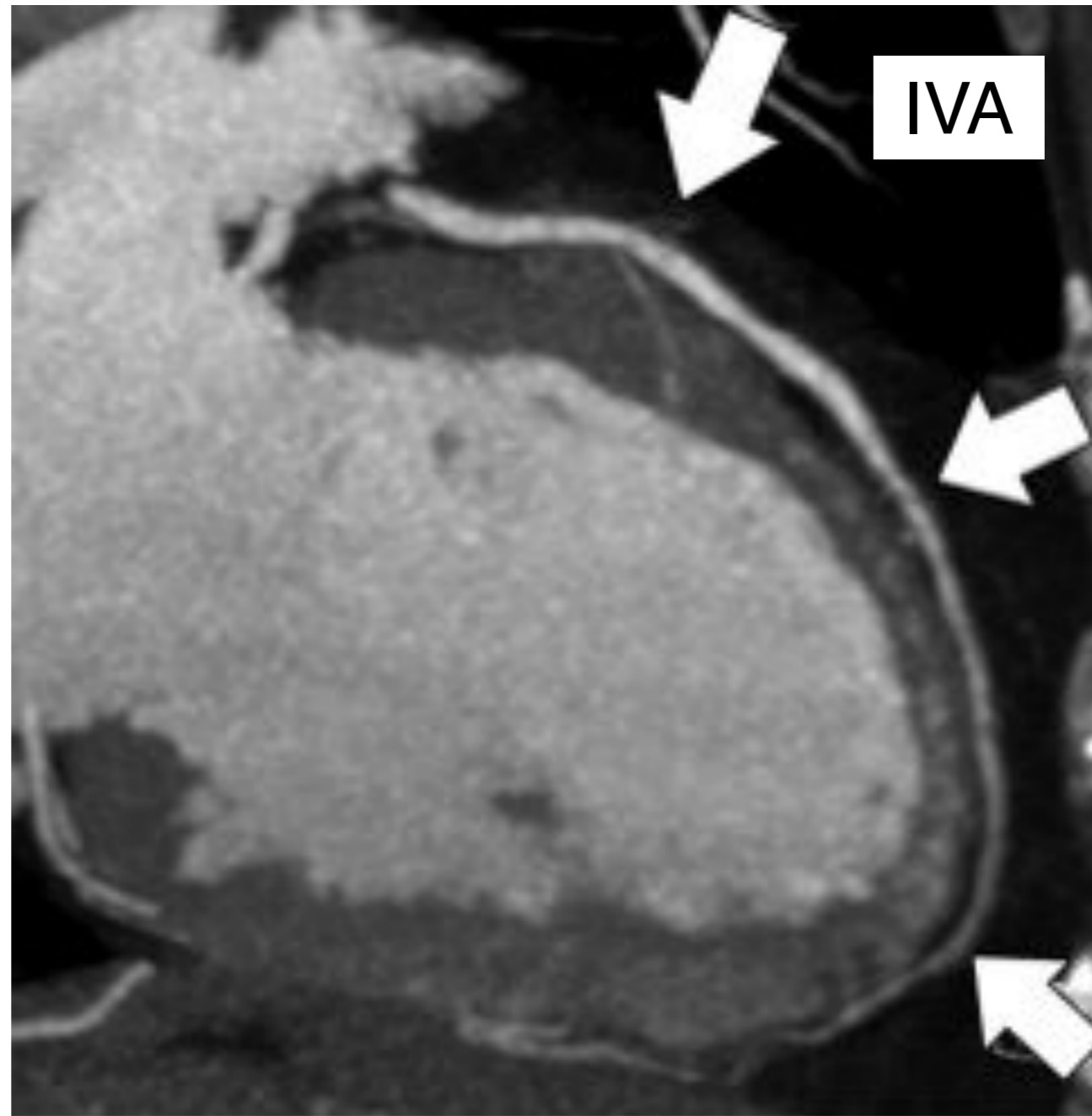
Artère Inter Ventriculaire Antérieure



O'Brien, J. P. et al. Radiographics 2007;27:1569-1582

RadiGraphics

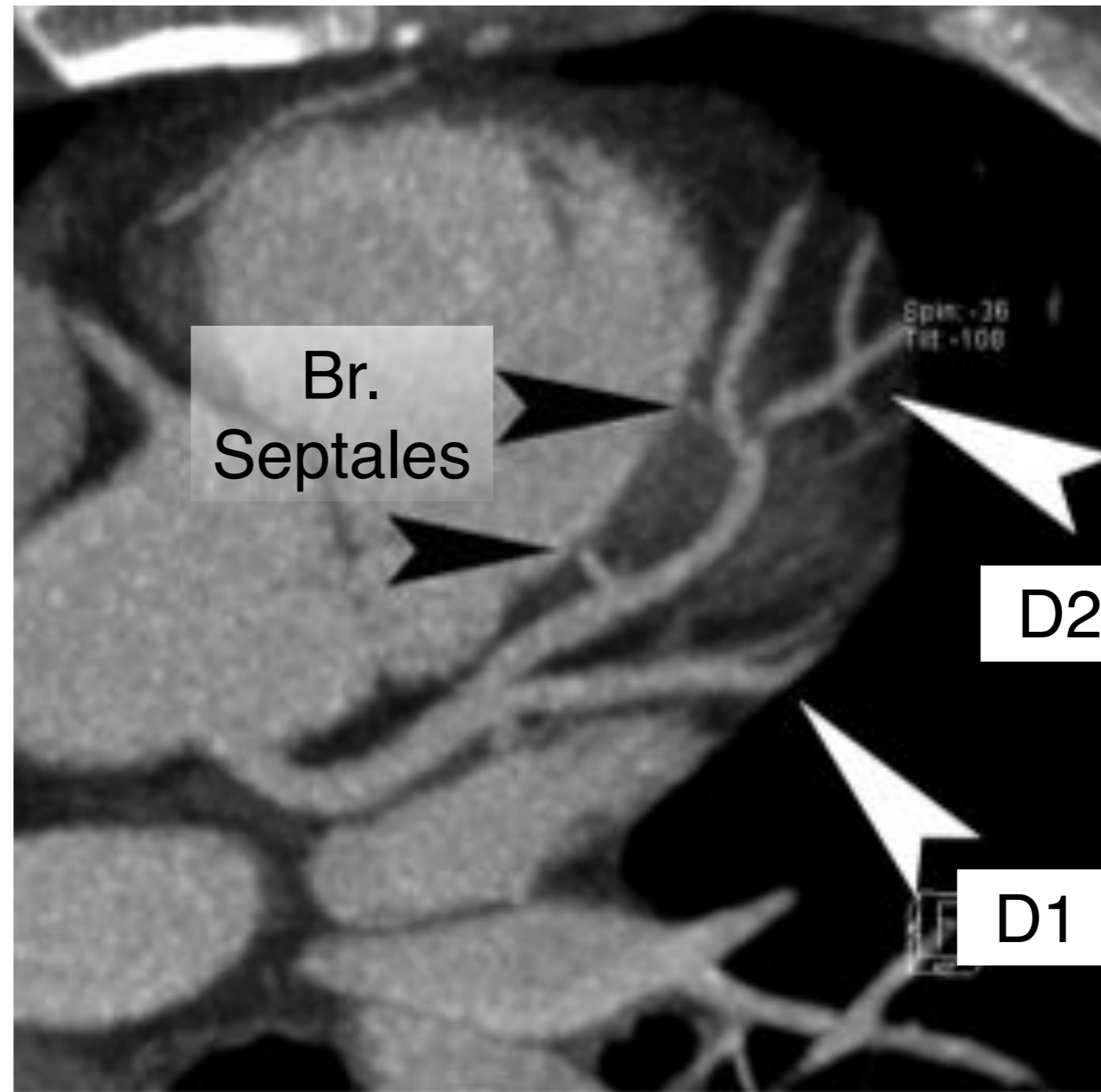
Artère Inter Ventriculaire Antérieure



O'Brien, J. P. et al. Radiographics 2007;27:1569-1582

RadiGraphics

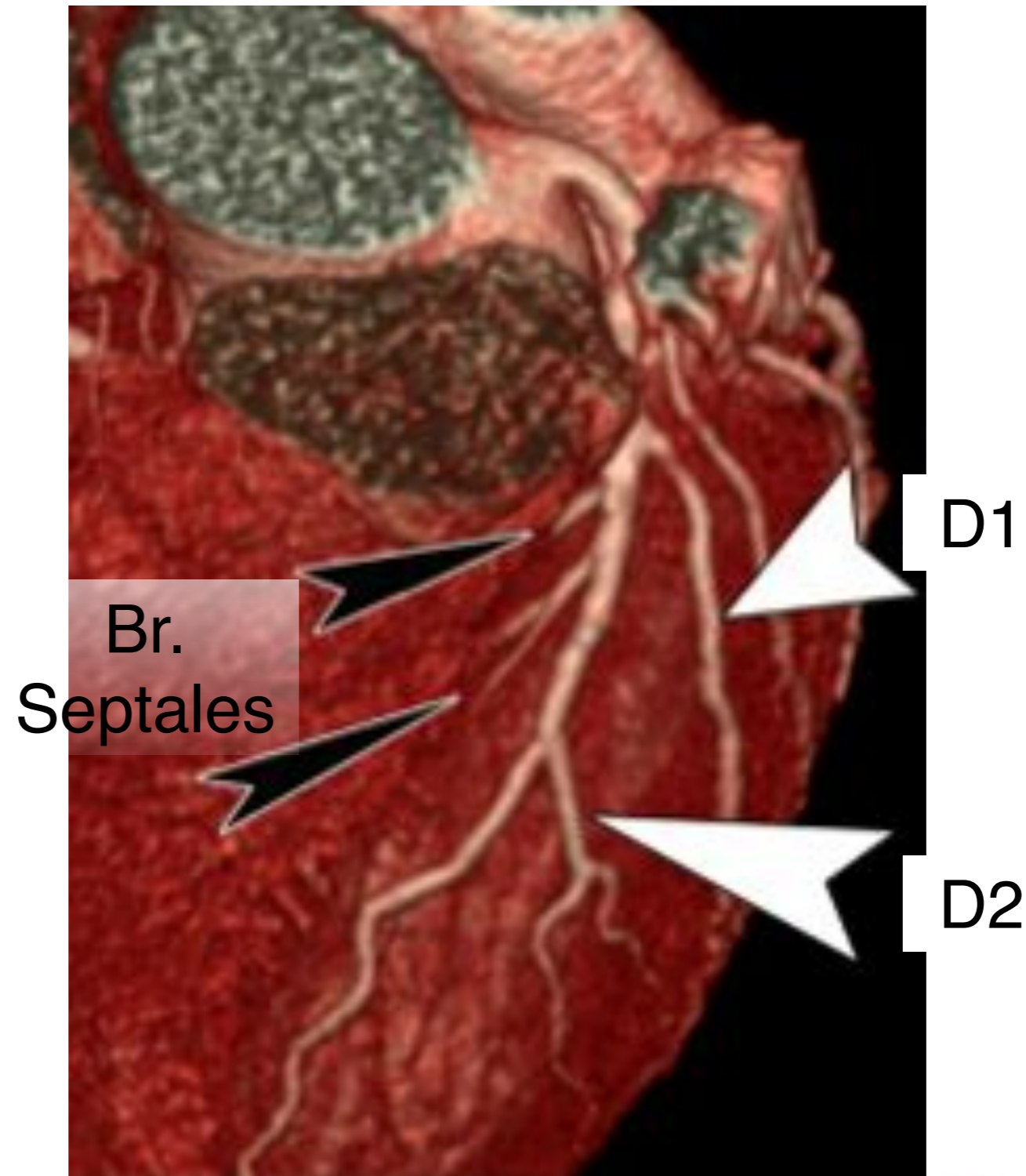Artère Inter Ventriculaire Antérieure



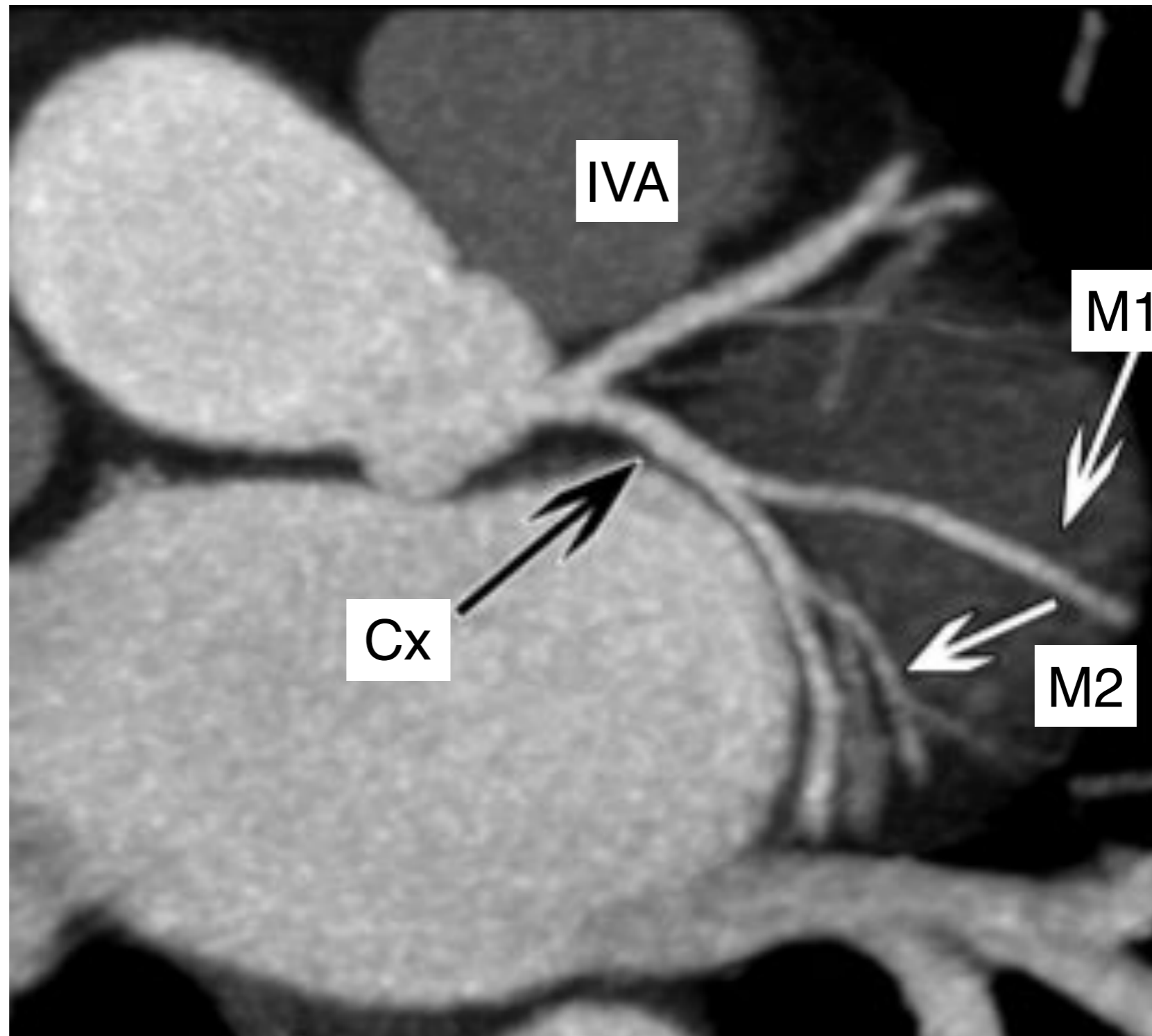
O'Brien, J. P. et al. Radiographics 2007;27:1569-1582

Radiographics

Artère Inter Ventriculaire Antérieure



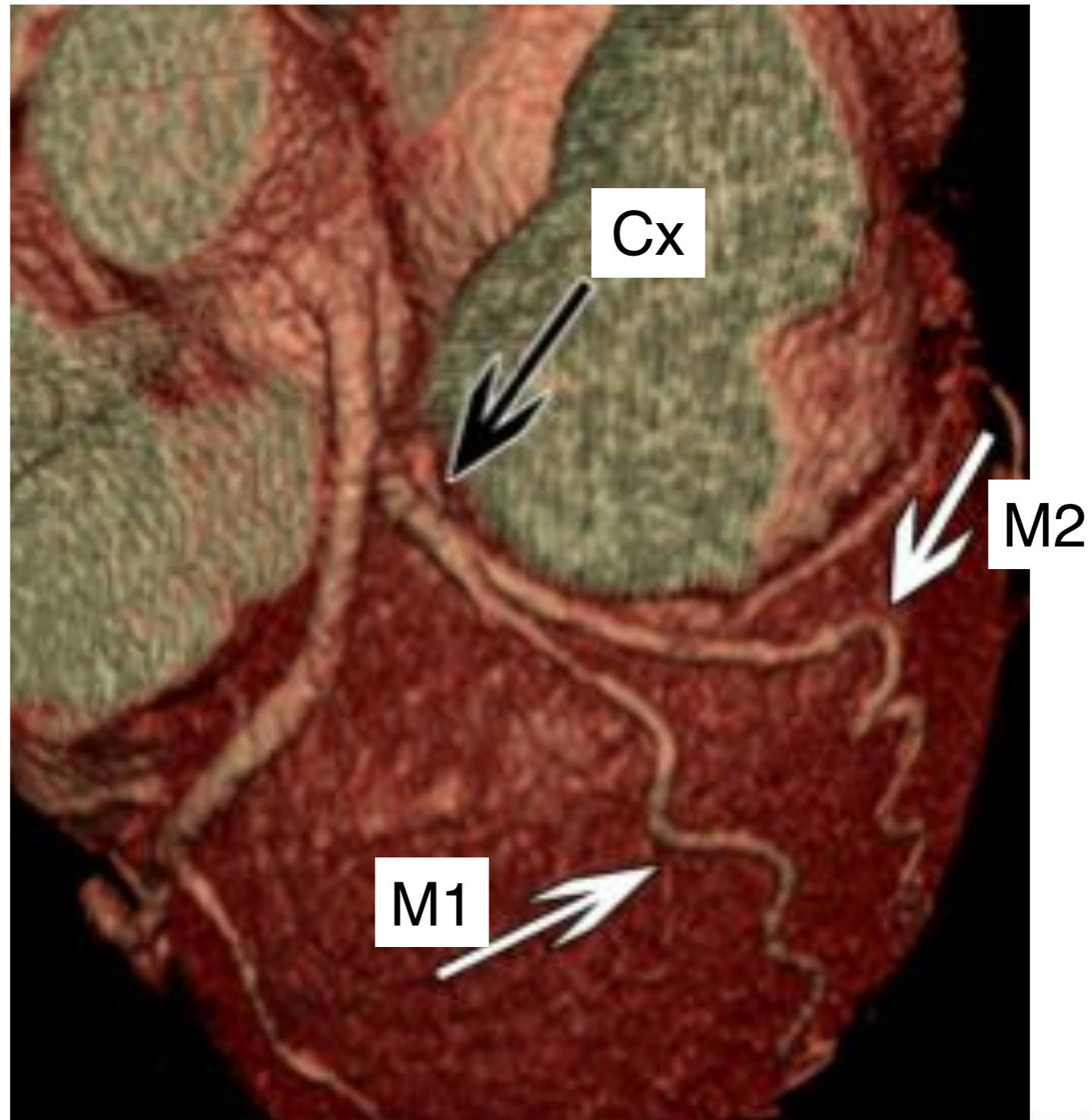
Artère circonflexe



O'Brien, J. P. et al. Radiographics 2007;27:1569-1582

Radiographics

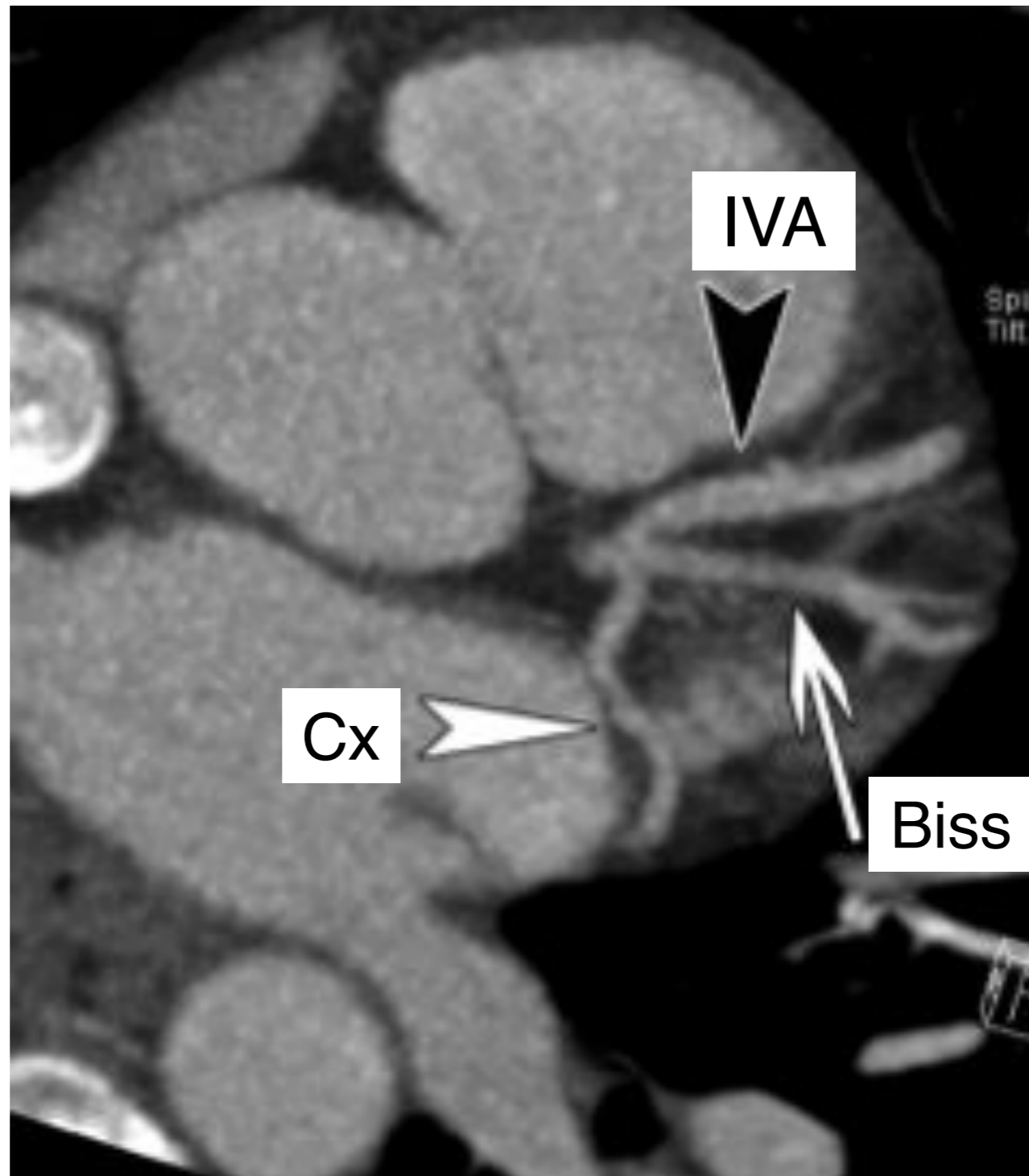
Artère circonflexe



O'Brien, J. P. et al. Radiographics 2007;27:1569-1582

Radiographics

Artère bissectrice (Biss.) (Angulaire)

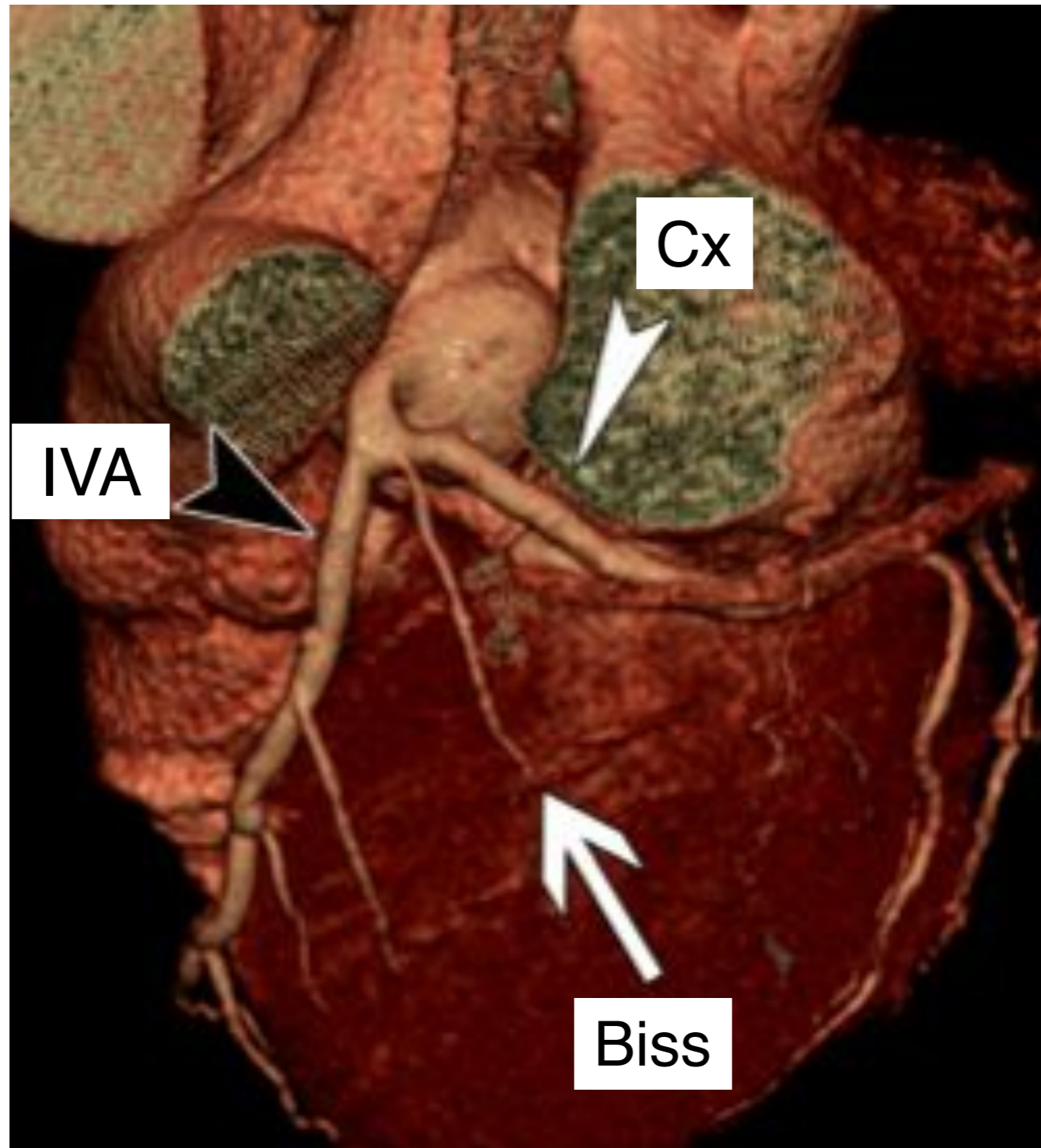


15% des patients

O'Brien, J. P. et al. Radiographics 2007;27:1569-1582

Radiographics

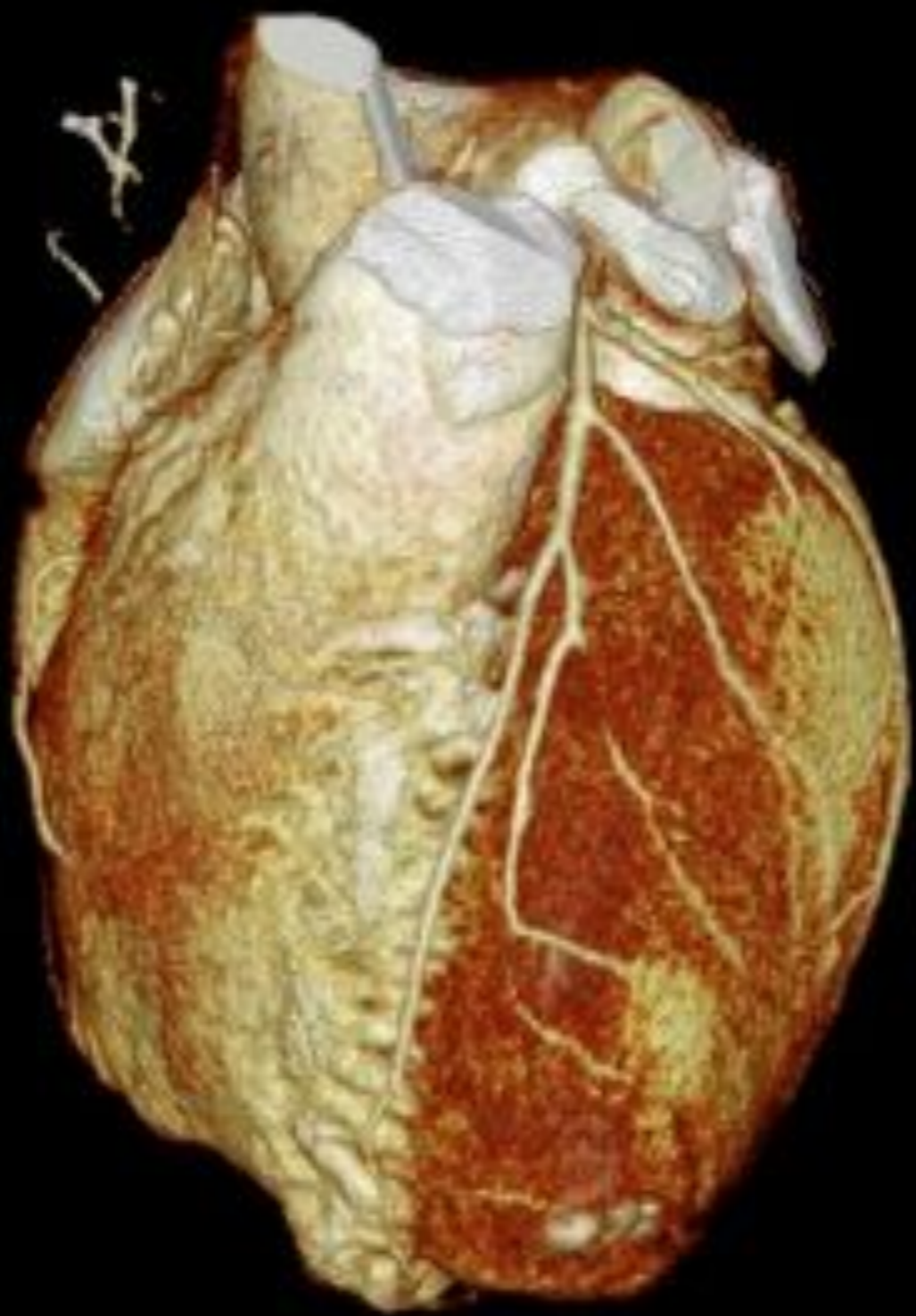Artère bissectrice



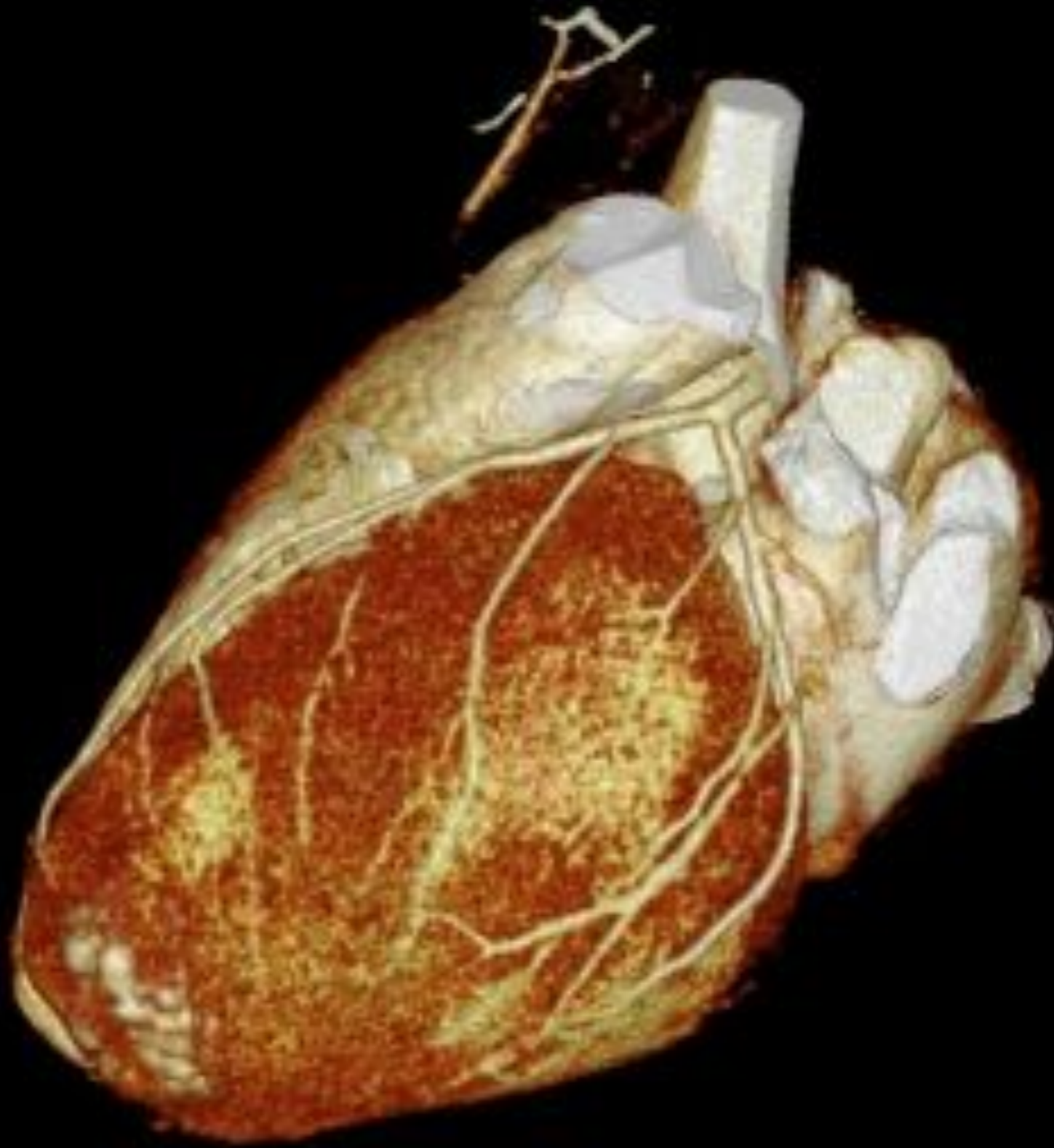15% des patients

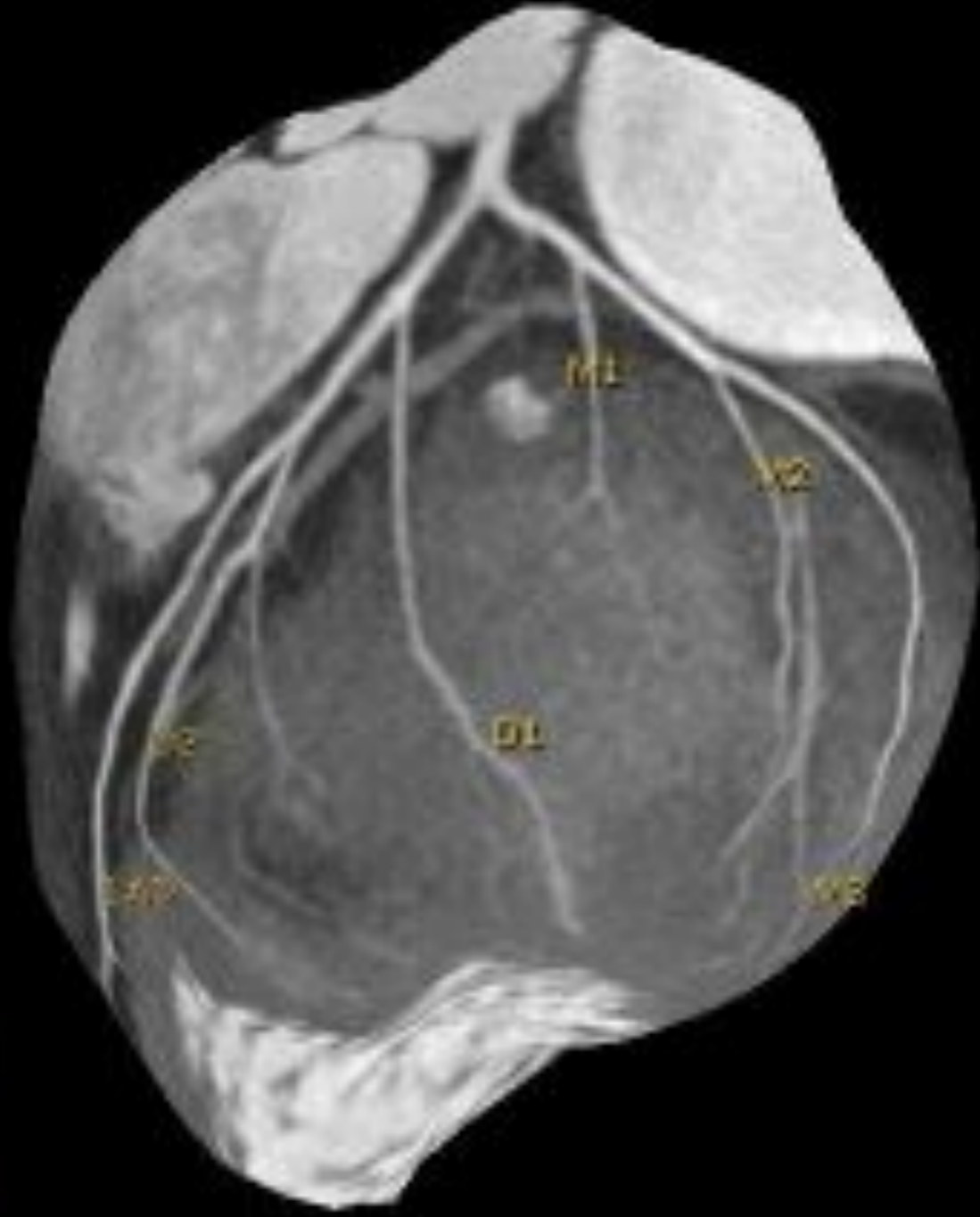O'Brien, J. P. et al. Radiographics 2007;27:1569-1582

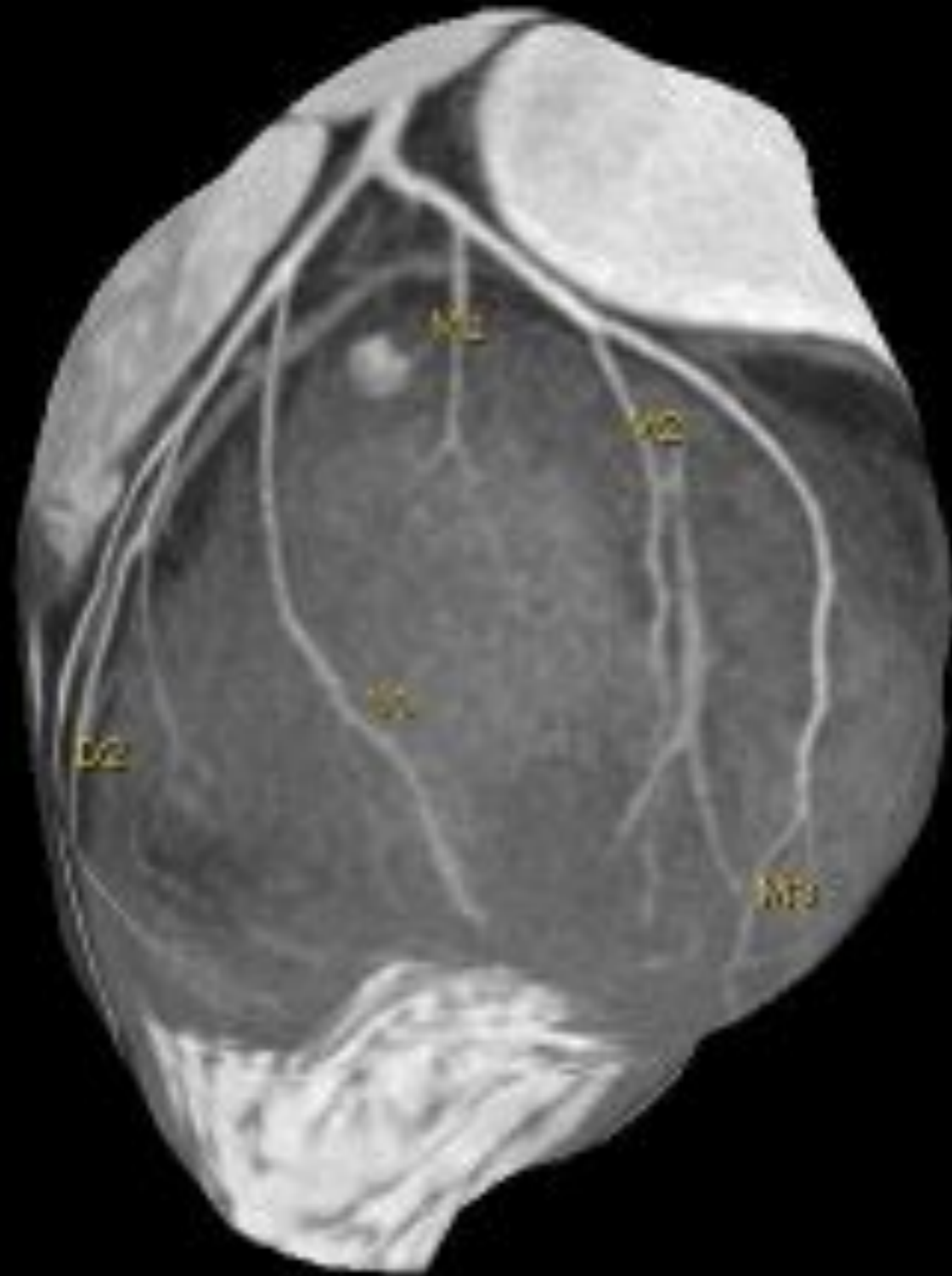Radiographics



PHILIPS

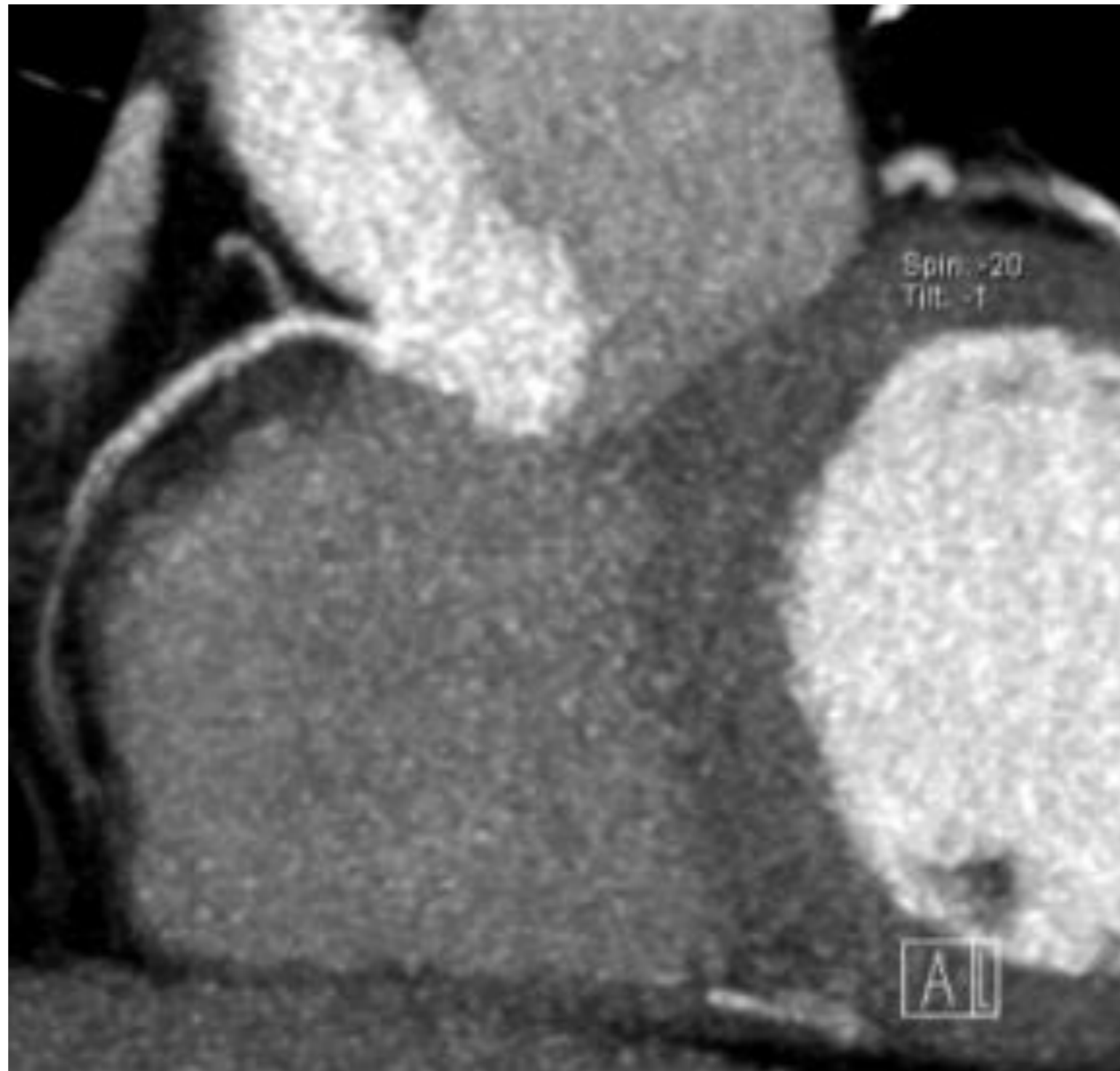






Dominance Gauche Exemple

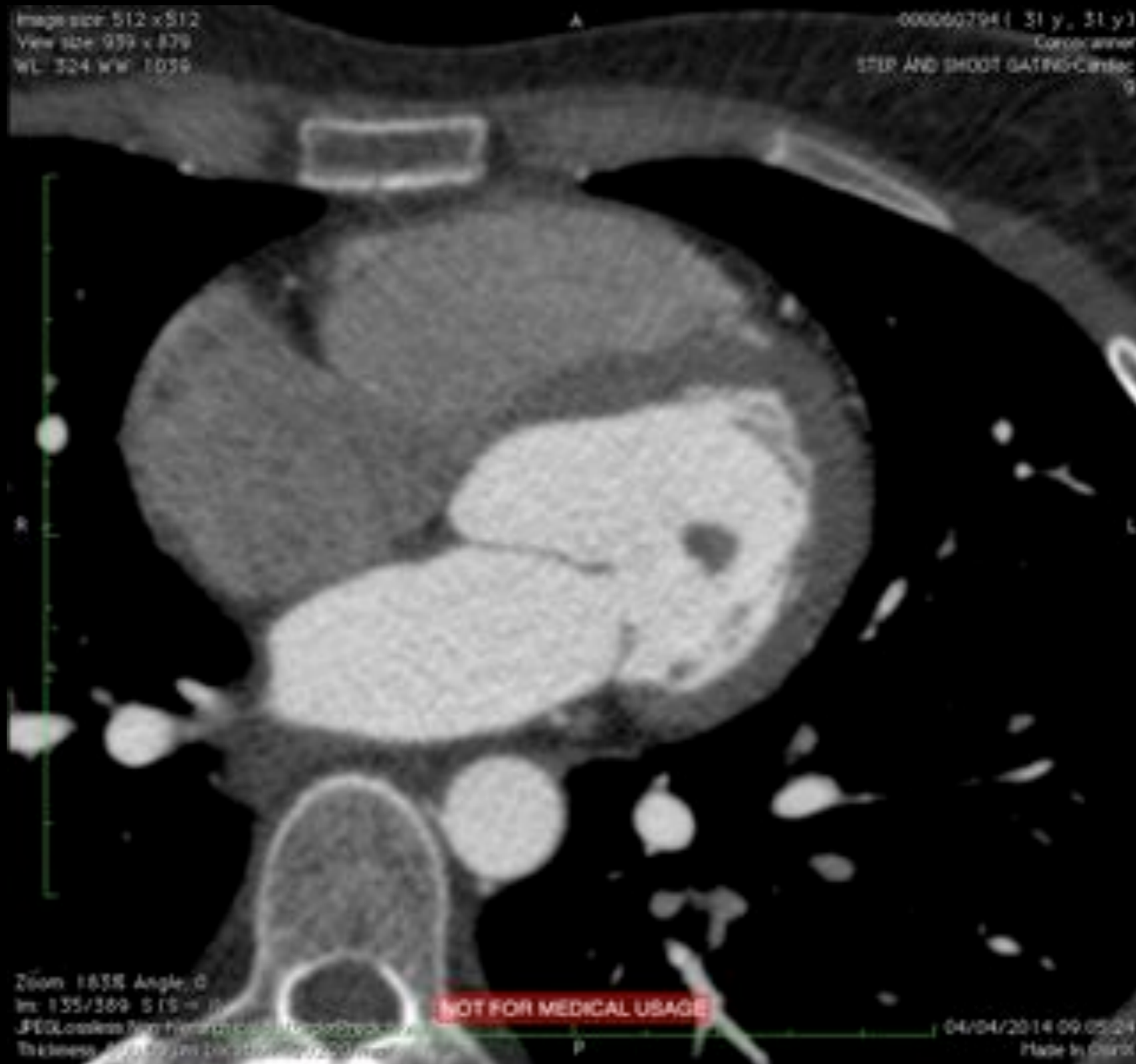Dominance gauche



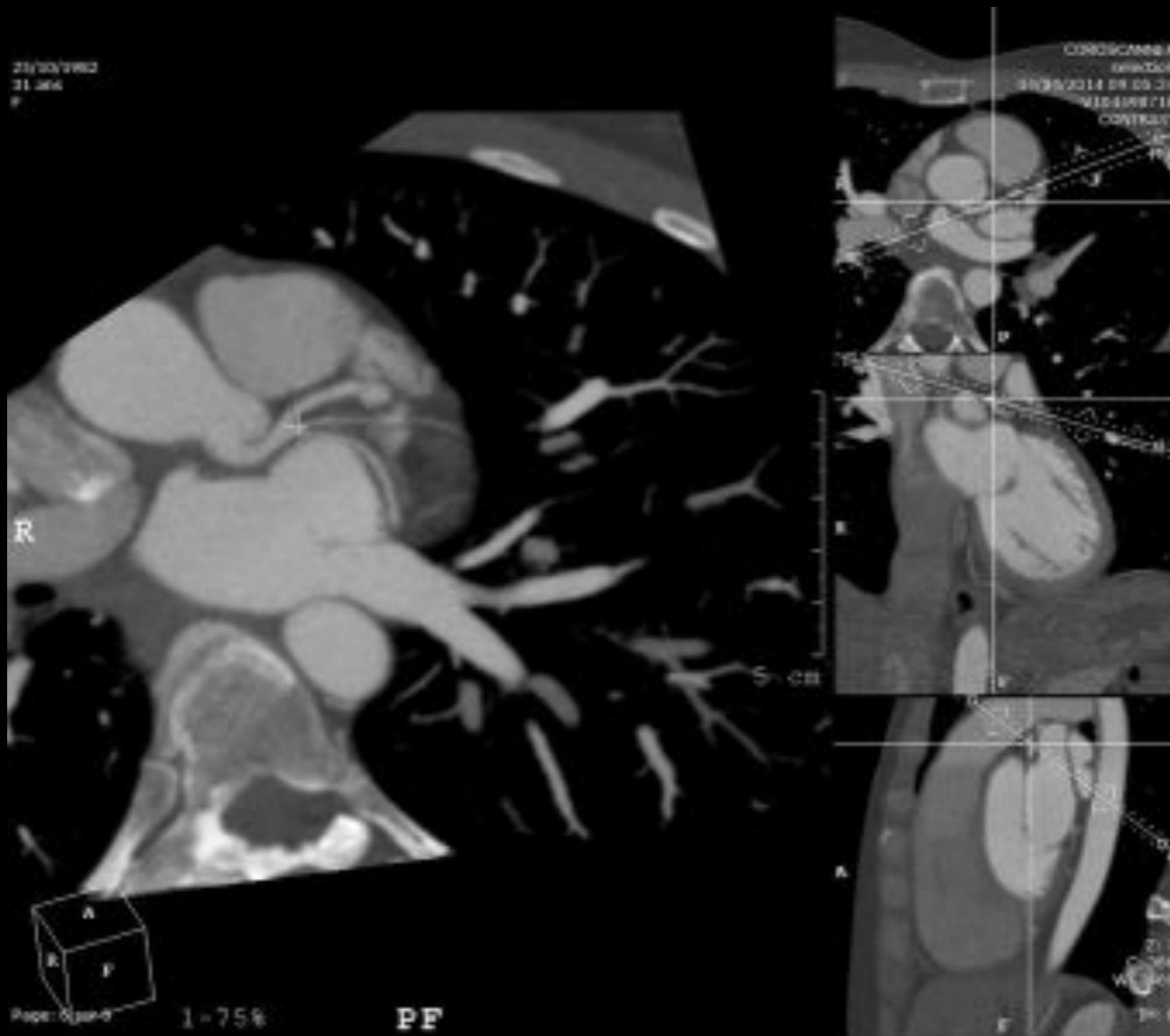
O'Brien, J. P. et al. Radiographics 2007;27:1569-1582

Radiographics

Dominance Gauche / Exemple



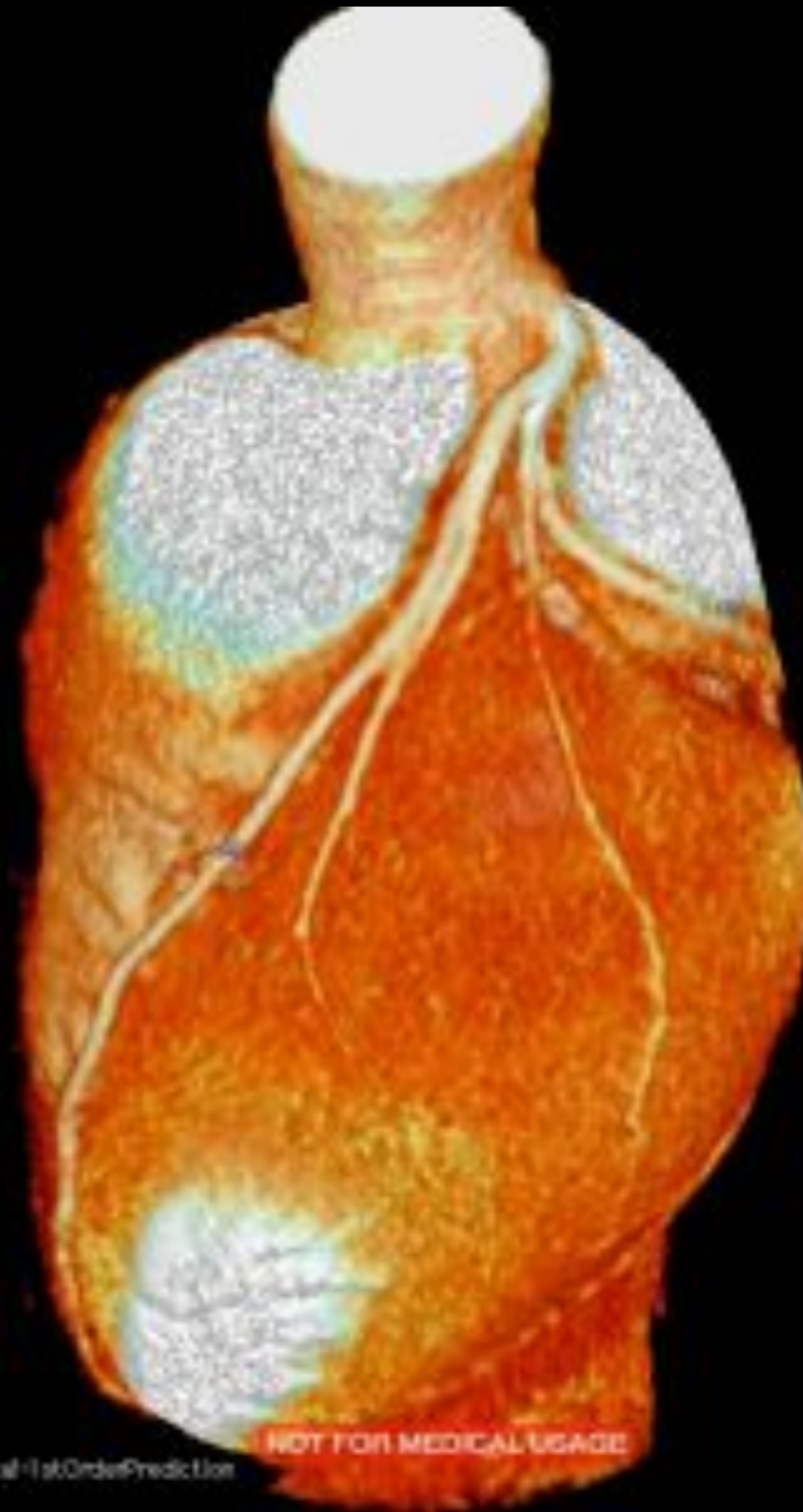
Dominance Gauche / Exemple



Dominance Gauche / Exemple

STEP AND SHOOT (A)TINDC (P)P
DC

STEP AND SHOOT (A)TINDC (P)P
DC

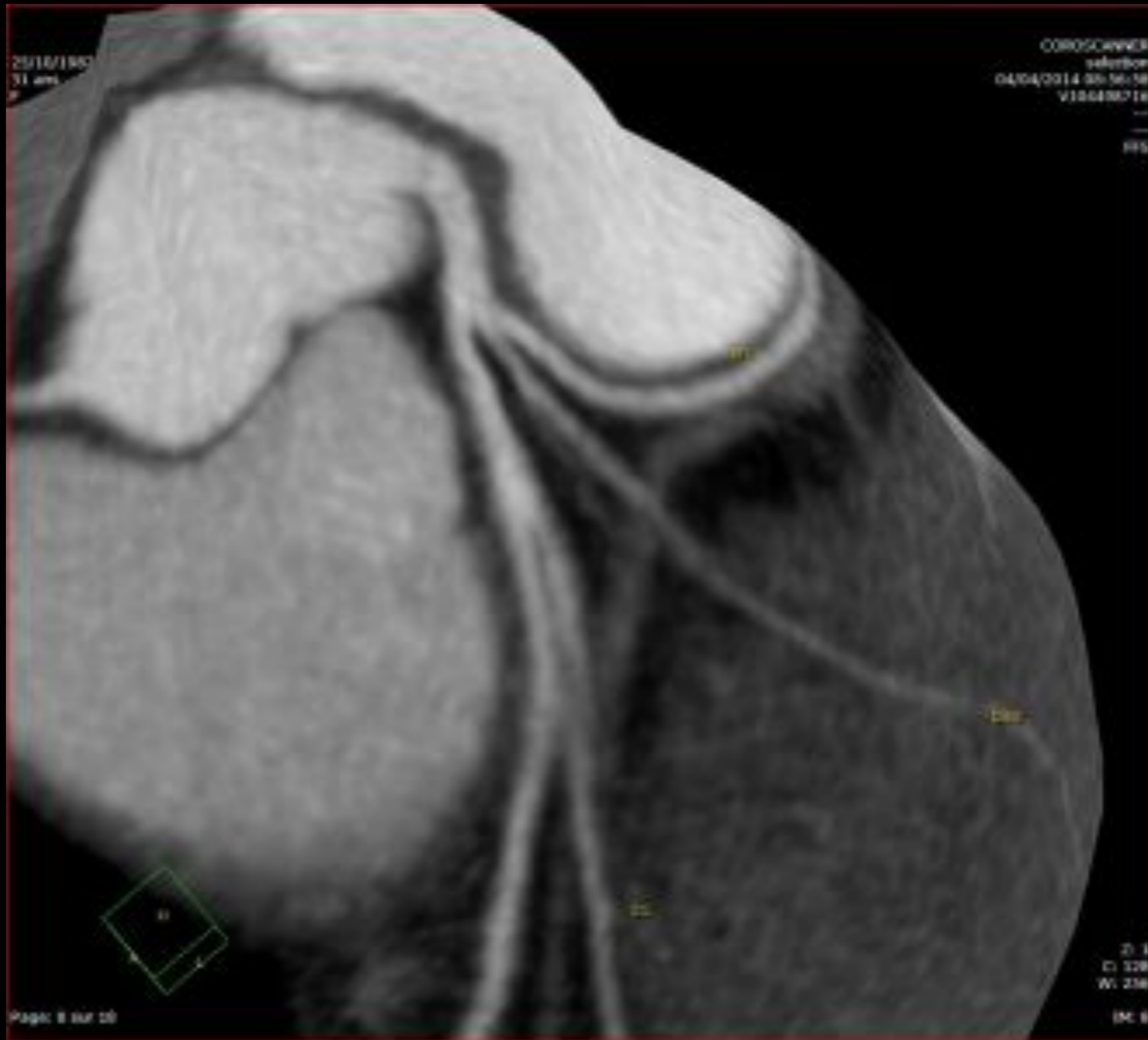

Zoom: 46% Angle: 0
In: 1/5
JPEG Lossless Non-hierarchical FlatOrder Prediction
Position: FFs

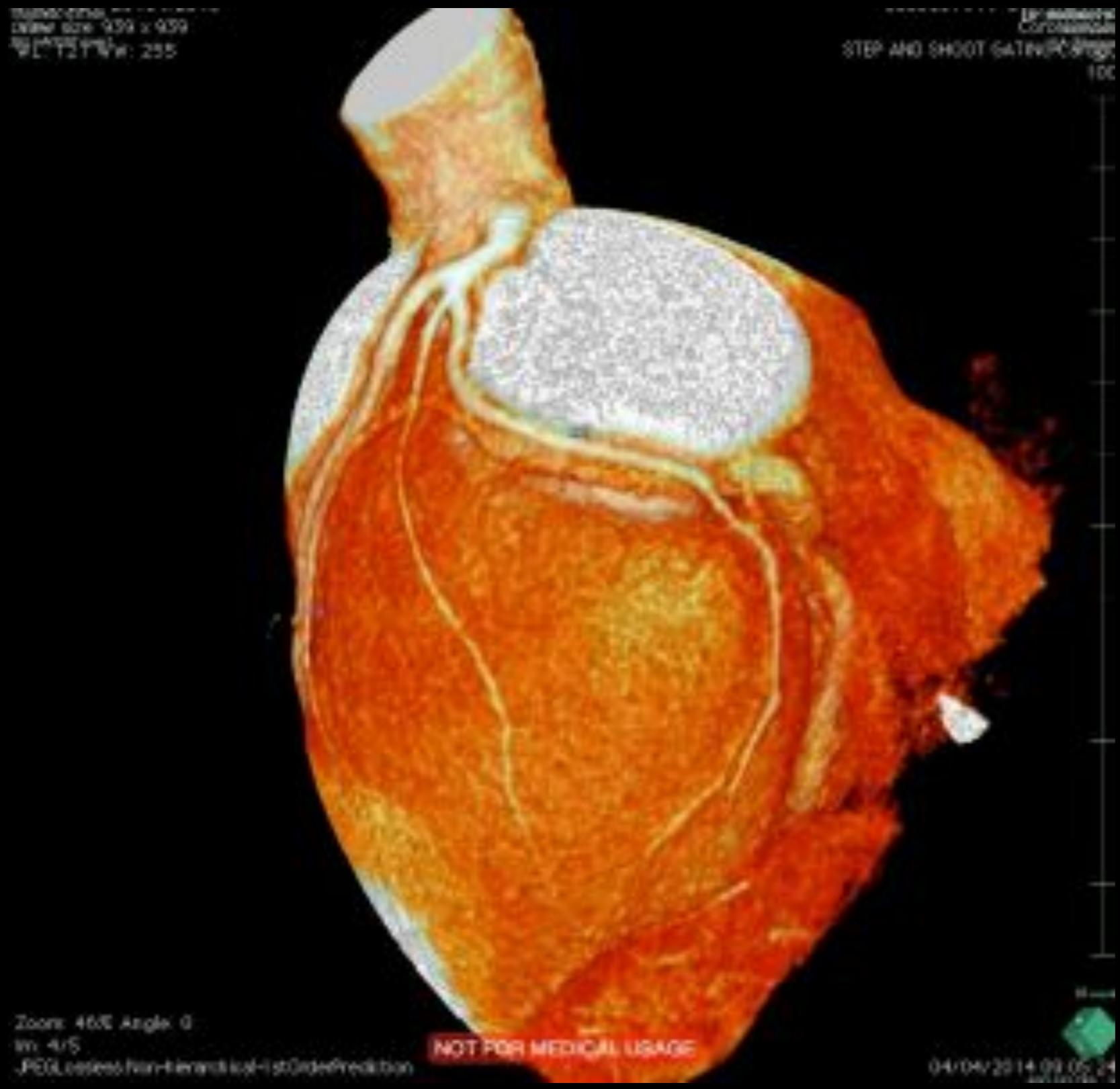NOT FOR MEDICAL USAGE

04/04/2014 09:05:24
Hed93600000

Dominance Gauche / Exemple



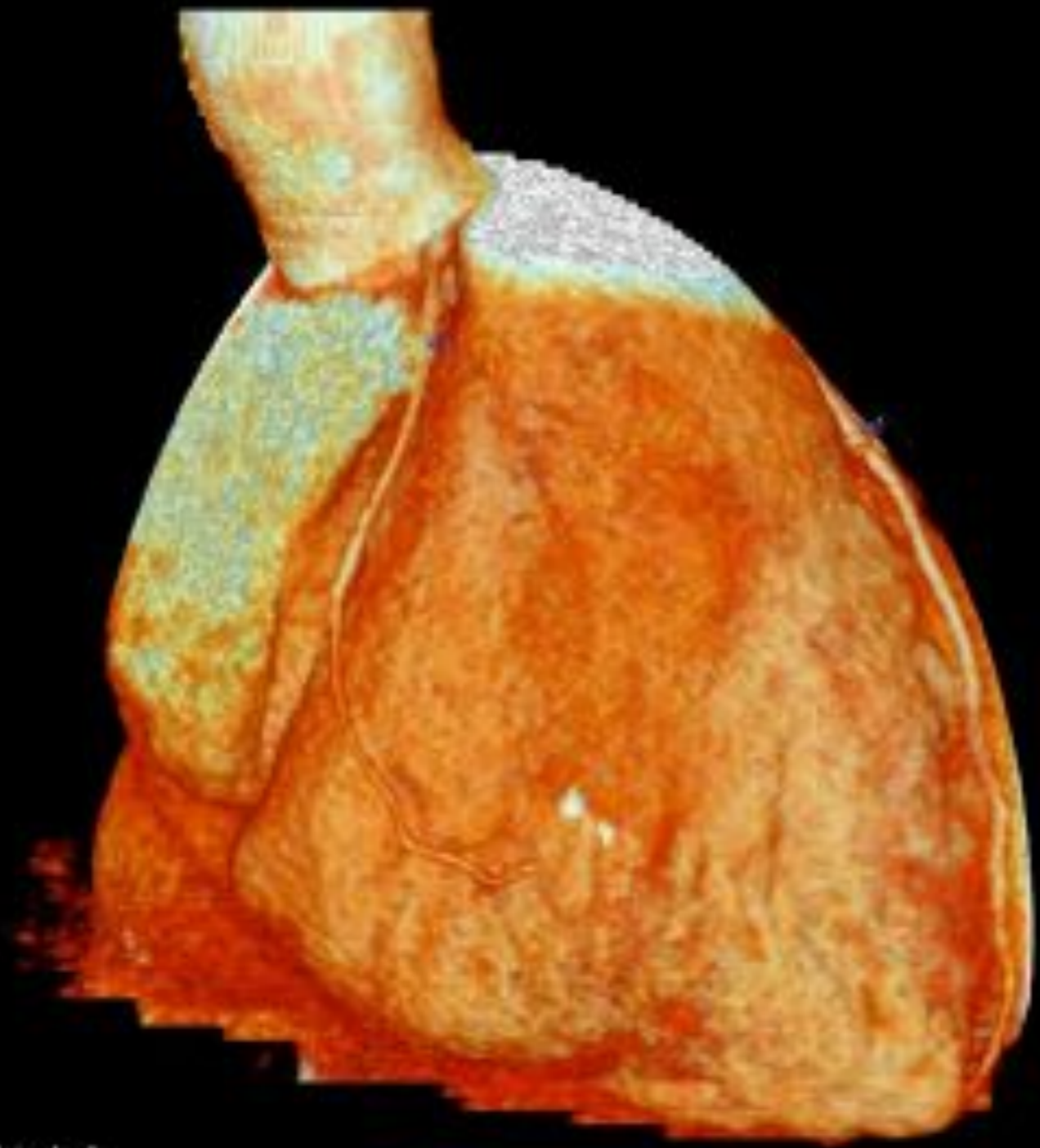Dominance Gauche / Exemple



Dominance Gauche / Exemple

Transverse
Image size: 939 x 939
Pixel size: 255

STEP AND SHOOT GATING
100



Zoom: 46% Angle: 0
Im: 5/5
JPEGLosslessNon-hierarchical-TabOrderPrediction

NOT FOR MEDICAL USAGE

04/04/2014 09:03:24

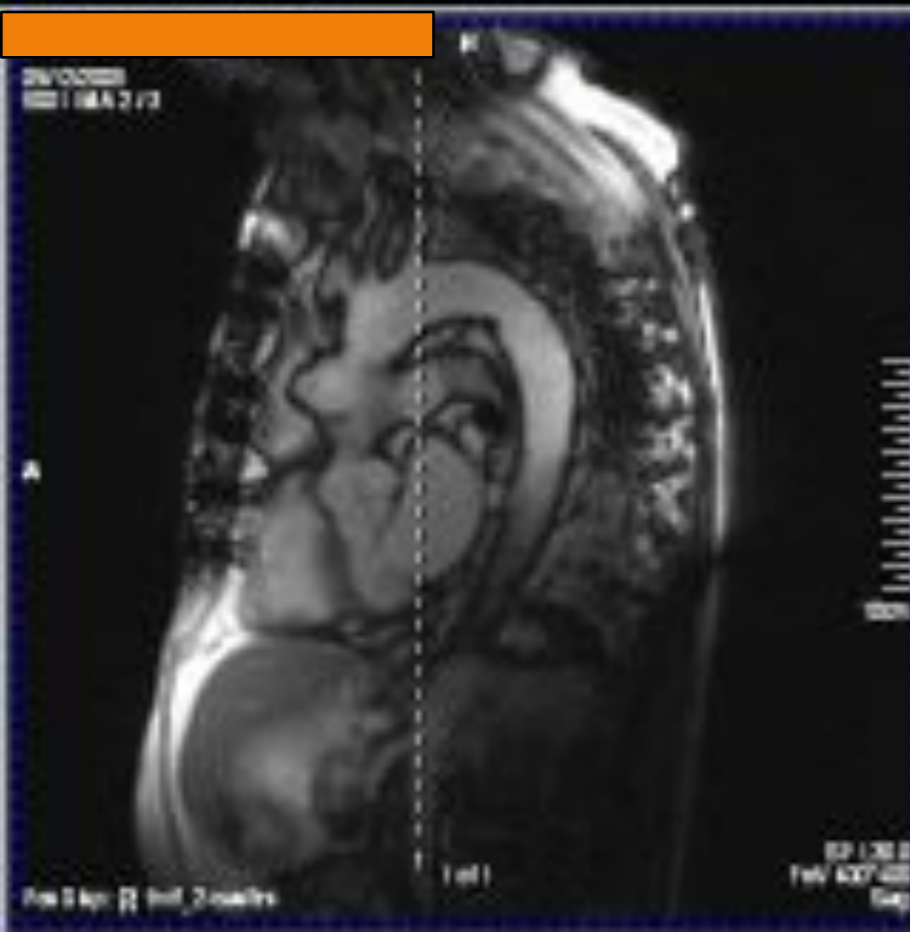
Plans de coupes
spécifiques du coeur

Plans de coupe

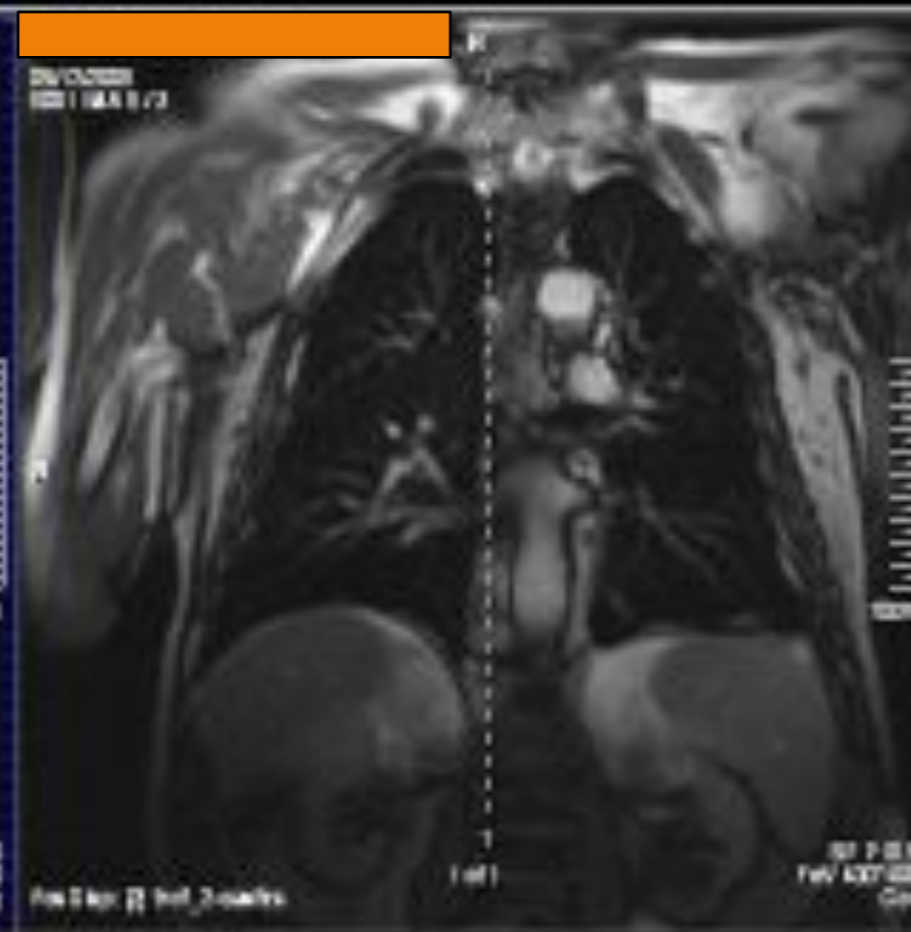
- L'analyse des images se fonde sur les plans de coupe suivants :
- 4 cavités
- Grand axe VG
- Petit axe VG

Localisateur de démarrage

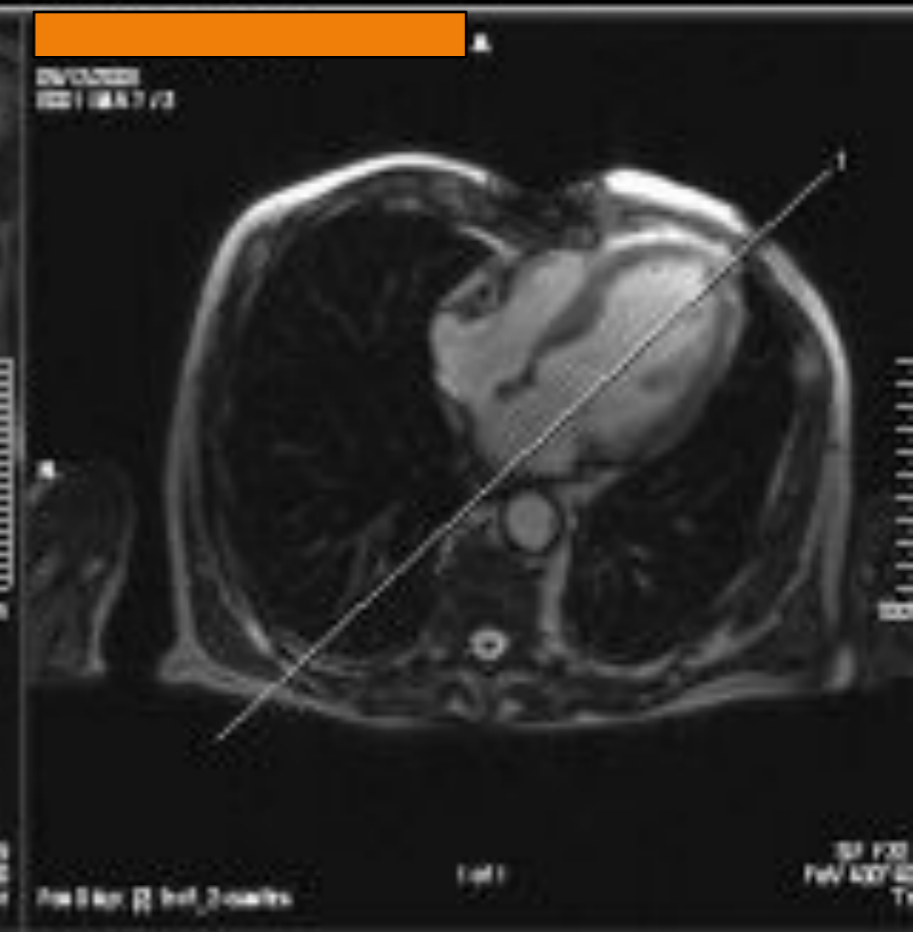
Coupes strictes



SAGITTALE



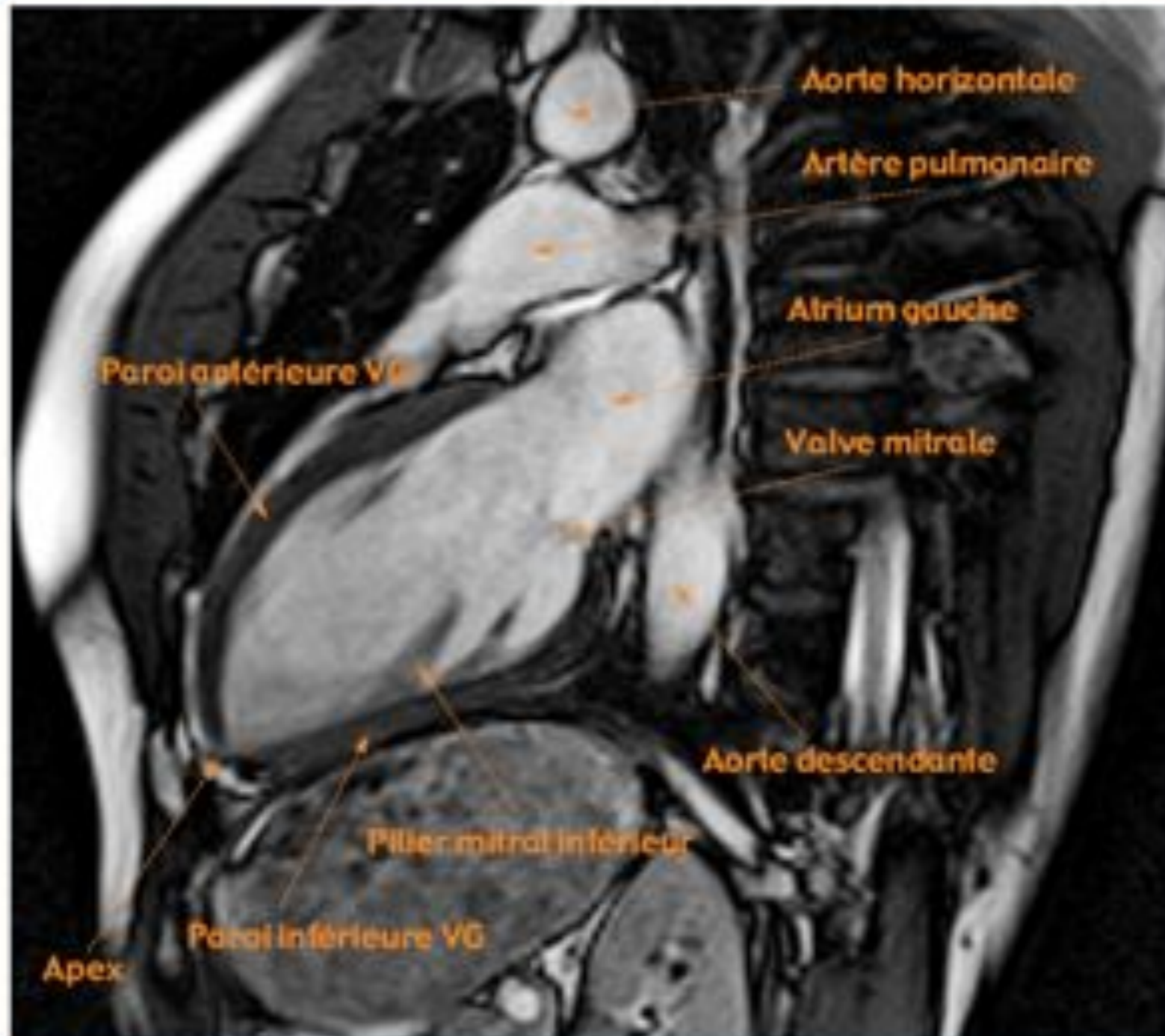CORONALE



AXIALE

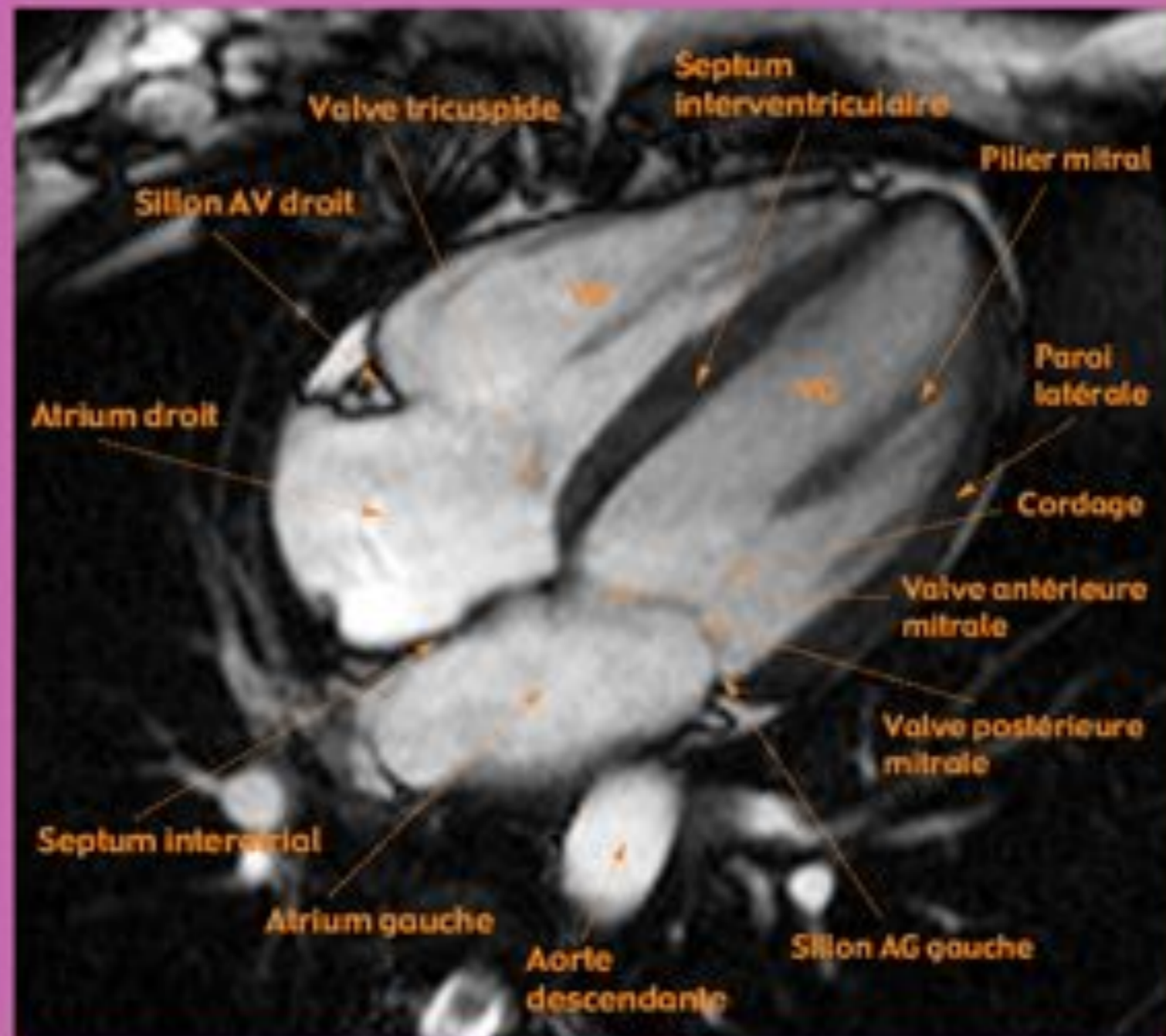
ANATOMIE

Long axe VG 2 cavités

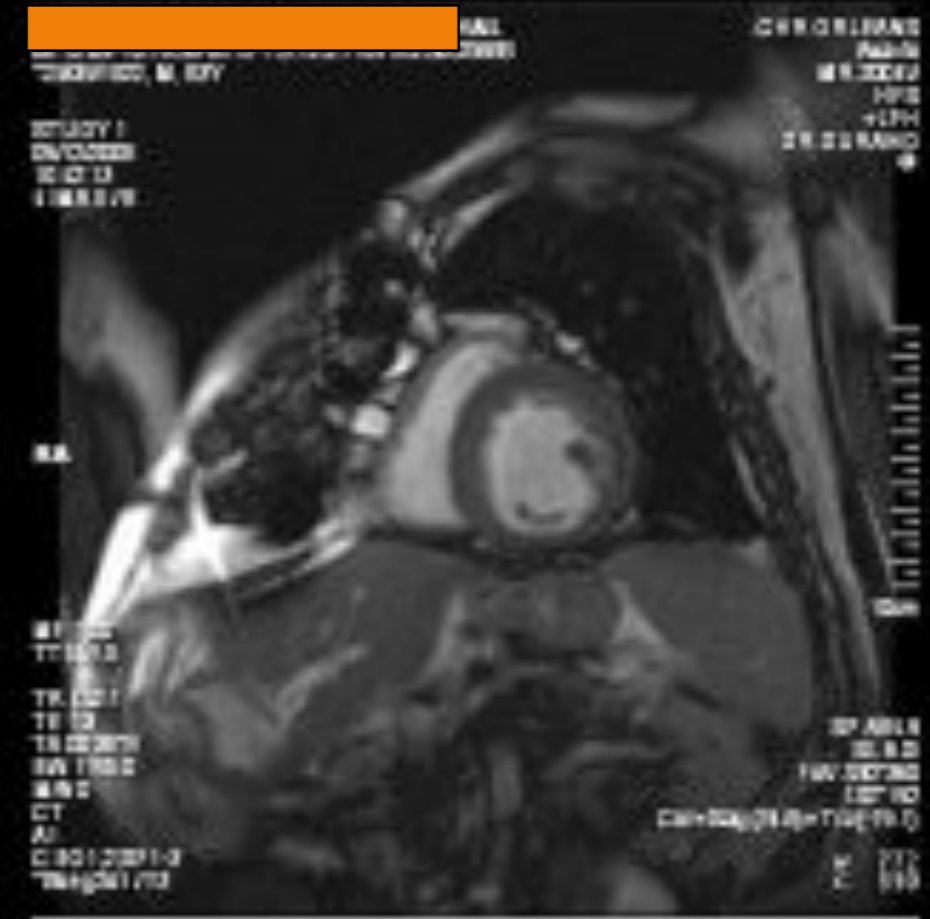
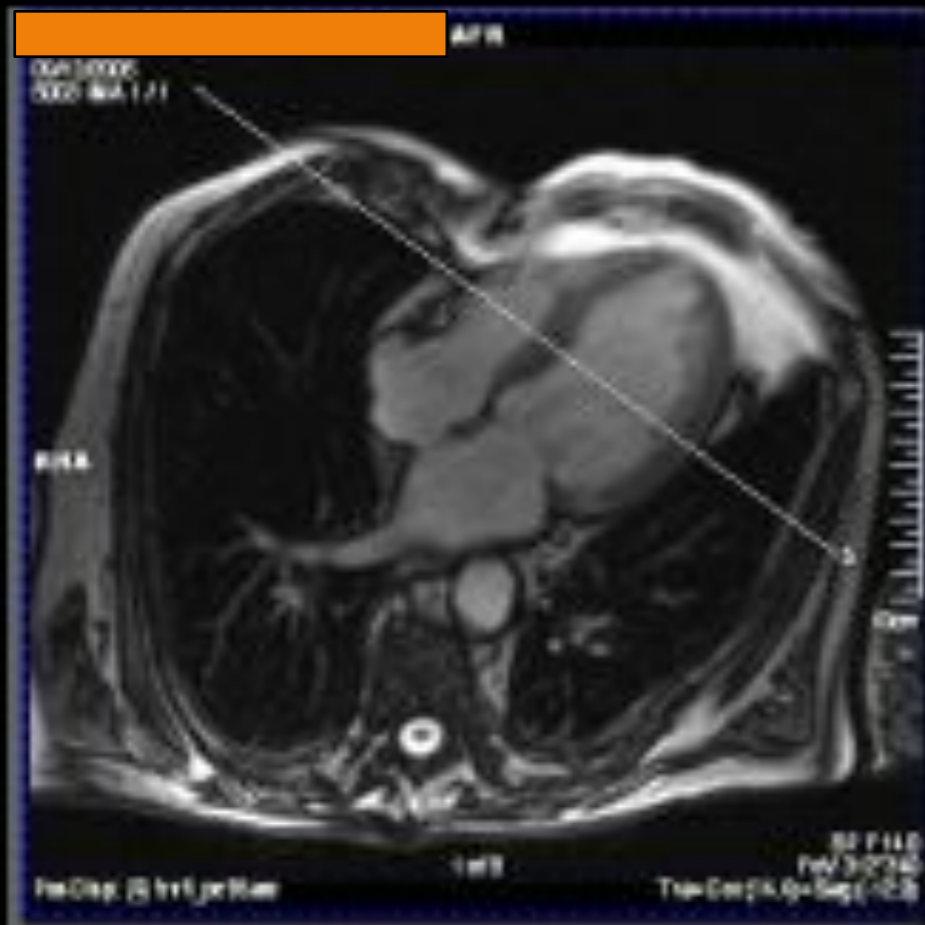
ANATOMIE

Long axe 4 cavités



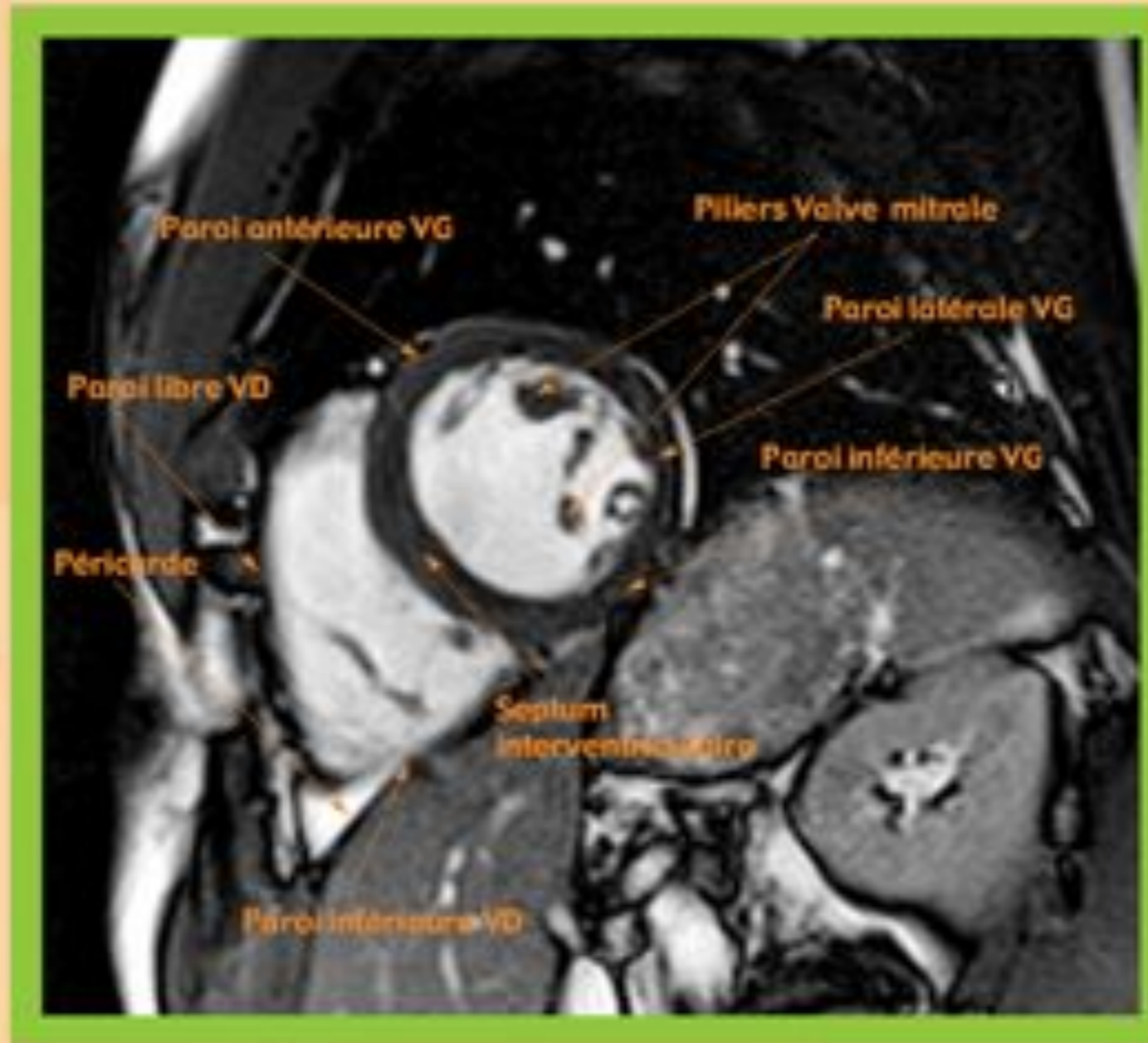
Grand axe Pseudo 4 cavités → Petit axe



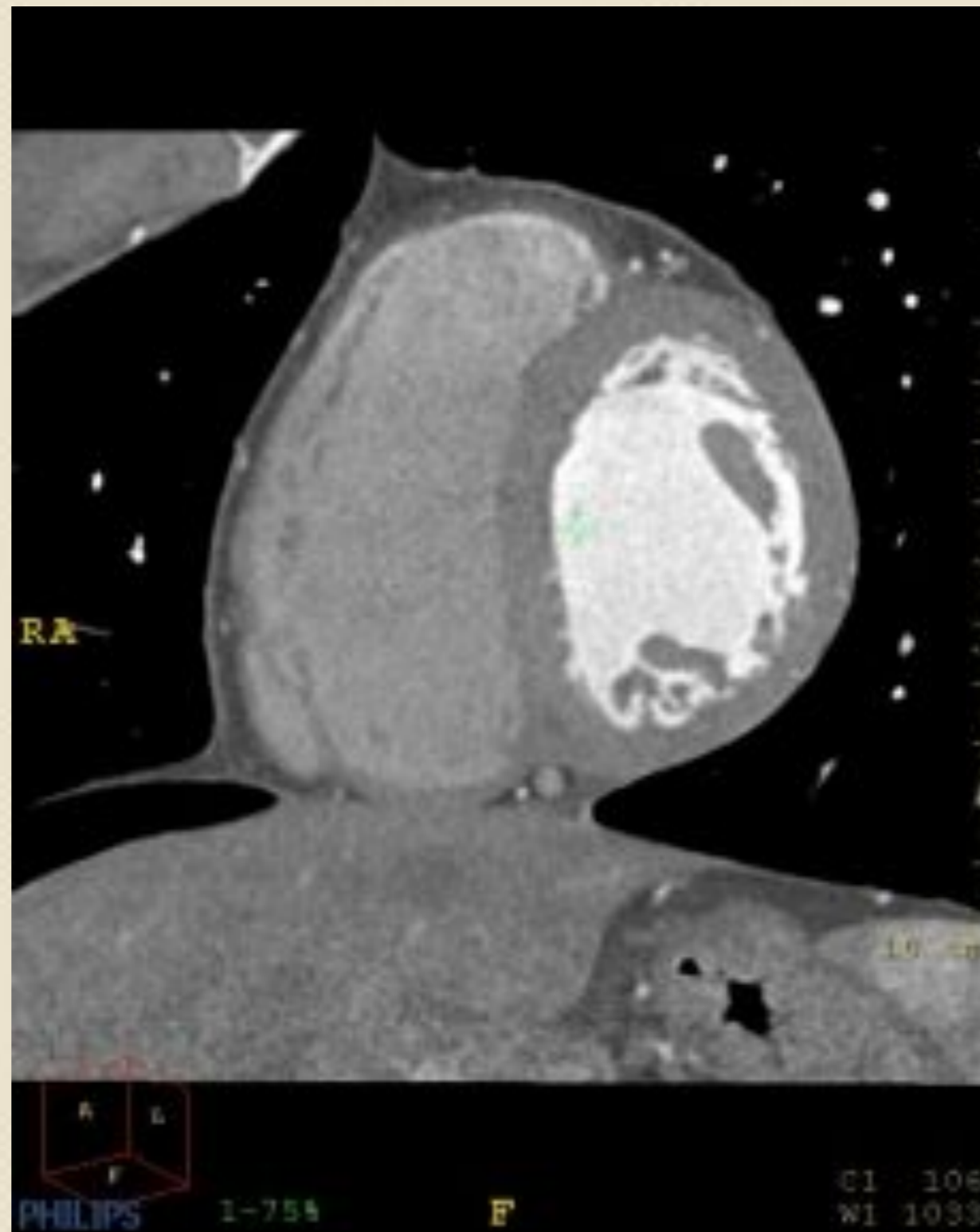
Coupe perpendiculaire à la bissectrice apex/mitral
Permet de calculer la fraction d'éjection

ANATOMIE

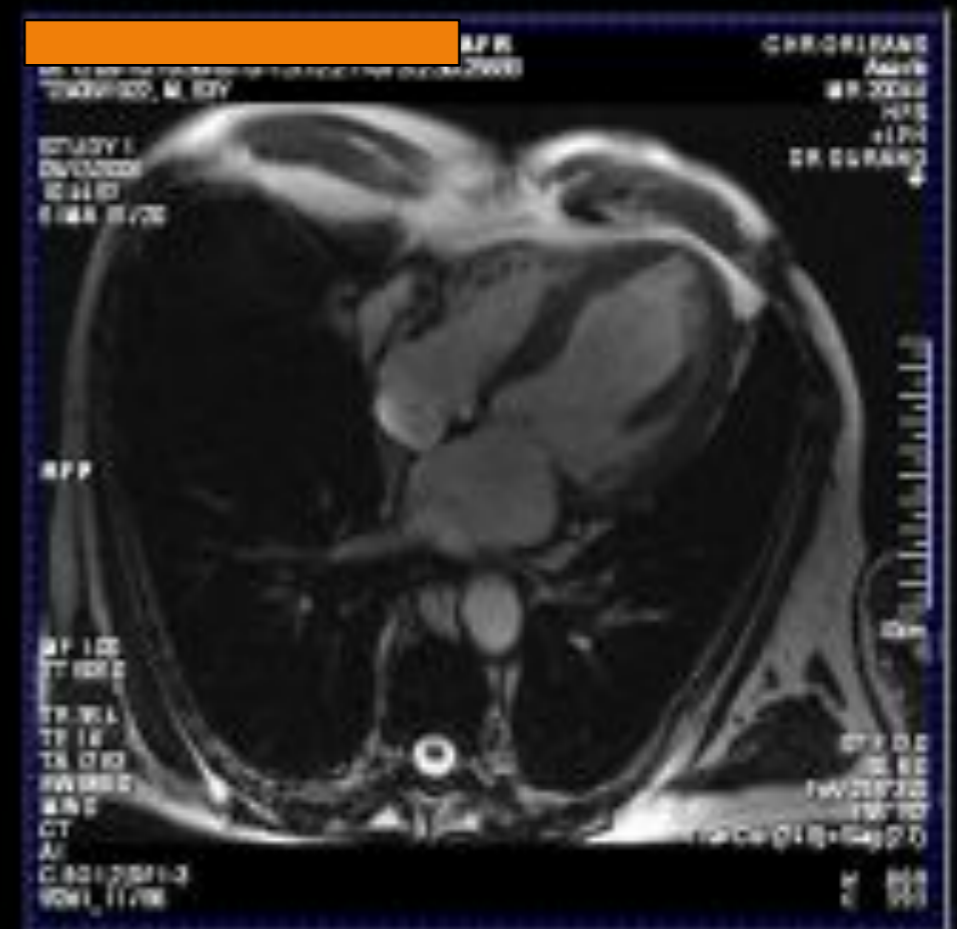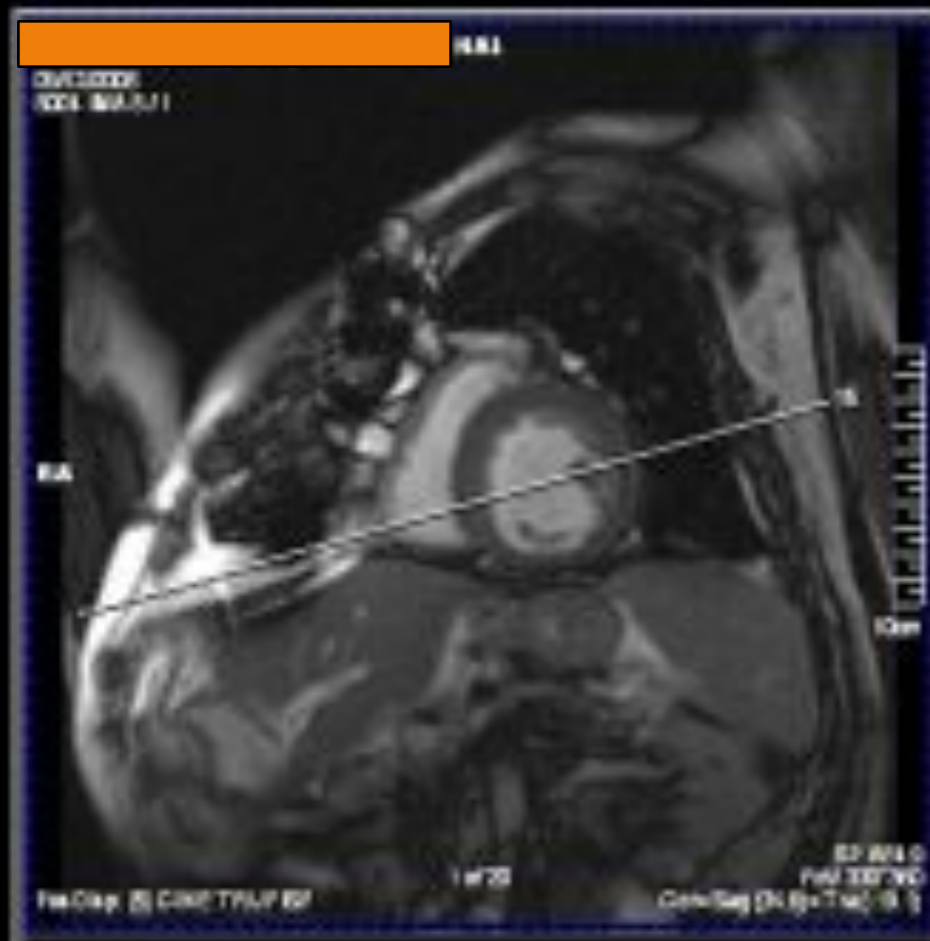
Petit axe ventriculaire



Coupe Petit Axe

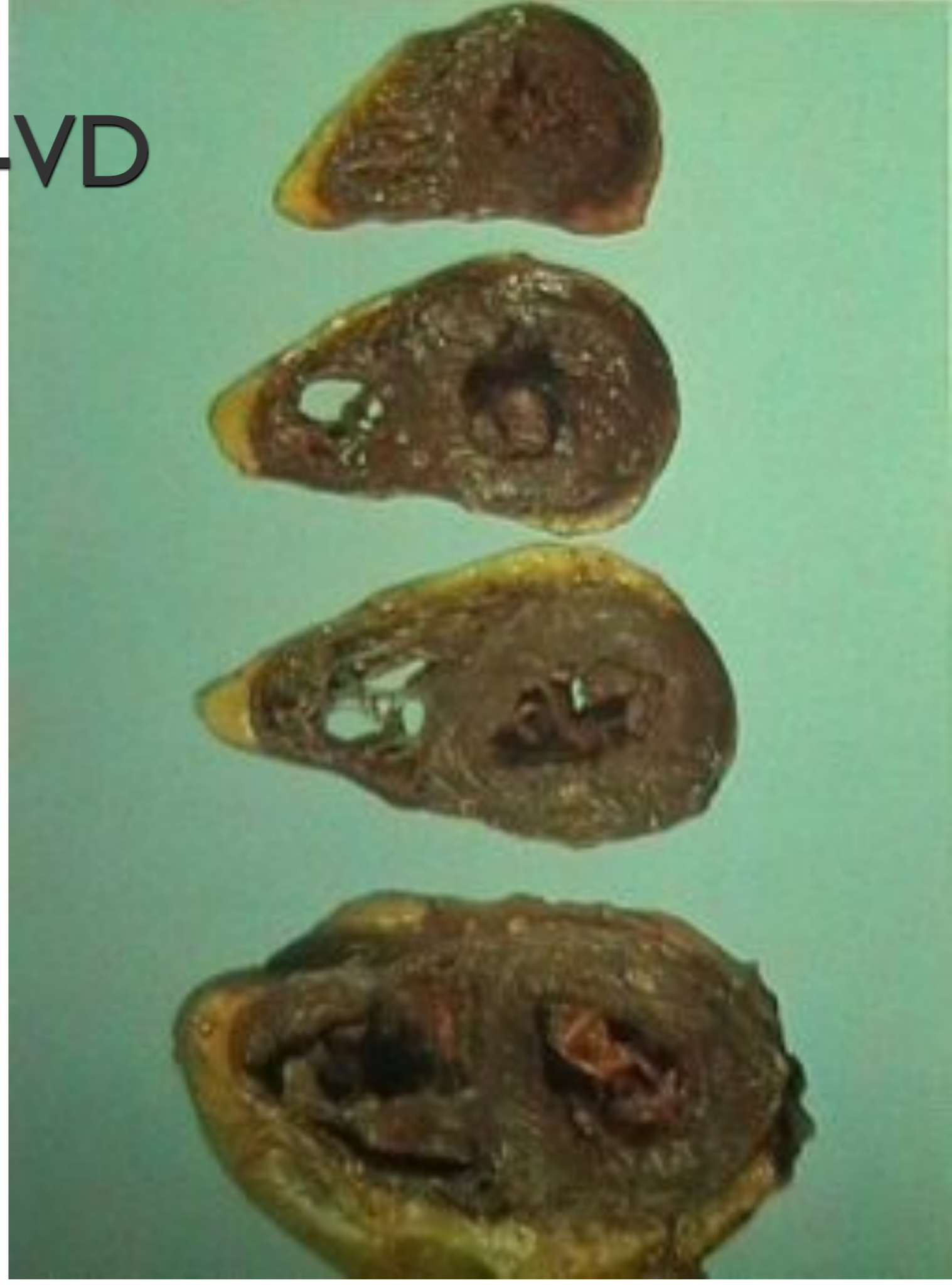


Petit axe → Grand axe 4 cavités **Strict**

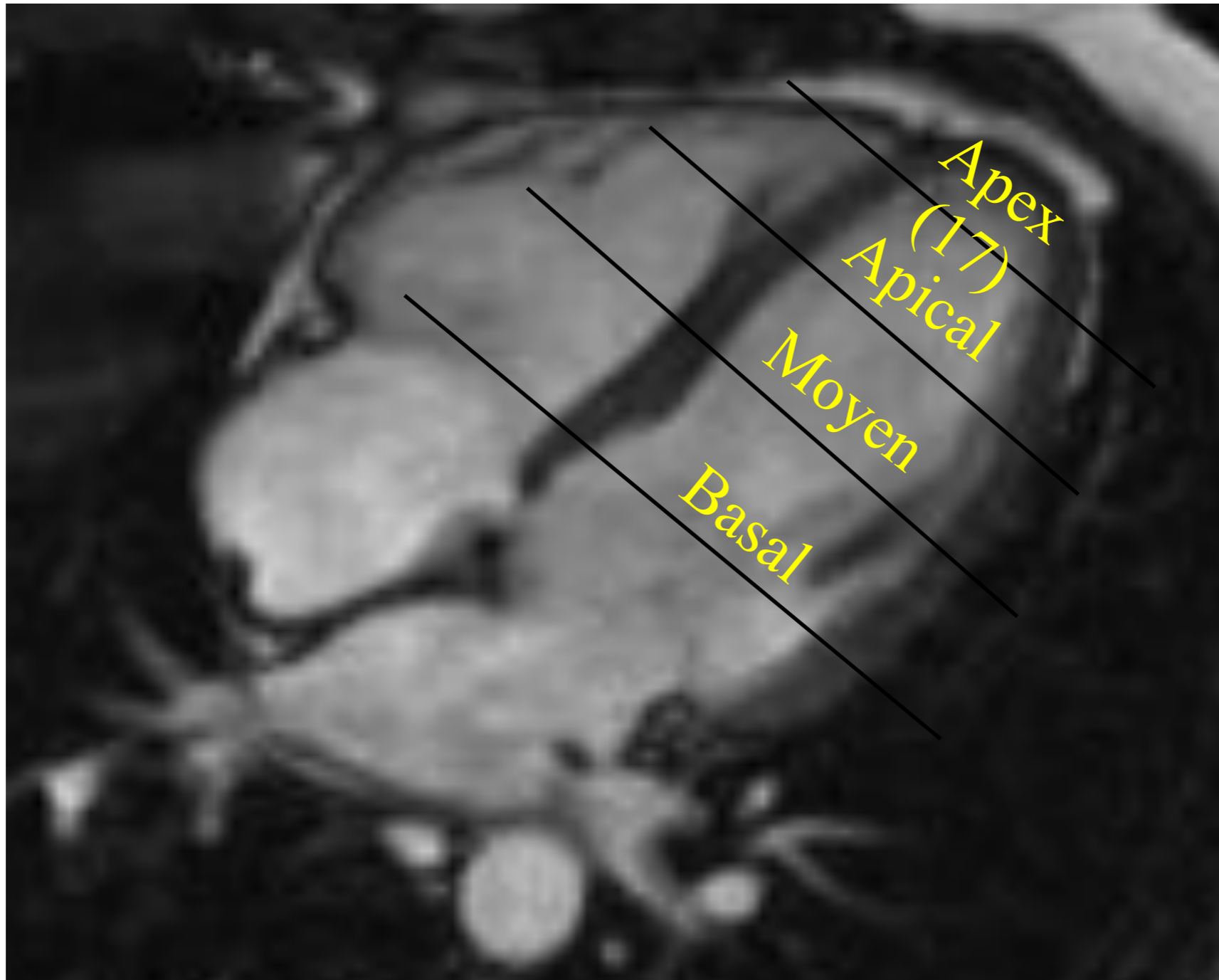


Petit Axe VG-VD


- VG = pneu
- VD =
trabéculations



Segmentation du Ventricule gauche



Segmentation du Ventricule gauche



1,7 anterieur

2,8 anteroseptal

3,9 inferoseptal

4,10 inferieur

5,11 inferolateral

6,12 anterolateral

13 anterieur

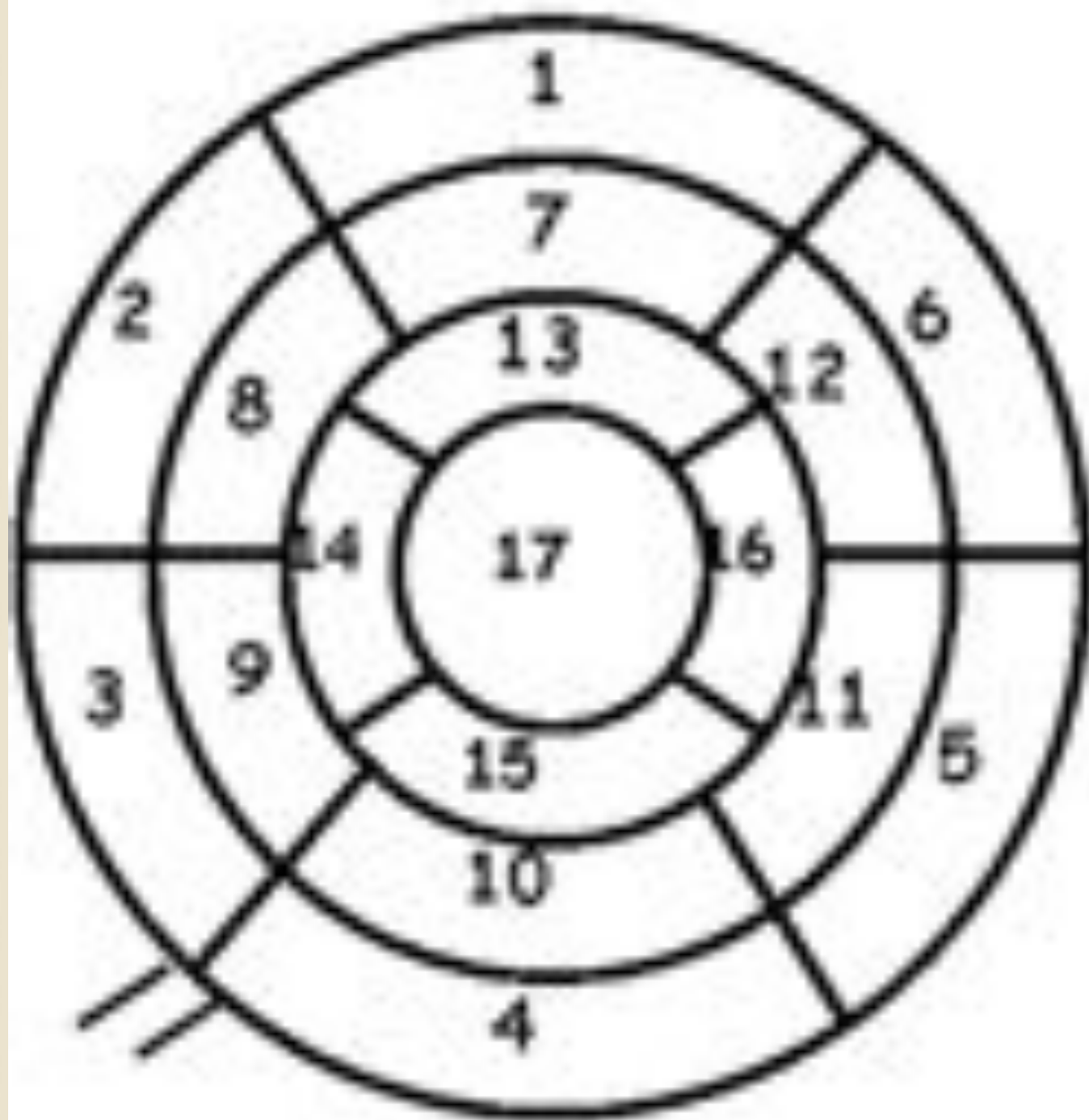
14 septal

15 inferieur

16 lateral

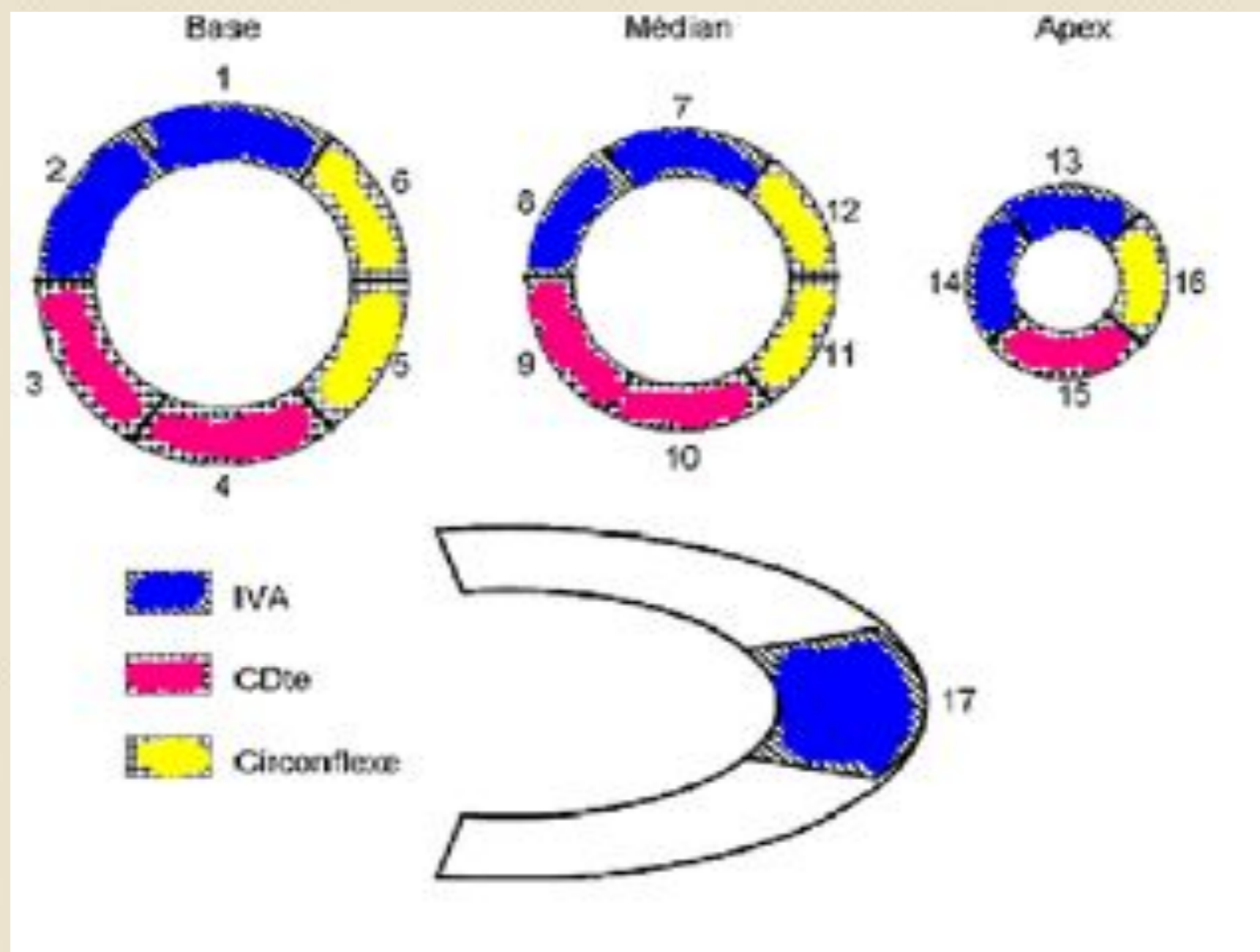
(17 apex)

SEGMENTATION DU CŒUR

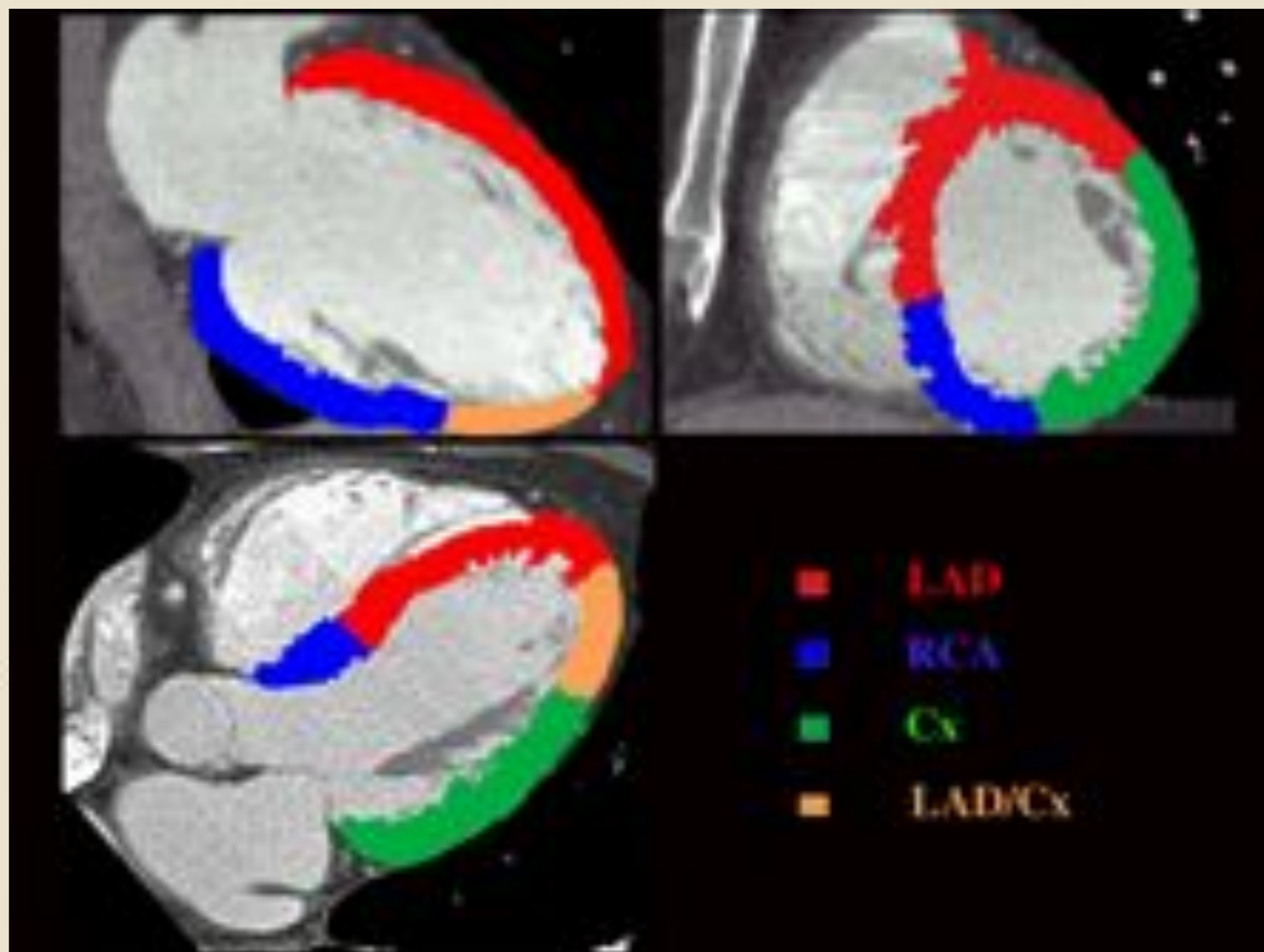


1. Antéro-basal
2. Antérosepto-basal
3. Inférosepto-basal
4. Inféro-basal
5. Inférolatéro-basal
6. Antérolatéro-basal
7. Antéro-médial
8. Antérosepto-médial
9. Inférosepto-médial
10. Inféro-médial
11. Inférolatéro-médial
12. Antérolatéro-médial
13. Antéro-apical
14. Septo-apical
15. Inféro-apical
16. Latéro-apical
17. Apex

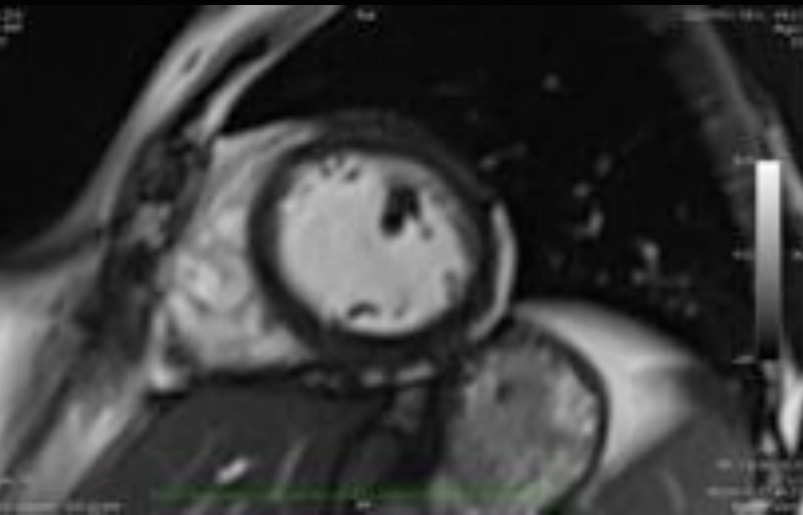
SEGMENTATION DU VENTRICULE GAUCHE



TERRITOIRES CORONAIRES



Analyse de la cinétique segmentaire



Export...

Presets

Name: Wall Motion

Add Delete

Selected Preset

Name: Wall Motion

State	Color	Score
normal		0
hypokinesia		1
akinesia		2
dyskinesia		3

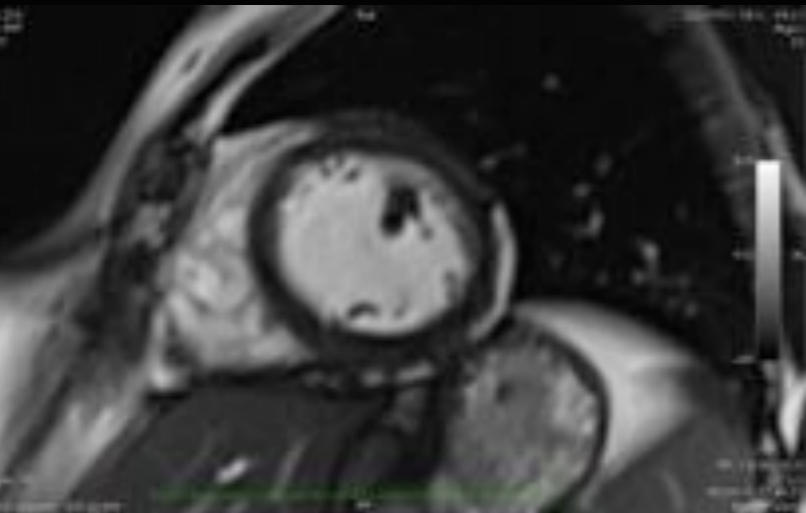
Add Delete

Decorations

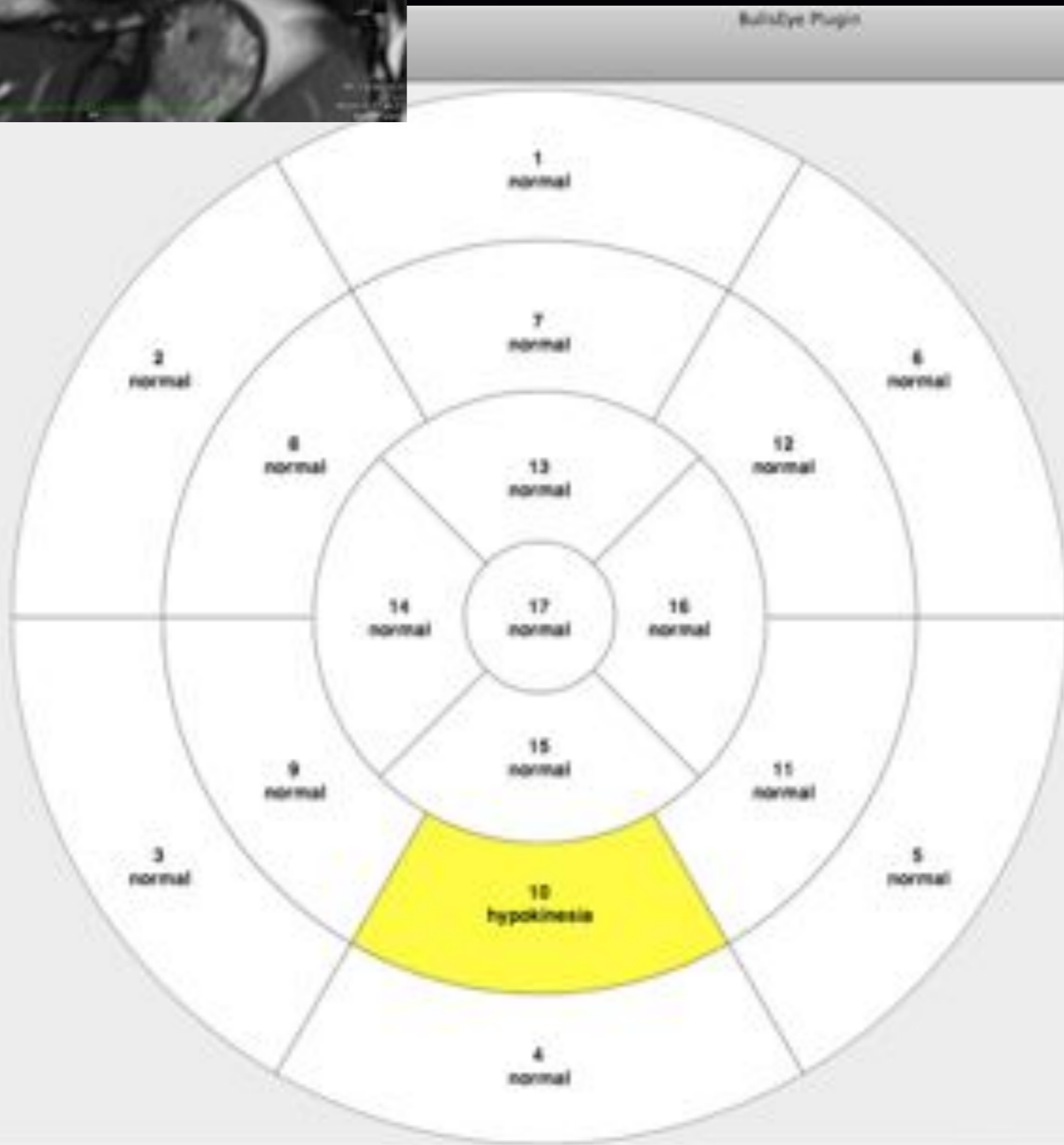
- Segments Number
- Segments State Text
- Segment ID
- Segments Size
- Score Sum

Coronary Arterial Distribution

1 LAD
2 LAD
3 LAD
4 LAD
5 LAD
6 LAD
7 LAD
8 LAD
9 LAD
10 LAD
11 LAD
12 LAD
13 LAD
14 LAD
15 LCA
16 LCA
17 LCA



Analyse de la cinétique segmentaire



Bullseye Plugin [Export...]

Presets
Name: Bullseye [v] [Add] [Delete]

Selected Preset
Name: Bullseye

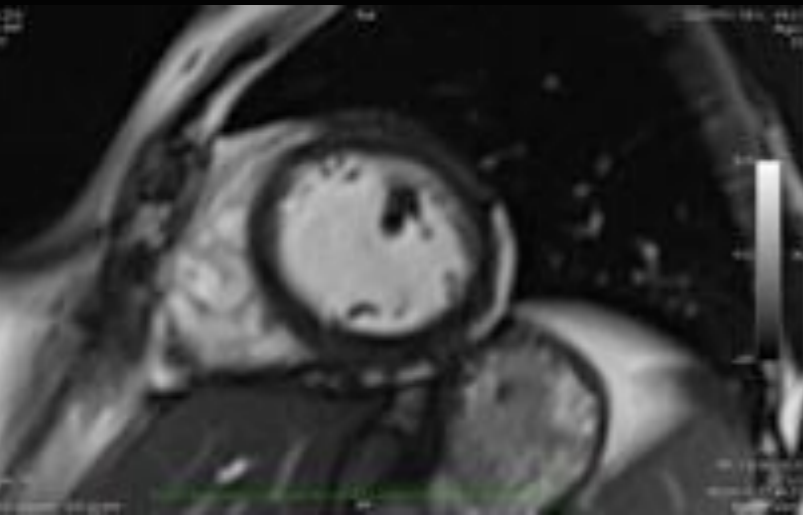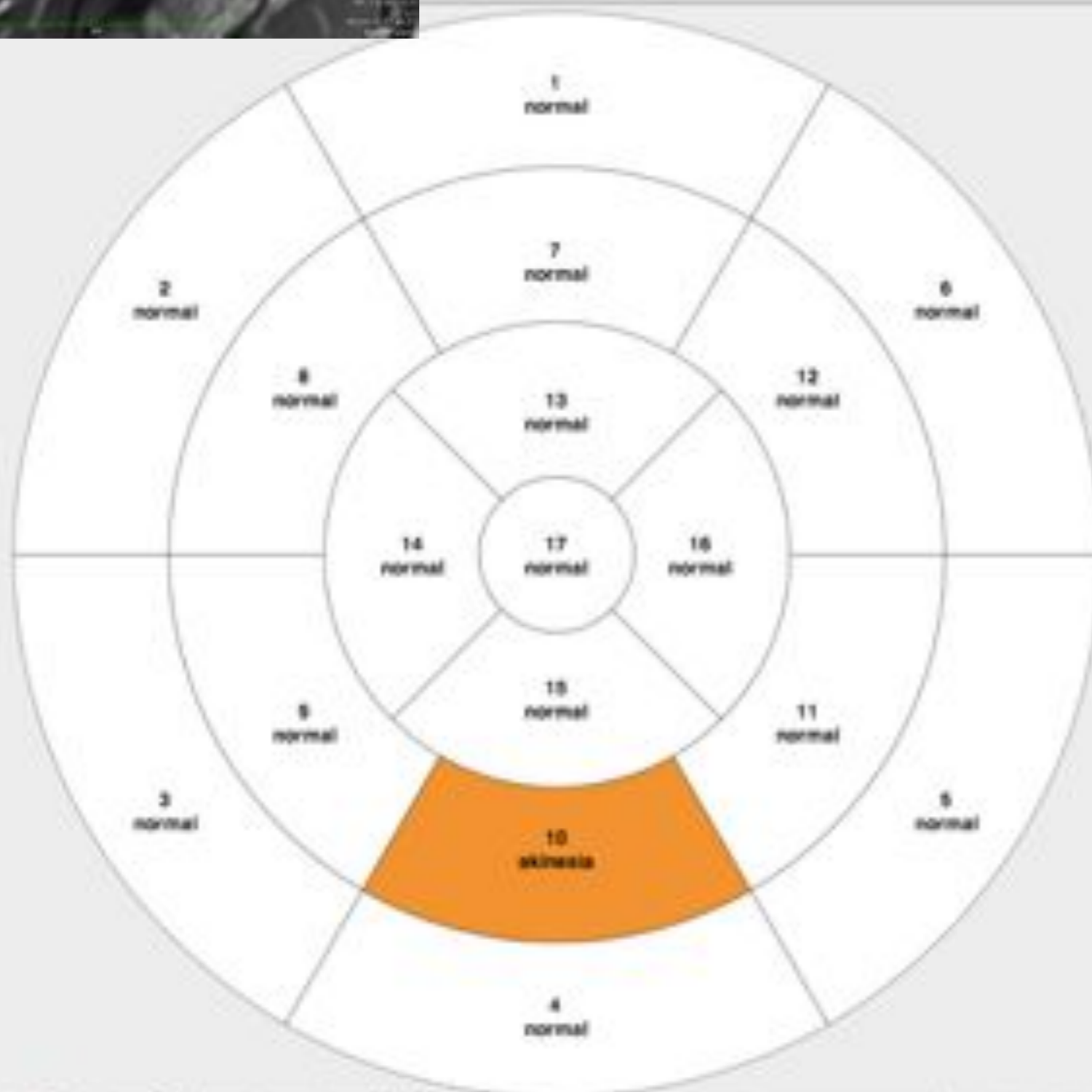
Status	Color	Score
normal	[White]	0
hypokinesia	[Yellow]	1
akinesia	[Orange]	2
dyskinesia	[Red]	3

[Add] [Delete]

Decorations
 Segments Number
 Segments State Text
 Segment ID
 Segments Score Score Sum

Coronary Arterial Distribution

Analyse de la cinétique segmentaire



Export...

Presets

Name: Wall Motion

Selected Preset

Name: Wall Motion

State	Color	Score
normal		0
hypokinesia		1
akinesia		2
dyskinesia		3

Decorations

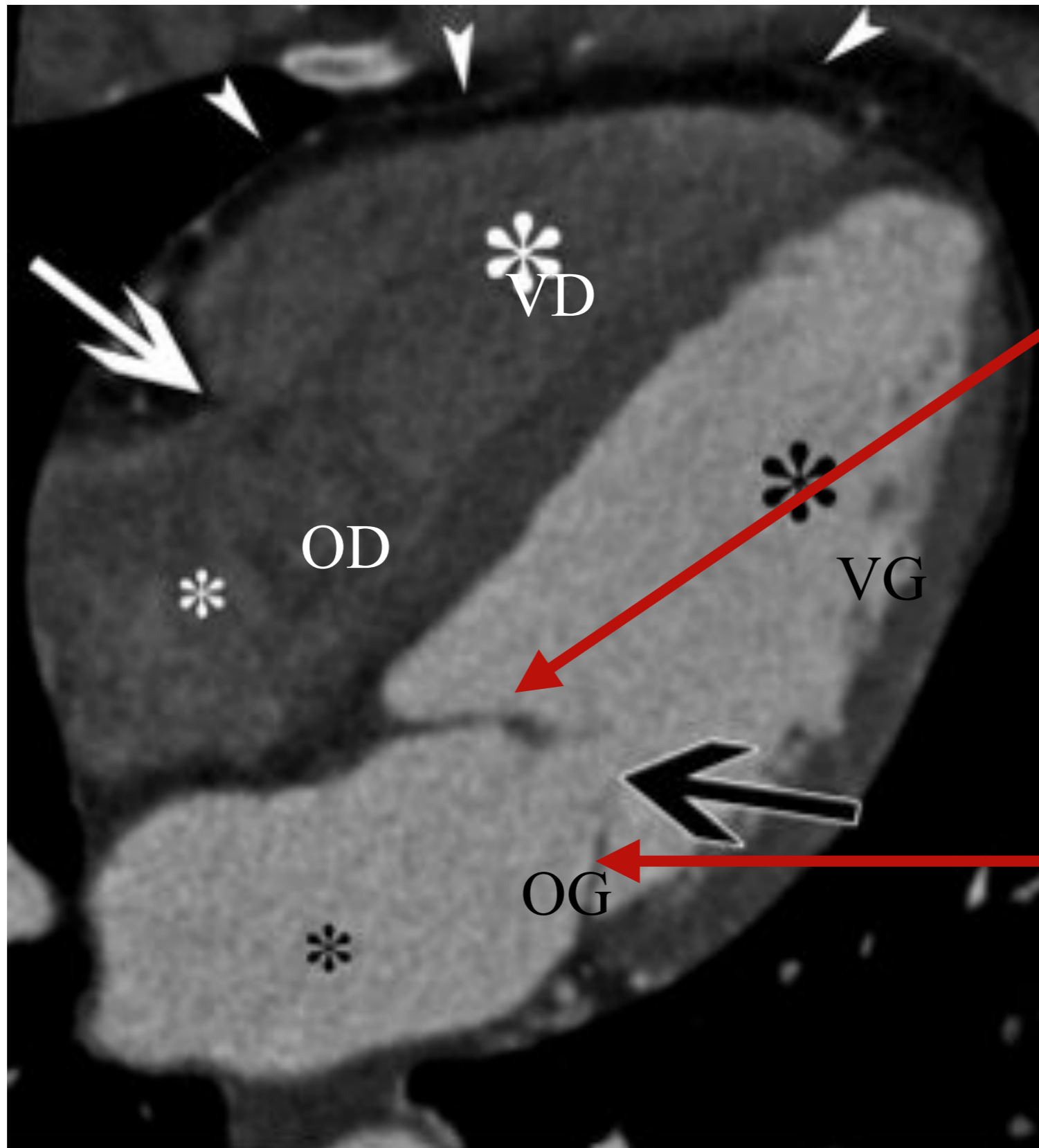
- Segments Number
- Segments Size Text
- Segment 17
- Segments Score
- Score Text

Coronary Arterial Distribution

Diagram illustrating the Coronary Arterial Distribution across the 17 segments:

- Segments 1-9: LAD (Yellow)
- Segments 10-12: RCA (Green)
- Segments 13-17: LCC (Red)

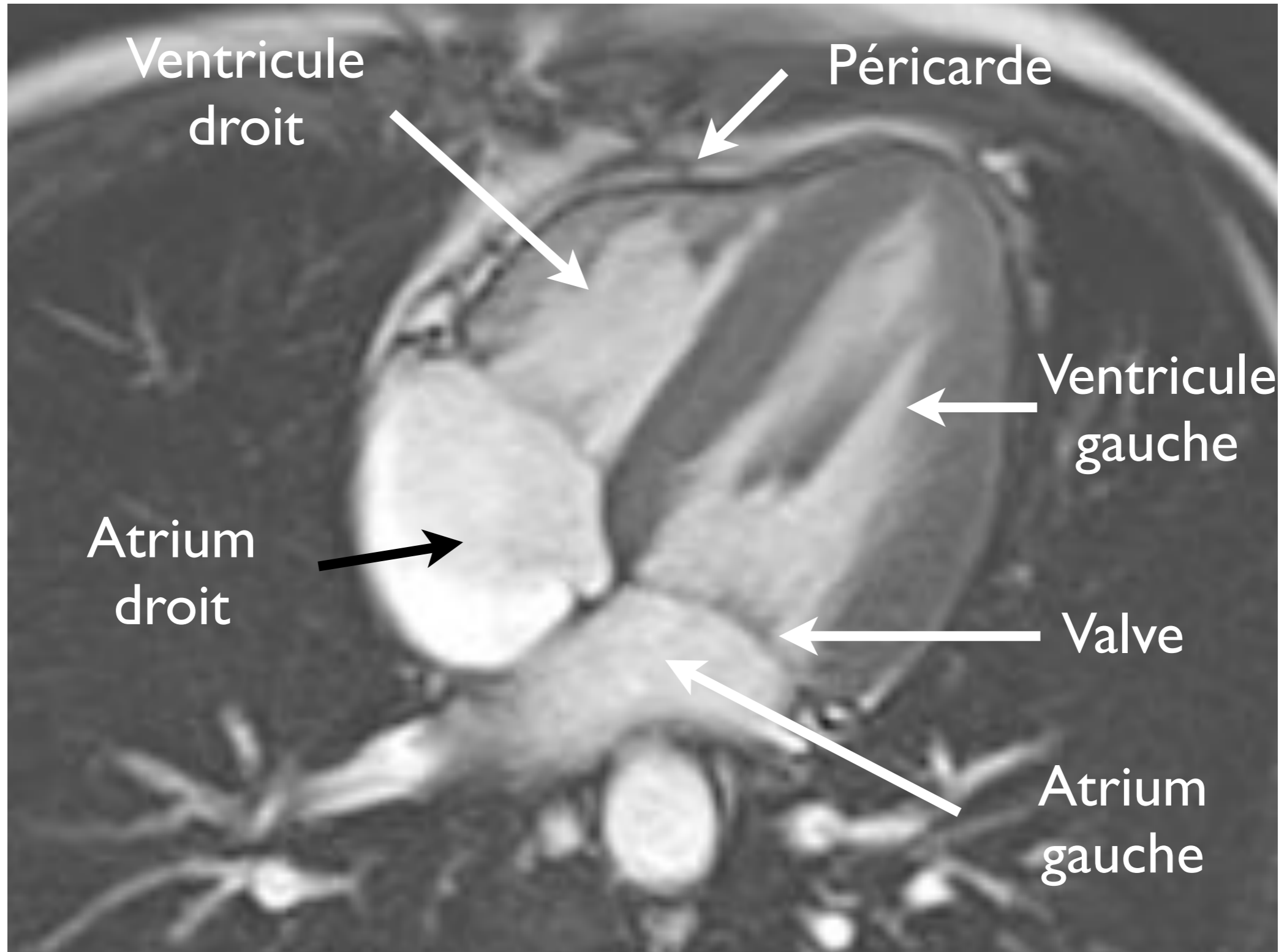
Péricarde



Feuillet
antérieur de la
valve mitrale

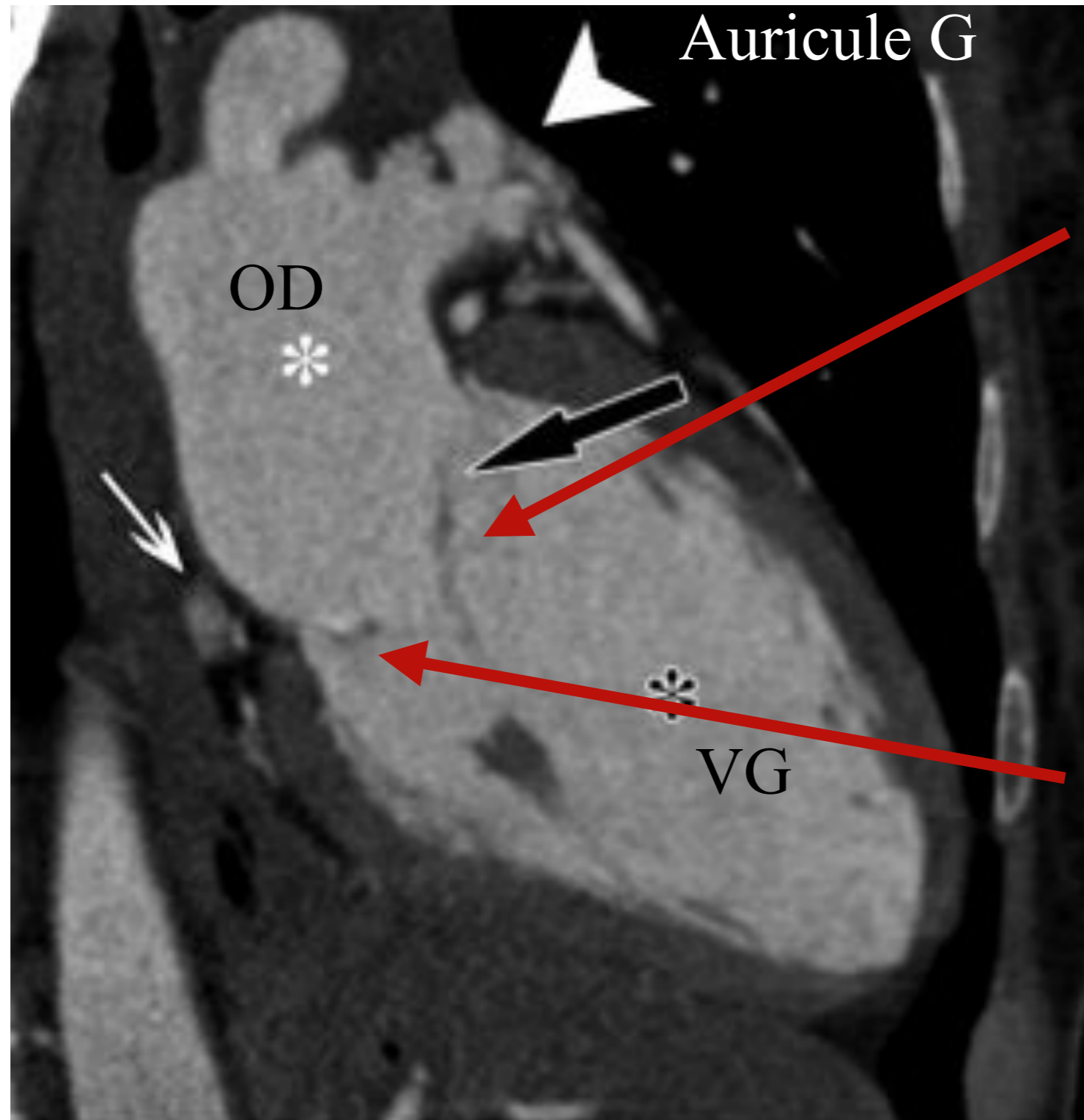
Feuillet
postérieur de
la valve mitrale

IRM Coupe 4 cavités



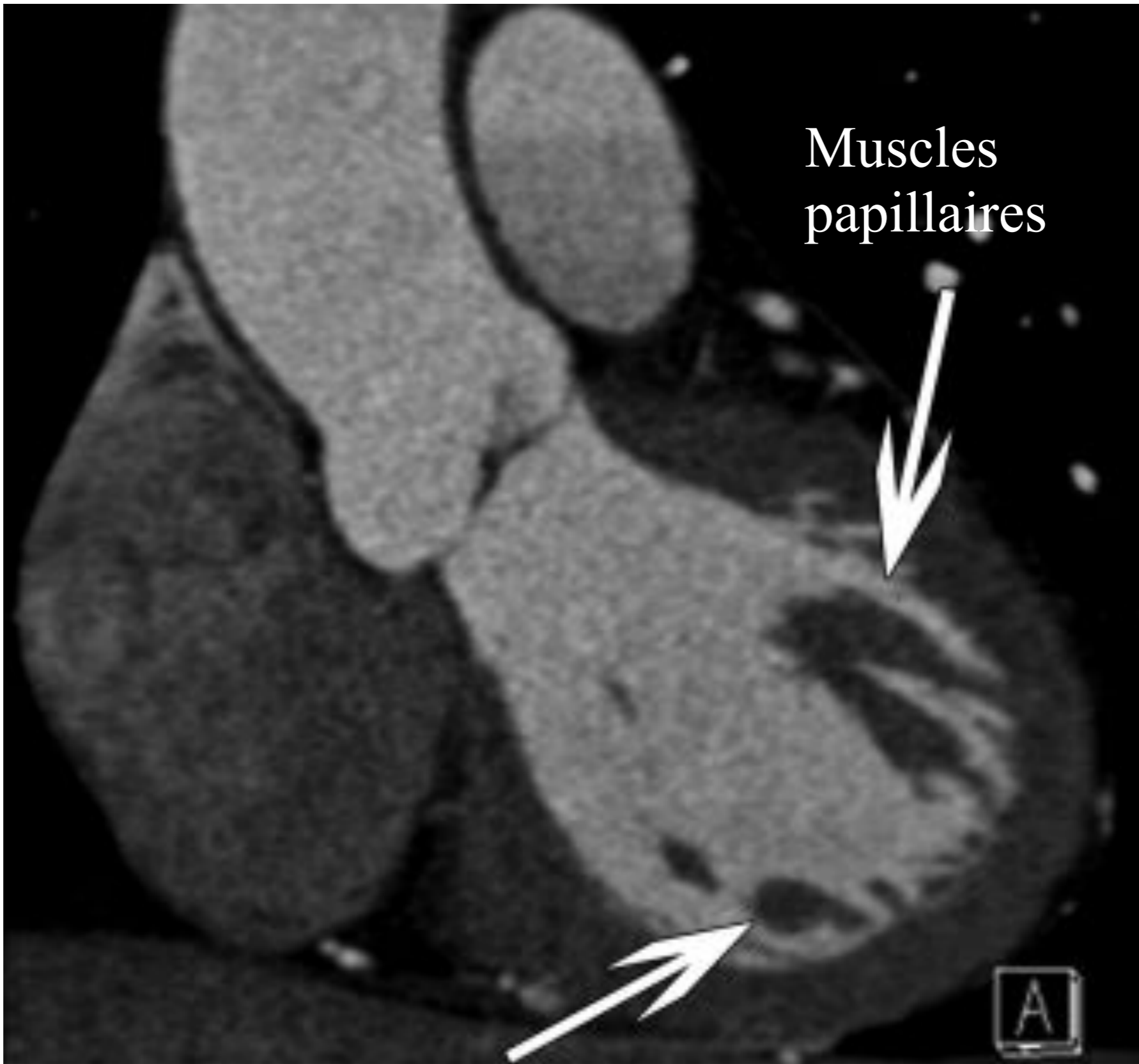
Dt

Coupe long axe du Ventricule G

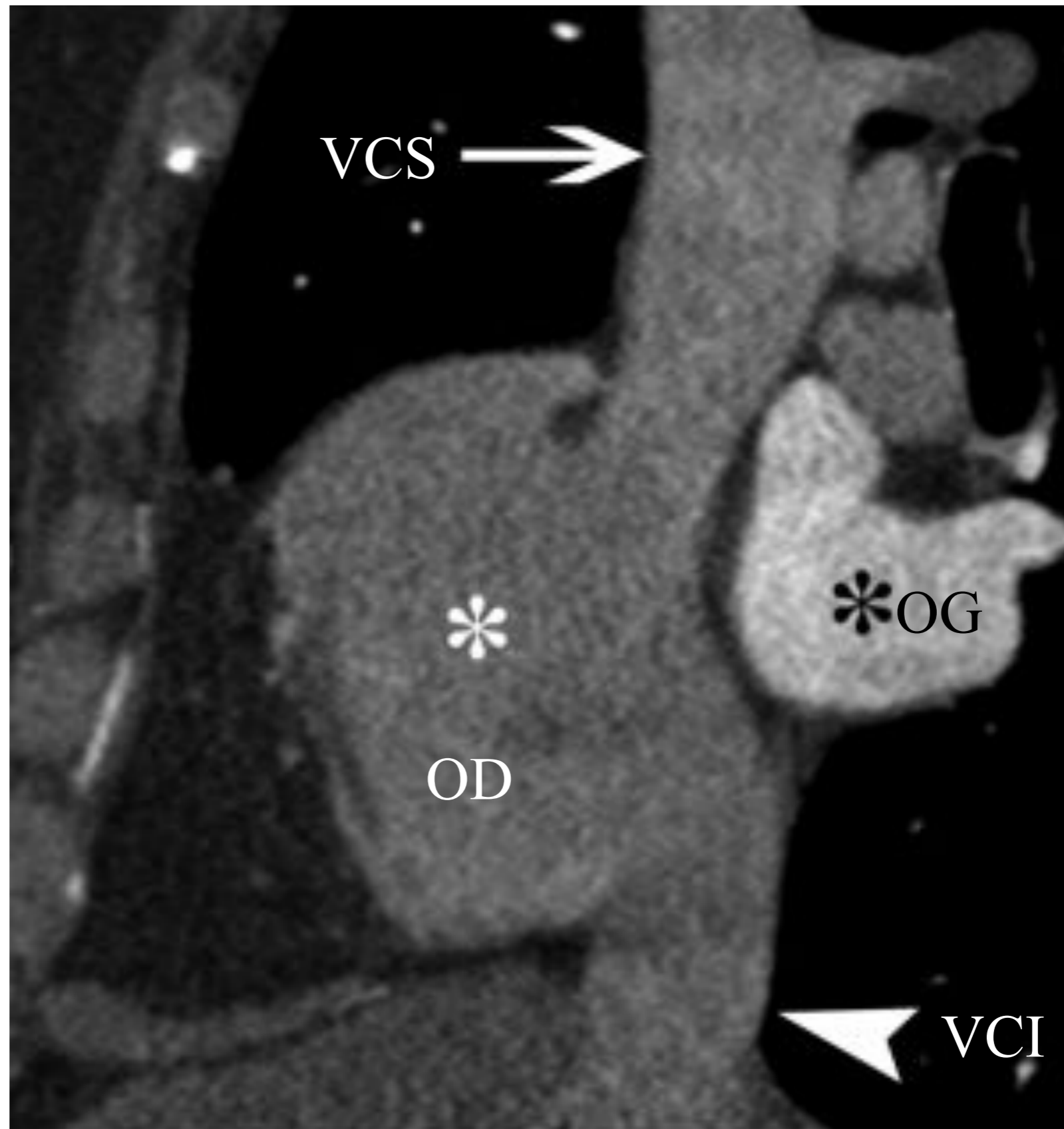


Feuillet
antérieur de la
valve mitrale

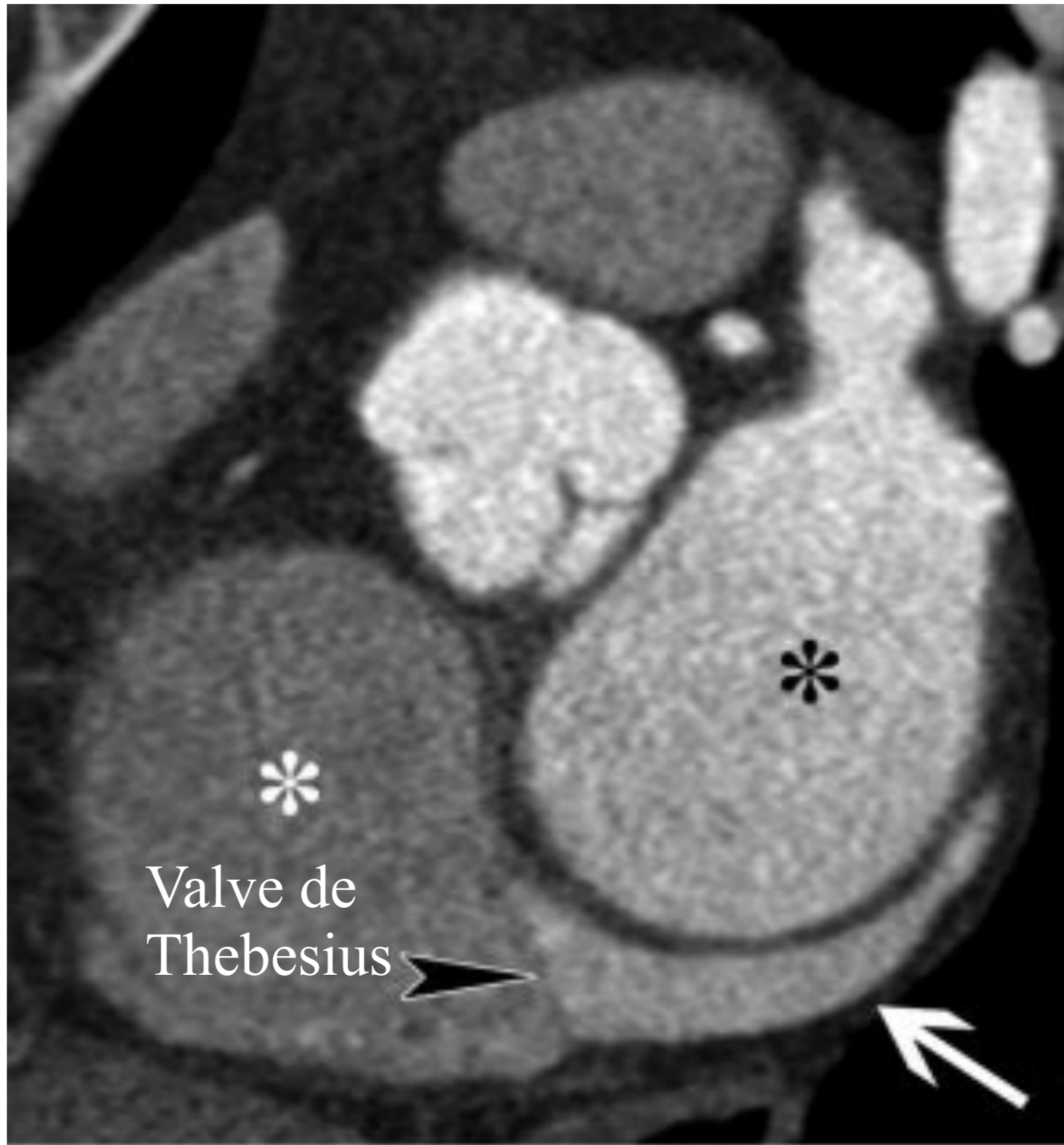
Feuillet
postérieur de
la valve mitrale



O'Brien, J. P. et al. Radiographics 2007;27:1569-1582



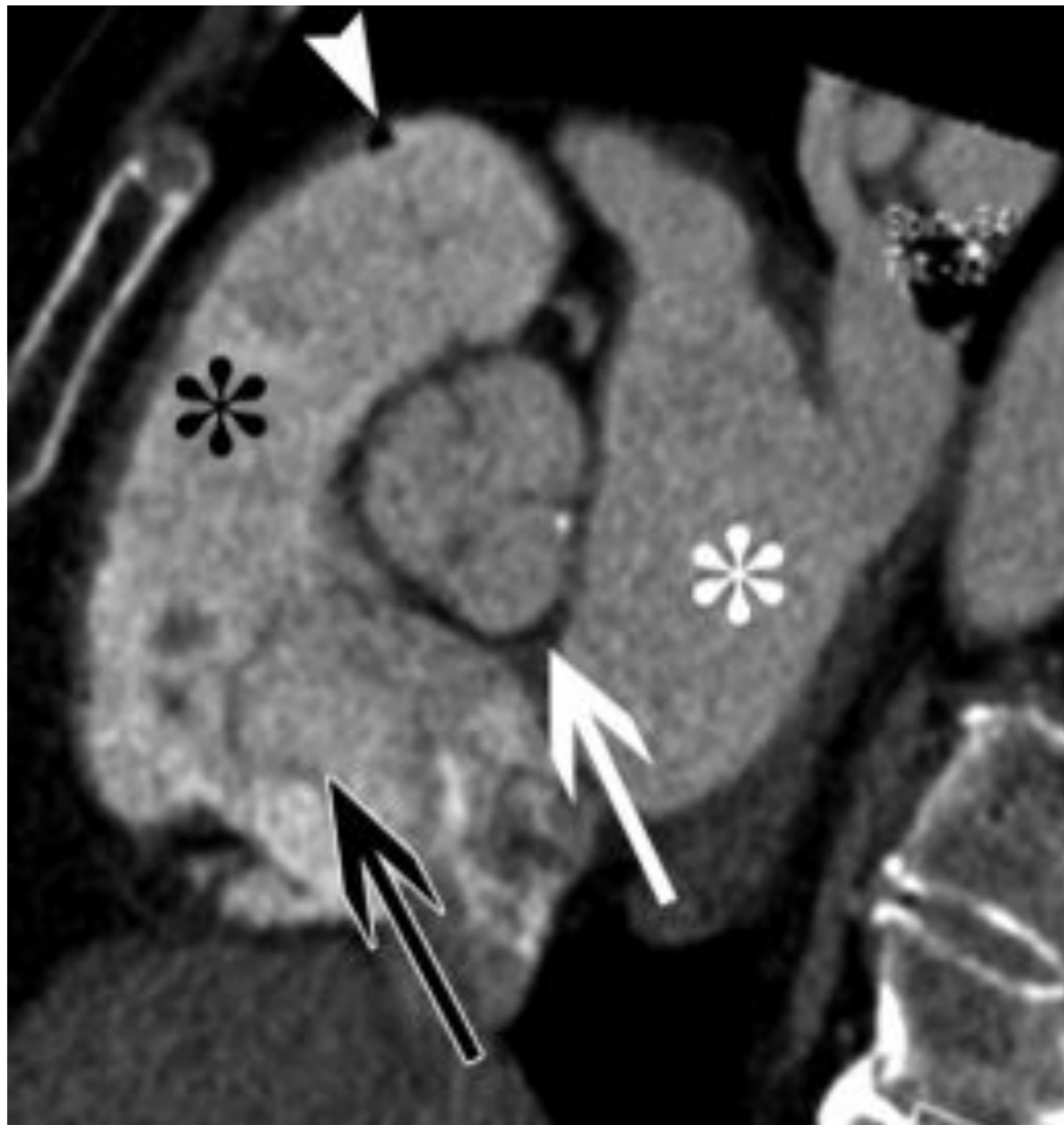O'Brien, J. P. et al. Radiographics 2007;27:1569-1582



Valve de
Thebesius

Sinus
coronaire

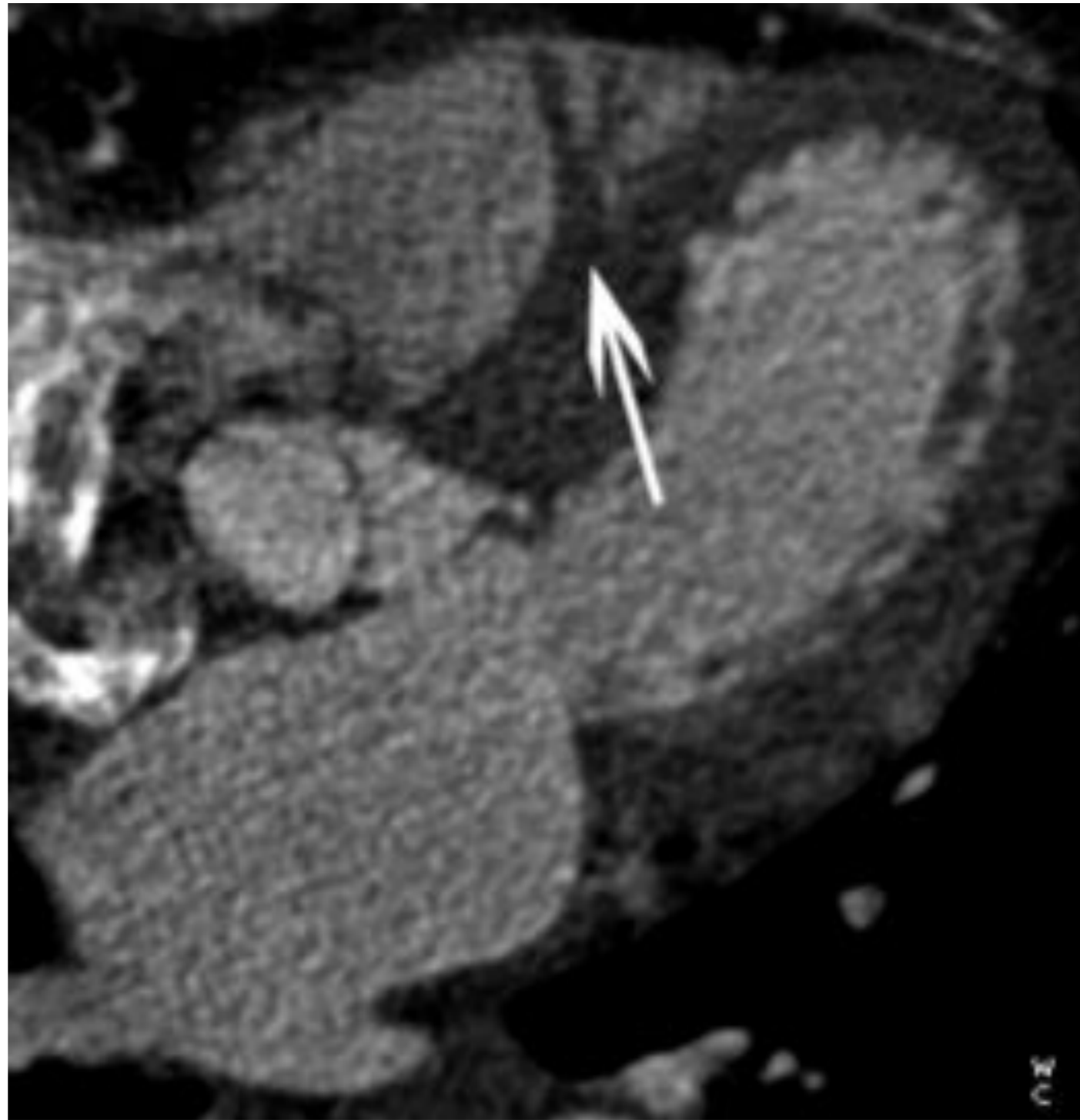
Valve Pulmonaire



O'Brien, J. P. et al. Radiographics 2007;27:1569-1582

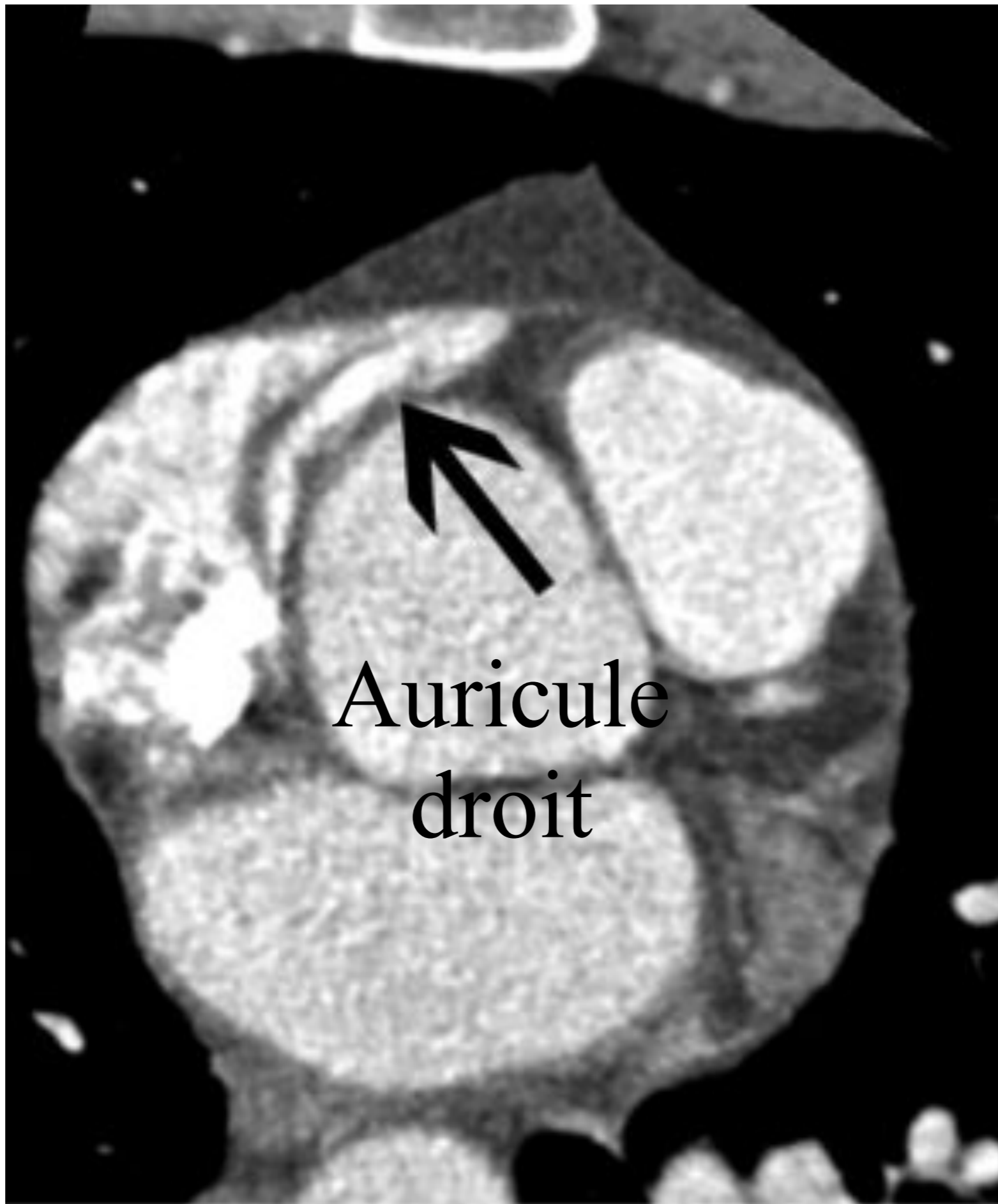
Radiographics

Bandelette modératrice



O'Brien, J. P. et al. Radiographics 2007;27:1569-1582

Radiographics

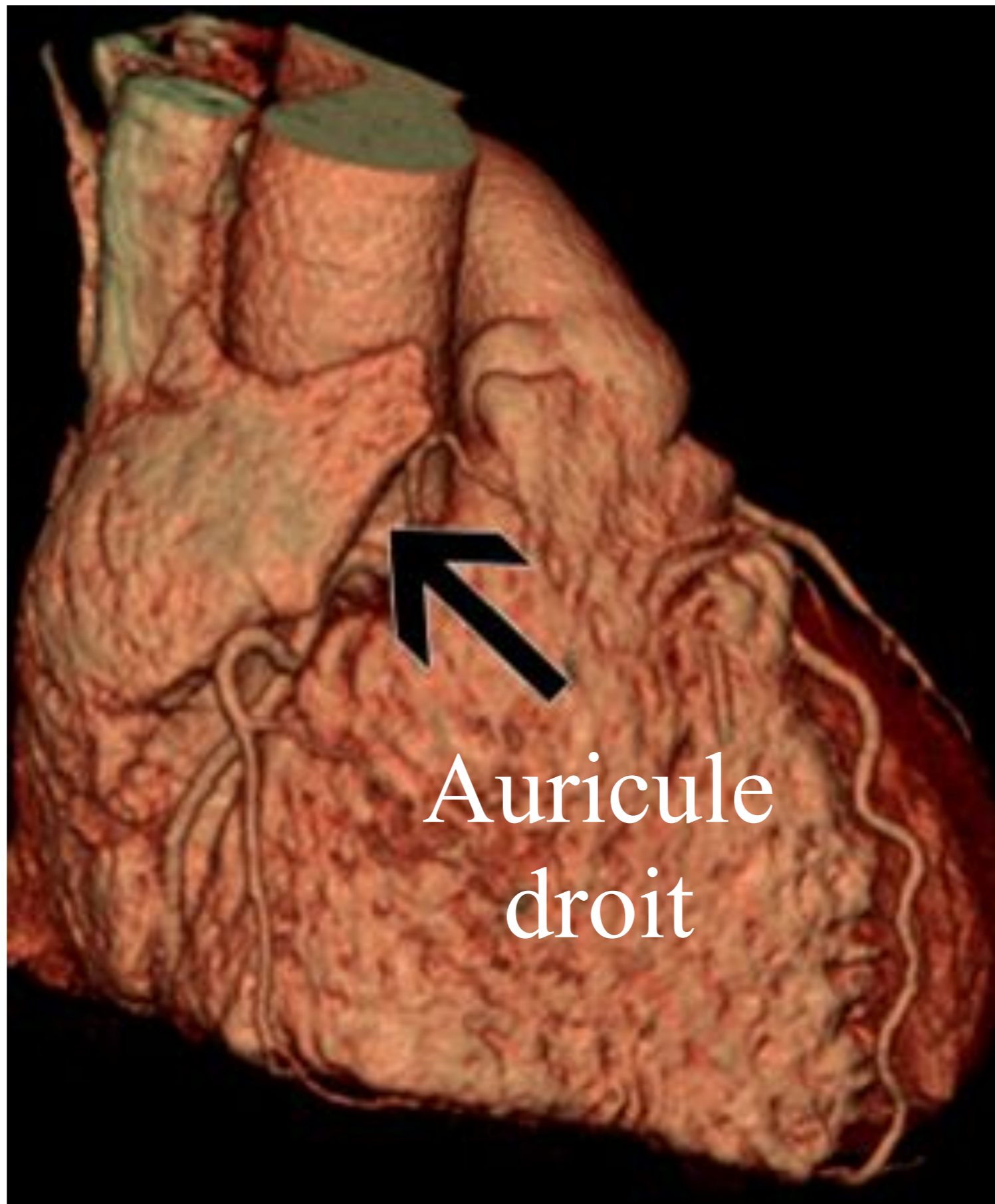


Auricule
droit

radiographics

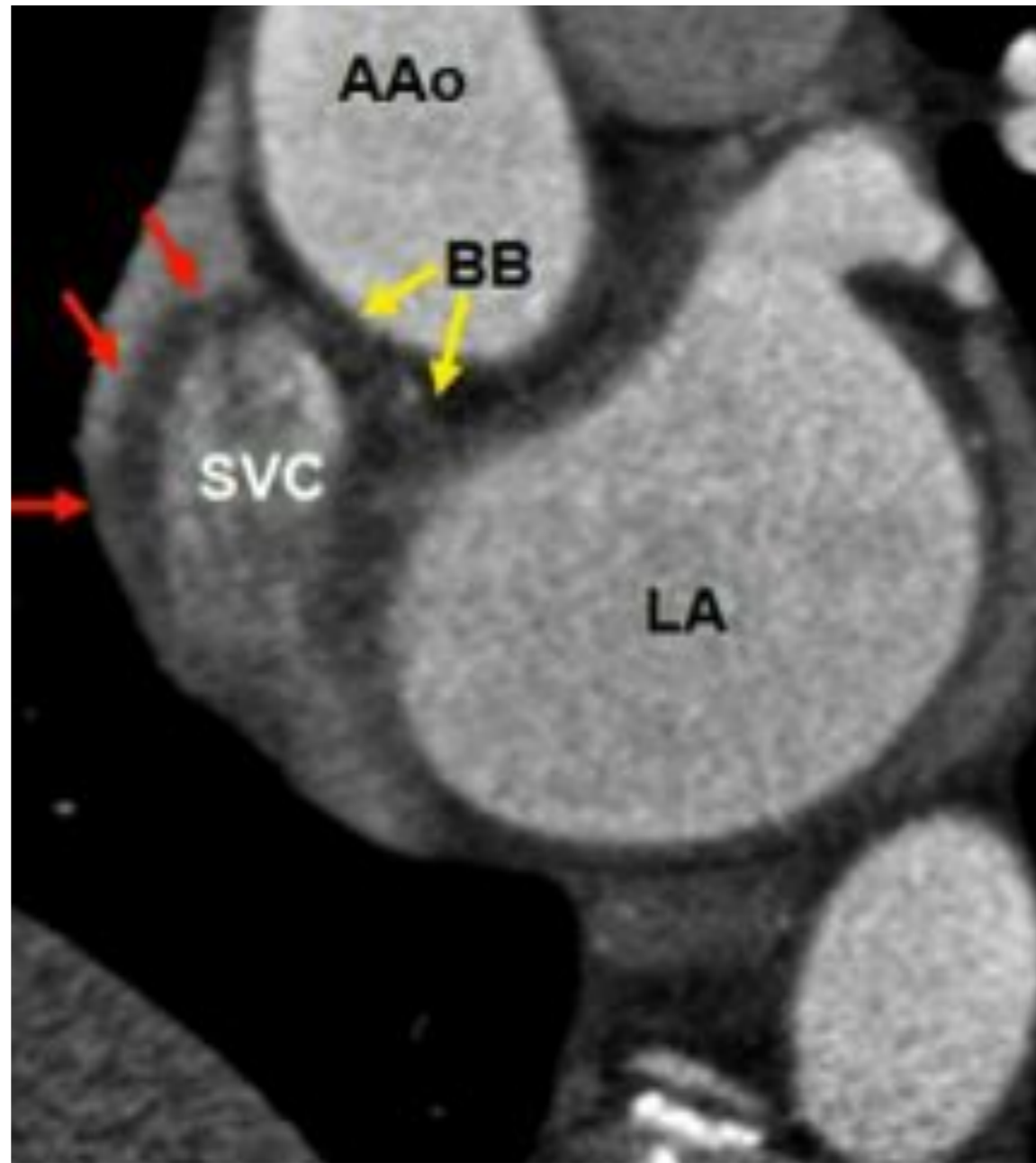
O'Brien, J. P. et al. Radiographics 2007;27:1569-1582

Copyright ©Radiological Society of North America, 2007



Auricule
droit

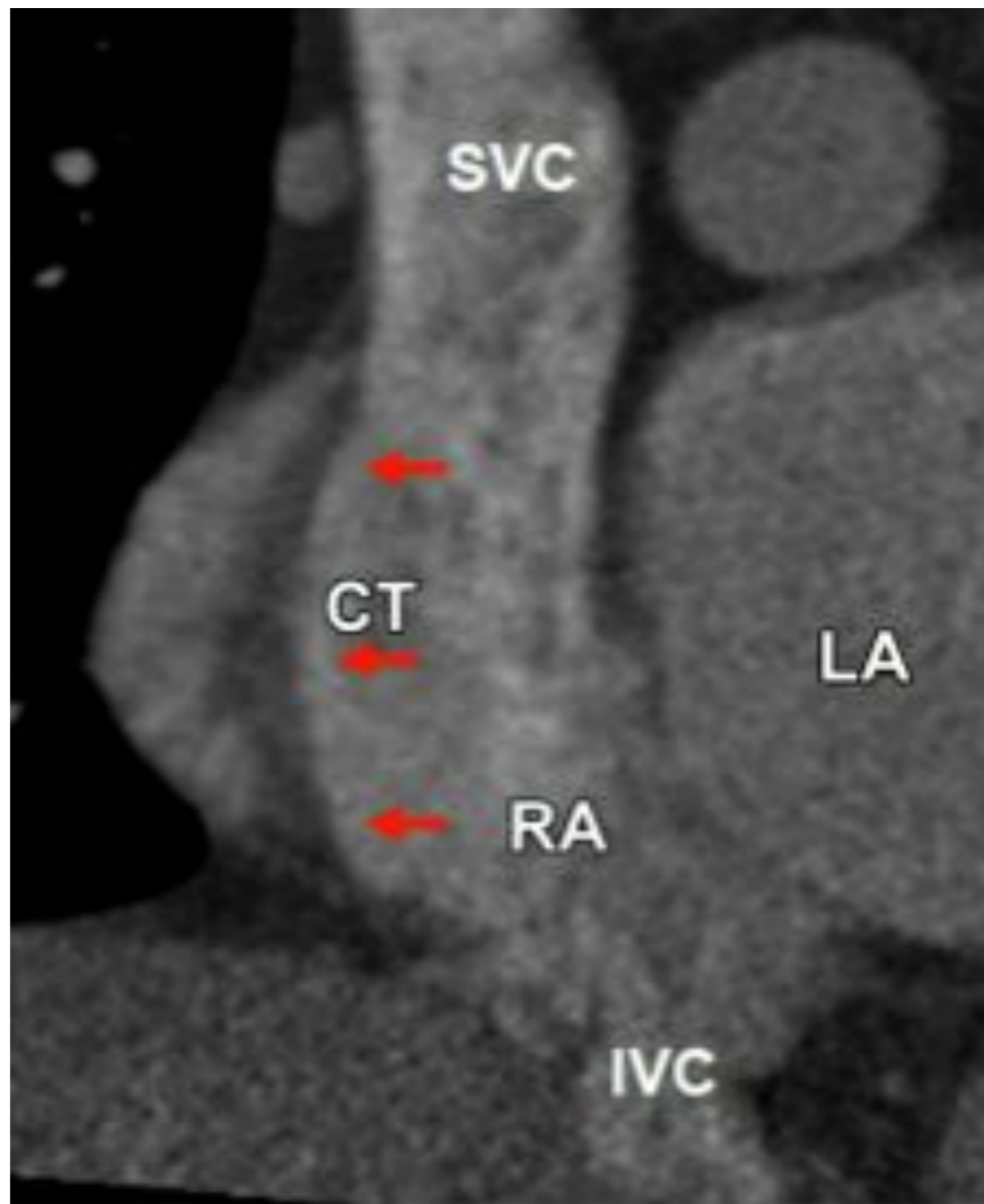
Crista terminalis



Saremi, F. et al. Radiographics 2007;27:1539-1565

Radiographics

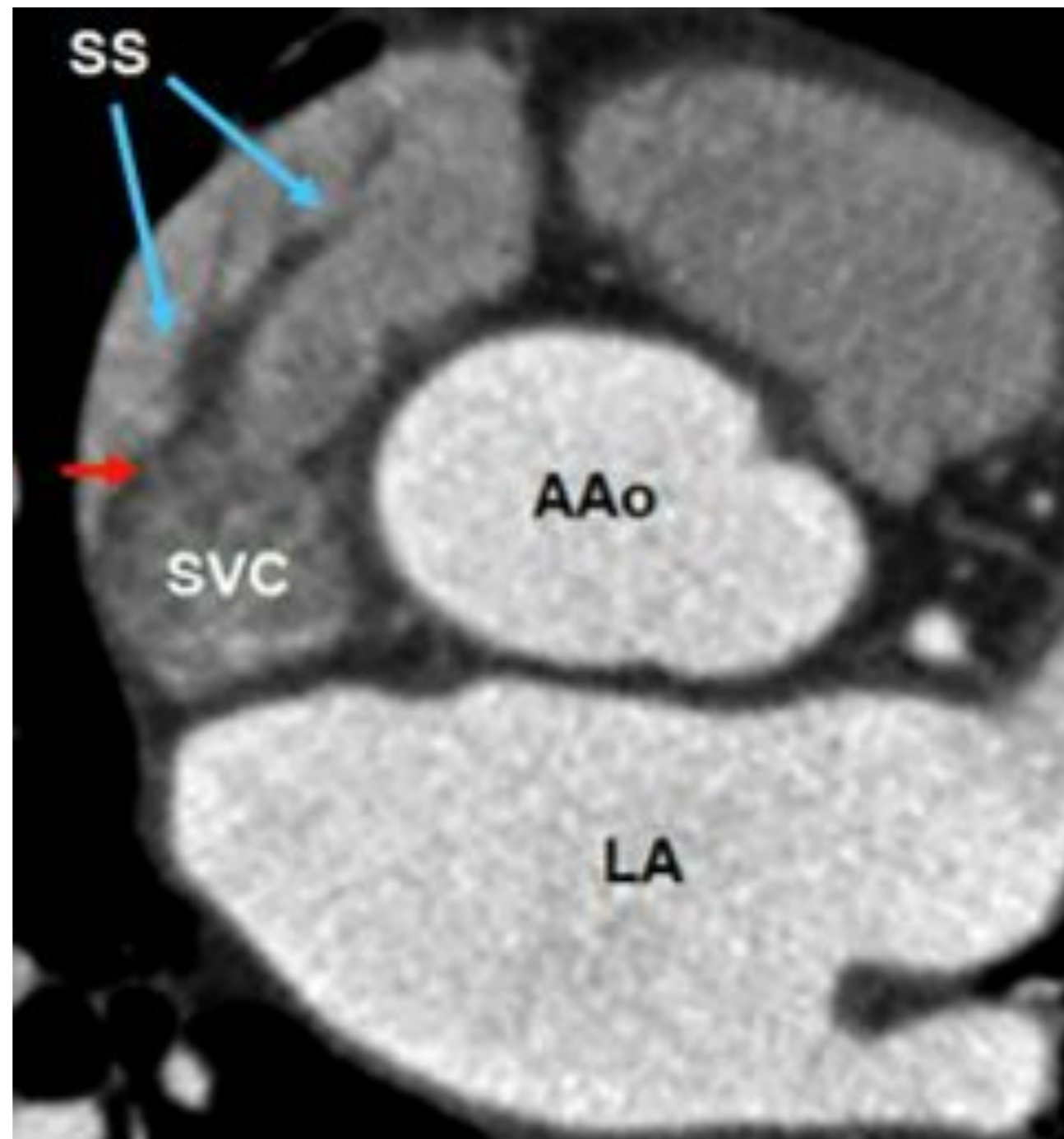
Crista terminalis



Saremi, F. et al. Radiographics 2007;27:1539-1565

Radiographics

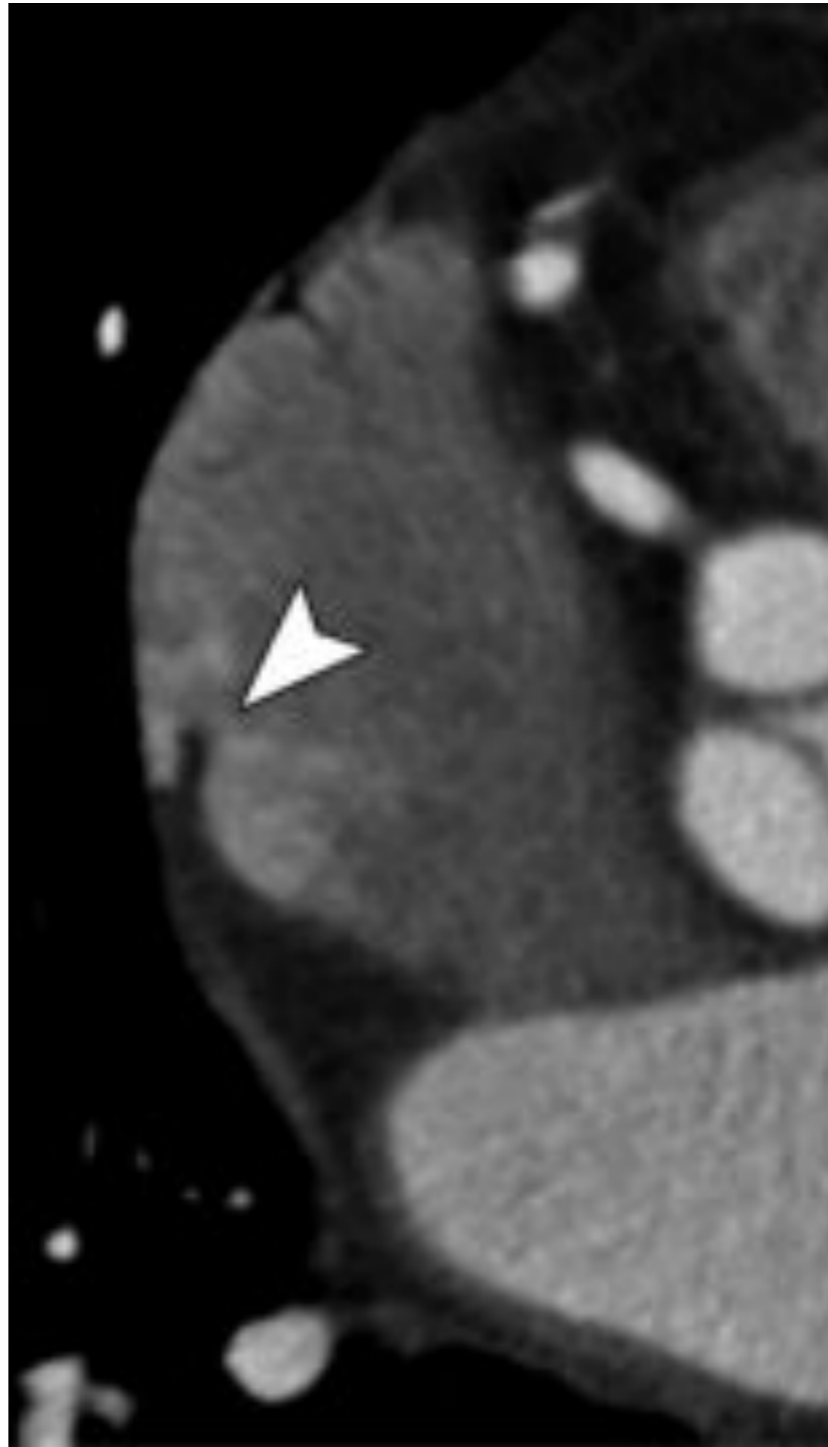
Crista terminalis



Saremi, F. et al. Radiographics 2007;27:1539-1565

Radiographics

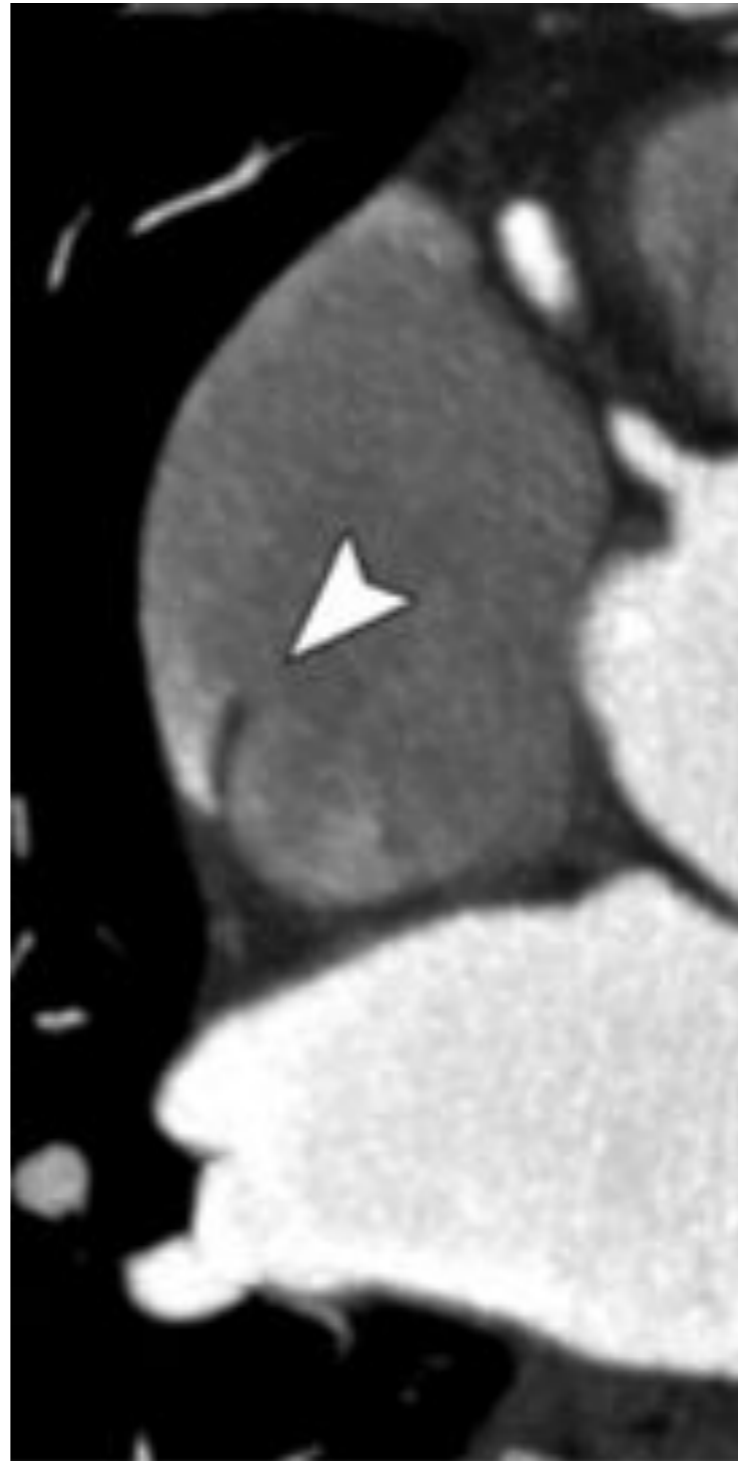
Crista terminalis



Saremi, F. et al. Radiographics 2007;27:1539-1565

Radiographics

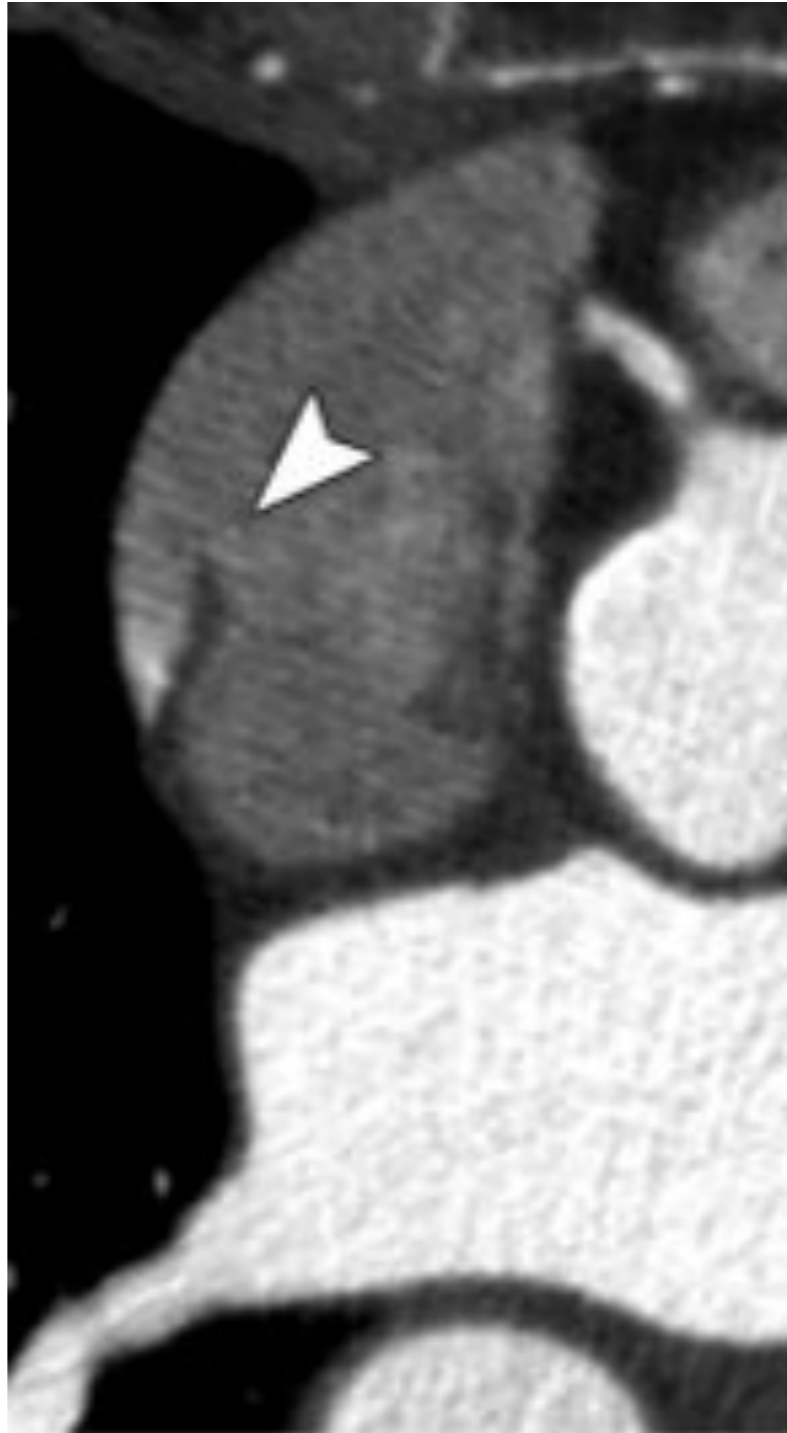
Crista terminalis



Saremi, F. et al. Radiographics 2007;27:1539-1565

Radiographics

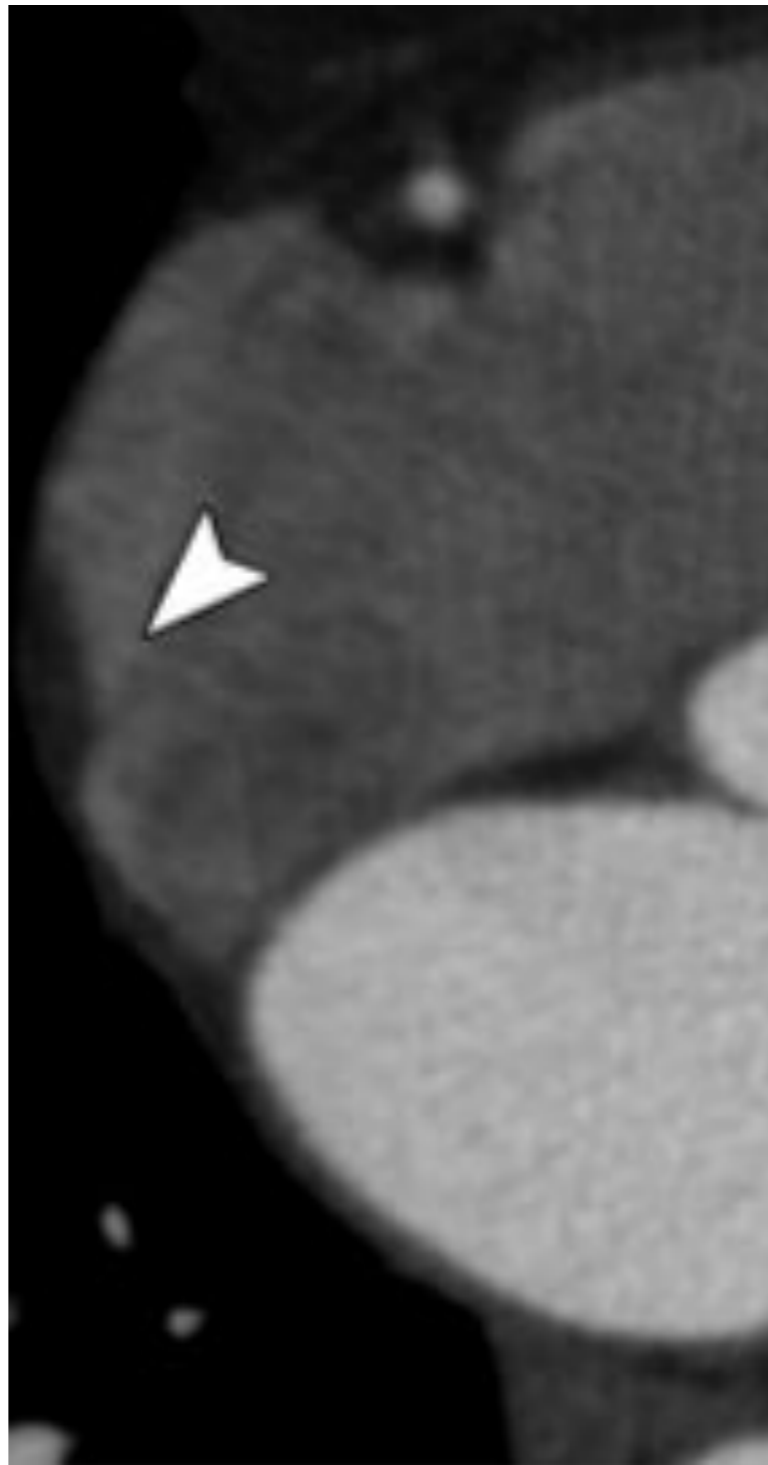
Crista terminalis



Saremi, F. et al. Radiographics 2007;27:1539-1565

Radiographics

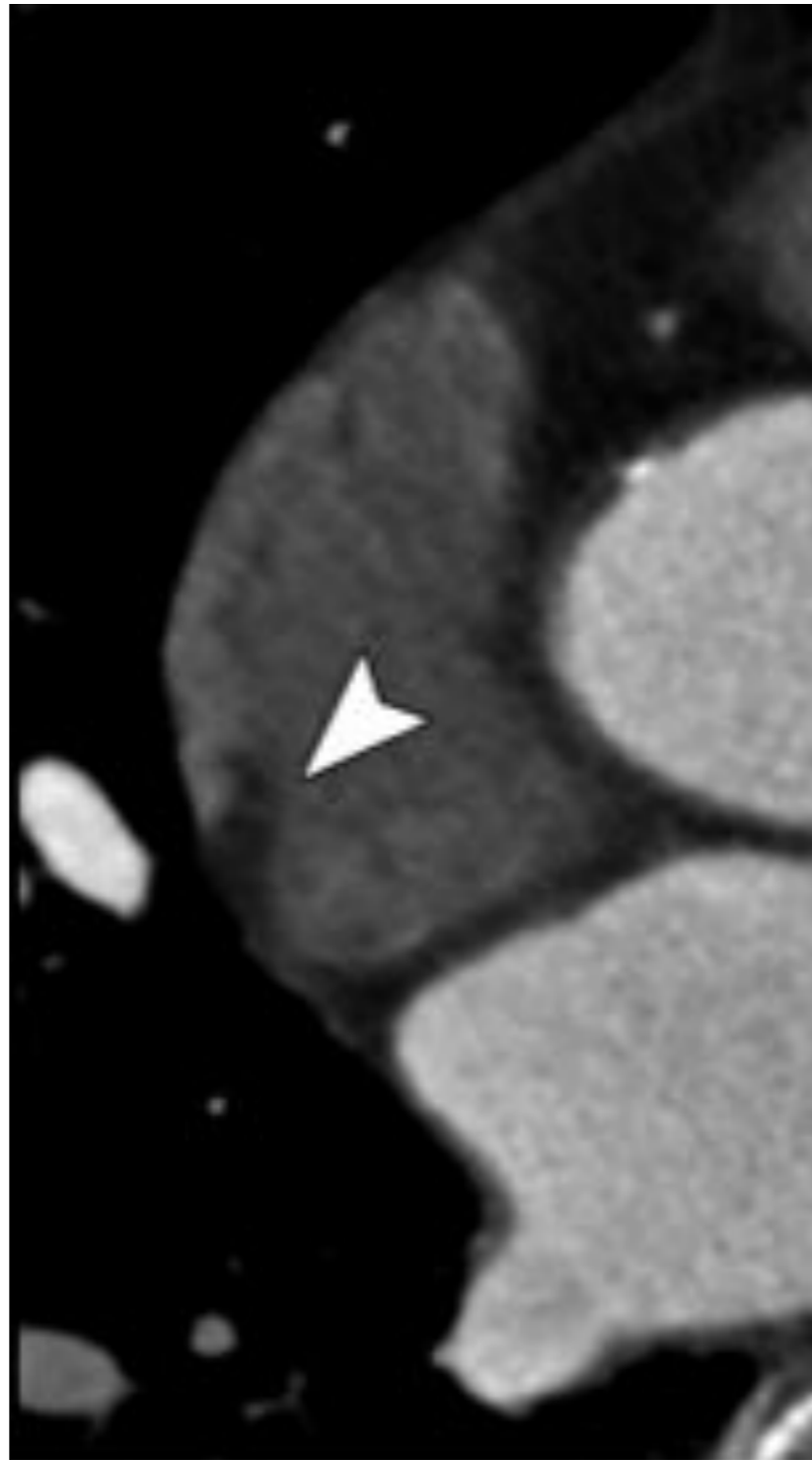
Crista terminalis



Saremi, F. et al. Radiographics 2007;27:1539-1565

Radiographics

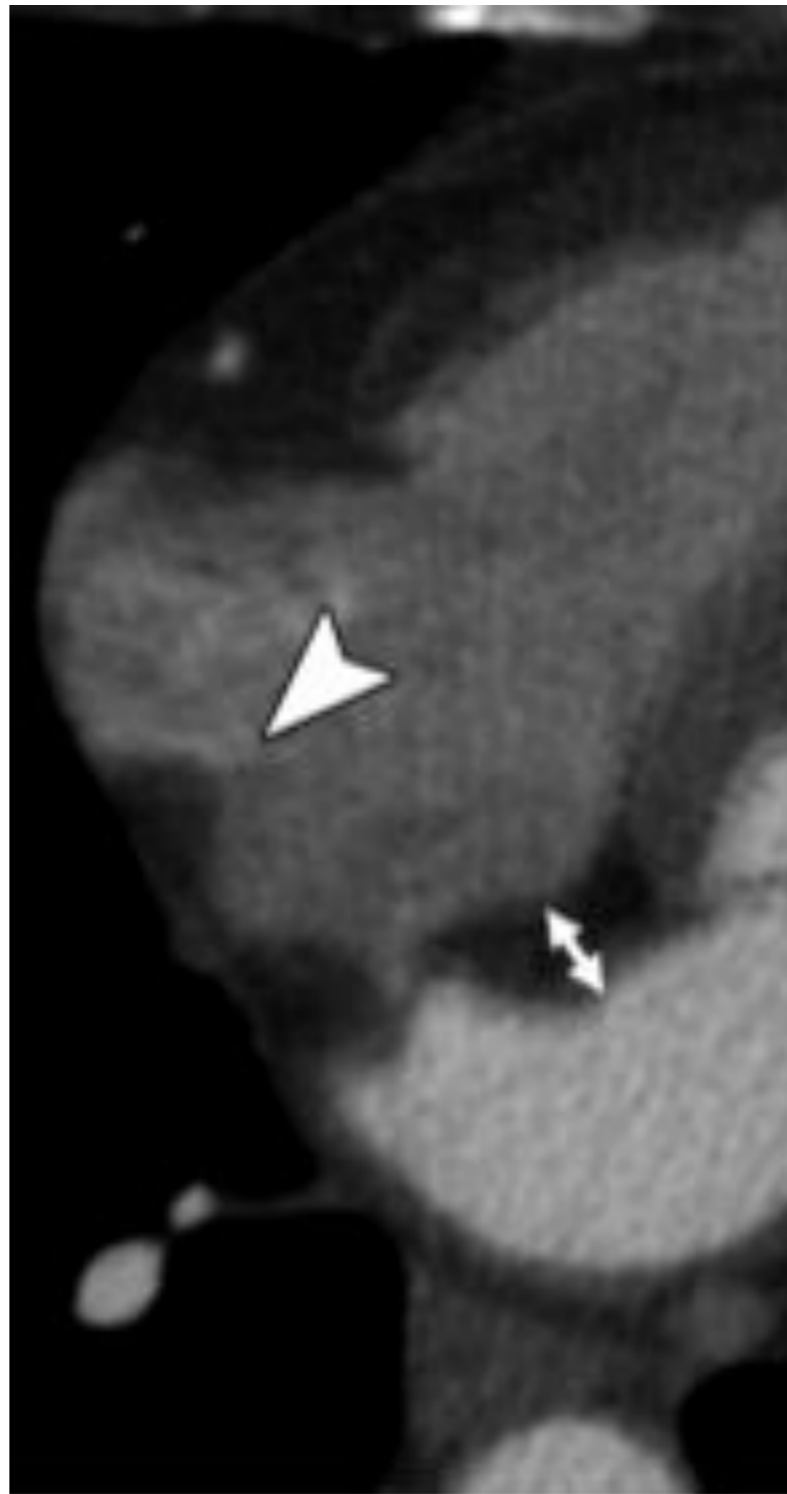
Crista terminalis



Saremi, F. et al. Radiographics 2007;27:1539-1565

Radiographics

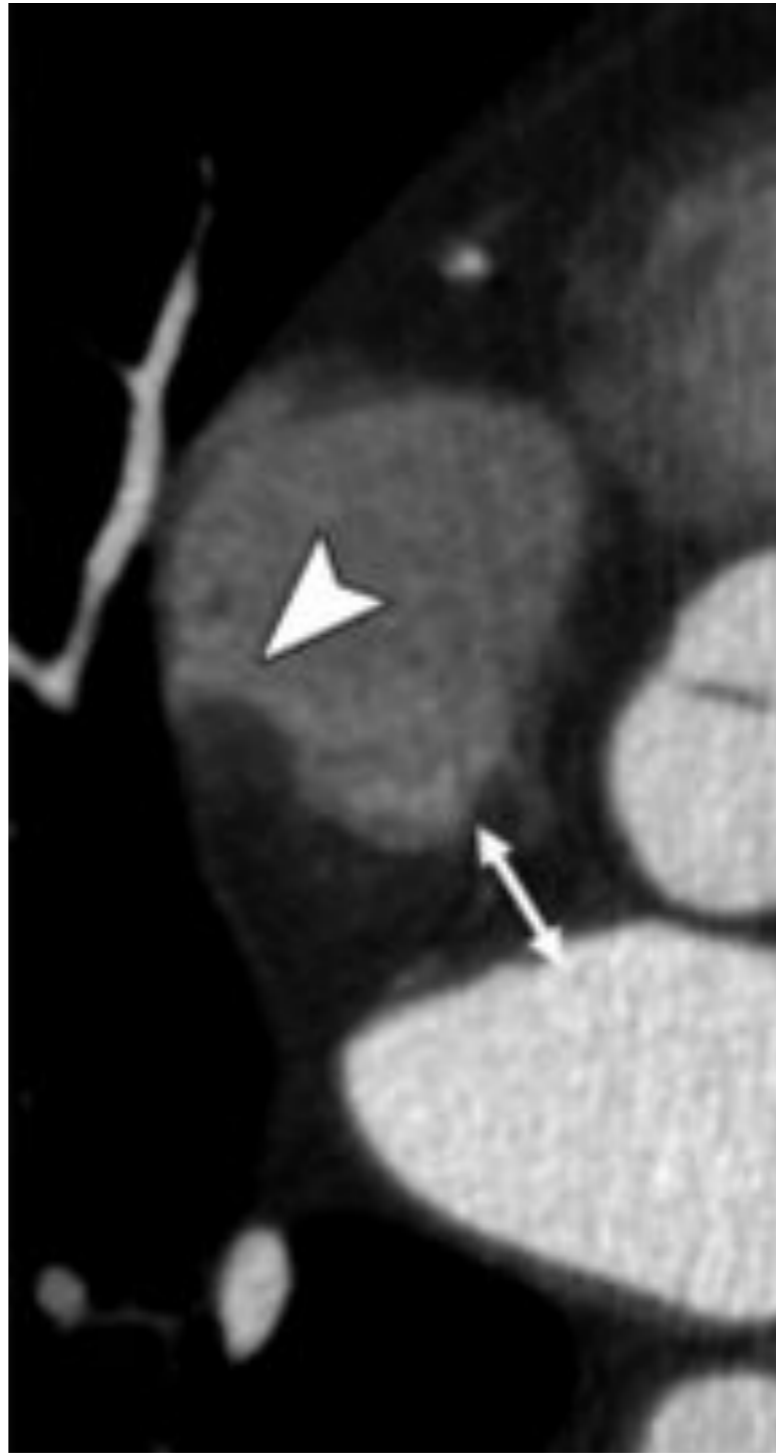
Crista terminalis



Saremi, F. et al. Radiographics 2007;27:1539-1565

Radiographics

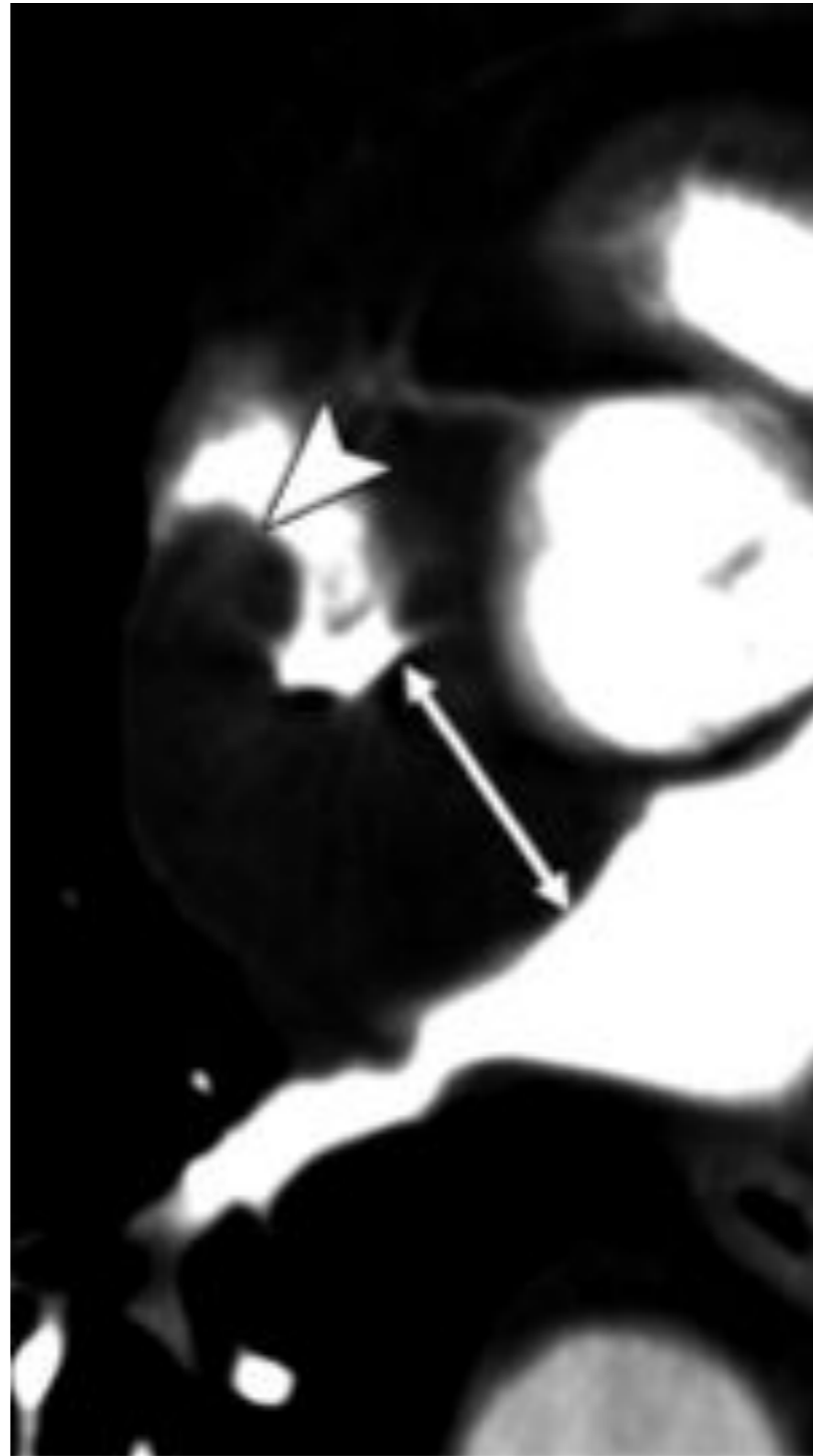
Crista terminalis



Saremi, F. et al. Radiographics 2007;27:1539-1565

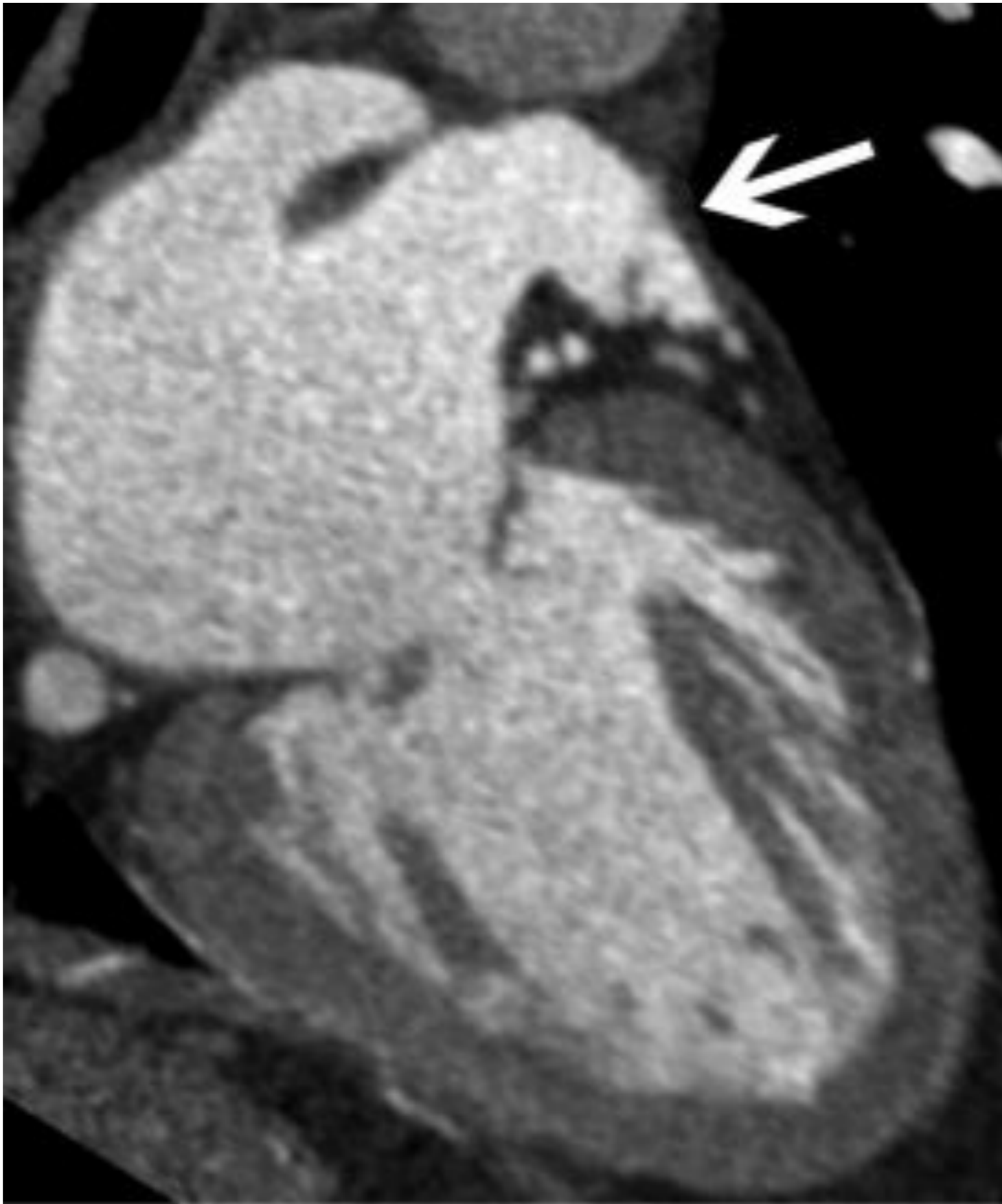Radiographics

Crista terminalis



Saremi, F. et al. Radiographics 2007;27:1539-1565

Radiographics

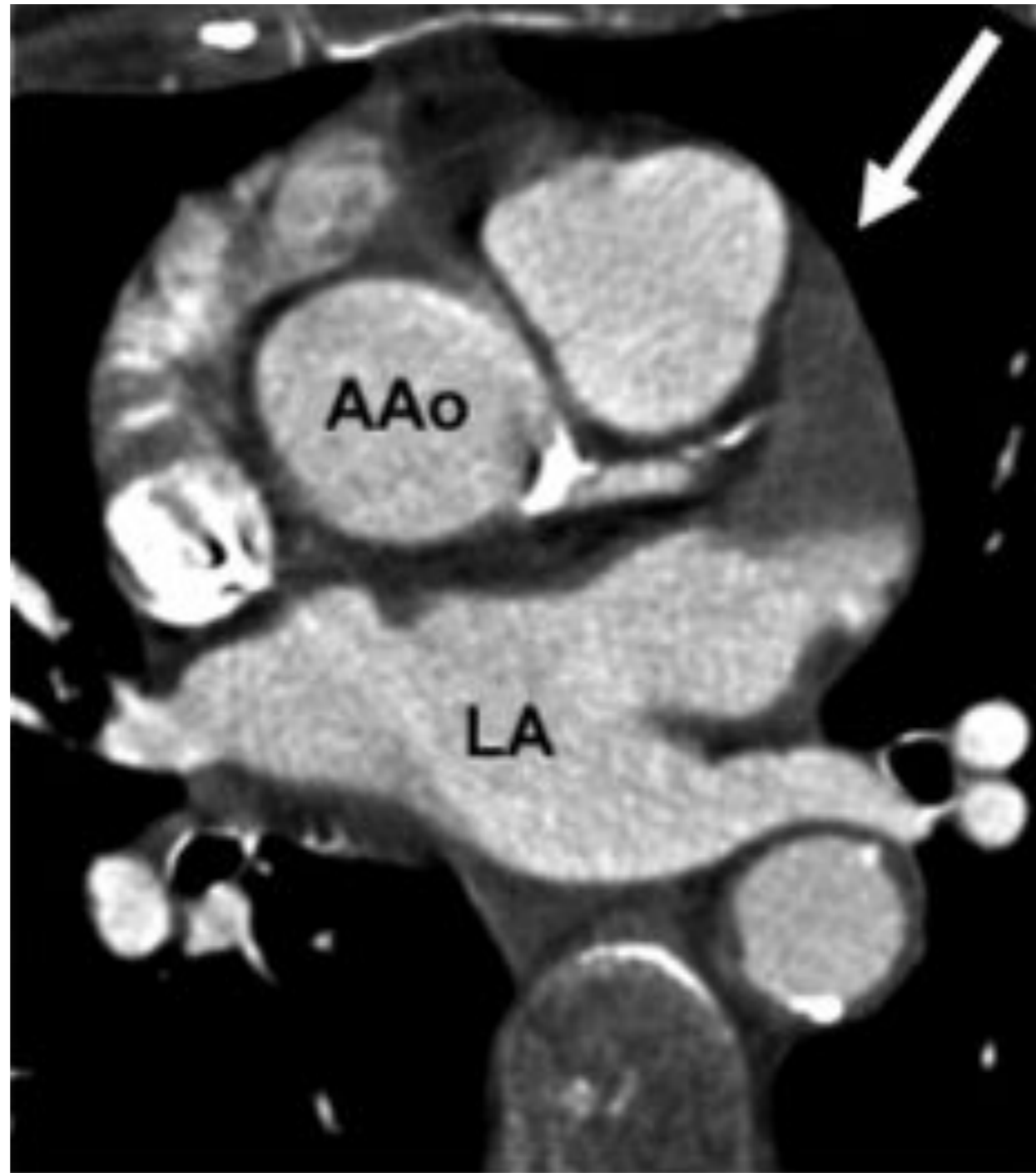


Auricule
gauche

O'Brien, J. P. et al. Radiographics 2007;27:1569-1582

Radiographics

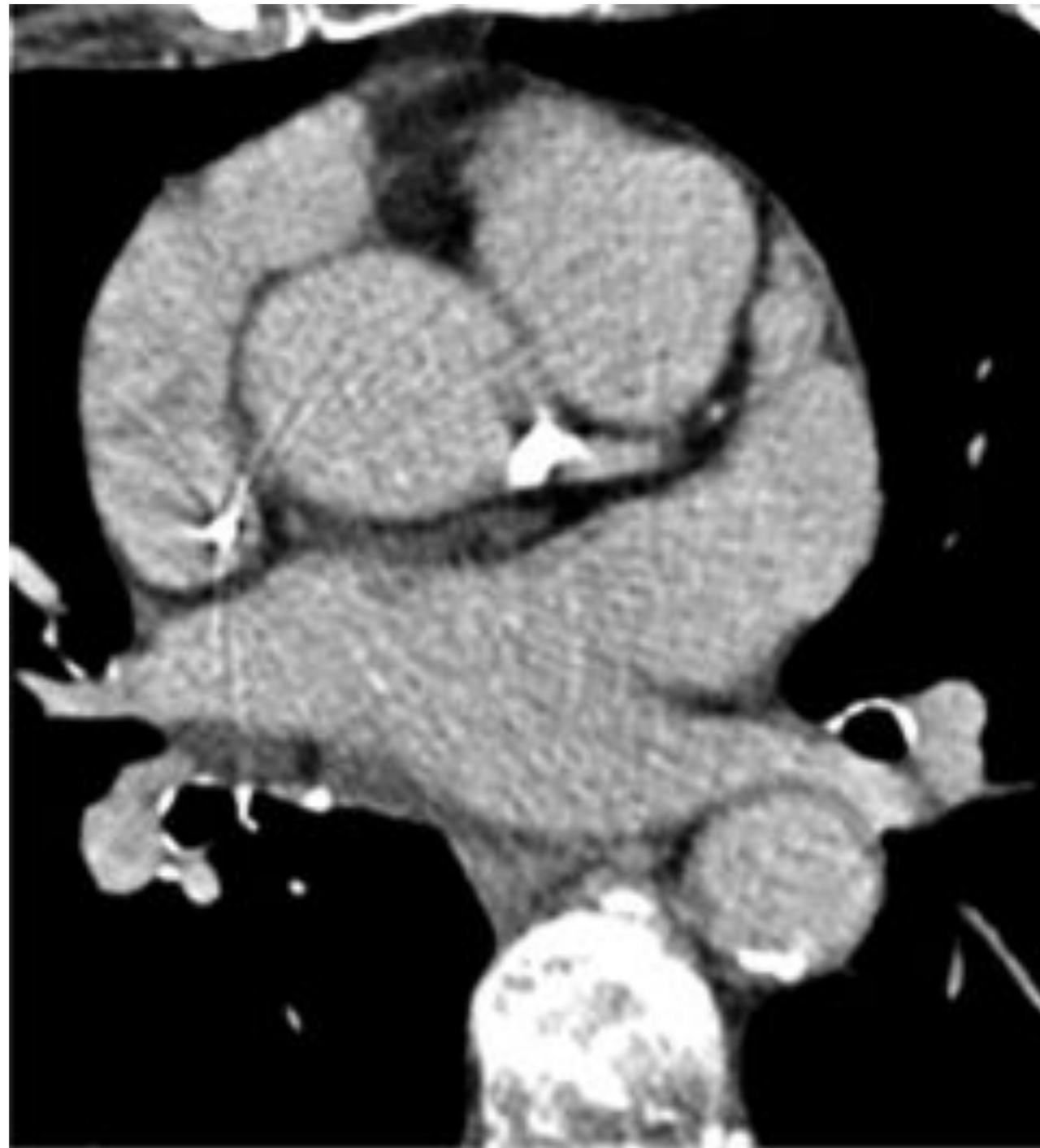Auricule gauche



Saremi, F. et al. Radiographics 2007;27:1539-1565

Radiographics

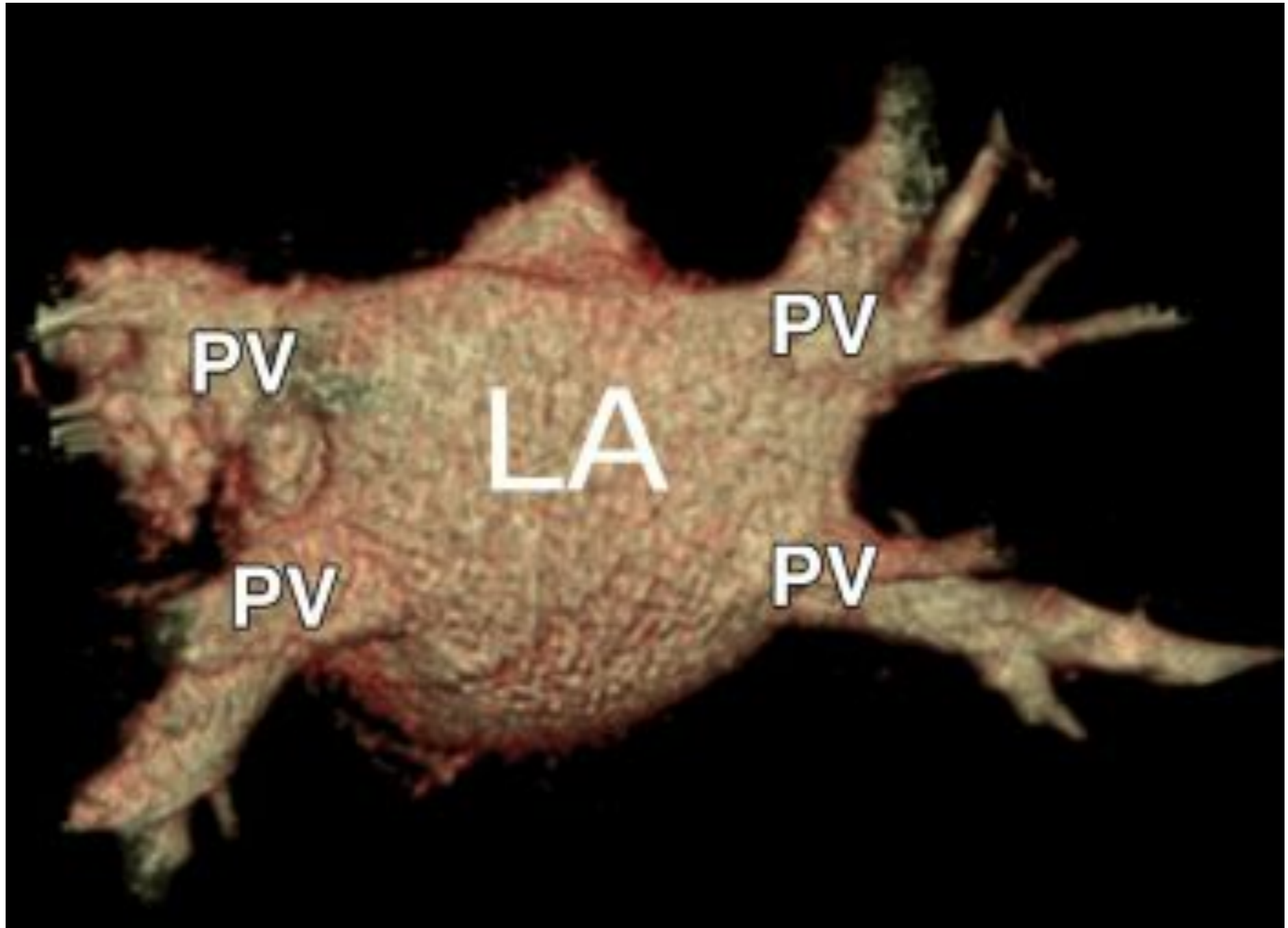
Auricule gauche



Saremi, F. et al. Radiographics 2007;27:1539-1565

Radiographics

Oreillette Gauche / Veines Pulmonaires



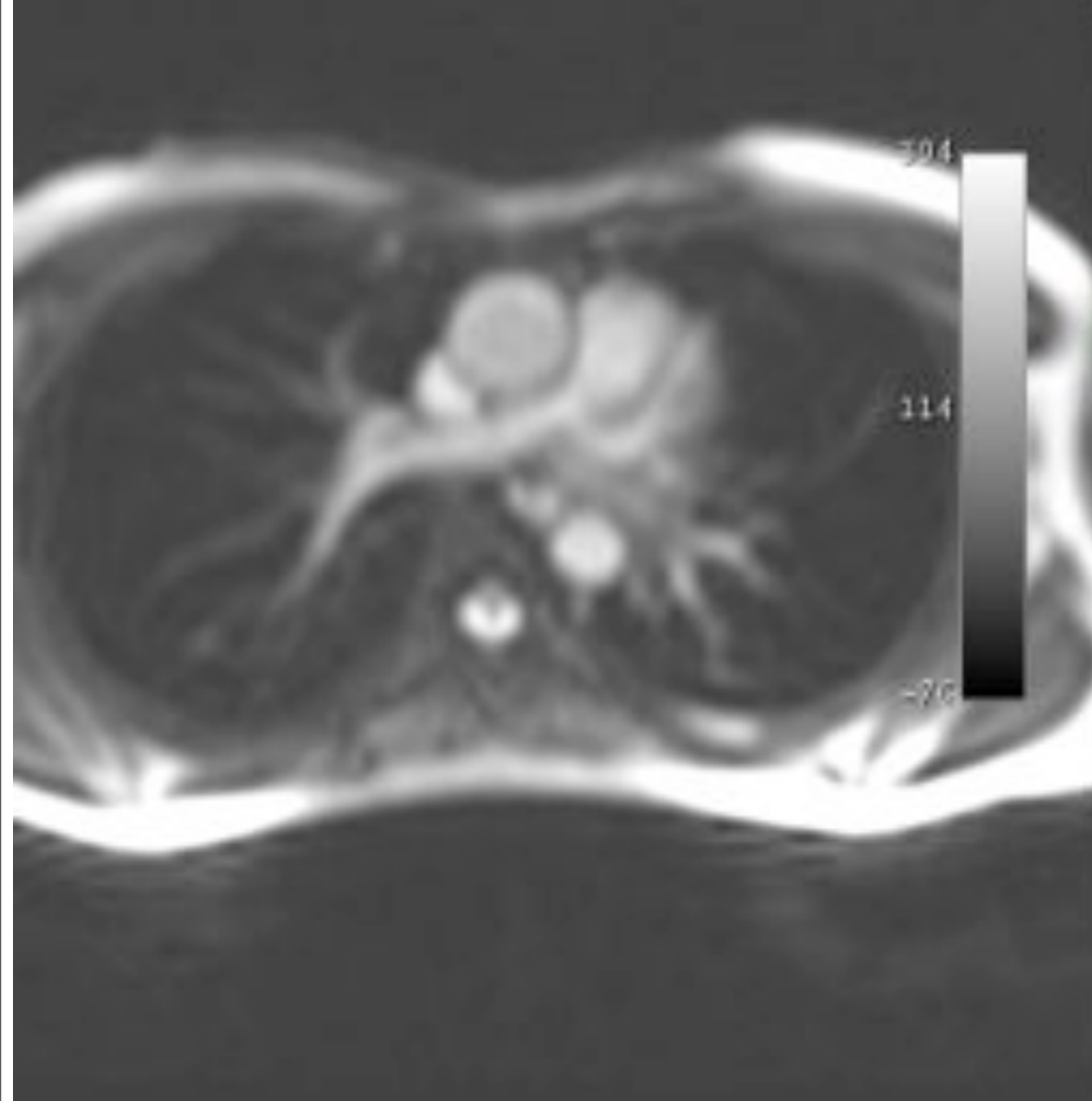
O'Brien, J. P. et al. Radiographics 2007;27:1569-1582

Radiographics

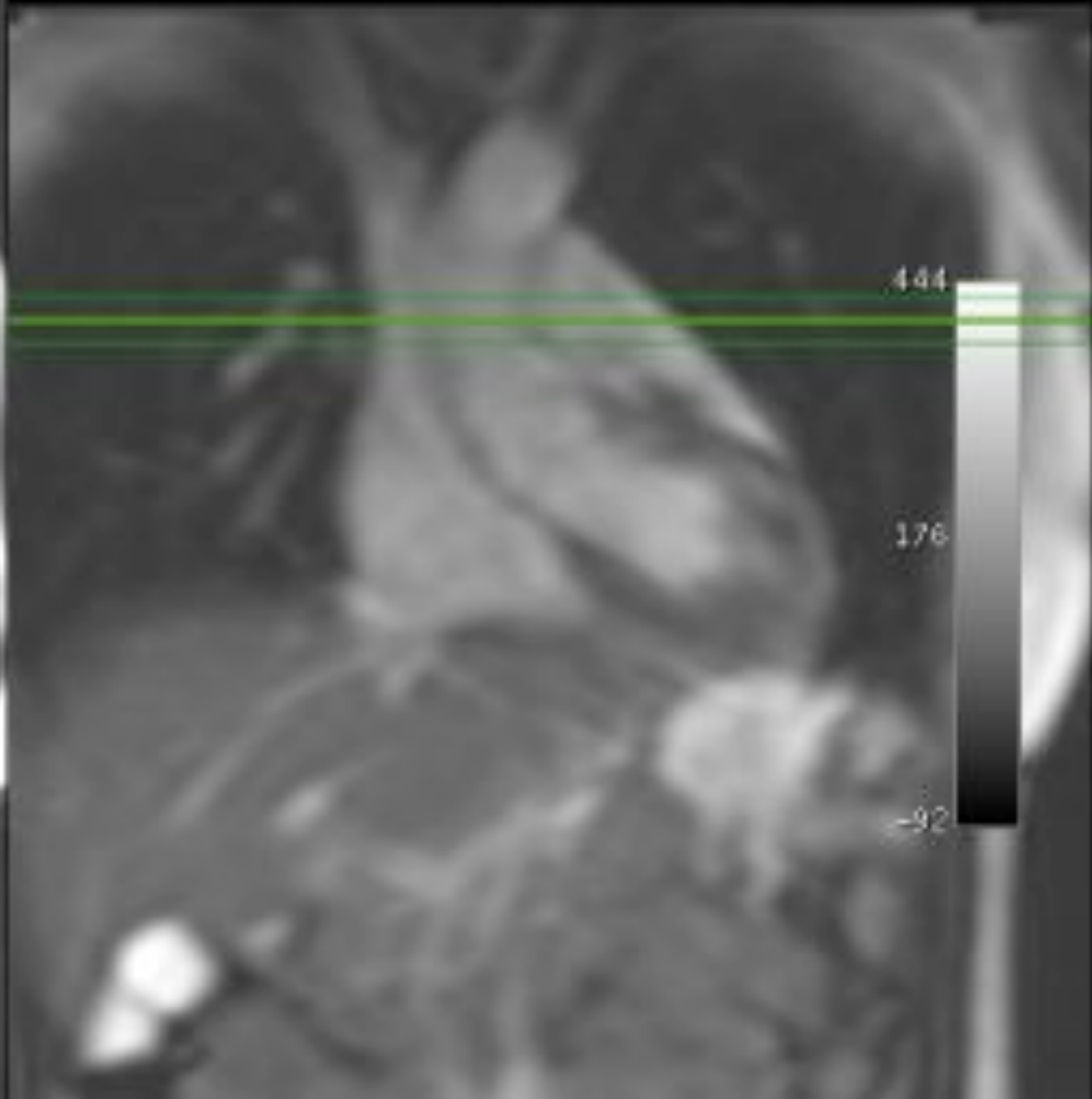


Aorte thoracique

Plan axial
transverse

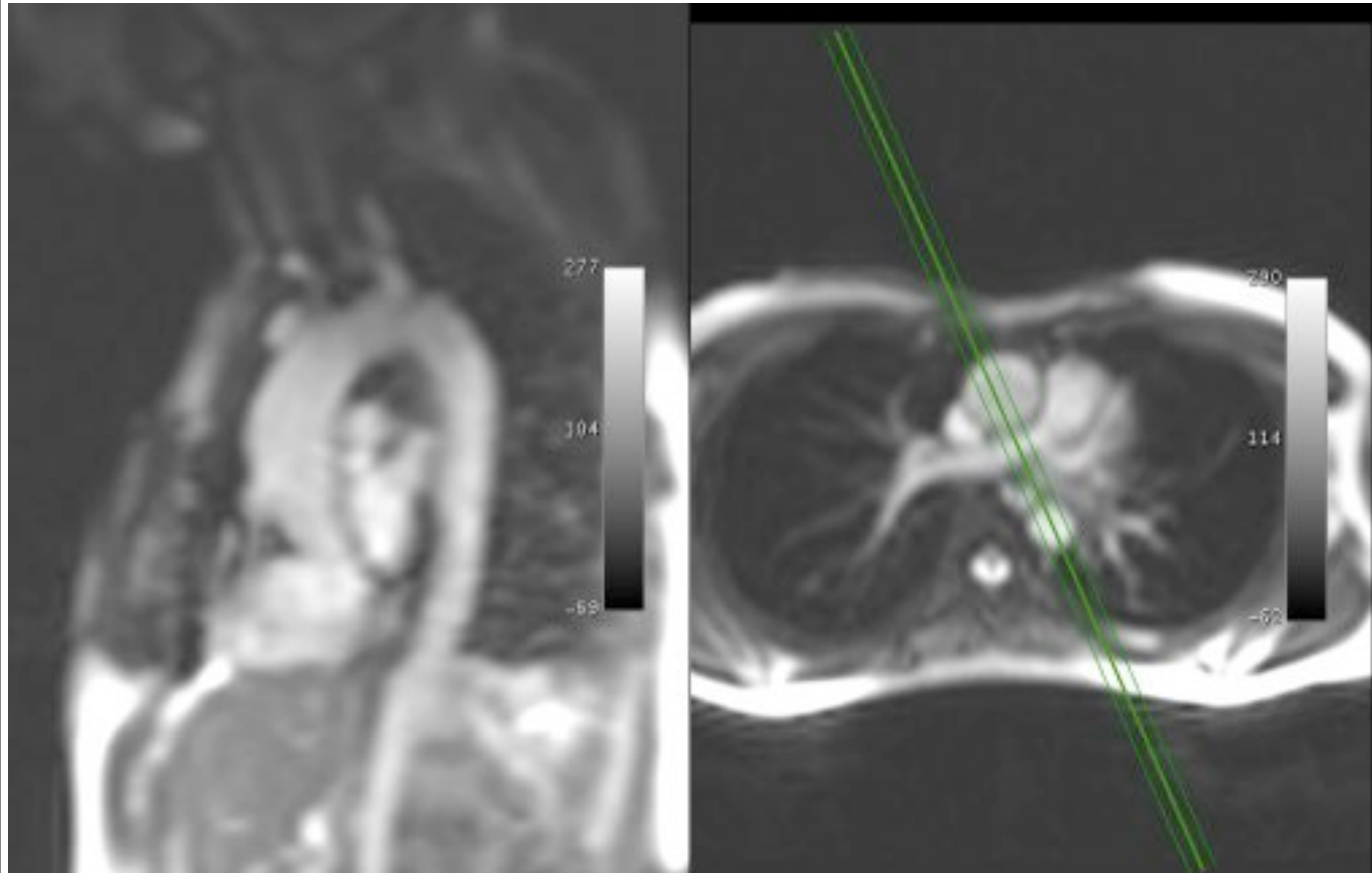


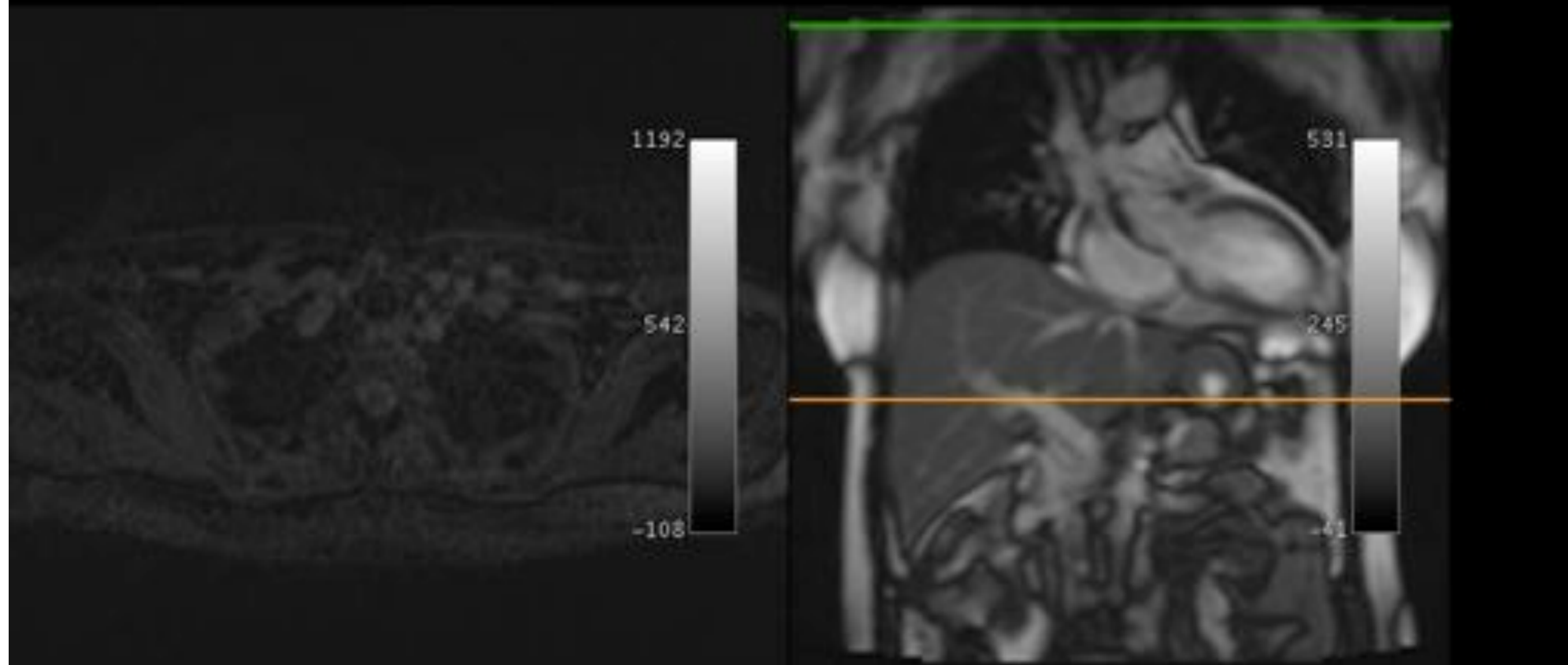
Plan frontal

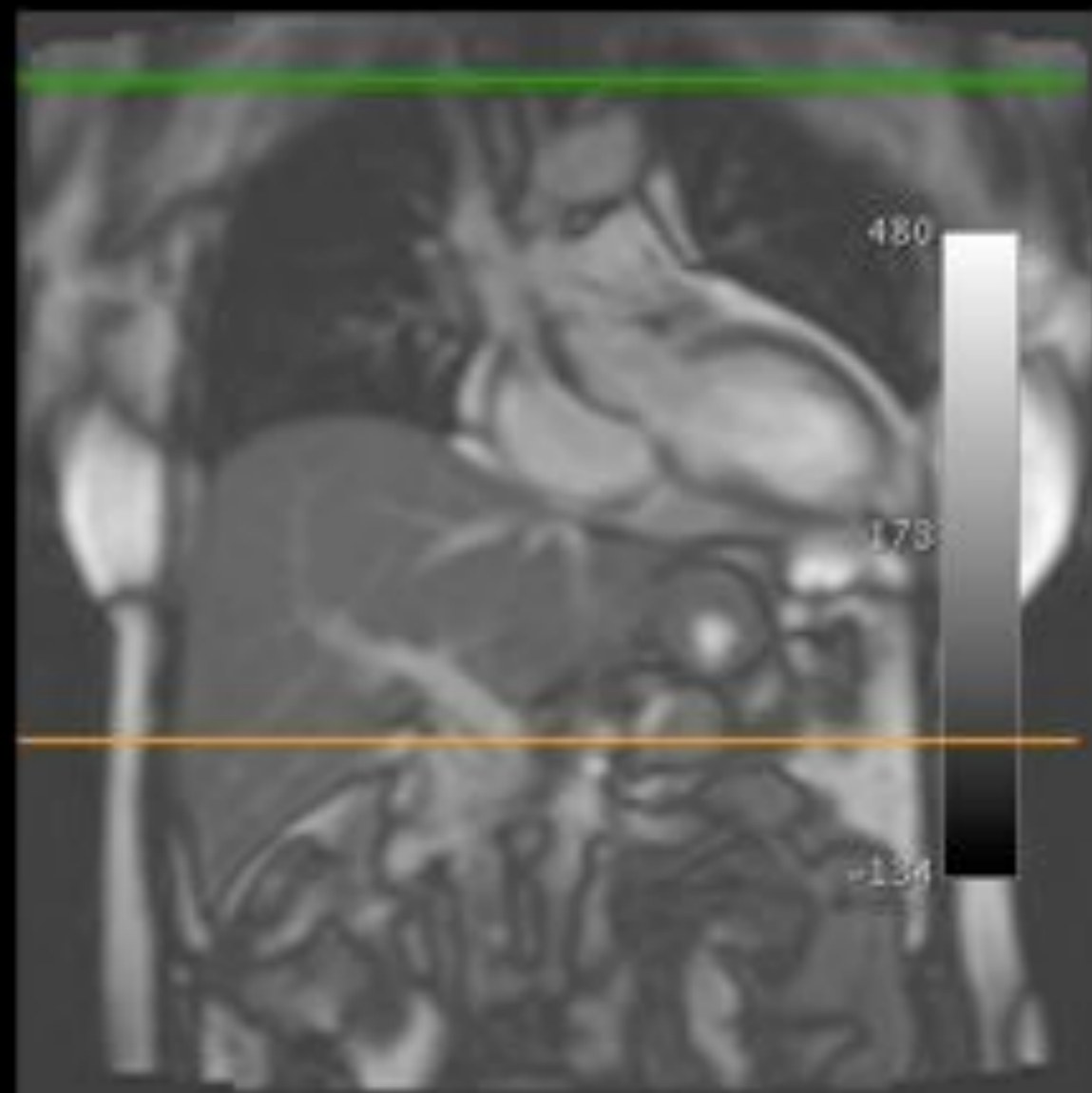
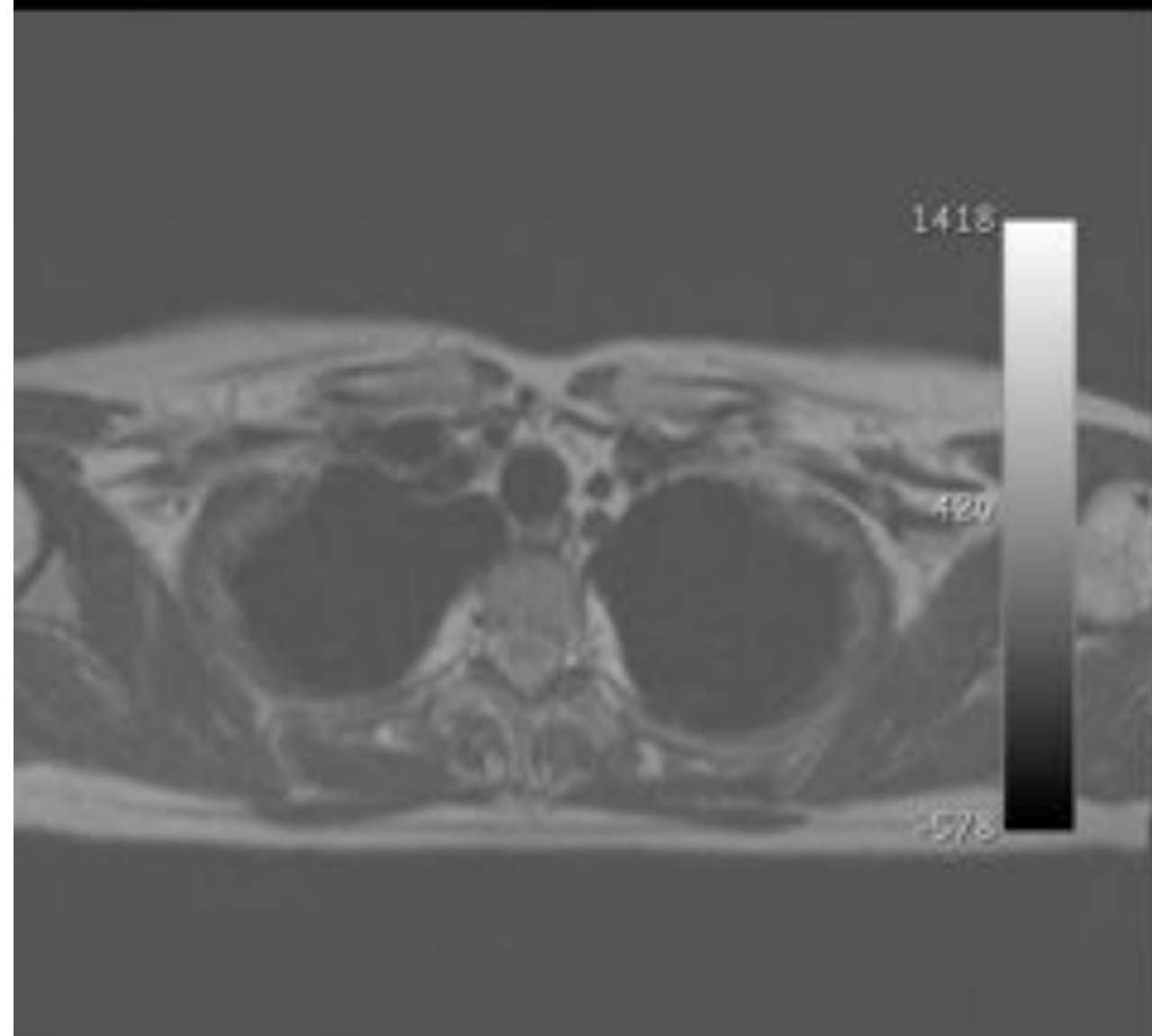


Plan de la crosse aortique

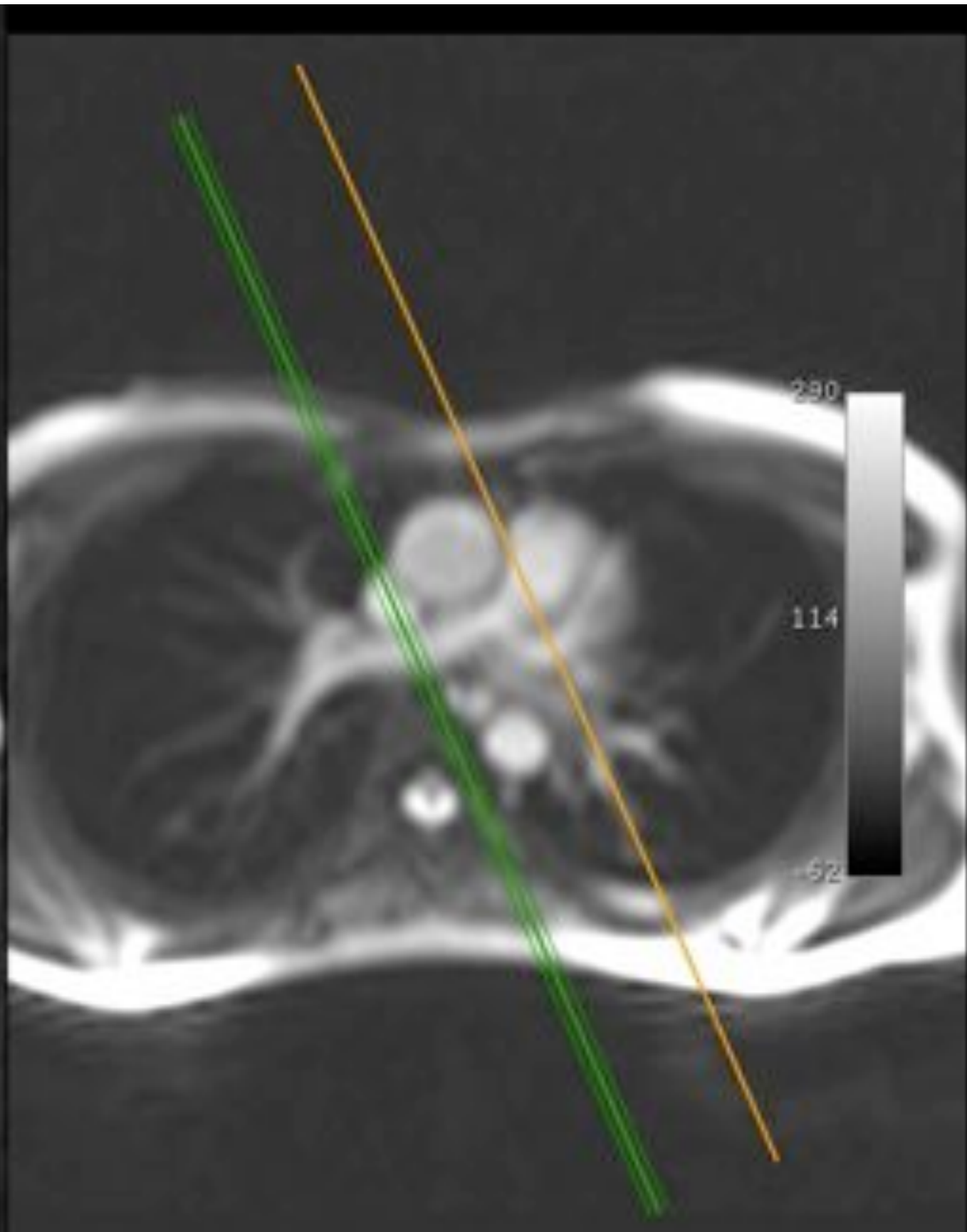
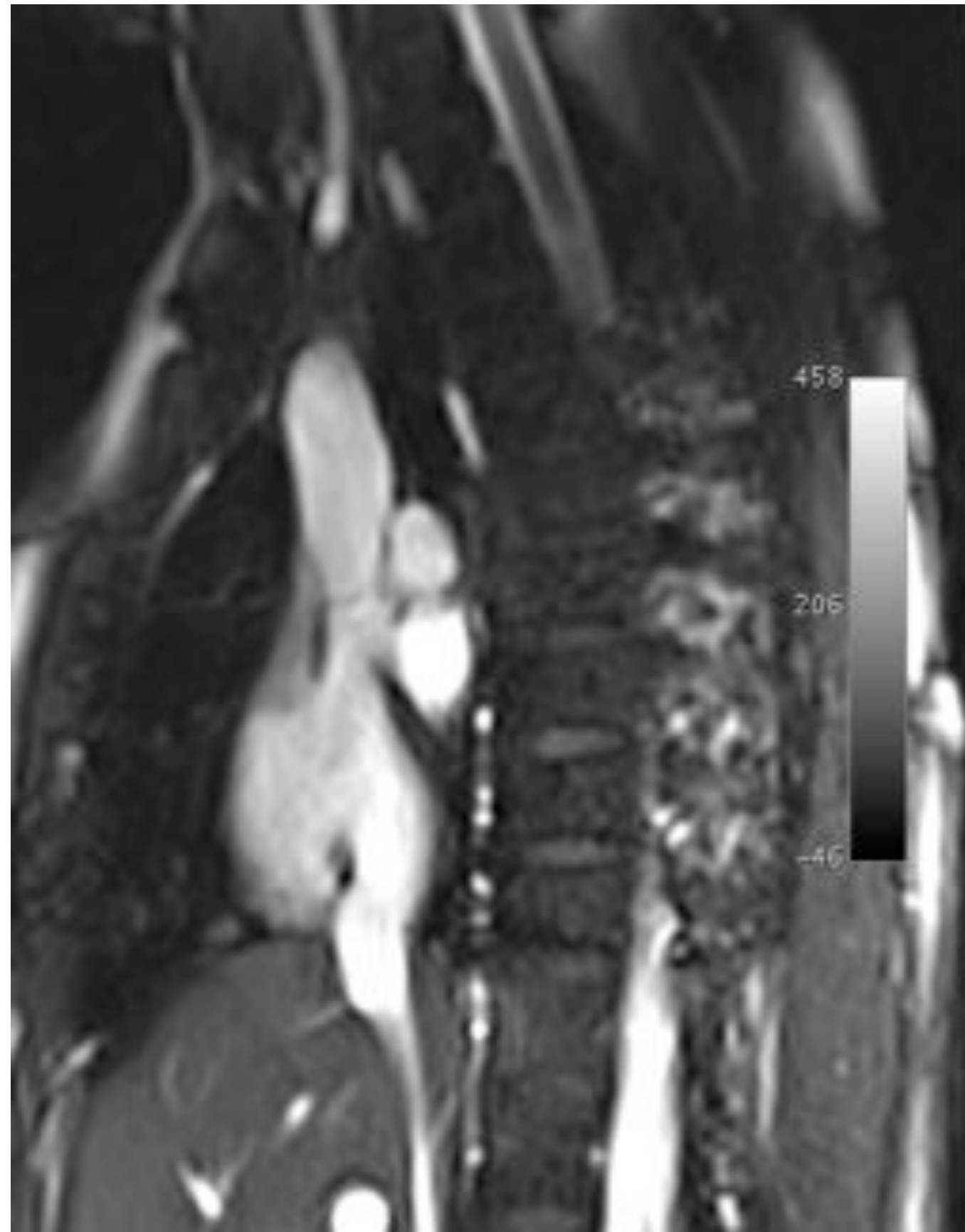
IRM







Plan de la crosse aortique



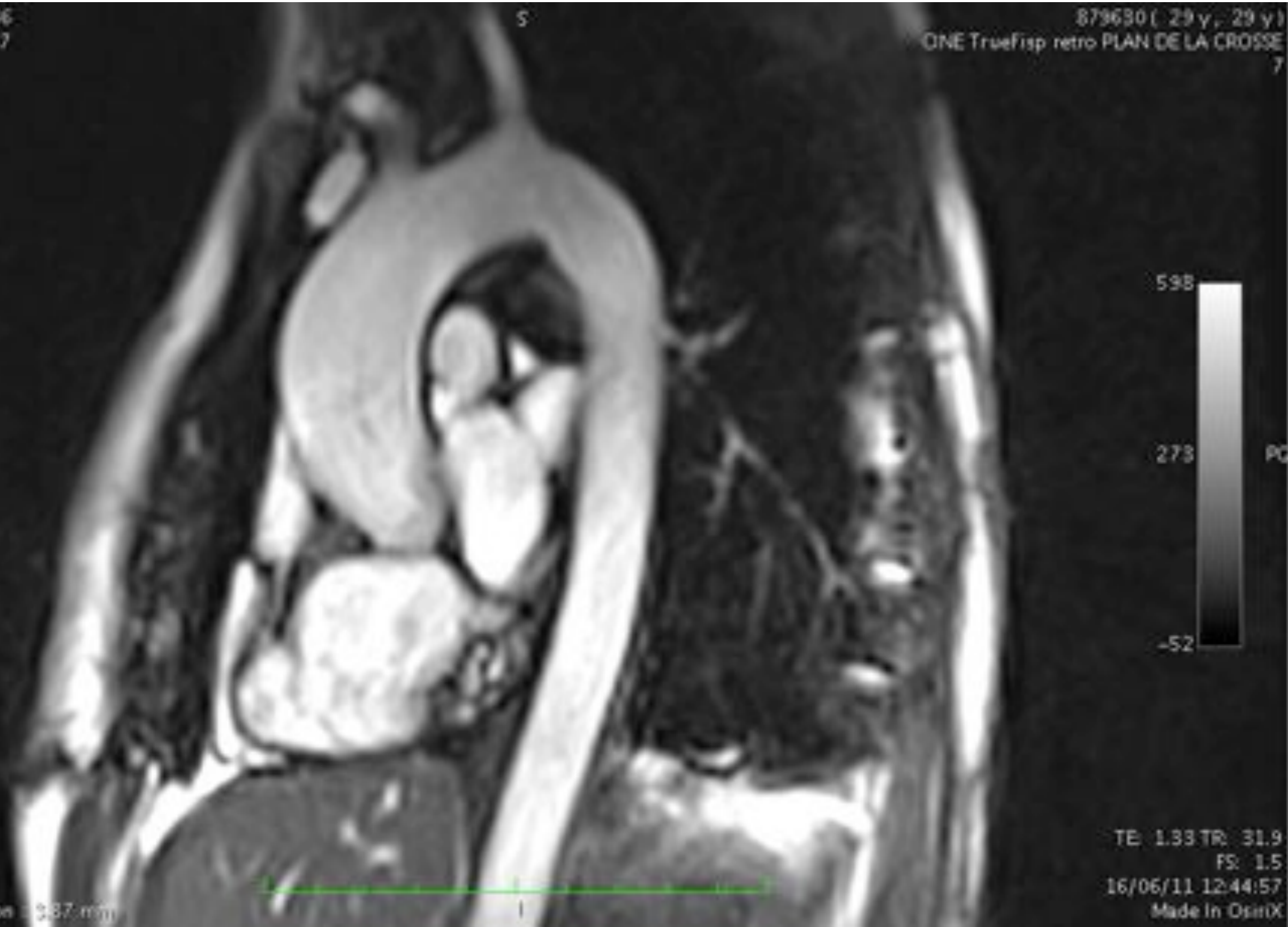Plan de la crosse aortique

l'image : 208 x 256
la vue : 1083 x 647
LF : 651

879630 (29 y, 29 y)
ONE TrueFisp retro PLAN DE LA CROSSE
7

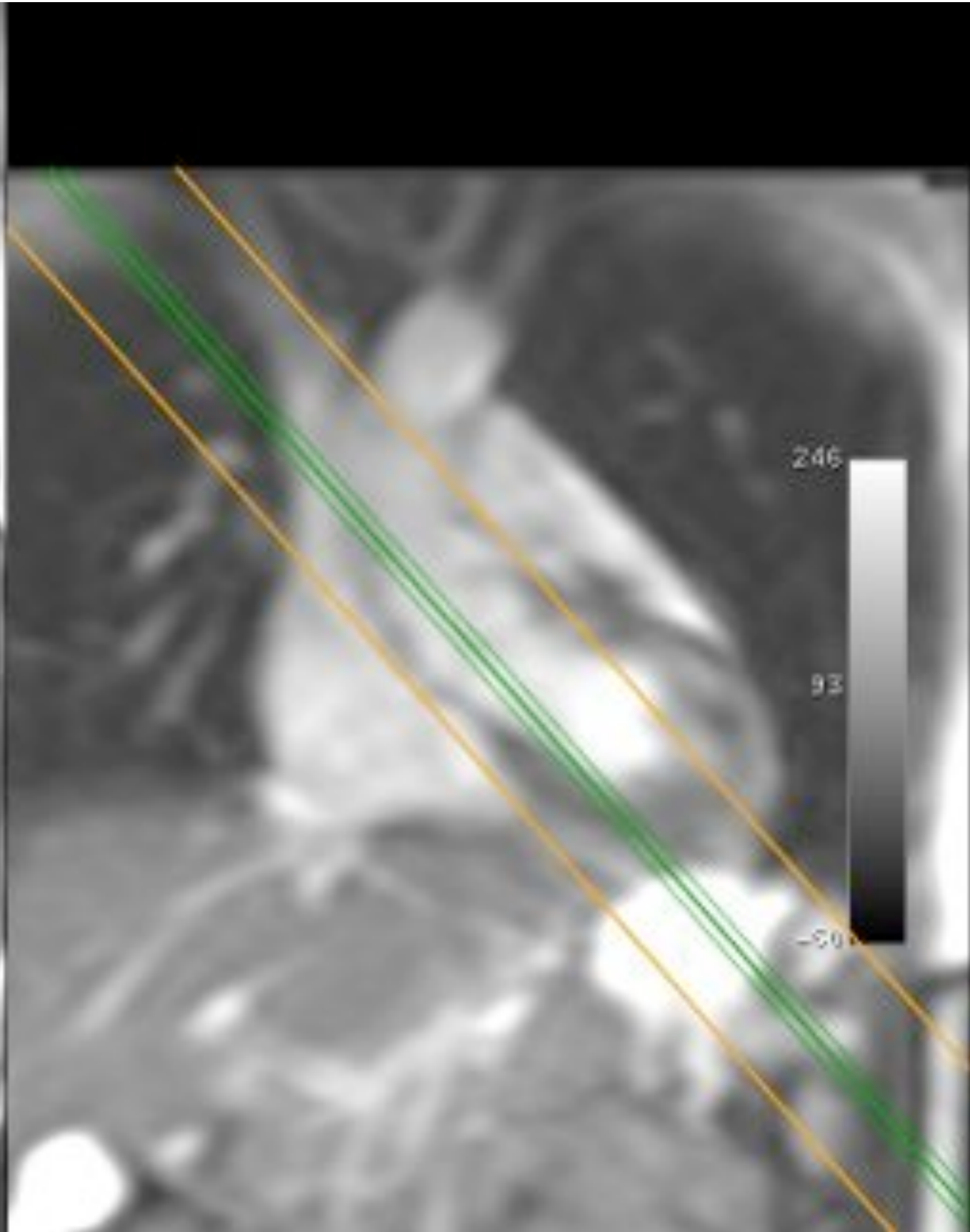
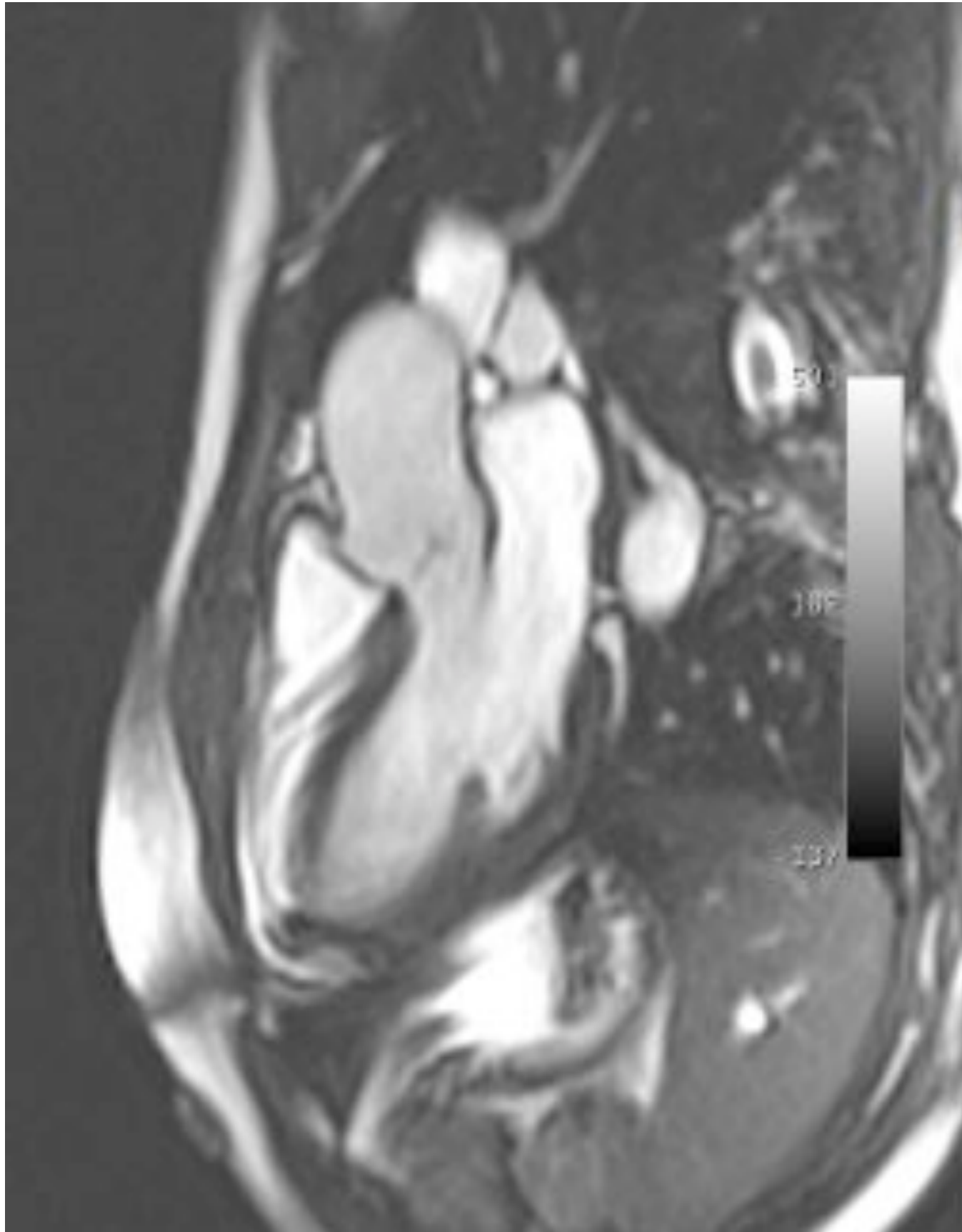
550% Angle : 0
/200
y : 5.00 mm Position : 887 mm

TE: 1.33 TR: 31.9
FS: 1.5
16/06/11 12:44:57
Made In Osirix



Coupe «3 cavités»

IRM




Coupe «3 cavités»

IRM

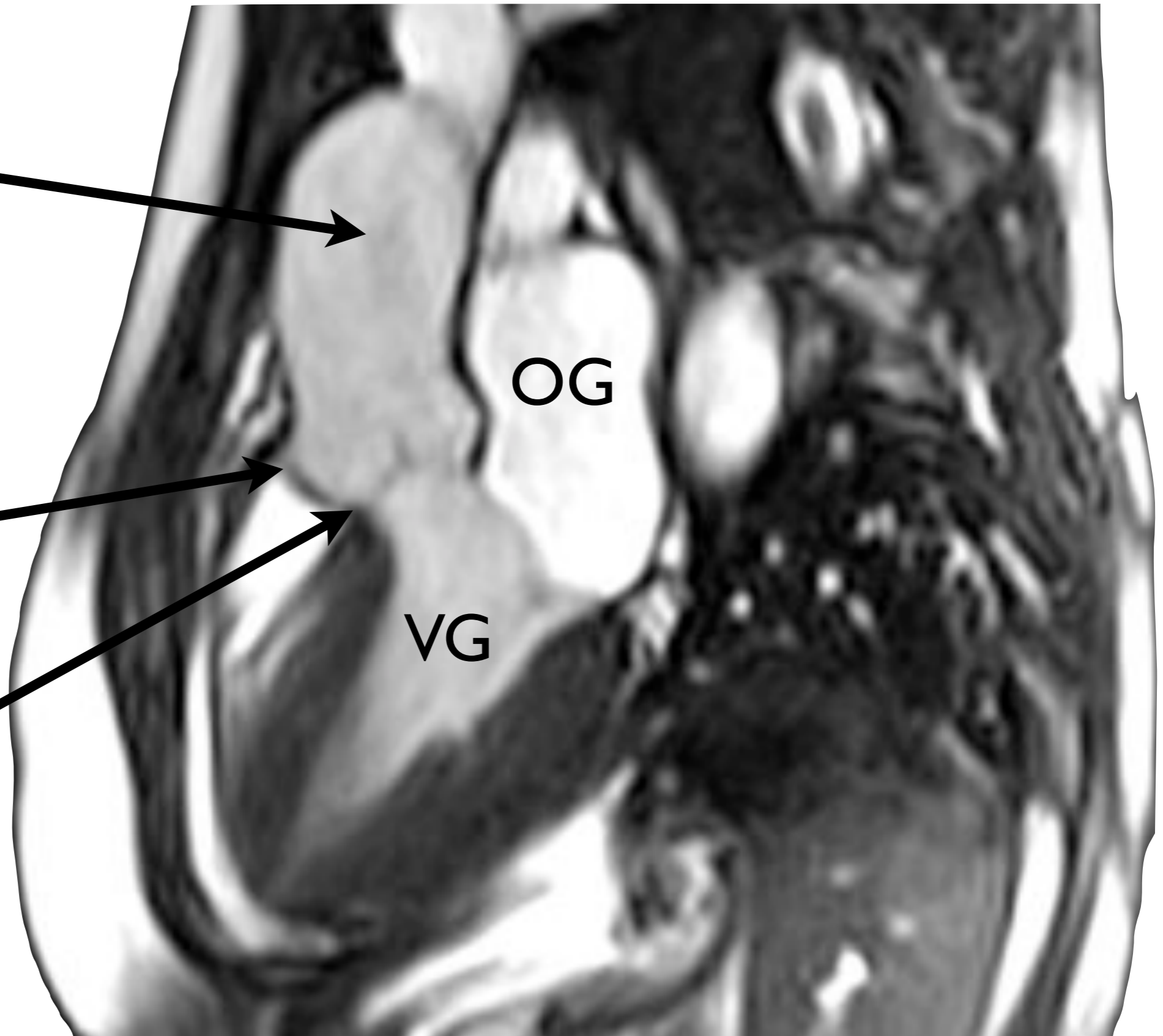

Ao Asc.



Sinus de Valsalva



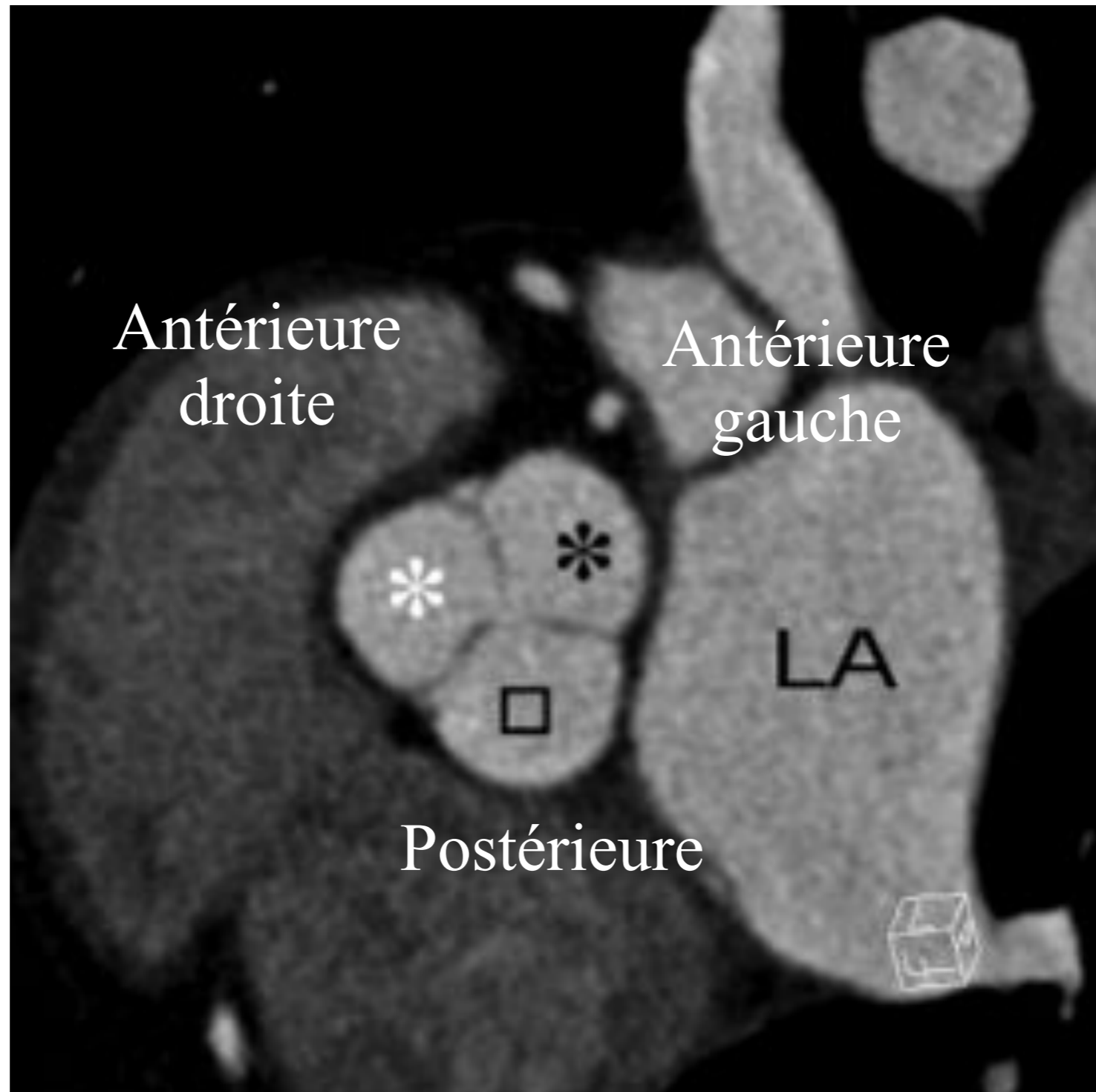
Valve aortique



OG

VG

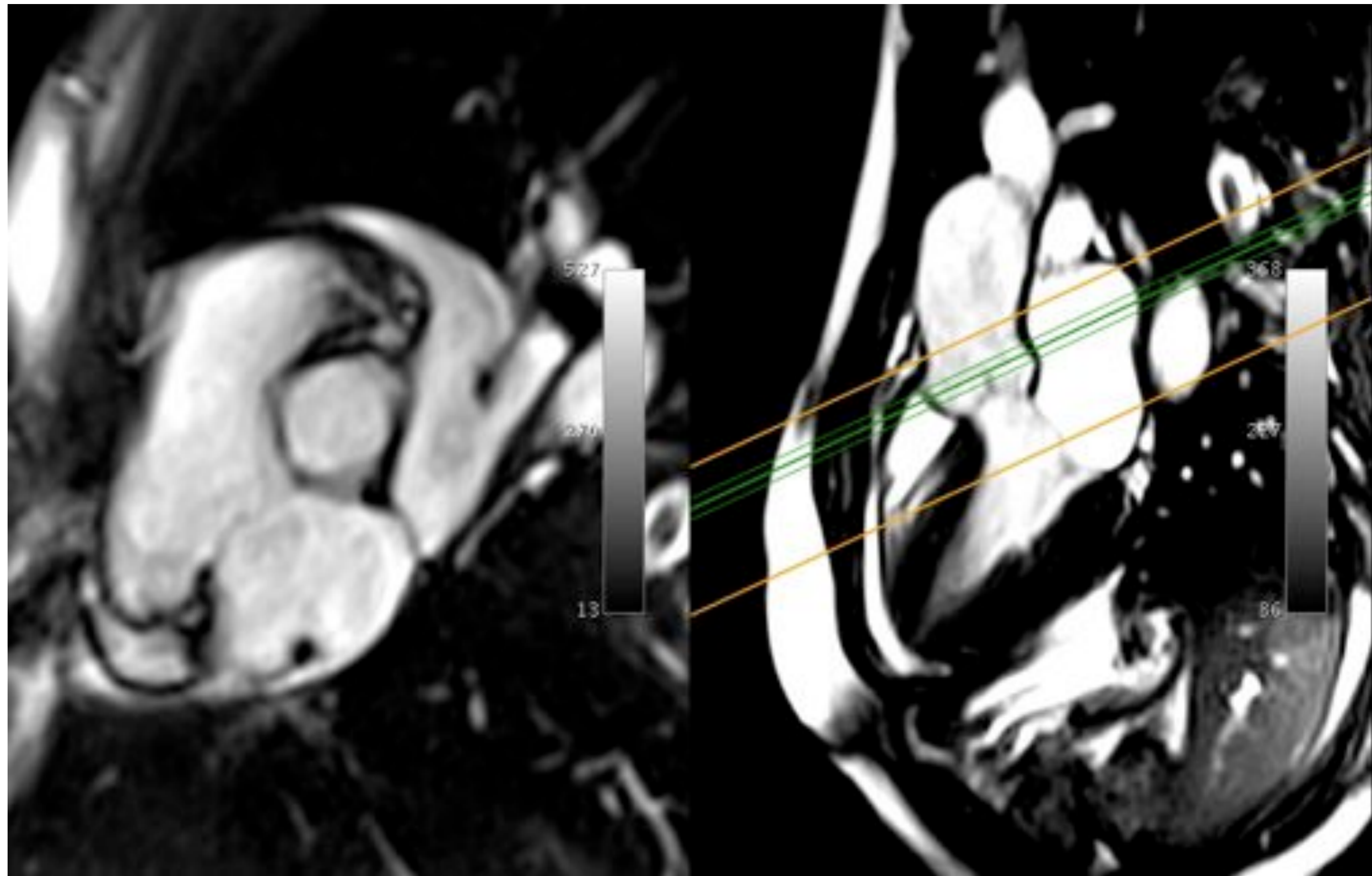
Valve Aortique



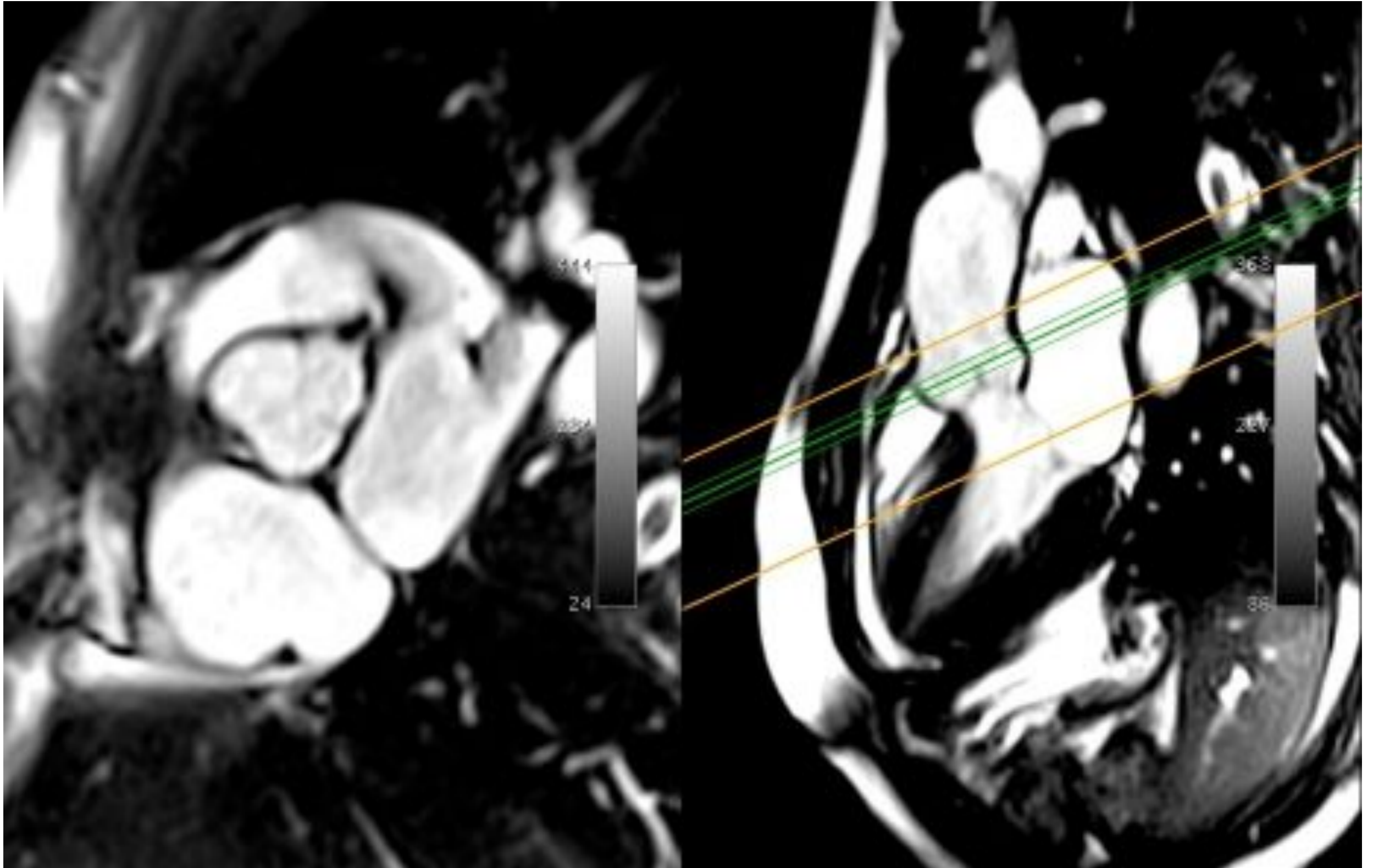
O'Brien, J. P. et al. Radiographics 2007;27:1569-1582

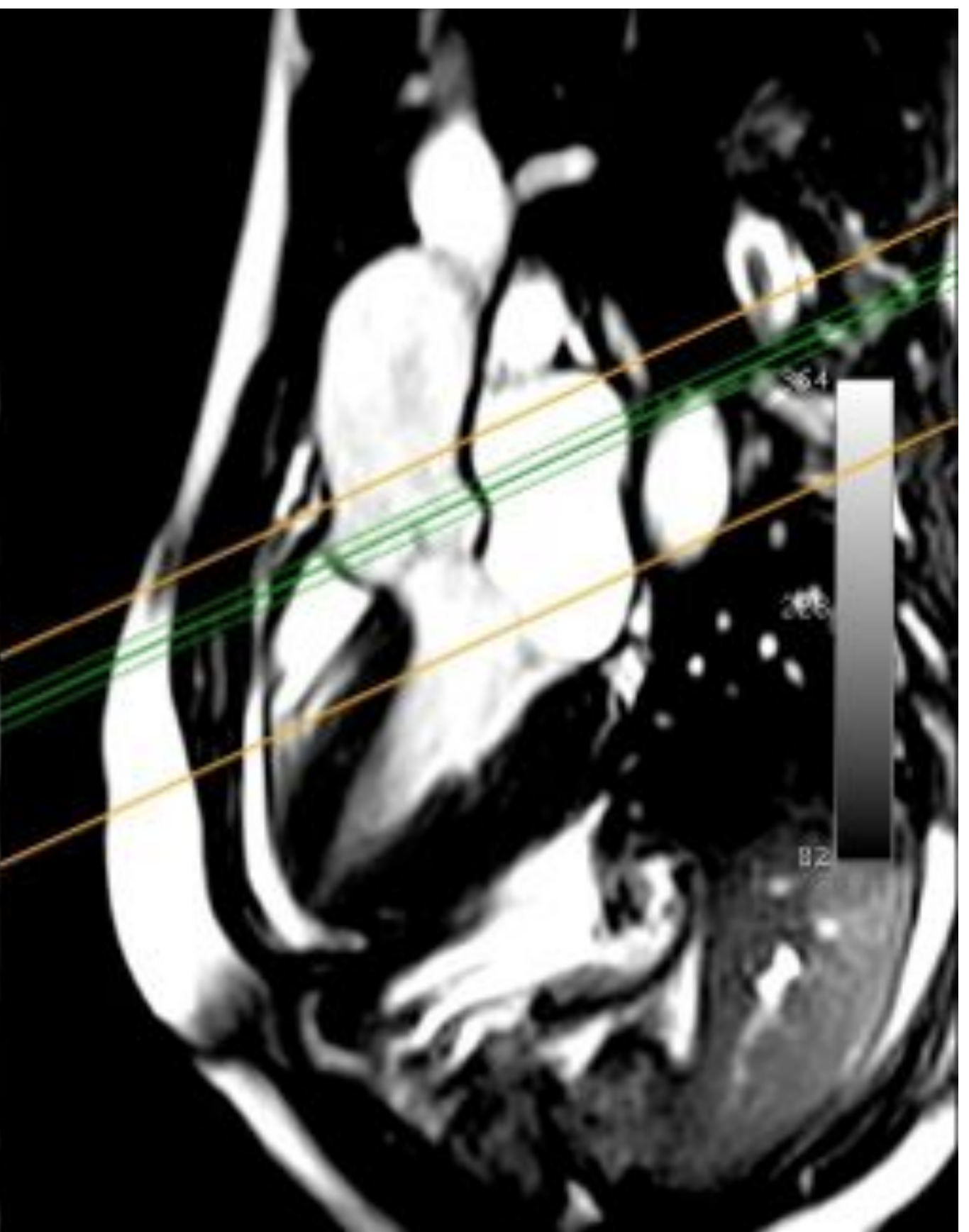
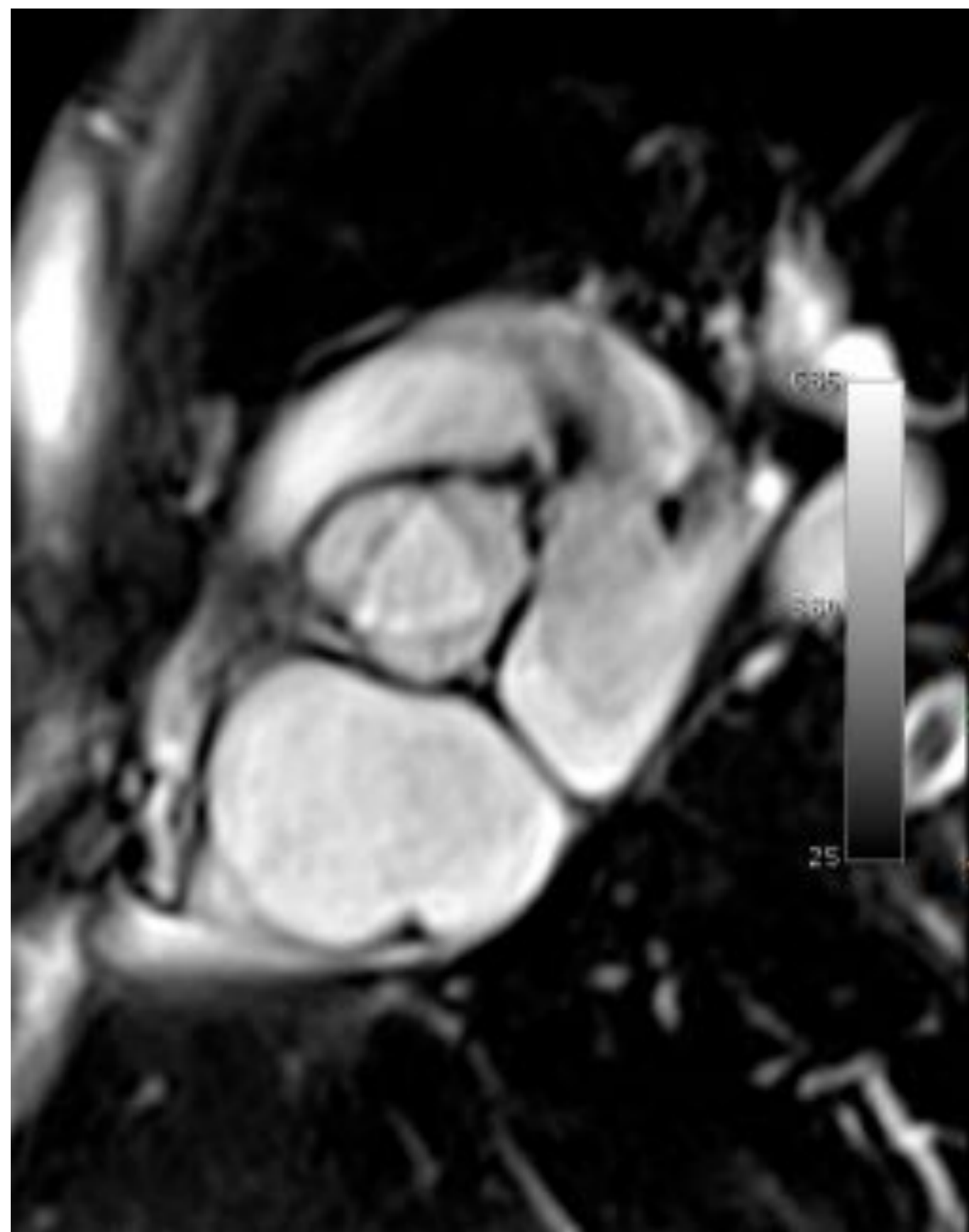
Radiographics

Plan de la Valve Aortique

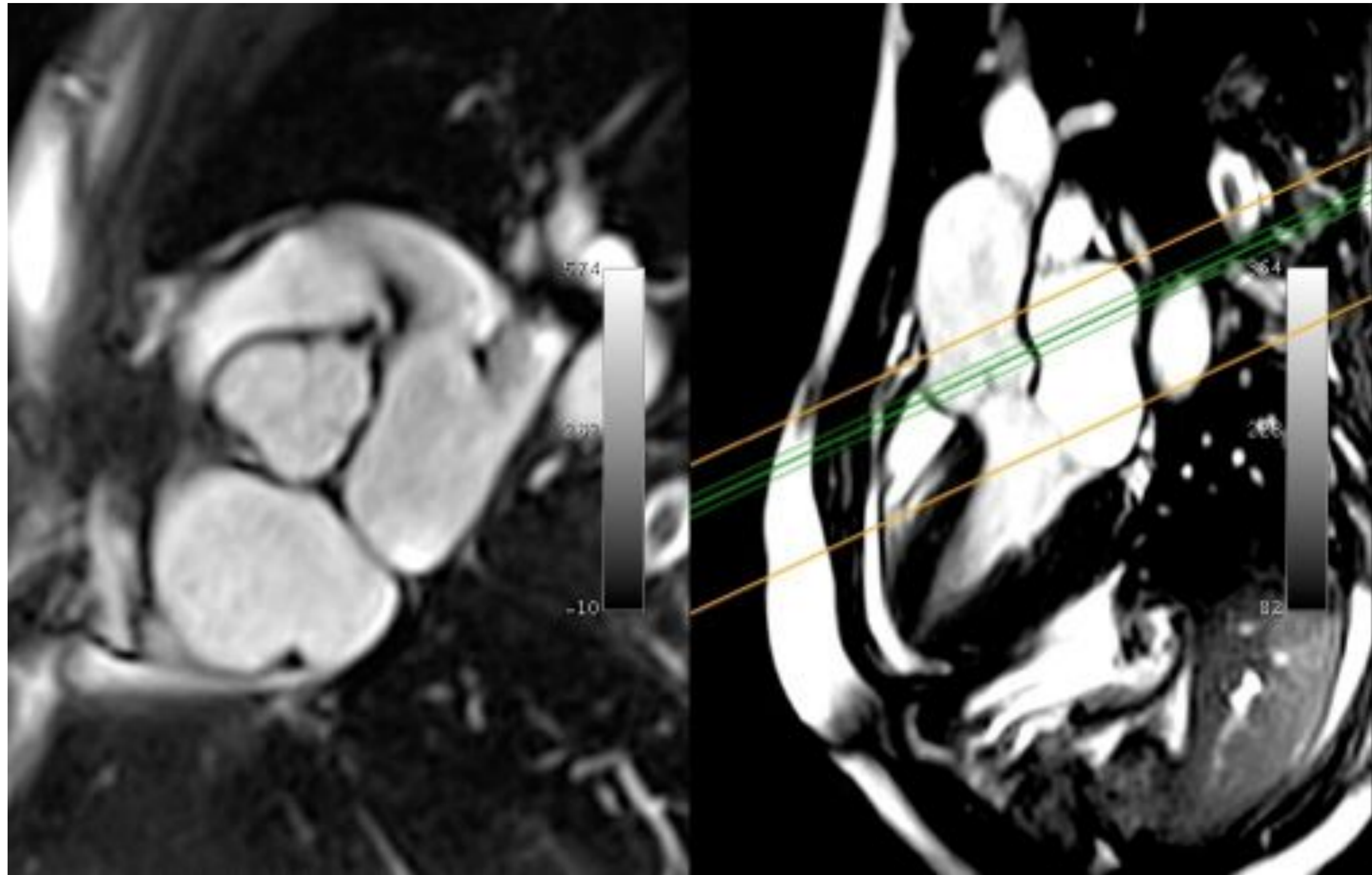


Plan de la Valve Aortique

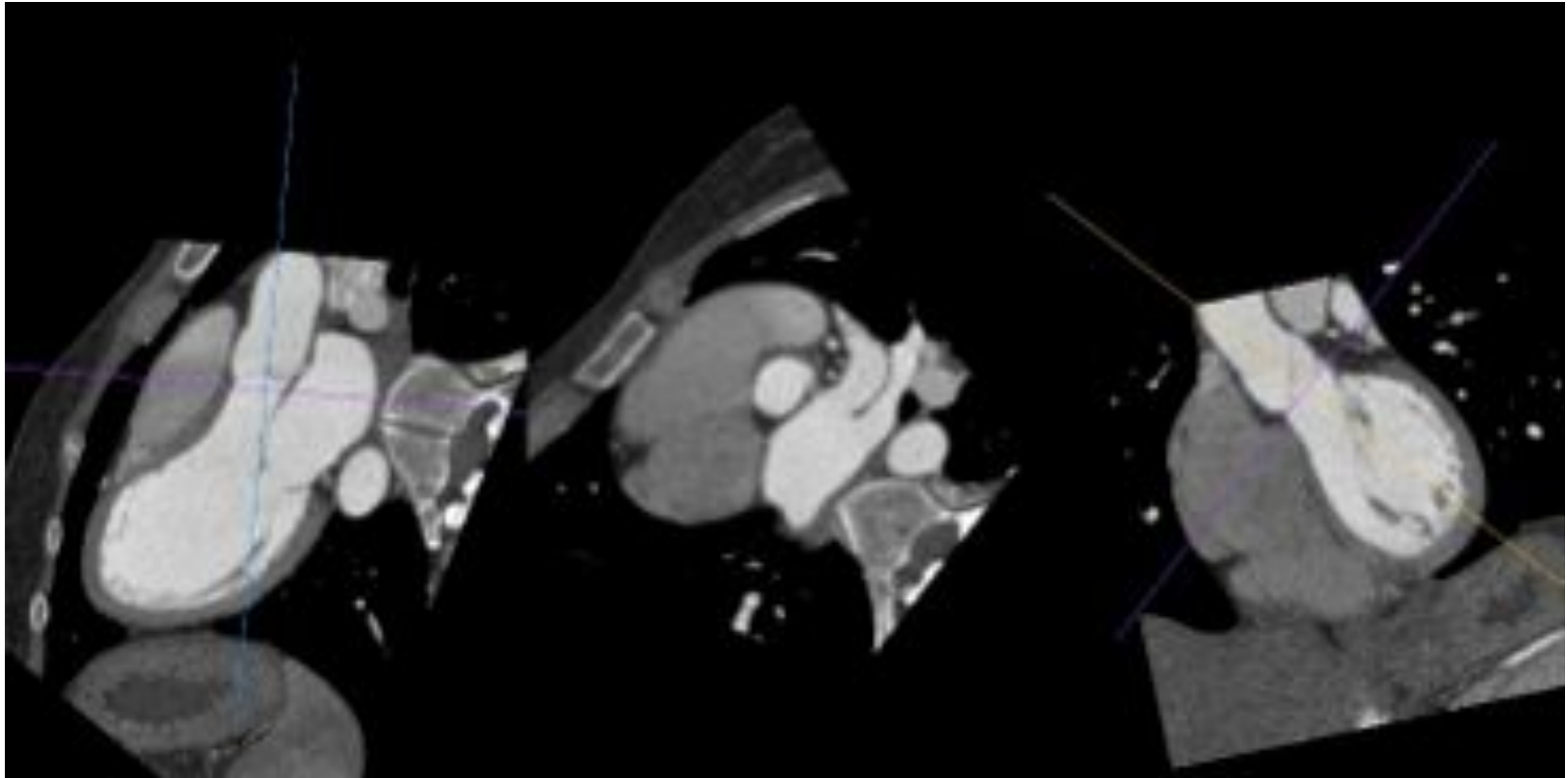




Plan de la Valve Aortique



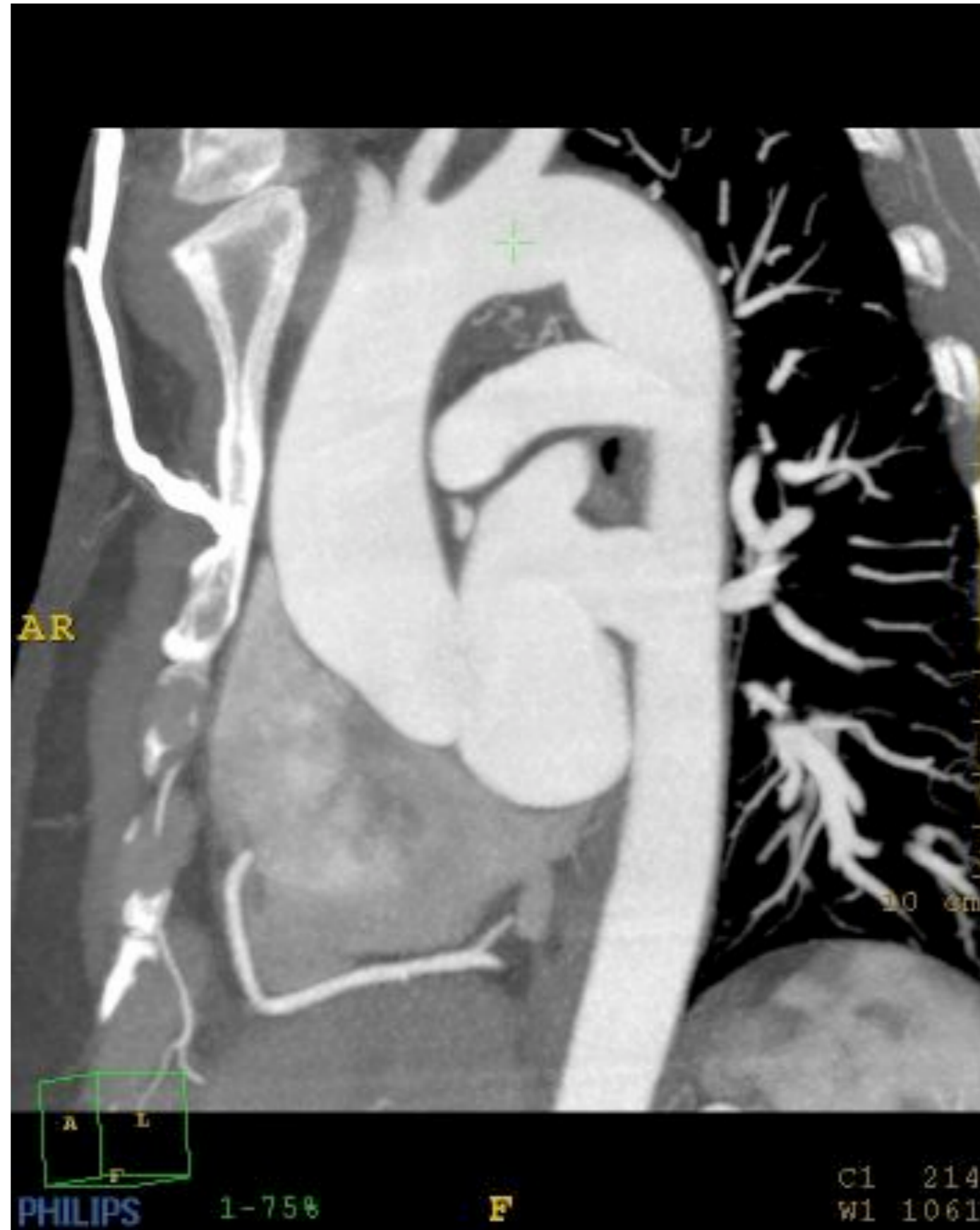Anneau aortique



Plan perpendiculaire à la chambre de chasse du VG, passant par les points d'insertion les plus bas de chacune des trois cusps

Plan de la crosse aortique

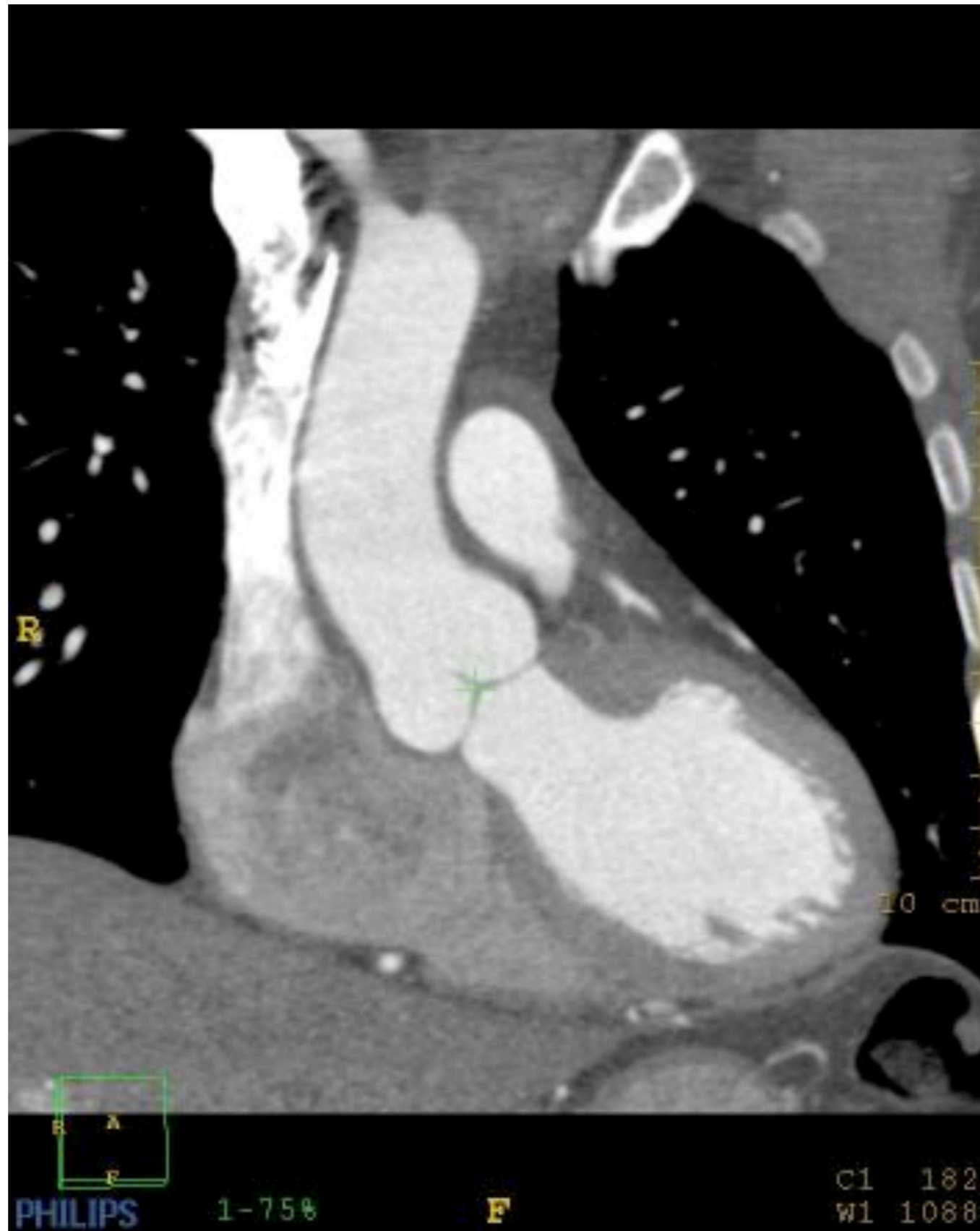
TDM



Plan frontal

TDM

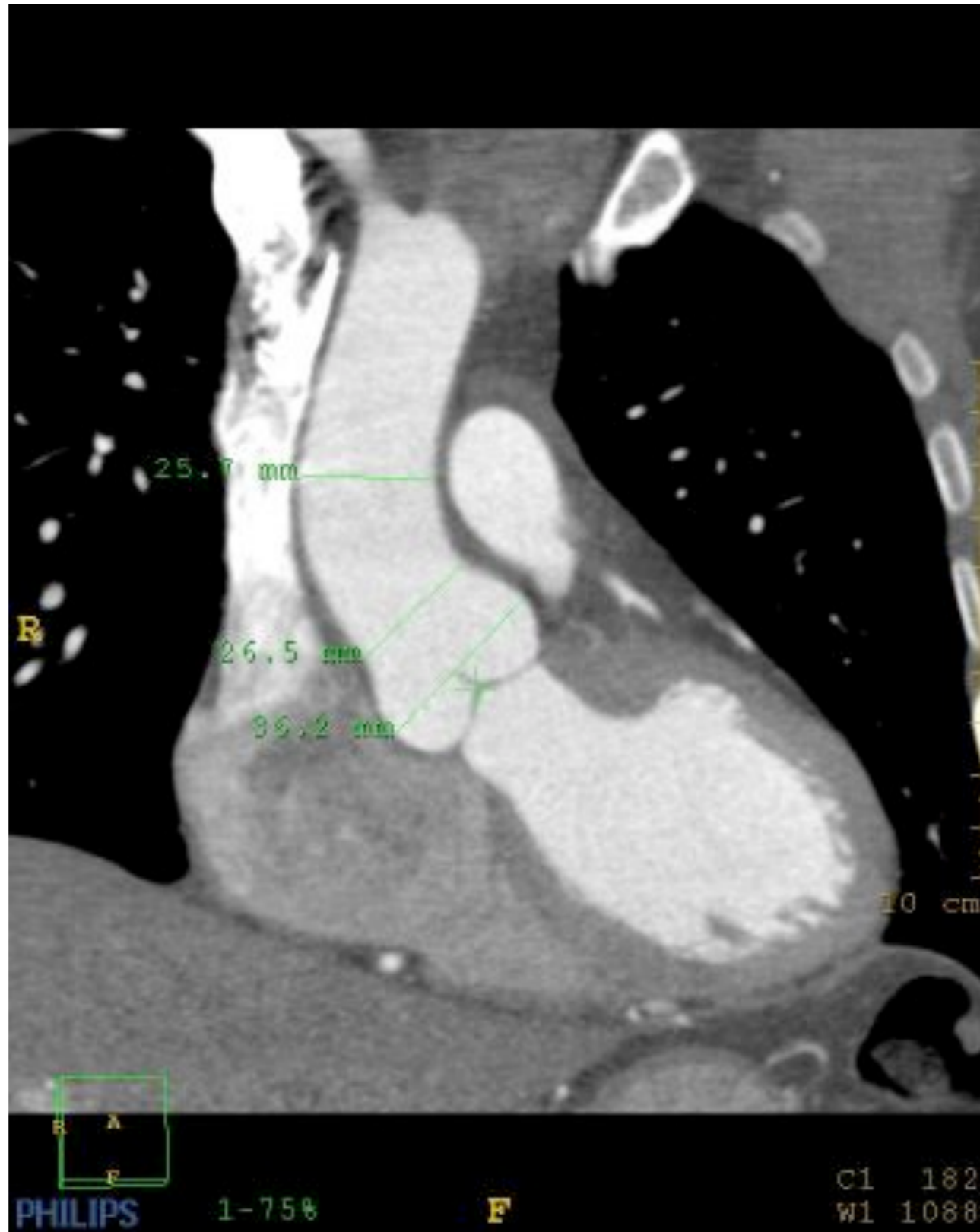
Dt

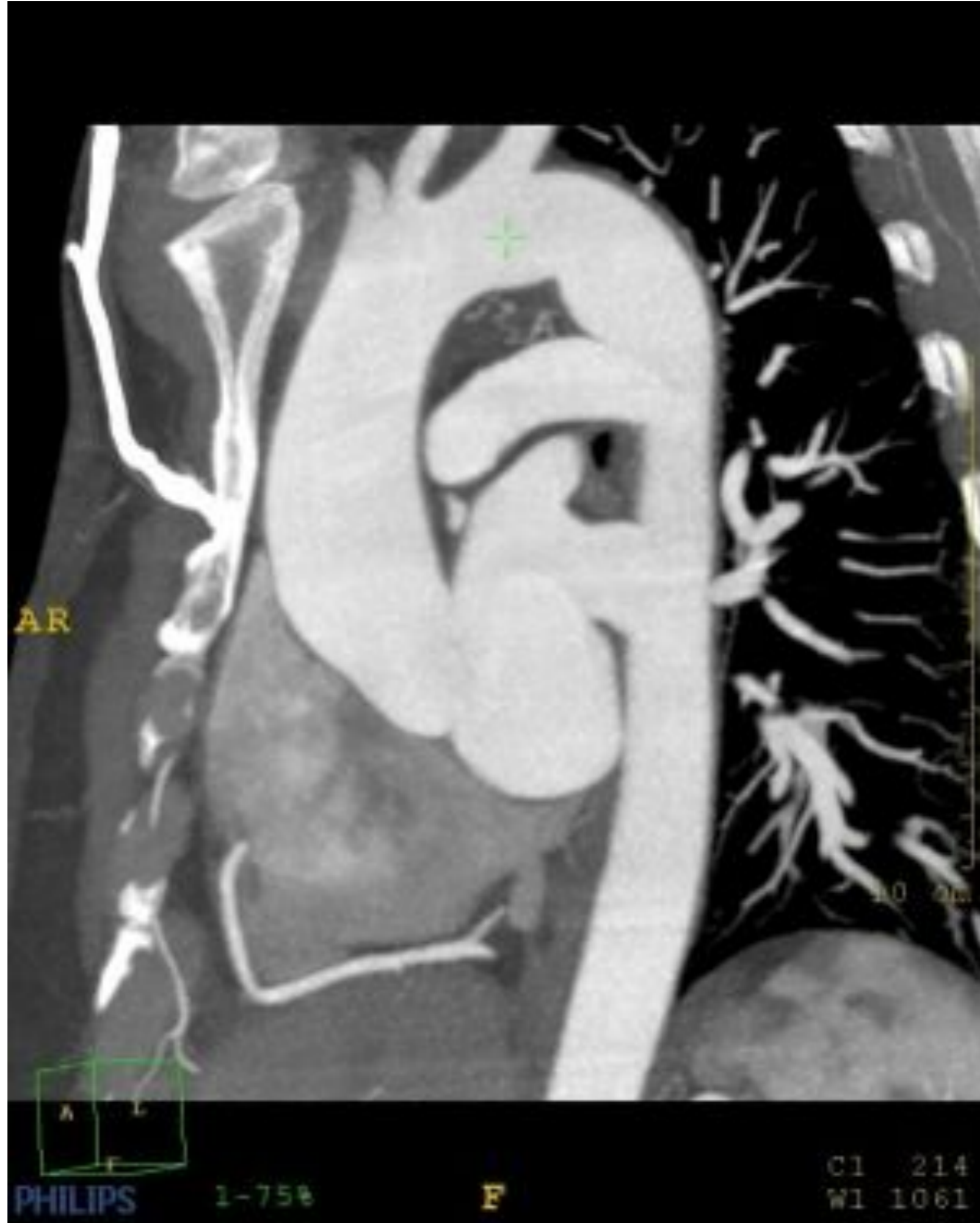


Plan frontal

TDM

Dt





Anatomie Cardiaque

- Examens d'imagerie spécifiques pour l'étude cardiaque
- Coeur dans le champ d'exploration d'un examen réalisé dans un autre but